

Seven-year follow-up for malrotation of a radial diaphysis fracture in a child corrected by osteotomy for loss of motion: A case report

JUN KOMATSU¹, NANA NAGURA¹, ATSUHIKO MOGAMI², HIDEAKI IWASE³ and KAZUO KANEKO¹

¹Department of Medicine for Motor Organs, Juntendo University Graduate School of Medicine,

Bunkyo-ku, Tokyo 113-8421; ²Department of Orthopaedic Surgery, Juntendo University Shizuoka Hospital;

³Department of Bio-Engineering, Juntendo University Institute of Casualty Center, Izunokuni, Shizuoka 410-2295, Japan

Received March 14, 2019; Accepted July 1, 2019

DOI: 10.3892/etm.2019.7932

Abstract. A greenstick fracture is an incomplete fracture where the compressive side of the cortex is still intact but plastically deformed. The incidence of poor results following the closed treatment of greenstick fractures in children >10 years of age is seriously underestimated. Therefore, fixing the position of the forearm is important for initial treatment. In cases of greenstick fracture, the possibility of inadequate remodeling of angulated deformities during growth, and in particular, the lack of correction between rotational malalignment and growth when the diaphyseal forearm is involved in the fracture, should be considered. A male, 10-year-old, left hand-dominant, Asian patient fell while playing in the garden and was immediately assessed by an orthopedic doctor at an Emergency Orthopaedic Clinic. Initial examination revealed a deformity of his dominant left forearm and an angulated greenstick fracture of the radius. However, after 3 months, he developed loss of supination of his left forearm and complained of limitation of left forearm supination. Radiography demonstrated a volar angulation of 20°. The patient underwent open reduction, internal fixation and 10° bending with a plate for correction without corrective rotation. At 12 months after injury, the patient did not exhibit pain or limitation of the elbow and wrist. After follow-up for 7 years, the patient was able to perform normal day-to-day activities with no adverse symptoms. The present case indicated that corrective osteotomy is required following the loss of supination after a greenstick fracture of the diaphysis of the radius. The patient of the current study exhibited rotation due to the central band of the interosseous membrane. In the treatment of greenstick fractures, a radius apex angulation of 20°

must be corrected via osteotomy due to loss of rotation. The present case indicated that corrective osteotomy of the radius apex alone without rotational correction, in combination with plate bending improved the loss of forearm rotation.

Introduction

The shape of the radius is important for normal forearm rotation. A forearm fracture is the third most common pediatric fracture (1-3), probably because the bones are weaker, and the gold standard for such fractures remains closed reduction and casting (2). These fractures are classified as greenstick, complete, or plastic deformation; 82.5% of forearm fractures are greenstick fractures (4). Rotational deformity occurs more often in greenstick fractures than in complete fractures, and the radius deformities are the direct effect of forearm rotation. Moreover, the diaphysis has less self-correction ability, and the rotation transposition is not corrected (2). Such fractures are treated by correcting the rotational and angular malalignments simultaneously by reversing the mechanism of injury, with follow-up radiography at >6 weeks (3). On the other hand, malunion of pediatric forearm fractures can cause permanent functional disability with limitation of forearm rotation. In children with functional disability, corrective osteotomy is indicated when there is malunion of a fracture in the midshaft of the forearm (5).

In this study, malrotation of the forearm that resulted in a malunion of a diaphyseal fracture of the radius 3 months after injury is presented. Radius apex angulation was improved by corrective osteotomy. This study suggests that the anatomic characteristics of the interosseous membrane affect forearm greenstick fractures. The interosseous membrane contributes to forearm stability, especially the central band (CB), which consists of a thin membranous part and a thick ligamentous part, that interferes with rotation after a forearm fracture (6,7). Based on the literature, we suggest that the fixed position of the forearm is important for the initial treatment of greenstick fractures, and radius apex angulation of 20° must be corrected by osteotomy due to loss of rotation. In the present case, follow-up at 7 years demonstrated full range of wrist and elbow movement and no adverse symptoms, and no malunion was observed on radiographs of the forearm.

Correspondence to: Dr Jun Komatsu, Department of Medicine for Motor Organs, Juntendo University Graduate School of Medicine, 2-1-1 Hongo, Bunkyo-ku, Tokyo 113-8421, Japan
E-mail: jkomatsu@juntendo.ac.jp

Abbreviation: CB, central band

Key words: radial diaphysis, greenstick fracture, malrotation, corrective osteotomy, interosseous membrane

Case report

A 10-year-old, left hand-dominant, Asian boy fell from a height of 1 meter playing in the garden. He noticed pain and swelling around his forearm and presented immediately to a nearby emergency department. Initial examination showed deformity, tenderness, and swelling of his left forearm. Full-length forearm radiographs were performed, confirming an angulated greenstick fracture of the middle third of the radius (Fig. 1). The radiographic diagnosis was incomplete fracture of the diaphysis of the left radius. The limb was fixed by a plaster slab with the forearm in the neutral position without repositioning. Three weeks after the injury, follow-up radiographs were taken (Fig. 2). However, after 3 months, loss of supination of the left forearm appeared, and he presented to our emergency department with limitation of supination of the left forearm. The left forearm range was 45° with the forearm in supination and 100° in pronation (Fig. 3). Range of motion of the elbow and wrist was unlimited, and there was no tenderness at the fracture and interosseous membrane. Radiography showed volar angulation (20°; Fig. 4).

The following day, the injury was treated surgically under general anesthesia. Written, informed consent was obtained from the patient and the patient's legal guardian for publication of this case report and any accompanying images. A copy of the written consent is available for review by the Editor-in-Chief of this journal. Open reduction and internal fixation of the radial shaft fracture were performed using a 1/3 tubular plate with 4 holes with screw diameters of 3.5 mm (standard cortical screws; Synthes, Paoli, PA) (8,9), which were bent 10° for corrective fixation (Figs. 5 and 6). Rotation was not corrected; only the apex angulation was corrected through an anterior approach to the radius.

At 12 months, the patient had no pain or limitation of the elbow and wrist and could carry out his normal day-to-day activities. The range of motion was 0-130° at the elbow, extension of 70° and flexion of 80° at the wrist, and supination of 85° and pronation of 90° at the forearm, although the radius showed a volar angulation deformity of 10° on radiographic examination (Fig. 7).

The patient had full range of movement of his left forearm and underwent plate removal from the left radius under general anesthesia 2 years after the corrective surgery. Moreover, follow-up at 7 years demonstrated the full range of wrist and elbow movements and no adverse symptoms. Postoperative radiographs at the 7-year follow-up evaluation (Fig. 8) demonstrated improved radiographic parameters, including improved alignment of the hand and elbow.

Discussion

A greenstick fracture is an incomplete fracture in which the compressive side of the cortex is still intact but plastically deformed. The incidence of poor results from closed treatment of such fractures in children greater than 10 years of age is seriously underestimated (10-12). Therefore, the fixed position of the forearm is important in the initial treatment of greenstick fractures, and in a case with radius apex angulation of 20°, we suggest that osteotomy must be performed for loss of rotation. The point of this study is that attention should be

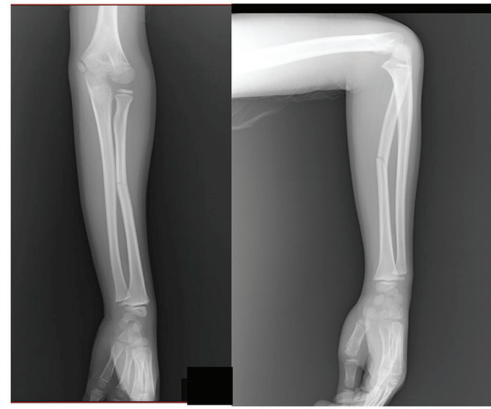


Figure 1. Initial radiographs at the previous orthopedic clinic revealed diaphyseal fractures of the radius. Full-length forearm radiographs were requested, which confirmed fracture of the middle third of the radius. An angulated greenstick fracture of the radius is presented.

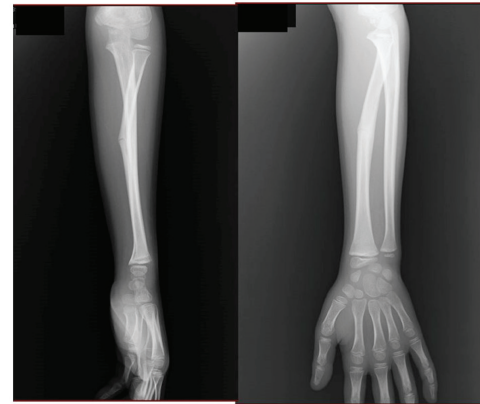

Figure 2. Radiographs demonstrating the displacement of both forearm bone fractures two months after the injury occurred. The fracture appears reduced in the neutral position. Bowing apposition with minimal angulation and rotational malalignment was accepted in the first orthopedic clinic. The fracture healed in this position.

paid to the position of fixation in conservative treatment and that the rotational limitation of the forearm recovered without correcting the rotation of the radius with only correction of apex angulation by corrective osteotomy. Although it has been an issue in the past, this is not well known in actual clinical practice. In fact, even in this case, a mature orthopedic surgeon had developed rotational deformation due to the insufficiency of the fixed position in conservative treatment. We need to reconfirm it as a warning to orthopedic surgeons including us. Although fractures in children are neglected, I think it is crucial in that there are few articles that report cases of indications for corrective osteotomy of diaphyseal forearm in children (13). In addition, I think that it is rare to observe cases up to 7 years after surgery.

It has been previously reported that adequate remodeling of angulated deformities in children did not occur with growth, particularly when the diaphyseal forearm was involved in the fracture, and there was also no correction of rotational malalignment with growth (14,15). Permanent functional disability with limitation of forearm rotation can occur in children with malunion of forearm fractures. A previous study showed that,

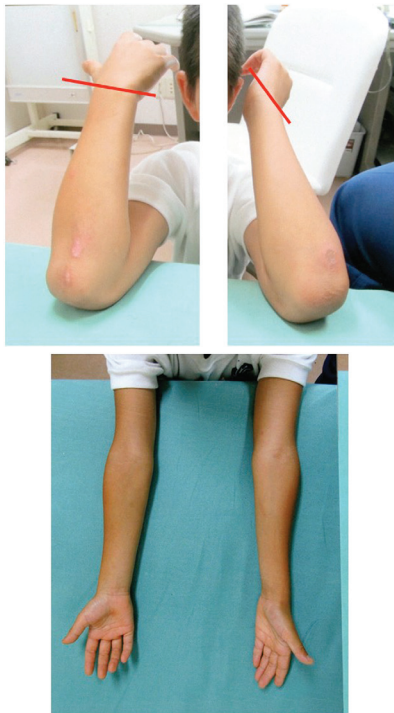

Figure 3. The patient was admitted to the Emergency Department of Juntendo University Shizuoka Hospital (Shizuoka, Japan) after exhibiting limitation of supination in the left forearm. The left forearm range of motion was 45° in supination and 100° in pronation. The red line indicates malalignment of the forearm with rotation and limited supination.

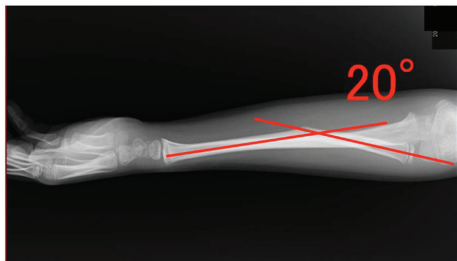


Figure 4. Radiographs obtained at the patient's initial visit to Juntendo University Shizuoka Hospital (Shizuoka, Japan) during which he exhibited imitated supination of the left forearm. Radiography revealed a volar angulation of 20° (horned transformation) and malrotation.

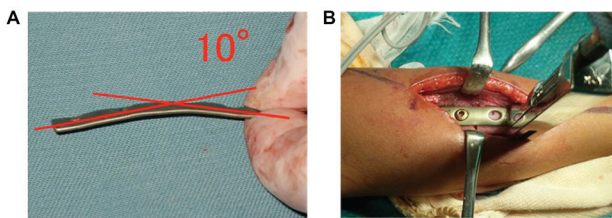


Figure 5. Surgical results. Bone osteotomy was performed at the fracture line. The malunion of the fracture was corrected via angulation and fixation (A) with a 10° bent plate (B) without overcorrection and rotation.

for pediatric forearm fractures, the age of 10 years was the limit for conservative therapy, because self-correction ability starts to decrease at ≥10 years, and it then disappears between 12 and 13 years (8). Furthermore, the self-correction ability of

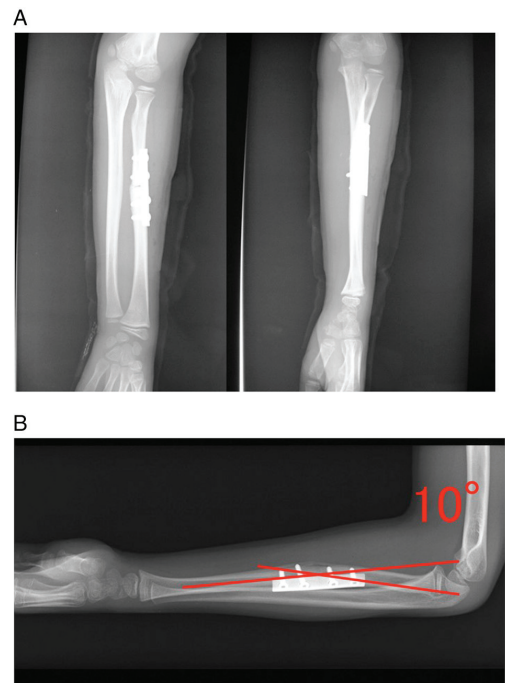


Figure 6. Postoperative antero-posterior and lateral radiographs of the forearm. (A) The postoperative antero-posterior and lateral radiographs of the forearm. (B) Angular deformation of 10°. The range of motion was improved to 90° in supination and 85° in pronation, with no difference compared with the right forearm.

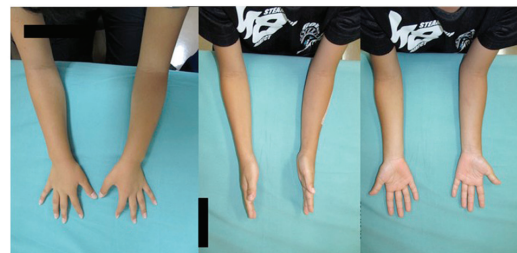
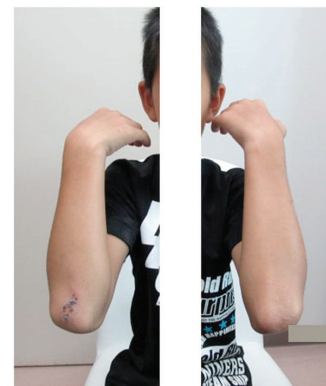

Figure 7. Images obtained at the last clinical examination, 12 months following injury. Follow-up clinical images obtained 12 months after injury revealed full elbow flexion/extension and full forearm supination/pronation.

the diaphysis is less, and there is no correction of the rotational transposition. Forearm diaphysis fractures are unforgiving, and because diaphyseal bone has less remodeling capacity, less angulation is acceptable (16). Therefore, when stable fractures or displaced fractures can be anatomically reduced correctly,

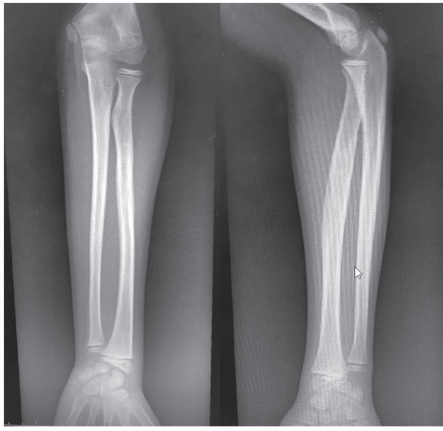


Figure 8. A total of 7 years after surgery, antero-posterior and lateral radiographs of the forearm were obtained. The compatibility of the distal and proximal radioulnar joint was good and no malunion was observed.

conservative therapy with a long arm cast is the first-choice therapy. In patients 0 to 8 years of age with fracture angulation $>20^\circ$ and malrotation $>45^\circ$, closed reduction is indicated. Similar studies have reported that sufficient remodeling of malunion of $20\text{--}30^\circ$ is unlikely after 9 years of age, and that such cases require correction as soon as soft tissue recovery from the initial immobilization has occurred (13). Moreover, patients 8 to 14 years of age with fracture angulation $>5^\circ$ and malrotation $>30^\circ$ require closed reduction (17). In clinical practice, the forearm rotation range is $145\text{--}170^\circ$, and 50% restriction of excursion is accepted. On the other hand, function is not impaired with loss of $20\text{--}30^\circ$ of rotation; moreover, loss of supination presents more problems than loss of pronation (18). A previous study showed that, in forearm diaphyseal fractures, loss of rotation can occur with angulation of $15\text{--}20^\circ$ (16).

It has previously been shown that excellent functional results can be obtained with a corrective osteotomy technique with few complications. Therefore, corrective osteotomy should be performed at the earliest opportunity (19). In recent studies, three-dimensional-planned, patient-specific guides and implants have been shown to facilitate precise corrective osteotomies of complex multiplanar forearm deformities, and the preliminary results have been satisfactory (20-22). However, another study indicated that, with an accurate understanding of forearm anatomy and appropriate X-ray views (with the tuberosity of the radius approximately on the opposite side of the radial styloid process), the corrective osteotomy procedure can be simplified and performed with fluoroscopy alone, without the need for computed tomography (13). Osteotomy was performed in the present patient only with correction of apex angulation, based solely on knowledge of the anatomical structure of the forearm and fluoroscopy.

The radius bent anatomically in our patient, with a possibility that rotational malalignment occurred at the same time as the apex deformity, but our concern was about dissection and the function of the interosseous membrane. A previous study suggested that rotation caused the apex to remain anterior (23). In addition, when there are angular deformities of the radius and ulna, tension is produced in the interosseous membrane, and this tension impairs the radius's rotation around the mechanical axis of the forearm (24).

Angulation of the apex in this case increased from 10° to 20° due to the interosseous membrane, which consists of a thin membranous part and a thick ligamentous part, the CB, which has 2 to 3 times the thickness of the membranous part, is responsible for 71% of interosseous membrane stiffness, and is the second principal stabilizer of the radius. The CB contributes to the stability of the radius (25). The CB leads to the ulna from approximately 62% of the distal radius (25). In the present case, radius fracture lines may have been proximal to the footprint of the CB band, so that the X-rays indicated horned transformation of the fracture with the pronated position short arm spica cast and the distal fragment pulled by a distal CB band. Therefore, the radius appeared to be pronated through the CB of the interosseous membrane because this was a greenstick fracture, and the radius changed onto the palm side, with loss of supination. It seems that the width of the interosseous membrane is smallest in pronation (radius and ulna closer) due to an anatomical feature of the interosseous membrane related to the supination limit; the interosseous membrane width is greatest in the middle rank (radius and ulna far) in a neutral or slightly supinated position (approximately 30°), but the repositioning suggested of forearm fractures in this position is unstable.

Although the possibility of contracture of the interosseous membrane was considered in the present case, the patient complained of loss of supination of the left forearm without tenderness or induration. In the surgery, pronation became smoother with osteotomy of the fracture region, and contracture of the interosseous membrane seemed unlikely. Of note, the rotational limitation of the forearm recovered without correcting the rotation of the radius with only correction of apex angulation by the plate that was bent 10° by corrective osteotomy. Taking into account previous studies (16,17), it was necessary to correct apex angulation less than 15° ; therefore, including the correction that would occur by remodeling, it was decided to correct the angle at 10° . This study was similar to and consistent with a previous study (23).

Thus, apex angulation of pediatric forearm bone fractures of 20° cannot be permitted, and the deformity must be reduced at the patient's first visit, if possible. It is also necessary to consider changing the plan if the forearm deformity is greater than 20° during conservative treatment.

In conclusion, this case suggests that corrective osteotomy was needed for loss of supination after a greenstick fracture of the diaphysis of the radius. In the present patient, there was rotation due to the CB of the interosseous membrane. In the initial treatment of greenstick fractures, the fixed position of the forearm is crucial, and radius apex angulation of 20° must be corrected by osteotomy due to loss of rotation. This case indicates that the corrective osteotomy of the radius apex alone, without rotational correction, with bending of the plate improves the loss of forearm rotation. Follow-up at 7 years demonstrated the full range of elbow and wrist movements and no adverse symptoms, and no malunion was observed on radiographs of the forearm.

Acknowledgements

Not applicable.

Funding

No funding was received.

Availability of data and materials

The datasets used and/or analyzed during the current study are available from the corresponding author on reasonable request.

Authors' contributions

JK and NN analyzed and interpreted the data, wrote the manuscript and organized the figures. JK, AM and KK performed the surgery. JK, NN and HI designed the study, edited and reviewed the manuscript and approved the version to be published. All authors reviewed and approved the final version of the manuscript.

Ethics approval and consent to participate

Not applicable.

Patient consent for publication

Written informed consent for the publication of patient data and accompanying images was obtained.

Competing interests

The authors declare that they have no competing interests.

References

- Cheng JC, Ng BK, Ying SY and Lam PK: A 10-year study of the changes in the pattern and treatment of 6,493 fractures. *J Pediatr Orthop* 19: 344-350, 1999.
- Jones K and Weiner DS: The management of forearm fractures in children: A plea for conservatism. *J Pediatr Orthop* 19: 811-815, 1999.
- Vopat ML, Kane PM, Christino MA, Truntzer J, McClure P, Katarincic J and Vopat BG: Treatment of diaphyseal forearm fractures in children. *Orthop Rev (Pavia)* 24: 5325, 2014.
- Alpar EK, Thompson K, Owen R and Taylor JF: Midshaft fractures of forearm bones in children. *Injury* 13: 153-158, 1981.
- Flynn JM, Jones KJ, Garner MR and Goebel J: Eleven years experience in the operative management of pediatric forearm fractures. *J Pediatr Orthop* 30: 313-319, 2010.
- Hotchkiss RN, An KN, Sowa DT, Basta S and Weiland AJ: An anatomic and mechanical study of the interosseous membrane of the forearm: Pathomechanics of proximal migration of the radius. *J Hand Surg Am* 14: 256-261, 1989.
- Shepard MF, Markolf KL and Dunbar AM: Effects of radial head excision and distal radial shortening on load-sharing in cadaver forearms. *J Bone Joint Surg Am* 83: 92-100, 2001.
- Price CT: Acceptable alignment of forearm fractures in children: Open reduction indications. *J Pediatr Orthop* 30: S82-S84, 2010.
- Tarmuzi NA, Abdullah S, Osman Z and Das S: Paediatric forearm fractures: Functional outcome of conservative treatment. *Bratisl Lek Listy* 110: 563-568, 2009.
- Shoemaker SD, Comstock CP, Mubarak SJ, Wenger DR and Chambers HG: Intramedullary kirschner wire fixation of open or unstable forearm fractures in children. *J Pediatr Orthop* 19: 329-337, 1999.
- Cullen MC, Roy DR, Giza E and Crawford AH: Complications of intramedullary fixation of pediatric forearm fractures. *J Pediatr Orthop* 18: 14-21, 1998.
- Price CT and Mencia GA: Injuries to the shafts of the radius and ulna. In: *Fractures in Children*. Beaty JH and Kasser JR (eds). 5th edition. Lippincott Williams & Wilkins, Philadelphia, PA, pp443-482, 2001.
- Price CT and Knapp DR: Osteotomy for malunited forearm shaft fractures in children. *J Pediatr Orthop* 26: 193-196, 2006.
- Creasman C, Zaleske DJ and Ehrlich MG: Analyzing forearm fractures in children. The more subtle signs of impending problems. *Clin Orthop Relat Res* 40-53, 1984.
- Daruwalla JS: A study of radioulnar movements following fractures of the forearm in children. *Clin Orthop Relat Res* 114-120, 1979.
- Shah AS, Lesniak BP, Wolter TD, Caird MS, Farley FA and Vander Have KL: Stabilization of adolescent both-bone forearm fractures: A comparison of intramedullary nailing versus open reduction and internal fixation. *J Orthop Trauma* 24: 440-447, 2010.
- Price CT: Part II: Injuries to the shaft of the radius and ulna. In: *Fractures in Children*. Rockwood CA Jr, Wilkins KE, Beaty JH and Green DP (eds). 4th edition. Lippincott-Raven, Philadelphia, PA, pp522-524, 1996.
- Patrick J: A study of supination and pronation, with especial reference to the treatment of forearm fractures. *J Bone Joint Surg Am* 28: 737-748, 1946.
- van Geen RC and Besselaar PP: Outcome after corrective osteotomy for malunited fractures of the forearm sustained in childhood. *J Bone Joint Surg Br* 89: 236-239, 2007.
- Byrne AM, Impelmans B, Bertrand V, Van Haver A and Verstreken F: Corrective osteotomy for malunited diaphyseal forearm fractures using preoperative 3-dimensional planning and patient-specific surgical guides and implants. *J Hand Surg Am* 42: 836.e1-836.e12, 2017.
- Murase T, Oka K, Moritomo H, Goto A, Yoshikawa H and Sugamoto K: Three-dimensional corrective osteotomy of malunited fractures of the upper extremity with use of a computer simulation system. *J Bone Joint Surg Am* 90: 2375-2389, 2008.
- Jeuken RM, Hendrickx RPM, Schotanus MGM and Jansen EJ: Near-anatomical correction using a CT-guided technique of a forearm malunion in a 15-year-old girl: A case report including surgical technique. *Orthop Traumatol Surg Res* 103: 783-790, 2017.
- Hensinger RN: Meeting highlights. 1986 Annual Meeting, American Academy of Orthopaedic Surgeons. *J Pediatr Orthop* 6: 500-506, 1986.
- Graham TJ, Fischer TJ, Hotchkiss RN and Kleinman WB: Disorders of the forearm axis. *Hand Clin* 14: 305-316, 1998.
- Chloros GD, Wiesler ER, Stabile KJ, Papadonikolakis A, Ruch DS and Kuzma GR: Reconstruction of Essex-Lopresti injury of forearm: Technical note. *J Hand Surg Am* 33: 124-130, 2008.



This work is licensed under a Creative Commons Attribution-NonCommercial-NoDerivatives 4.0 International (CC BY-NC-ND 4.0) License.