

Evaluation of apoptotic cells and immunohistochemical detection of FAS, FAS-L, Bcl-2, Bax, p53 and c-Myc in the skin of patients with chronic venous leg ulcers

SUSANNA HEISING¹, JÜRGEN GIEBEL², ANNA-LENA OSTROWITZKI², FRANZISKA RIEDEL¹,
HERMANN HAASE¹, KIRSTIN SIPPEL¹ and MICHAEL JÜNGER¹

¹Department of Dermatology, Ernst Moritz Arndt University, Fleischmannstr. 42-44, D-17475 Greifswald;

²Institute of Anatomy and Cell Biology, Ernst Moritz Arndt University,
Friedrich Loeffler Str. 23c, D-17487 Greifswald, Germany

Received April 30, 2008; Accepted June 2, 2008

DOI: 10.3892/ijmm_00000048

Abstract. In the present study we were interested, if apoptosis plays a role in the surrounding skin of venous ulcers, where microcirculatory disorders were already observed. For this purpose laser Doppler flow and partial oxygen pressure were measured in 17 patients at the ulcer edge, the transitional area of the lower leg and the thigh. Subsequently biopsies were taken from the respective sites and subjected to terminal deoxynucleotidyl transferase labelling (TUNEL) and immunohistochemistry using antibodies to determine the protein expression of Fas, Fas-L, Bax, Bcl-2, p53 and c-Myc. Laser Doppler flow was increased and transcutaneous oxygen partial pressure was decreased, with significant differences at the ulcer edge and the lower leg compared to the thigh. The skin biopsies did not show any differences when labelling for apoptotic cells. Keratinocytes of basal and spinous layer stained with antibodies against Fas, Fas-L and Bax in all probes of the three sites. c-Myc and p53 were negative in all keratinocytes of the skin probes. However, staining with Bcl-2 was significantly decreased at the ulcer edge in comparison to the lower leg and the thigh ($p=0.017$). Our study revealed that a disturbed microcirculation does not increase the number of apoptotic cells at the ulcer edge in patients with venous disease. The reduced staining pattern with Bcl-2 at the ulcer edge seems not to result in higher susceptibility to apoptosis, but it remains to be proven whether it is involved in epidermal acanthosis.

Introduction

In the wound healing process apoptosis plays an important role (1-3), but until now only little is known about cell death in keratinocytes at the ulcer edge (2,4) and at the transient area of the lower leg affected by chronic venous insufficiency as stasis dermatitis, dermatoliposclerosis respectively. In contrast, Andriessen *et al* (5) showed that epidermal proliferation was not impaired at the ulcer edge in chronic venous ulcers.

Thrombosis and valvular disorders in the leg veins often result in chronic venous insufficiency. The impaired venous hemodynamics, particularly hypertension and hypervolemia, in the large veins of the leg affect even the capillaries of the skin, which lead to a loss of function. As a result trophic skin damage becomes visible as hyperpigmentation, Purpura jaundice, stasis dermatitis, dermatoliposclerosis, white atrophy and venous ulcers in extreme cases. Venous ulcers of the lower extremities are chronic in nature, with frequent relapses, affecting some 0.6% (C5) and 0.1% (C6) of the adult German population (6). Cutaneous microcirculation consists of 85% of blood flow in the thermo regulative plexus and up to 15% in the nutritive plexus (7). Laser Doppler flow technique and measurement of transcutaneous oxygen pressure are well established methods for quantifying disturbed microcirculation. Laser Doppler flowmetry quantifies blood flow of the thermo regulative plexus and was found induced in patients with CVI and stasis (8). Transcutaneous oxygen pressure with reflection spectrophotometry heating 43°C of the skin quantifies mainly oxygen passing from superficial skin capillaries through the epidermis (8,9).

There is evidence that apoptosis plays a regulative role in the homeostasis of normal human epidermis (10,11). Apoptosis can be triggered by a wide variety of internal and external stimuli such as nutrient deprivation, mechanical stress (3), and their signal transduction is tightly regulated by genes and proteins such as p53, c-Myc, Bcl-2, Bax, Fas, Fas-L (12). The most thoroughly described initiation path in the epidermis involved the binding of Fas ligand (Fas-L) to its membrane receptor Fas (CD 95, Apo-1), a protein of the tumour necrosis factor receptor family (10,13). Bcl-2, a

Correspondence to: Dr Susanna Heising, Department of Dermatology, Ernst Moritz Arndt University, Fleischmannstr. 42-44, D-17475 Greifswald, Germany
E-mail: heising@uni-greifswald.de

Key words: leg ulcer, venous disease, apoptosis, immunohistochemistry, skin

proto-oncogene, protected basal keratinocytes from cell death by preventing leakage of the mitochondrial membrane and thus release of cytochrome c (10,12). Bax, a member of the bcl-2 family and a principal inducer of apoptosis (14), was found normally in the cytosol but during apoptosis Bax translocated to the mitochondrial membrane (15). It regulated the transcription of Bax but down regulated that of Bcl-2, thus favoring mitochondria-dependent apoptosis; in addition, it up-regulated the transcription of Fas to support Fas-mediated apoptosis (3).

C-Myc belongs to the basic helix-loop-helix/leucinezipper family of DNA-binding proteins and promoted *in vitro* the differentiation of human epidermal stem cells (16). In normal epidermis c-Myc expression was confined to the proliferative basal cell layer, whereas the suprabasal, terminally differentiated, layers of epidermis exhibited decreased c-myc expression levels (17).

There is evidence that apoptosis plays a role in the pathogenesis of ulcer formation and delayed wound healing (3), but only little is known about venous ulcers. As epidermal wound healing was found to be promoted from ulcer edge (18), we assessed blood flow and oxygen pressure at the ulcer edge, the transitional area of the lower leg and the thigh in patients with chronic venous insufficiency. Subsequently, we took biopsies from respective sites and investigated the number of apoptotic cells by terminal deoxynucleotidyl transferase labelling (TUNEL) and immunohistochemical expression of Fas-L, Fas, Bcl-2, Bax, c-Myc and p53. For the first time we included the thigh in the investigation procedure to evaluate whether microcirculatory changes or differences in the staining of apoptosis associated antibodies are already visible.

Patients and methods

Patients. Tissue samples and patient data for this study were obtained and used after advice from the ethics committee of the University of Greifswald and in accordance with the declaration of Helsinki. The study included 17 patients being treated at the University Dermatology Hospital of Greifswald at the Wound Center, who presented with chronic venous ulceration according to CEAP-classification C6 (19). Patients were investigated by standardized quantification of arterial and venous circulation of the lower extremities, including color duplex sonography and photoplethysmographic measurement of venous function. A total of 17 patients, 11 females and 6 males, took part in this study. The mean age was 69 years (SD \pm 11.4; range 44-81 years) with chronic venous ulcers, which existed in 58.5% for 1-5 years and in 41.2% for >5 years. The mean peripheral arterial Doppler (ankle/brachial) pressure index was 1.04 with triphasic flow. Nine patients had insufficiency of the great saphenous vein and 6 of the small saphenous vein. Deep venous insufficiency was seen in 5 out of 17 patients.

Microcirculation. Transcutaneous oxygen tension and laser Doppler flowmetry were performed for quantification of the skin perfusion in three areas - unaffected skin at the thigh, transitional area (hyperpigmentation, stasis dermatosis, dermatoliposclerosis, white atrophy of chronic venous

disease) at the lower leg and the ulcer edge, which was often localized at the inner or outer ankle (Fig. 1). Skin hypoxia was measured with an electrode heated to 43°C with transcutaneous oxygen monitor as described earlier by Jünger (9). Laser Doppler flow was measured at the same skin areas with the PeriFlux System 5000 (Perimed, Stockholm) according to Jünger *et al* (20,21) (Fig. 1). Thereafter skin punch biopsies were taken under local anesthesia from exactly the same areas. The probes were fixed in formalin (4%) and embedded in paraffin for hemalaun/eosin (H&E) and specific antibody staining.

Histopathological evaluation. Histopathological evaluation was on H&E stained paraffin sections of each region (ulcer edge, transitional area of the lower leg, thigh).

Immunohistochemistry. Paraffin sections were cut at 4 μ m, mounted on coated glass-slides (Superfrost, Menzel, Braunschweig, Germany), deparaffized according to standard protocols and subjected to immunohistochemistry using the 4plus™ Universal Immunoperoxidase Detection System (Biocarta, Hamburg, Germany). After blocking of endogenous peroxidase activity with Peroxidazed® (5 min, Biocarta), samples were microwaved for antigen retrieval (10 mM citrate buffer, pH 6.0, 20 min). Slides were allowed to cool down, washed [tap water, distilled water and PBS-buffer (pH 7.3), 5 min each] and incubated with blocking solution (Biocarta, 10 min). Slides were washed (PBS, 2x5 min) and incubated overnight (4°C) with primary antibodies against Bcl-2 (monoclonal, 1:200, Biosource, Camarillo, USA), p53 (monoclonal, 1:100, DPC Biemann, Bad Nauheim, Germany), c-myc and bax (monoclonal, 1:50, Acris Antibodies, Hiddenhausen, Germany), FAS (polyclonal, CD 95, 1:100, Acris Antibodies), FAS-L (rat polyclonal, 1:200, Kamiya Biomedical Co., Seattle, USA). Slides were covered with coverslips to ensure that the whole section was coated with antibody solution. After washing (PBS, 2x5 min), slides were incubated with secondary antibody (10 min, Biocarta) and subsequently washed in PBS (2x5 min). Slides were applied to Steptavidin-HRP solution (10 min, Biocarta) and washed in PBS (2x5 min). Antibody binding was visualized with 0.1% diaminobenzidine (Sigma, Munich, Germany) in PBS/0.01% H₂O₂ (5 min). Slides were counterstained with hemalaun and mounted in Neo-mount (Merck, Darmstadt, Germany).

Control reactions were done by: i) incubation with PBS alone omitting all antibodies and detection steps except DAB-chromogen reaction; ii) omitting the primary antibody; and iii) by replacing the primary antibodies by an antibody not reactive in paraffin sections (β 1; Biomol, Hamburg, Germany) or by normal rabbit serum.

The evaluation of the staining intensity and digital documentation were performed on an Olympus Bx50 microscope equipped with an Olympus DP 10 digital camera. Histological staining was judged by two independent observers. Staining in the epidermis was scored '1' when basal cells were positive only, '2' when basal cells and the adjacent spinal layer were positive and '3' when basal cells and >3 spinal layers were positive. Membrane (Fas, Fas-L), cytoplasmic (Bax, Bcl-2) or nuclear (p53, c-Myc) staining patterns were considered positive.

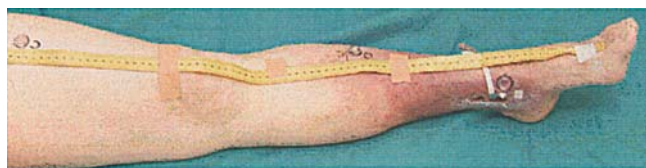

Figure 1. Measurement of laser Doppler flow and transcutaneous oxygen partial pressure investigated in a patient with CVI in supine position at the thigh, transitional area of the lower leg, and the ulcer edge. After this procedure the same sites were biopsied.

TUNEL (terminal deoxynucleotidyl transferase (TdT)-mediated deoxyuridine triphosphate (dUTP) nick end labelling) - apoptotic index. Dewaxed paraffin sections were equilibrated in proteinase K buffer (0.05 M KCl; 0.01 M Tris; 0.002 MgCl₂; 5 min, 22°C) and incubated in proteinase K (3 mg proteinase in 50 ml proteinase K buffer, 30 min, 37°C). Sections were washed in PBS (3x5 min), incubated in lysis buffer (0.1% Triton-X-100, 0.1% Na-azide; 2 min, 22°C) and washed (PBS, 3x5 min). Samples were then incubated with TdT-mixture [20 µl TdT-buffer (Promega, Madison, WI, USA), 1 µl 100x Biotin d16 UTP (Boehringer-Mannheim, Germany), 10 µl CoCl₂, 69 µl Aqua dest., 1.6 µl TdT enzyme (Promega, 20 U/µl)] in a humid chamber (60 min, 37°C). After 3 washes (PBS, 3x5 min) samples were incubated with streptavidin-AP (1:100, 30 min, 22°C), washed again (PBS, 3x5 min) and subjected to BCIP-substrate buffer (10 min, 22°C). Samples were mounted in glycerol gelatine (Merck). For negative controls TdT-mixture was used without biotin d16UTP and for positive controls sections were incubated with Dnase I (1 µg/ml in TdT buffer, 20 min, 22°C, Promega).

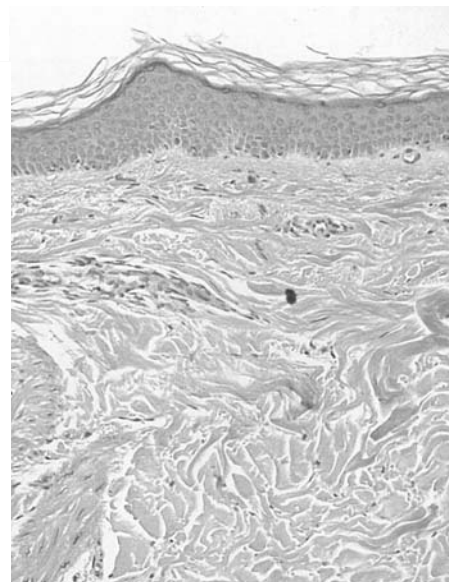
Statistical analysis. SPSS for Windows, release 11, was used for statistical analysis. The data were presented either in absolute numbers or as mean and standard deviation. Normal distribution was evaluated with Kolmogoroff-Smirnoff-test. When data were in normal distribution paired t-test was used. When data were not definite in normal distribution the non-parametric Mann-Whitney U test, the χ^2 and the Fisher's test exact were used for comparison between the groups. A $p < 0.05$ was considered as statistically significant.

Results

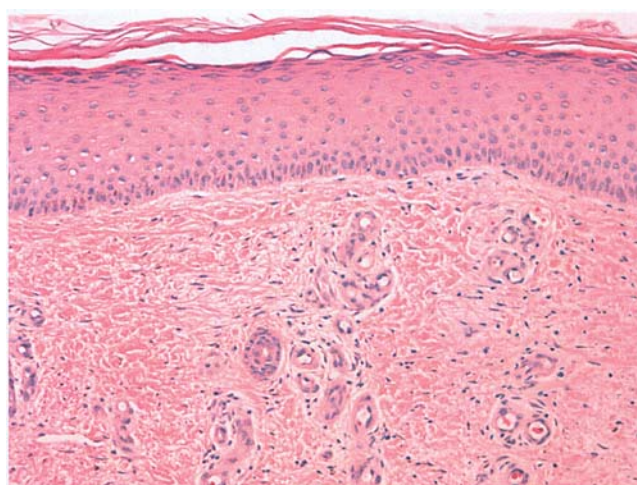
Skin microcirculation. Patients with chronic venous ulcer had a decreased transcutaneous oxygen pressure at the ulcer edge (Table I). Values increased to the transitional region at the lower leg and were highest at the thigh. As data were in normal distribution, we performed t-test for paired sample surveys. The differences between ulcer edge ($p=0.011$), transitional area of the lower leg ($p=0.000$) and thigh ($p=0.000$) were all significant. Laser Doppler flow was increased at the ulcer edge (Table I) and still elevated at the transitional region. Normal laser Doppler flow values were obtained at the thigh. As data were in normal distribution, we performed t-test for paired sample surveys. The differences between ulcer edge ($p=0.019$), transitional area of the lower leg ($p=0.000$) and thigh ($p=0.004$) were all significant.

H&E staining. In the thigh a normal histological pattern in the epidermis and dermis was observed in 16/17 probes (Fig. 2A).

A



B



C

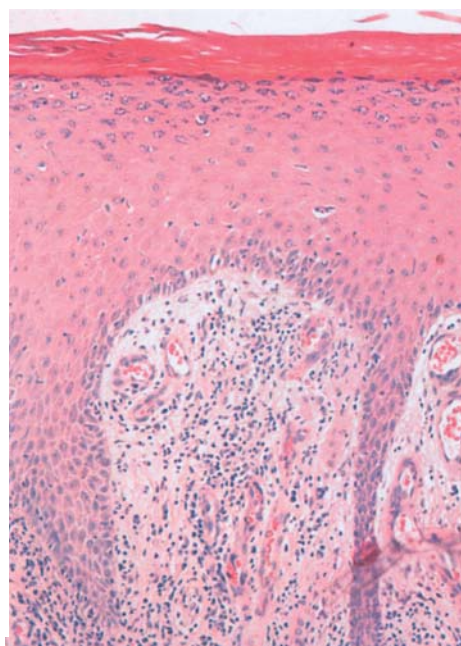


Figure 2. Haemalaun/eosin staining of skin probes from the thigh (A) with normal epidermis and dermis; transitional area of the lower leg (B) and the ulcer edge (C) in a patient with chronic venous insufficiency. (A) Normal corneal layer and epidermis, but increased number of sliced vessels in the upper dermis. (B) Hyper- and parakeratosis in corneal layer, acanthosis of the epidermis, increased number of sliced vessels in the upper dermis with cellular infiltrate of lympho- and histiocytic cells. Magnification x20.

Table I. Trophic skin changes at the leg in patients with chronic venous insufficiency and their corresponding histological findings, values of transcutaneous oxygen tension and laser Doppler flow as mean \pm standard deviation (AU, arbitrary units).

Investigated site	Clinical findings	Histological findings	Transcutaneous oxygen tension	Laser Doppler flow
Thigh	No trophic skin changes	Normal histology (16x) hyperkeratosis (1x)	51.6 \pm 11.5 mmHg	8.8 \pm 5.5 AU
Transitional area of the lower leg	Hyperpigmentation (16x), lipodermatosclerosis (16x)	Epidermal: hyperkeratosis (6x), acanthosis (10x) Dermal: edema (11x), fibrosis (8x) dilated, elongated, increased number of sliced vessels (13x), lymphohistiocytic infiltrate (13x)	27.1 \pm 18.5 mmHg	37.7 \pm 37.7 AU
Ulcer edge	Hyperpigmentation (16x), lipodermatosclerosis (16x), edema (12x), erythema (7x), white atrophy (2x), eczema (1x)	Epidermal: hyperkeratosis (17x), acanthosis (17x) Dermal: edema (17x), fibrosis (17x) Vessels: dilated, elongated, increased in number (17x), lymphohistiocytic infiltrate (17x)	10.6 \pm 10.3 mmHg	62.6 \pm 47.4 AU

In one case we saw hyperkeratosis. In the transitional area of the lower leg a small epidermal acanthosis was still visible in 10/17 probes (Fig. 2B). Hyperkeratosis was seen in 7/17 cases. Dermal vessels were increased in number in 13/17 and edema in 11/17 probes. A lymphohistiocytic infiltrate was confirmed in 13/17 probes. Changes in the connective tissue (increasing presence of fibroblasts, homogenized collagen fibres, fibrosis) were seen in 8/17 probes.

A small or thick epidermal acanthosis and hyperkeratosis was seen in all probes from the ulcer edge (Fig. 2C). Edema and infiltrate of lymphohistiocytic cells perivascular or in the upper dermis were seen. The probes from ulcer edge showed capillaries and small vessels increased in number, partly the wall was thicker or the vessels were dilated. Homogenized collagen fibres, increasing number of fibroblasts or fibrosis of the connective tissue were seen in 17/17 probes.

Immunohistochemistry

Fas and Fas-L. Immunostaining with the Fas antibody gave the same result in the basal and spinous cell layer of the epidermis in the ulcer edge, transitional area of the lower leg and thigh (Table II and Figs. 3 and 4). Fas-L was stained in all cells of the basal and spinous cell layer in all of the samples taken from ulcer edge, transitional area of the lower leg and thigh (Table II).

Bax and Bcl-2. Bcl-2 was demonstrated in basal keratinocytes of the epidermis in most of the biopsies taken from the thigh and the transitional zone at the lower leg (Table II and Fig. 5), but only about half of the probes stained positive with bcl-2 at the ulcer edge (Table II). The statistical relation was significant different for the ulcer edge and the transitional

Table II. Results of immunohistochemistry in the skin probes from ulcer edge, transitional area of the lower leg, thigh of the ipsilateral leg with chronic venous insufficiency.

Antibody	Basal cell layer			Spinous cell layer		
	Ulcer edge	Lower leg	Thigh	Ulcer edge	Lower leg	Thigh
Fas	14/17	13/16	12/17	12/17	11/16	13/17
Fas-L	10/10	9/9	10/10	8/10	9/9	7/10
Bcl-2	<u>9/17</u>	16/17	12/16	4/17	5/17	7/16
bax	14/16	14/14	15/16	13/16	10/14	14/16
p53	0/17	0/15	0/17	0/17	0/15	0/17
c-Myc	0/17	0/16	0/17	0/17	0/16	0/17

Number of positive stained probes in relation to all investigated probes is given of the three different sites at the patient's leg. Significant difference of Bcl-2 is underlined.

area at the lower leg by non-parametric Mann-Whitney U test $p=0.017$ (2-sided). In the dermis, endothelial and lymphocytic cells stained positive in all investigated areas. Immunostaining for Bax was seen in basal, spinous and granular keratinocytes in most of the probes taken from the ulcer edge, transitional area of the lower leg and thigh (Table II and Fig. 6).

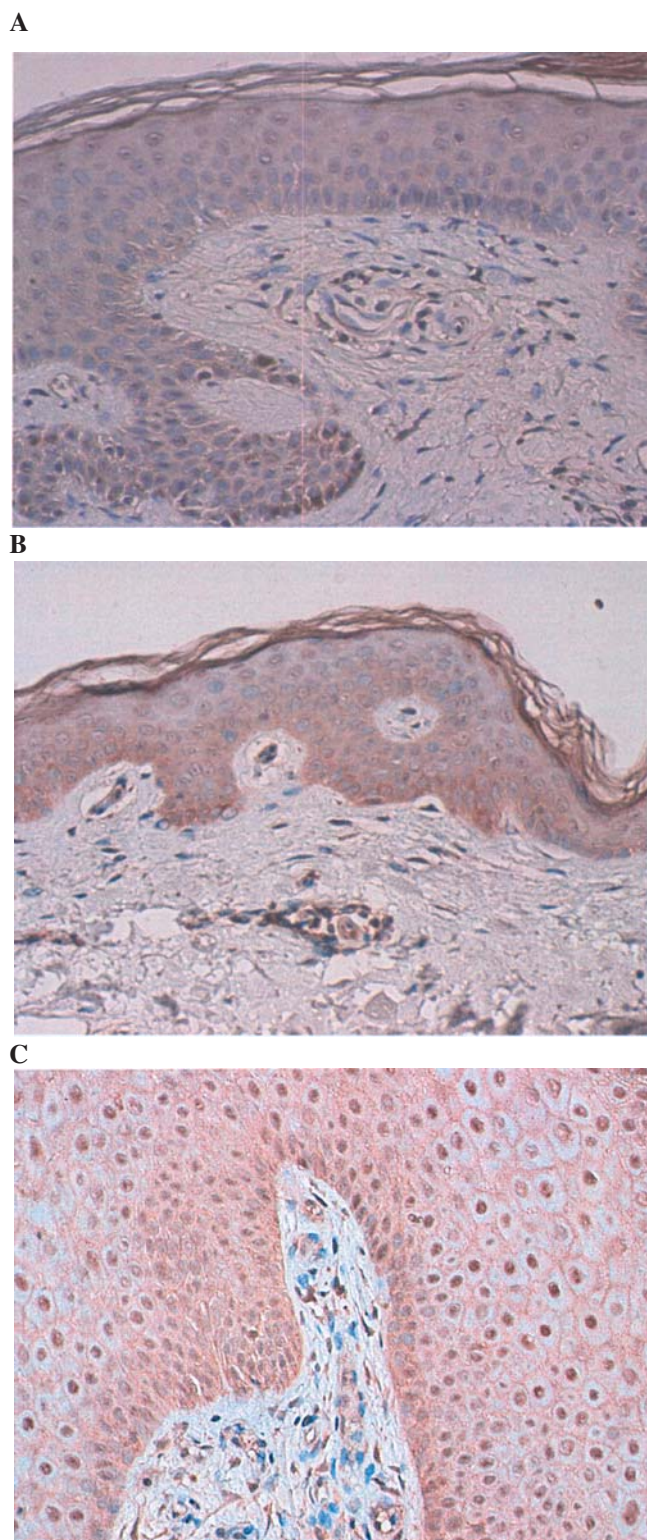


Figure 3. Immunohistochemical staining of Fas antibody. The keratinocytes and endothelial cells were positive in the probes from the thigh (A), transitional area of the lower leg (B) and the ulcer edge (C) in a representative patient with chronic venous insufficiency and ulceration. Magnification x20.

c-Myc and p53. The antibody c-Myc did not show any nuclear staining in the epidermis in any of the investigated areas, thigh, transitional area of the lower leg, or ulcer edge (Table II and Fig. 7). Also p53 was negative in keratinocytes of the

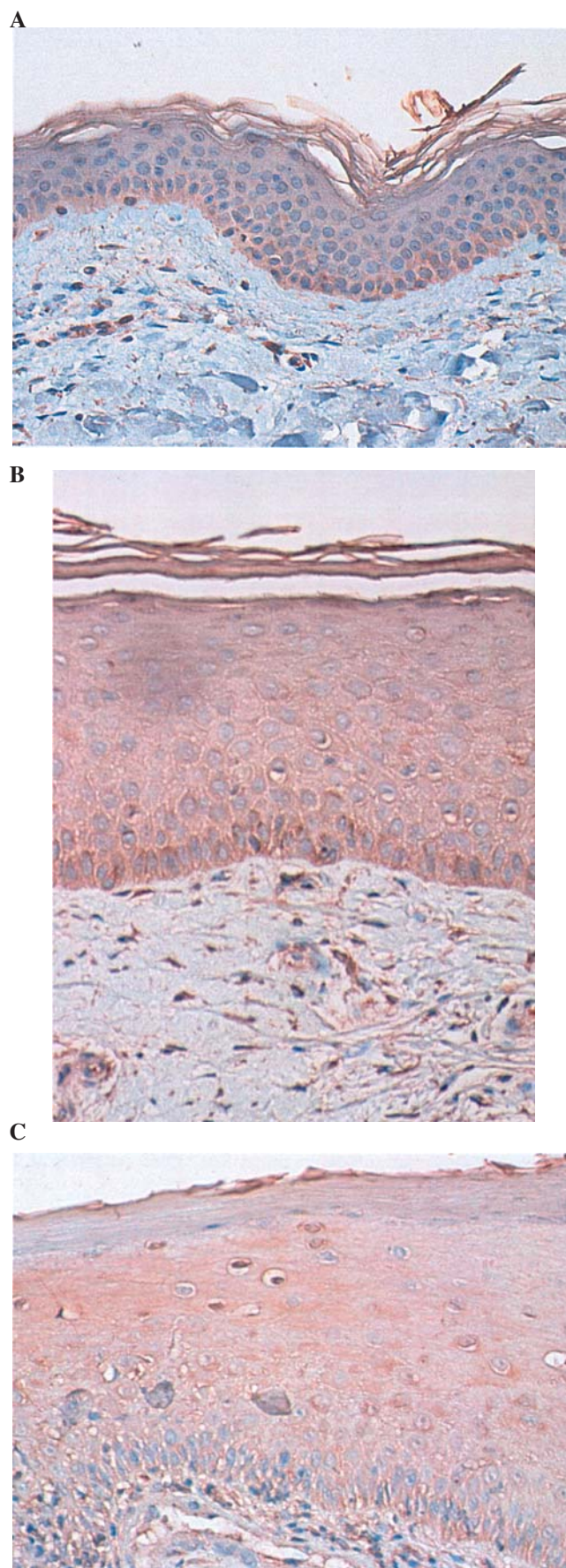


Figure 4. Immunohistochemical staining of Fas-L in the epidermis of probes from the thigh (A), transitional area of the lower leg (B) and at the ulcer edge (C) in a representative patient with chronic venous insufficiency and ulceration. Magnification x20.

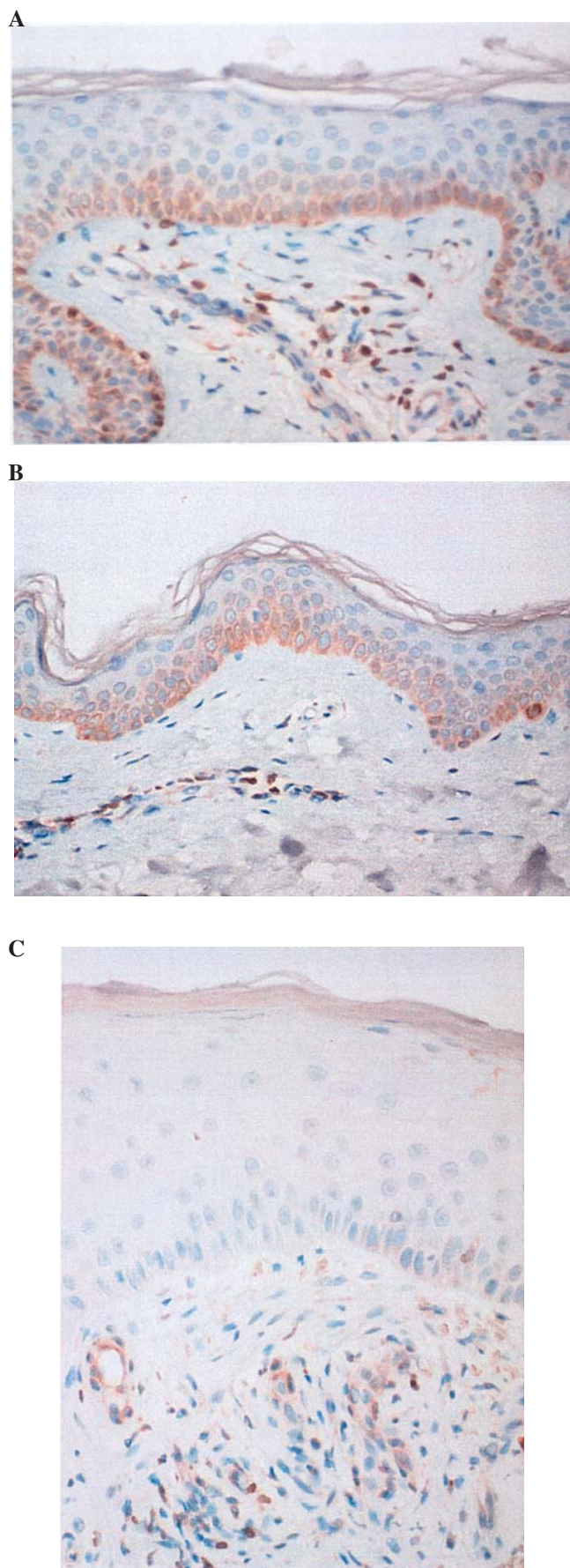


Figure 5. Immunohistochemical localization of bcl-2 in the thigh (A), transitional area of the lower leg (B) mainly in basal keratinocytes. No staining in the epidermis at the ulcer edge (C) in a representative patient with chronic venous insufficiency and ulceration. Magnification x20.

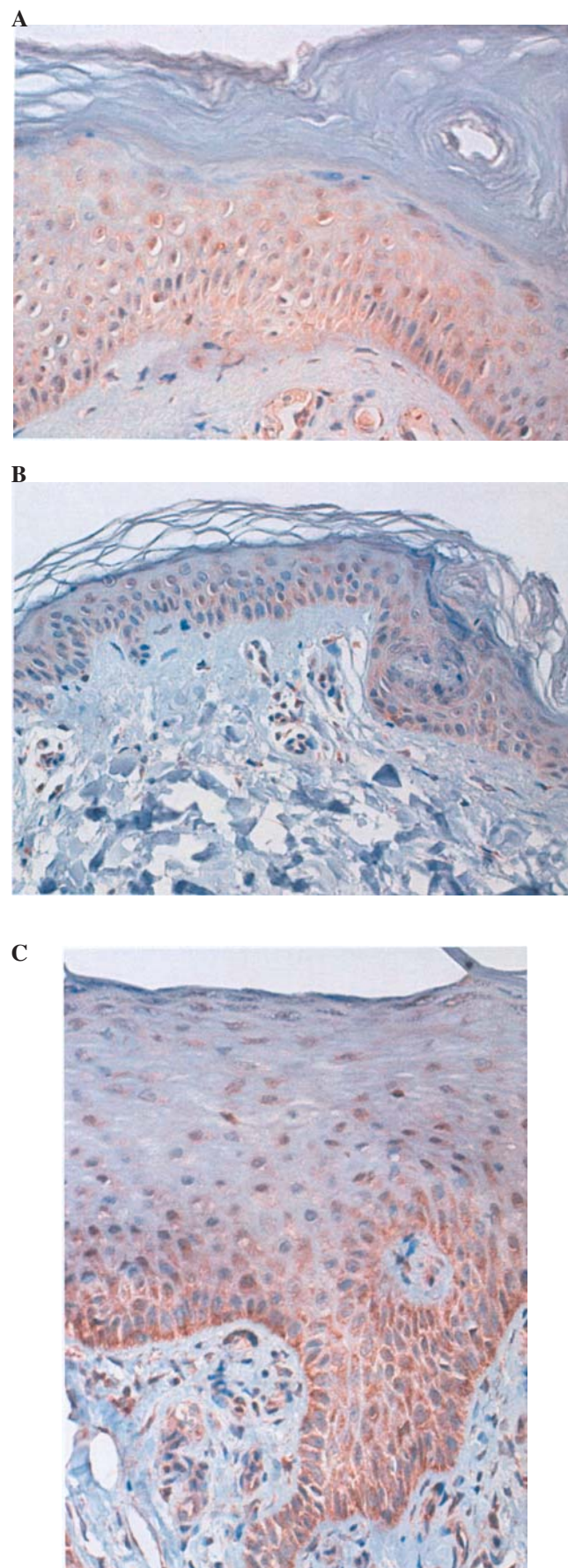


Figure 6. Immunohistochemical localization of Bax protein in basal and spinous cell layer at the thigh (A), transitional area of the lower leg (B) and at the ulcer edge (C) in a representative patient with chronic venous insufficiency and ulceration. Magnification x20.

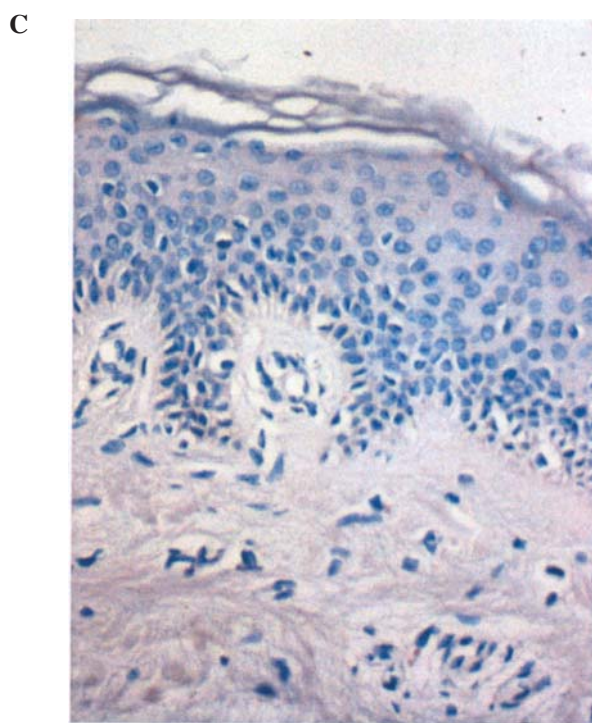
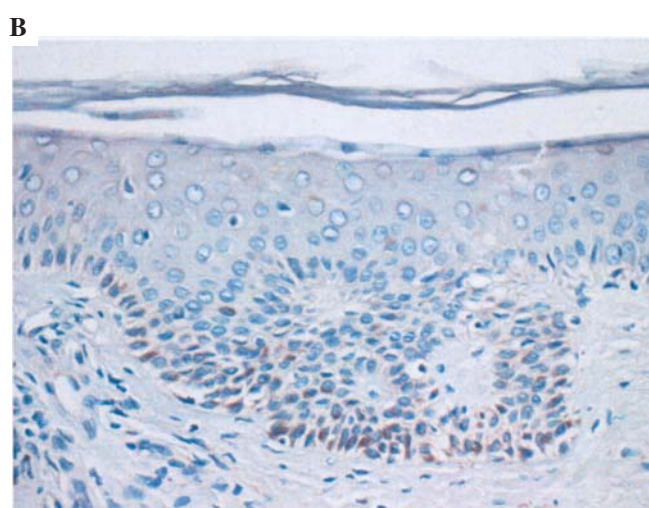
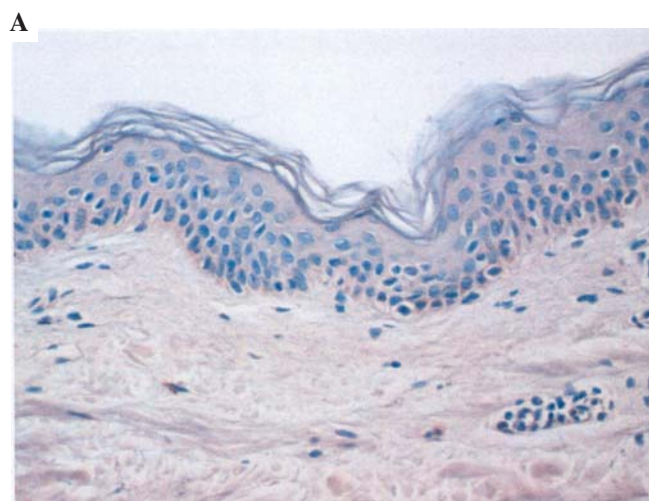


Figure 7. c-Myc antibody did not stain the nucleus of epidermal keratinocytes in the immunohistochemical probes from the thigh (A), transitional area of the lower leg (B) and at the ulcer edge (C) in a representative patient with chronic venous insufficiency and ulceration. Magnification x20.

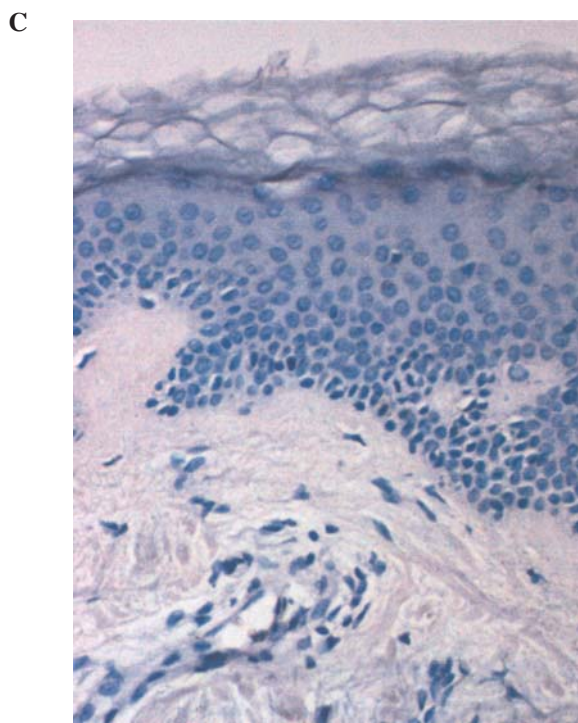
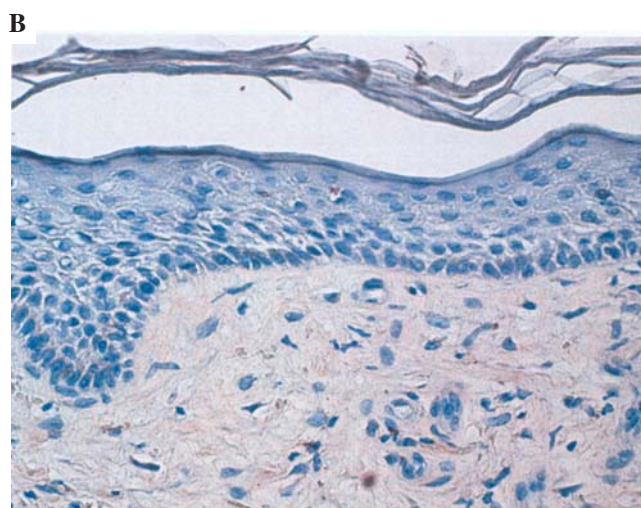
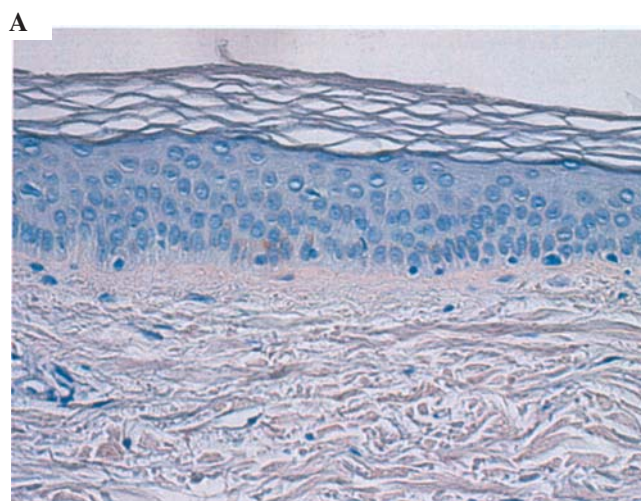


Figure 8. P53 antibody did not stain the nucleus of epidermal keratinocytes in immunohistochemistry of the probes from the thigh (A), transitional area of the lower leg (B) and the ulcer edge (C) in a representative patient with chronic venous insufficiency and ulceration. Magnification x20.

epidermis in the thigh, the lower leg and ulcer edge (Table II and Fig. 8). Cells of the dermis did not show any staining of c-Myc or p53.

TUNEL assay. Very few TUNEL-positive cells were detected at the transition zone of the granular-corneal layer in the biopsy investigated. There was no difference in apoptotic index when comparing the three sites investigated.

Discussion

In the present study we were interested, if changes of apoptotic proteins (Fas, Fas-L, Bcl-2, Bax, c-Myc, p53) could be found in microcirculatory disturbed skin at the ulcer edge, the lower leg and the thigh in patients with CVI. We have shown that hypoxia measured by TcPo₂ was most evident at the ulcer edge and at transitional area of the lower leg. This finding was explained with hypoperfusion in the superficial nutritive vessels (22). There was a close temporal and topographic correlation between the intensity of the microangiopathy and the severity of the dermatoses (23). The result was an inadequate transport of wastes out of the skin and an insufficient supply of nutrients and oxygen. Furthermore we found, that laser Doppler flow was significantly increased at the ulcer edge and also at transitional area of the lower leg. This could be a sign of a raised blood perfusion due to chronic inflammation in the thermoregulative plexus of the dermis as described recently (24). Another reason was maintained by Bollinger *et al* (22) in the opening of shunt vessels. Stücker *et al* (8) reported a stasis induced increase in erythrocyte concentration in patients with CVI. Our histological findings suggested a higher number of sliced vessels in the dermis at ulcer edge, but also already at the transitional area. Also Vanscheidt *et al* (25) reported this and their interpretation was no capillary proliferation, but an elongation and distension of the capillaries.

In the present study we found normal oxygen und laser Doppler flow values at the thigh. The alteration of the cutaneous microcirculation started already at the transitional area at the lower leg, where distended and elongated vessels were already visible, the oxygen levels were still at the lower limit and laser Doppler flow values were increased. First it seemed paradoxical, but as Takiwaki (26) described TcPo₂ is easily influenced and reduced by various skin changes, such as hyperkeratosis, acanthosis, cellular infiltrate and fibrosis. Stacey *et al* (27) showed a negative correlation of the transcutaneous oxygen ratio with the fibrin score determined in the gaiter area and the thigh from patients with a healed venous ulcer in one leg. It was discussed that an inflammatory reaction is the underlying mechanism of development of skin changes like venous ulceration (23,28). We think that the skin changes (stasis dermatitis and fibrosis) in case of venous disease are provoked by venous hypertension and hypervolemia in capillaries and venules in the dermis.

Interestingly in our study, as revealed by the TUNEL method, we found no alteration in apoptotic labelling index in probes from the ulcer edge, lower leg and thigh in patients with chronic venous ulceration. In agreement were the results of Heroy *et al* (4), who found apoptotic cell death elevated within venous leg ulcers, but 1.5 cm distance from the edge

no significant differences were seen in the TUNEL assay compared to healthy skin.

Fas and Fas-L were expressed in basal and spinous cell layer of the epidermis in all investigated probes from the ulcer edge, transitional area of the lower leg and the thigh. In human keratinocytes Weisfelner and Gottlieb (10) confirmed the Fas detection, but Gilhar *et al* (29) postulated that this way of apoptosis seemed to be inactive. Our result of a normal number of TUNEL positive cells not only at the ulcer edge supports this theory. Probably Fas is only implicated in protection of skin against inflammation (10).

Bcl-2 expression is localized in adult skin in the proliferating basal keratinocytes, suggesting suppression of apoptotic program in these cells (10-12). Cells lost bcl-2 expression with epidermal upward migration, Weisfelner and Gottlieb (10) postulated that suprabasal cells were more susceptible to apoptosis. We observed bcl-2 in basal keratinocytes in skin probes of the thigh and lower leg, instead basal keratinocytes of the ulcer edge were characterized by a reduced bcl-2 staining with a lost expression in a significant number of probes. Heroy *et al* (4) also reported a reduced staining of bcl-2 at the ulcer edge. On the other hand, Galkowska *et al* (2) found increased bcl-2 staining at ulcer edge of venous and diabetic origin. Although bcl-2 expression was reduced at the ulcer edge apoptotic index did not change in our study. Therefore, it seems likely that susceptibility to apoptosis is not increased. This could indicate either that apoptosis is prevented by other molecules of the bcl-2 family members or it might prevent the keratinocytes from uncontrolled cell proliferation in this region. Whether the reduced expression of bcl-2 is indicative for chronic venous ulcers has to be proven.

We found Bax stained in the epidermis of almost all biopsies taken from the thigh, the transitional area of the lower leg and the ulcer edge. In previous studies Bax was localized in keratinocytes of normal human epidermis, but down-regulated in squamous carcinomas and absence in basal cell carcinoma (14). Bax staining was found in venous and diabetic ulcers and control epidermis from foot and calf in the same intensity (2). It seems likely that Bax is involved in protection against malignant transformation.

We did not find any staining for p53 at the ulcer edge, the transitional area of the lower leg and the thigh. Also Galkowska *et al* (2) found no p53 staining at the ulcer edge of venous and diabetic origin, but they found p53 staining in the distal and proximal area of an ulcer. Normal human basal keratinocytes expressed p53 slightly (30), whereas keratinocytes in patients with psoriasis strongly expressed p53 even in spinous and granular layer (31). P53 expression was found down regulated directly after wounding and increased at time of epithelization and healing in non-diabetic mice (1). Thus, it may contribute to the apoptotic changes in proliferated epidermis (32).

In our study c-Myc was not stained at the ulcer edge, transitional area of the lower leg and the thigh. Overexpression of c-myc in the epidermis of transgenic mice resulted in epidermal hyperproliferation, delayed terminal differentiation and altered programmed cell death. In normal epidermis c-Myc expression was confined to the proliferative basal cell layer, whereas the suprabasal, terminally differentiated, layers of

epidermis exhibited decreased c-myc expression levels (17). Gandarillas and Watt (16) reported that the level of c-myc mRNA decreases when keratinocytes undergo terminal differentiation, *in vitro*. They described, that c-Myc down regulation was a prerequisite for the initiation of terminal differentiation.

There is evidence that the reduced epidermal staining of bcl-2 in basal keratinocytes at the ulcer edge in comparison to the thigh and the transitional area of the lower leg may be a result of the disturbed macro- and microcirculation in venous disease and may cause epidermal acanthosis. It has been shown by Boehm (33) that diminished epidermal apoptosis was associated with epidermal acanthosis. Further, in lesional skin of psoriasis bcl-2 was found significantly reduced in keratinocytes (34). Whether decreased bcl-2 at the ulcer edge results in acanthosis and is caused by high capillary pressure, interstitial edema and inflammation has to be further elucidated.

Acknowledgments

This research was funded by the Federal Ministry of Education and Research of Germany, as well as the Bauerfeind Company of Zeulenroda in Germany. The authors thank Millie Heitmann, Rotraud Lüdke, and Marlies Bansemir for excellent technical assistance.

References

- Kane CD and Greenhalgh DG: Expression and localization of p53 and bcl-2 in healing wounds in diabetic and non-diabetic mice. *Wound Repair Regen* 8: 45-58, 2000.
- Galkowska H, Olszewsk WL, Wojewodzka U, *et al*: Expression of apoptosis- and cell cycle-related proteins in epidermis of venous leg and diabetic foot ulcers. *Surgery* 134: 213-220, 2003.
- Rai NK, Tripathi K, Sharma D, *et al*: Apoptosis: a basic physiologic process in wound healing. *Int J Low Extrem Wounds* 4: 138-144, 2005.
- Heroy Y, Kahle B, Idzko M, *et al*: Venous leg ulcers and apoptosis: a TIMP-3 mediated pathway? *J Invest Dermatol* 123: 1210-1212, 2004.
- Andriessen MP, van Bergen BH, Spruijt KI, *et al*: Epidermal proliferation is not impaired in chronic venous ulcers. *Acta Derm Venereol* 75: 459-462, 1995.
- Rabe E, Pannier-Fischer F, Broman K, *et al*: Bonner Venenstudie der Deutschen Gesellschaft für Phlebologie. Epidemiologische Untersuchung zur Frage der Häufigkeit und Ausprägung von chronischen Venenkrankheiten in der städtischen und ländlichen Wohnbevölkerung. *Phlebologie* 32: 1-14, 2003.
- Wollina U, Abdel-Naser MB and Mani R: A review of the microcirculation in skin in patients with chronic venous insufficiency: the problem and the evidence available for therapeutic options. *Int J Lower Extremity Wounds* 5: 169-180, 2006.
- Stücker M, Steinbrügge J, Memmel U, *et al*: Disturbed vasomotion in chronic venous insufficiency. *J Vasc Surg* 38: 522-527, 2003.
- Jünger M, Steins A, Hahn M, *et al*: Microcirculatory dysfunction in chronic venous insufficiency. *Microcirculation* 7: S3-S12, 2000.
- Weisfelner ME and Gottlieb AB: The role of apoptosis in human epidermal keratinocytes. *J Drugs Dermatol* 4: 385-391, 2003.
- Haake AR and Polakowska RR: Cell death by apoptosis in epidermal biology. *J Invest Dermatol* 101: 107-112, 1993.
- Teraki Y and Shiohara T: Apoptosis and the skin. *Eur J Dermatol* 9: 413-426, 1999.
- Wehrli P, Viard I, Bullani R, Tschopp J and French LE: Death receptors in cutaneous biology and disease. *J Invest Dermatol* 115: 141-148, 2000.
- Tomkova H, Fujimoto W and Arata J: Expression of the bcl-2 homologue bax in normal human skin, psoriasis vulgaris and non-melanoma skin cancers. *Eur J Dermatol* 8: 256-260, 1998.
- Baliga BC and Kumar S: Role of Bcl-2 family of proteins in malignancy. *Hematol Oncol* 20: 63-74, 2002.
- Gandarillas A and Watt FM: c-Myc promotes differentiation of human epidermal stem cells. *Genes Dev* 11: 2869-2882, 1997.
- Waikel RL, Wang XJ and Roop DR: Targeted expression of c-Myc in the epidermis alters normal proliferation, differentiation and UV-B induced apoptosis. *Oncogene* 18: 4870-4878, 1999.
- Lotti T and Benci M: Plasminogen activators, venous leg ulcers and reepithelialization. *Int J Dermatol* 34: 696-699, 1995.
- Kistner RL, Eklof B and Masuda EM: Diagnosis of venous disease of the lower leg extremities: the CEAP classification. *Mayo Clin Proc* 71: 338-345, 1996.
- Jünger M, Hahn M, Klyszcz T, *et al*: Influence of healing on the disturbed blood flow regulation in venous ulcers. *VASA* 25: 341-348, 1996.
- Jünger M, Klyszcz T, Hahn M, *et al*: Disturbed blood flow regulation in venous leg ulcers. *Int J Microcirc* 16: 259-265, 1996.
- Bollinger A, Leu AJ, Hoffmann U, *et al*: Microvascular changes in venous disease: an update. *Angiology* 48: 27-32, 1997.
- Hahn J, Jünger M, Friedrich B, *et al*: Cutaneous inflammation limited to the region of the ulcer in chronic venous insufficiency. *VASA* 26: 277-281, 1997.
- Schmeller W, Roszinski S and Huesmann M: Tissue oxygenation and microcirculation in dermatoliposclerosis with different degrees of erythema at the margins of venous ulcers. A contribution to hypodermatitis symptoms. *VASA* 26: 18-24, 1997.
- Vanscheidt W, Laaff H, Weiss JM, *et al*: Immunohistochemical investigation of dermal capillaries in chronic venous insufficiency. *Acta Derm Venereol* 71: 17-19, 1991.
- Takiwaki H: Transcutaneous Po₂ and Pco₂ measurement in dermatology. *Acta Derm Venereol Suppl* 185: 21-25, 1994.
- Stacey MC, Burnand KG, Bhogal BS, *et al*: Pericapillary fibrin deposits and skin hypoxia precede the changes of lipodermatosclerosis in limbs at increased risk of developing a venous ulcer. *Cardiovasc Surg* 8: 372-380, 2000.
- Pascarella L, Schmid Schönbein GW and Bergan JJ: Microcirculation and venous ulcers: a review. *Ann Vasc Surg* 19: 921-927, 2005.
- Gilhar A, Ullmann Y, Karry R, *et al*: Ageing of human epidermis: the role of apoptosis, Fas and telomerase. *Br J Dermatol* 150: 56-63, 2004.
- Hussein MR, Al-Badaiwy ZH and Guirguis MN: Analysis of p53 and bcl-2 protein expression in the non-tumorigenic, pre-tumorigenic, and tumorigenic keratinocytic hyperproliferative lesions. *J Cutan Pathol* 31: 643-651, 2004.
- Baran W, Szepletowski JC and Szybejko-Machaj G: Expression of p53 protein in psoriasis. *Acta Dermatovenereol Alp Panonica Adriat* 14: 79-83, 2005.
- Guan DW, Ohshima T and Kondo T: Immunohistochemical study on fas and fas-ligand in skin wound healing. *Histochem J* 32: 85-91, 2000.
- Boehm I: Apoptosis in physiological and pathological skin: implications for therapy. *Curr Mol Med* 6: 375-341, 2006.
- Batinac T, Zamolo G, Hadzisejdic I, *et al*: Expression of Bcl-2 family proteins in psoriasis. *Croat Med J* 48: 319-326, 2007.