

Optimizing perampanel monotherapy for surgically resected brain tumors

UTARO HINO¹, RYOTA TAMURA¹, KENZO KOSUGI¹, TAKETO EZAKI², KOSUKE KARATSU¹, KOSEI YAMAMOTO¹, AZUNA TOMIOKA¹ and MASAHIRO TODA¹

¹Department of Neurosurgery, Keio University School of Medicine, Shinjuku-ku, Tokyo 160-8582, Japan;

²Department of Pharmacy, Keio University School of Medicine, Shinjuku-ku, Tokyo 160-8582, Japan

Received January 16, 2024; Accepted April 10, 2024

DOI: 10.3892/mco.2024.2740

Abstract. Perampanel (PER) is an antiseizure medication (ASM) with a unique mechanism of action, which was approved in Japan for use in combination therapy in 2016 and as a monotherapy in 2020. It has exerted antitumor effects against several types of tumors *in vitro*. However, the efficacy of PER monotherapy for seizure control is not well-established in patients with brain tumor. In the present study, 25 patients with brain tumor treated using PER monotherapy at our institution were analyzed and compared with 45 patients treated using the most commonly prescribed ASM, levetiracetam (LEV). The PER group was younger and had a higher frequency of glioma cases. During drug administration, seizures were observed in two patients from the PER group (8.0%) and five patients from the LEV group (11.1%); however, the difference was not significant. The incidence of adverse effects did not significantly differ between the groups (12.0 and 2.2%, respectively). In the PER group, mild liver dysfunction was observed in two patients and drug rash in one. In the LEV group, a drug-induced rash was observed in one patient. PER monotherapy may be safe and effective for seizure treatment or prophylaxis in patients with brain tumor. Further large-scale clinical studies are warranted.

Introduction

The incidence of convulsive seizures following surgery for non-traumatic supratentorial brain lesions is estimated to range between 15 and 20% (1). However, depending on the

underlying pathology, seizure risk shows marked variations, ranging from 3 to 92% (2). Postoperative seizures generally manifest in the first month after surgery and may herald the onset of refractory epilepsy (3,4).

The prophylactic use of antiseizure medication (ASM) in patients undergoing neurosurgical procedures is still being debated (4). Randomized controlled trials have yielded conflicting results; certain trials have indicated a significant reduction in the incidence of early postoperative seizures due to ASM prophylaxis (3,5), while others do not agree (6). Around 35-70% of patients with brain tumor suffer from seizures (7,8). Perioperative levetiracetam (LEV) appears to be effective in treating these patients; however, the evidence regarding perioperative prophylaxis remains conflicting (9-11). LEV binds to synaptic vesicle glycoprotein 2A to modulate presynaptic neurotransmitter release (12) and inhibits presynaptic Ca^{2+} channels to reduce neuronal excitability (12,13). Though LEV is a relatively safe and effective ASM with fewer side effects than carbamazepine, phenytoin and valproic acid, its side effects include somnolence, asthenia, mood disorder and behavioral disturbance (14), which cannot be tolerated by certain patients. In addition, LEV monotherapy does not adequately control seizures in all patients.

Perampanel (PER) is a novel antiepileptic agent that selectively and non-competitively inhibits α -amino-3-hydroxy-5-methyl-4-isoxazolepropionic acid (AMPA)-type glutamate receptors present on the post-synaptic membrane. It can suppress neuronal excitability irrespective of the glutamate concentration in the synaptic cleft (15). PER was approved in Europe and the US in 2012, while in Japan, in 2016, it was approved for use in combination with other ASMs for treatment-resistant focal seizures (including those with secondary generalization) and tonic-clonic seizures, and in 2020, it was approved in Japan as monotherapy for treating focal seizures (including those with secondary generalization) (16,17).

Several studies have reported the use of PER in patients with brain tumors (18,19). These reports have demonstrated the efficacy of PER combined with other ASM in controlling seizures. Only one study has examined PER monotherapy, and has demonstrated its efficacy in preventing early seizures in patients with supratentorial brain tumors undergoing craniotomy (20). The present study aimed to further investigate

Correspondence to: Dr Ryota Tamura, Department of Neurosurgery, Keio University School of Medicine, 35 Shinanomachi, Shinjuku-ku, Tokyo 160-8582, Japan
E-mail: moltobello-r-610@keio.jp

Abbreviations: ASM, antiseizure medication; LEV, levetiracetam; PER, perampanel

Key words: antitumor effects, brain tumor, epilepsy, monotherapy, perampanel

PER monotherapy in patients with brain tumor and determine its safety and effectiveness.

Materials and methods

Patients and study design. This retrospective case-control study analyzed the cases of 25 patients with brain tumor who underwent surgery and received PER monotherapy at Keio University Hospital, (Tokyo, Japan) between April 2020 and September 2022. Furthermore, 45 patients with brain tumor who underwent surgery and received LEV monotherapy from April 2018 to October 2018 were used as controls. All of the patients in both the PER and LEV groups received standard clinical treatment. In the PER group, the patients were prescribed an initial dose of 2 mg/day of PER. The daily dosage was increased by 2 mg at 2-week intervals based on each patient's clinical response and tolerance, as per the label instructions. In the LEV group, the patients were initially prescribed a dosage of 1,000 mg/day of LEV, and the dosage was subsequently increased by 1,000 mg/day until the epileptic seizures were resolved.

The present study was approved by the Keio University School of Medicine Ethics Committee (Tokyo, Japan; approval no., 20050002). At the time of surgery, all patients provided written consent for the possibility of subsequent retrospective review of clinical and other outcomes. If the patient was a minor or was incapable of making decisions due to the effects of a brain tumor, the next of kin signed the form.

Data collection. Clinical data, including age, sex, diagnosis, date of surgery, date of initiation of ASM, details of seizures before initiation of treatment, details of seizures after initiating administration, side effects and dosage were obtained from the medical records. Inclusion criteria were as follows: Patients who had undergone craniotomy for tumor resection or a biopsy along with a histopathological diagnosis; and had received either PER or LEV during the above-mentioned period. Patients with a previous history of epilepsy were also included, since patients who had surgery at our hospital during the relevant period were included, regardless of their previous epilepsy history. Patients were excluded if they were receiving concomitant therapy with other antiepileptic drugs or if any essential variables were missing from the records. Tumors were graded in accordance with the World Health Organization classification (21). Adverse events were graded in accordance with the Common Terminology Criteria for Adverse Events, version 5.0 (22). The ASM administration patterns were categorized as follows: Perioperative prophylaxis administered within one week post-surgery, perioperative prophylaxis administered for more than one week, initiation of ASM due to seizures, switch from another ASM due to adverse events and others (Fig. 1). Epileptic seizures were defined in accordance with the International League Against Epilepsy 2017 seizure classification (23).

Statistical analysis. Fisher's exact test or the Mann-Whitney U-test were used as appropriate for comparison of the clinical and demographic data. Rates of seizures and adverse events between the PER and LEV groups were compared using Fisher's exact test. $P < 0.05$ was considered significant.

Compliance with standards. The present study followed The Strengthening the Reporting of Observational Studies in Epidemiology checklist (24).

Results

Patient characteristics. The 25 patients in the PER group included 11 males and 14 females. The mean age at initiation of PER therapy was 46.2 years (range, 17-83 years). The different types of brain tumor were as follows: Glioma [grade 4 (10 patients, 40.0%); grade 3 (two patients, 8.0%); grade 2 (one patient (4.0%)); meningioma [grade 3 (one patient, 4.0%); grade 1 (four patients, 16.0%); malignant lymphoma (one patient, 4.0%); metastatic brain tumor (two patients, 8.0%); and other tumor types (four patients, 16.0%). The tumor distribution in the PER group is depicted in Fig. 2A. Glioma was the most prevalent tumor type (13 patients, 52.0%), with the majority of patients (10 patients, 77%) having grade 4 glioma.

Among the 45 patients in the LEV group, 23 were males and 22 were females. The mean age at initiation of LEV therapy was 60.6 years (range, 21-85 years). The following brain tumor types were present in this group: Glioma [grade 4 (eight patients, 17.8%); grade 2 (three patients, 6.7%); meningioma [grade 2 (four patients, 8.9%); grade 1 (21 patients, 46.7%); malignant lymphoma (two patients, 4.4%); metastatic brain tumor (four patients, 8.9%); and other tumors (three patients, 6.7%). The tumor distribution in the LEV is depicted in Fig. 2B.

While the PER and LEV groups differed significantly with respect to age and tumor type, the differences with regard to sex were not significant. The mean age was significantly lower and gliomas were significantly more frequent in the PER group (Table I).

ASM administration patterns. Patients were classified based on the PER/LEV administration pattern (Fig. 1) as follows: Perioperative prophylaxis administered for one week following surgery, perioperative prophylaxis administered for more than one week, initiation prompted by seizure/s, switch from another ASM due to adverse events and others. In the PER group, the number of patients in each category was 3 (12%), 12 (48%), 6 (24%), 2 (8%) and 2 (8%), respectively. Six of the 12 patients (50%) who received prophylactic PER for more than one week had a grade 3 or 4 glioma (data not shown). In the LEV group, 17 patients had received perioperative prophylaxis for one week, 14 received prophylaxis for more than one week and 14 had received LEV because of seizures (Table I).

Dosage. PER was initiated at 2 mg/day; the daily dose was increased in 2-mg increments at 2-week intervals if needed, based on clinical response and tolerability and in accordance with the label instructions. In patients receiving PER for seizure treatment, the dose was increased until the cessation of seizures. Prophylactic PER was administered at maintenance doses of 2 or 4 mg based on tolerability. The mean dose administered was 3.12 mg/day (range, 2-8). In two patients, the dosage had to be reduced because of side effects. LEV was initiated at 1,000 mg/day, and when used as a treatment regime, the dose was increased by 1,000 mg/day until resolution of

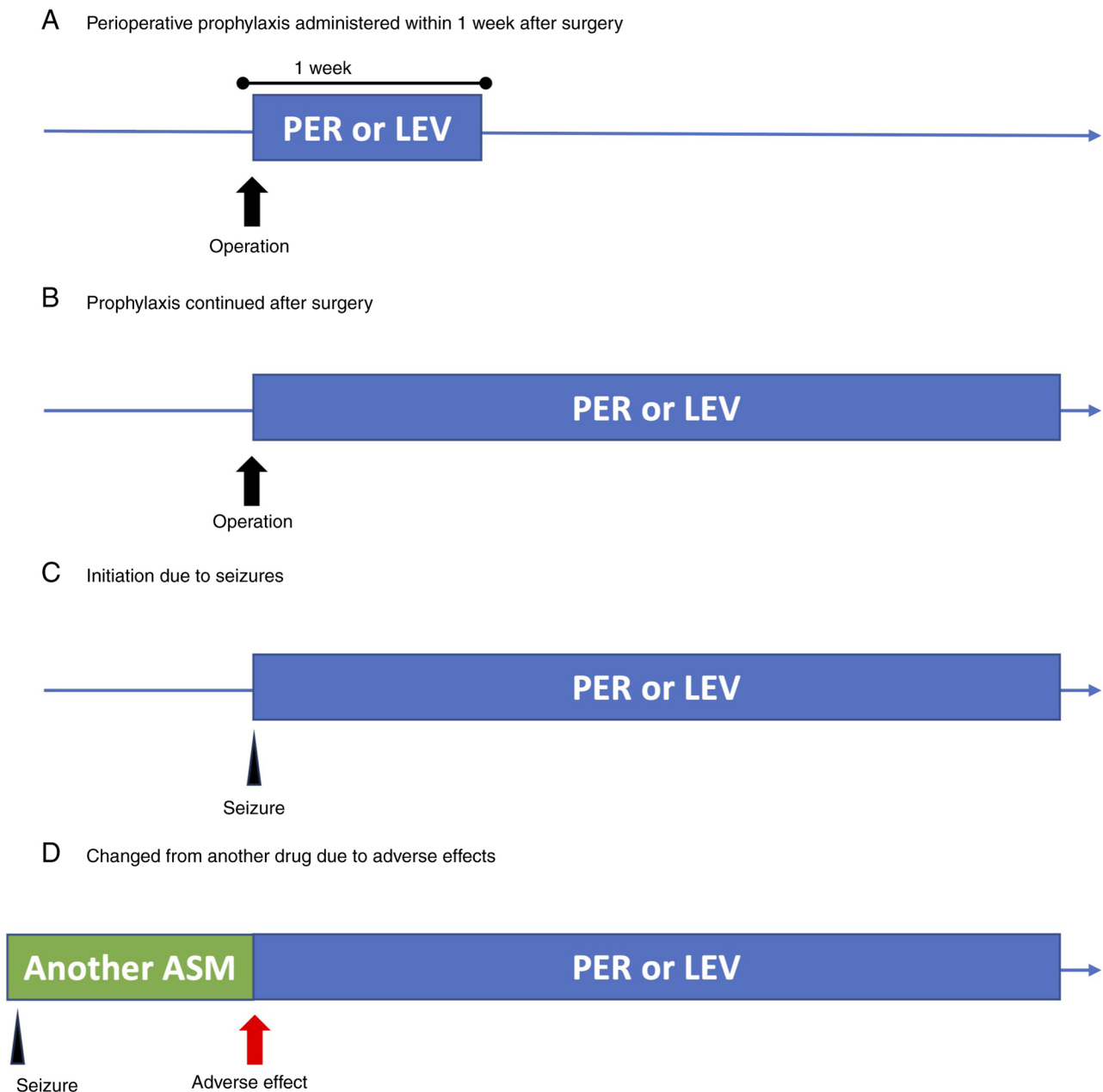


Figure 1. Administration pattern. Drug administration patterns were classified into four categories. (A) Prophylactic administration only perioperatively, within one week. (B) Prophylactic administration continued beyond the perioperative period. (C) Administration as a treatment for seizures. (D) Administration changed due to adverse effects of another drug. ASM, antiseizure medication; PER, Perampanel; LEV, levetiracetam.

epileptic seizures. The mean dose was 1,066.7 mg/day (range, 1,000-2,000) (Table II).

Seizure control and adverse events. Two patients in the PER group and five in the LEV group suffered from seizures during ASM administration (8.0 and 11.1%, respectively; $P=1.000$) (Table II). Increasing the dose or adding another ASM successfully controlled the seizures in all patients in each group. Both patients from the PER group who experienced seizures had focal seizures and had a history of seizures prior to PER administration. One of the patients had a grade 4 glioma and the other had a grade 1 meningioma. None of the patients who received PER for prophylaxis experienced seizures.

All five patients in the LEV group with seizures also experienced focal seizures. Of these, three patients had a

history of seizures and two patients experienced seizures while on prophylactic LEV. Tumor pathology in these five patients was as follows: One patient had a grade 4 glioma, two patients had grade 1 meningioma and the remaining two had other types.

A total of three patients in the PER group (12.0%) taking PER at 2 mg/day experienced adverse events, with two patients suffering from grade 3 liver dysfunction and one patient having a grade 2 drug rash. In these patients, PER was either discontinued or they were switched to another ASM. In the LEV group, only one patient (2.2%) taking 1,000 mg per day experienced an adverse event (drug rash, grade was not documented). The PER and LEV groups did not differ significantly with regard to incidence of adverse events ($P=0.127$) (Table II).

Table I. Patients' characteristics.

Item	PER (n=25)	LEV (n=45)	P-value
Female sex	14 (56.0)	22 (48.9)	0.568
Mean age, years (range)	46.2 (17-83)	60.6 (21-85)	0.002
Type of tumor			0.017
Glioma WHO grade 2	1 (4.0)	3 (6.7)	
Glioma WHO grade 3	2 (8.0)	0 (0)	
Glioma WHO grade 4	10 (40.0)	8 (17.8)	
Meningioma	4 (16.0)	21 (46.7)	
Atypical meningioma	0 (0)	4 (8.9)	
Anaplastic meningioma	1 (4.0)	0 (0)	
Metastatic brain tumor	2 (8.0)	4 (8.9)	
Malignant lymphoma	1 (4.0)	2 (4.4)	
Others	4 (16.0)	3 (6.7)	
Antiseizure medication administration pattern			0.010
Prophylactic use within 1 week after surgery	3 (12)	17 (37.8)	
Prophylaxis continued after surgery	12 (48)	14 (31.1)	
Initiation due to seizures	6 (24)	14 (31.1)	
Changed from another drug due to adverse effects	2 (8)	0	
Others	2 (8)	0	

Values are expressed as n (%) unless otherwise specified. LEV, levetiracetam; PER, perampanel; WHO, World Health Organization.

Table II. Outcomes regarding dose, seizures and adverse effects.

Item	PER (n=25)	LEV (n=45)	P-value
Mean dosage, mg/day (range)	3.12 (2-8)	1066.7 (1,000-2,000)	
Seizure, n (%)	2 (8)	5 (11.1)	1.000
Adverse effect, n (%)	3 (12)	1 (2.2)	0.127
Liver dysfunction	2 (8)	0 (0)	0.124
Drug rash	1 (4)	1 (2.2)	1.000

LEV, levetiracetam; PER, perampanel.

Discussion

In the present study, the results of PER monotherapy in patients with brain tumor were summarized and the results were compared with those of LEV monotherapy. Both groups were similar with respect to the rates of seizures and adverse events. Adverse events were observed in 12% of patients in the PER group, which is lower than previously reported rates for PER monotherapy (20.0-45.9%) (25-28). Since in the present study, ASM was mostly used in both groups in the perioperative period, one of the many other drugs administered during this period may have been the underlying cause of the adverse events instead of PER or LEV. Reported incidence rates of adverse events that result in discontinuation of PER monotherapy range from 6.7 to 16.3% (16), which is similar to that observed in the present study (12%).

Approximately 20% of patients undergoing craniotomy for a supratentorial non-traumatic lesion experience seizures (1).

Several randomized controlled trials and systematic reviews have reported that ASM prophylaxis does not result in a significant reduction in postoperative seizures in these patients (6,10,29). However, a meta-analysis that specifically included patients undergoing craniotomy for brain tumors has reported a significant reduction in early postoperative seizures caused by prophylactic ASM (30). While recent surgical techniques, such as awake surgery, can induce intraoperative seizures (31), the efficacy of prophylactic administration for such seizures has not yet been adequately debated.

Although the efficacy of prophylactic ASMs in the perioperative period remains a debatable topic (29), they are still frequently used (32). In our institution, prophylactic ASM is routinely used in the first week after craniotomy, even in patients who have not suffered preoperative seizures. One study has reported that a combination of PER and LEV in patients undergoing awake surgery for glioma is associated with a significantly lower risk of intraoperative seizures

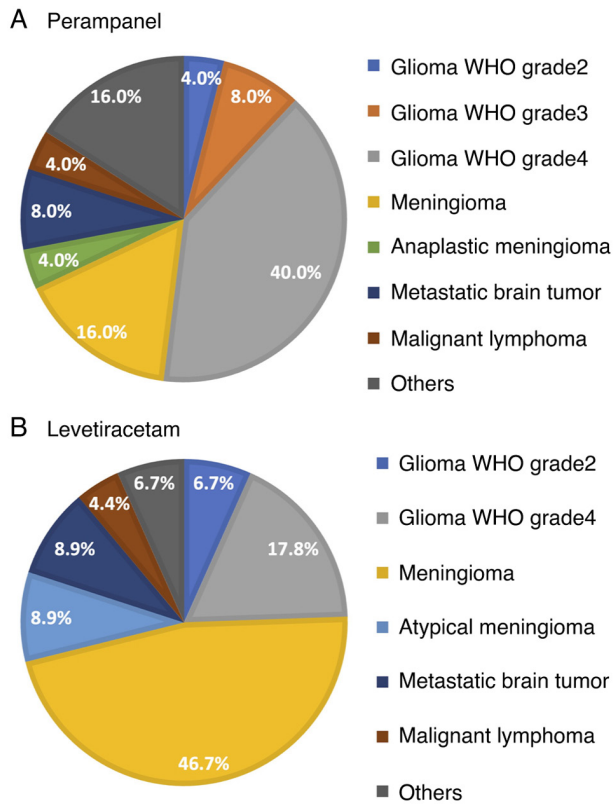


Figure 2. Number of patients classified based on brain tumors. (A) Breakdown graph by tumor type of patients treated with perampanel monotherapy: Glioma WHO grade 4 is the most common. (B) Breakdown graph by tumor type of the levetiracetam monotherapy group, with meningioma being the most common. WHO, World Health Organization.

compared with LEV monotherapy (33). Prophylactic administration of PER during the first six days following a brain tumor surgery may be associated with a similar seizure prevention rate and safety profile to that of LEV (20). Only 15 patients in the present study received PER as perioperative prophylaxis and none experienced postoperative seizures. Also, 12 of them continued PER monotherapy beyond one week and six of these patients suffered from grade 3 or 4 gliomas. Seizure-free patients with grade 3 or 4 gliomas at the time of initial surgery may experience tumor recurrence, and recurrence can further be associated with new seizures (34). Malignant tumors remain incurable even when combinations of various treatments are used, and although substantial basic research has been conducted (35,36), only a limited number of treatments have actually been put to practical use. Drug repositioning, which has been attracting attention in recent years, is a method of discovering new drug effects from existing drugs with proven safety and pharmacokinetics in humans (37). In addition, PER has been observed to inhibit glioma cell growth *in vitro* (38). In a phase II trial, talampanel, an AMPA receptor inhibitor, was observed to extend median survival in patients with glioblastoma treated with radiation and temozolomide (39). Salmaggi *et al* (40) demonstrated that PER in combination with temozolomide exerts a synergistic effect in promoting apoptosis in human glioblastoma cell lines. A phase II trial to assess the efficacy and tolerability of PER in recurrent glioblastoma is ongoing (41). Numerous studies have demonstrated the safety

and efficacy of PER in suppressing seizures in patients with brain tumors (42), particularly when used in combination with other ASMs.

The expression of *GRIA2* and *GRIA4*, which encode separate subunits of the AMPA receptor, is upregulated in certain brain tumors besides gliomas (43,44). AMPA receptor inhibitors exhibit antitumor effects in small-cell lung cancer, but not in the brain microenvironment (45). *GRIA2* upregulation has also been detected in melanoma brain metastases (46). Hence, the AMPA receptor may be an effective therapeutic target for brain tumors, leading to the drug repositioning strategy.

The present study indicates the safety and efficacy of PER monotherapy in patients with brain tumor. Although the evidence supporting prophylactic ASM administration in patients with brain tumor who are seizure-free is limited, PER can be considered if the side effects are tolerable. PER monotherapy may be preferable to combination therapy for prophylactic treatment, in terms of side effects. Currently, the most specific drug option via drug repositioning for refractory brain tumor remains elusive. If the side effects of the drug repositioning strategy using PER are less severe than those of chemotherapy and molecular targeted therapy, PER can represent a meaningful option in terms of both seizure control and tumor control, which may lead to an improvement in symptoms and enhanced quality of life for patients with brain tumors. Further studies on the effects of PER on seizures and tumor growth are warranted.

This study has several limitations. The retrospective design and small sample size may have resulted in a selection bias, which may affect the stability and generalizability of the results. Furthermore, patient age and tumor type were not homogeneous between the PER and LEV groups, which may have introduced certain inaccuracies in the results. Due to the small number of cases and the variety of tumors included, classification by brain tumor grade did not allow for a statistically powerful analysis. Detailed information regarding the usage of analgesic and antiemetic medications during the perioperative period may also be necessary for further discussion regarding adverse events. Comprehensive and in-depth comparisons of serum biological indicators and electroencephalograms are warranted for obtaining more convincing results. Although gliomas are the most common type of brain tumor causing epilepsy (47,48) and the glioma prevalence was much higher in the PER group, the seizure rates in the PER and LEV groups were comparable. A difference between the groups would have been detectable if the groups had been more homogeneous. Various types of tumor were included in this analysis, and thus, factors such as the extent of tumor resection, which are affected by the tumor type, were not included because they were not standardized. In future analyses, we would like to standardize the tumor types and include other variables, such as the extent of tumor resection.

In conclusion, PER monotherapy may be safe and effective for seizure treatment or prophylaxis in patients with brain tumor. Recent studies have revealed that PER may also have antitumor effects, which could potentially make it an effective treatment option for epilepsy related to brain tumors. Further accumulation of case studies is necessary to confirm its efficacy in the future.

Acknowledgements

Not applicable.

Funding

No funding was received.

Availability of data and materials

The data generated in the present study may be requested from the corresponding author.

Authors' contributions

UH and RT conceptualized, designed and performed the study and wrote the manuscript. TE, KKa, KY and AT assisted in the acquisition of data. The authenticity of the raw data was checked and confirmed by UH and RT. KKo and MT assisted with the discussion and review of the manuscript. All authors have read and approved the final version.

Ethics approval and consent to participate

The studies involving humans have been approved by the Keio University School of Medicine Ethics Committee (Tokyo, Japan; approval no. 20050002). The patients or their next of kin provided written informed consent to participate in the study.

Patient consent for publication

Not applicable.

Competing interests

The authors declare that they have no competing interests.

References

1. Foy PM, Copeland GP and Shaw MD: The incidence of postoperative seizures. *Acta Neurochir (Wien)* 55: 253-264, 1981.
2. Manaka S, Ishijima B and Mayanagi Y: Postoperative seizures: Epidemiology, pathology, and prophylaxis. *Neurol Med Chir (Tokyo)* 43: 589-600; discussion 600, 2003.
3. North JB, Penhall RK, Hanieh A, Frewin DB and Taylor WB: Phenytoin and postoperative epilepsy. A double-blind study. *J Neurosurg* 58: 672-677, 1983.
4. Temkin NR: Prophylactic anticonvulsants after neurosurgery. *Epilepsy Curr* 2: 105-107, 2002.
5. Lee ST, Lui TN, Chang CN, Cheng WC, Wang DJ, Heimburger RF and Lin CG: Prophylactic anticonvulsants for prevention of immediate and early postcraniotomy seizures. *Surg Neurol* 31: 361-364, 1989.
6. Wu AS, Trinh VT, Suki D, Graham S, Forman A, Weinberg JS, McCutcheon IE, Prabhu SS, Heimberger AB, Sawaya R, *et al*: A prospective randomized trial of perioperative seizure prophylaxis in patients with intraparenchymal brain tumors. *J Neurosurg* 118: 873-883, 2013.
7. Rudà R, Bello L, Duffau H and Soffietti R: Seizures in low-grade gliomas: Natural history, pathogenesis, and outcome after treatments. *Neuro Oncol* 14 (Suppl 4): iv55-iv64, 2012.
8. Vecht CJ and Wilms EB: Seizures in low- and high-grade gliomas: Current management and future outlook. *Expert Rev Anticancer Ther* 10: 663-669, 2010.
9. Walbert T, Harrison RA, Schiff D, Avila EK, Chen M, Kandula P, Lee JW, Le Rhun E, Stevens GHJ, Vogelbaum MA, *et al*: SNO and EANO practice guideline update: Anticonvulsant prophylaxis in patients with newly diagnosed brain tumors. *Neuro Oncol* 23: 1835-1844, 2021.
10. Iuchi T, Kuwabara K, Matsumoto M, Kawasaki K, Hasegawa Y and Sakaida T: Levetiracetam versus phenytoin for seizure prophylaxis during and early after craniotomy for brain tumours: A phase II prospective, randomised study. *J Neurol Neurosurg Psychiatry* 86: 1158-1162, 2015.
11. Konrath E, Marhold F, Kindler W, Scheichel F, Popadic B, Blauensteiner K, Calabek B, Freydl E, Weber M, Ristl R, *et al*: Perioperative levetiracetam for seizure prophylaxis in seizure-naïve brain tumor patients with focus on neurocognitive functioning. *BMC Neurol* 22: 250, 2022.
12. Dircio-Bautista M, Colín-González AL, Aguilera G, Maya-López M, Villeda-Hernández J, Galván-Arzate S, García E, Túnez I and Santamaría A: The antiepileptic drug levetiracetam protects against quinolinic acid-induced toxicity in the rat striatum. *Neurotox Res* 33: 837-845, 2018.
13. Vogl C, Mochida S, Wolff C, Whalley BJ and Stephens GJ: The synaptic vesicle glycoprotein 2A ligand levetiracetam inhibits presynaptic Ca²⁺ channels through an intracellular pathway. *Mol Pharmacol* 82: 199-208, 2012.
14. Fuller KL, Wang YY, Cook MJ, Murphy MA and D'Souza WJ: Tolerability, safety, and side effects of levetiracetam versus phenytoin in intravenous and total prophylactic regimen among craniotomy patients: A prospective randomized study. *Epilepsia* 54: 45-57, 2013.
15. Hanada T, Hashizume Y, Tokuhara N, Takenaka O, Kohmura N, Ogasawara A, Hatakeyama S, Ohgoh M, Ueno M and Nishizawa Y: Perampnel: A novel, orally active, noncompetitive AMPA-receptor antagonist that reduces seizure activity in rodent models of epilepsy. *Epilepsia* 52: 1331-1340, 2011.
16. Yamamoto T, Gil-Nagel A, Wheless JW, Kim JH and Wechsler RT: Perampnel monotherapy for the treatment of epilepsy: Clinical trial and real-world evidence. *Epilepsy Behav* 136: 108885, 2022.
17. Eisai News Release. Approval of antiepileptic drug Fycompa® in Japan for monotherapy and pediatric indications for partial-onset seizures, as well as a new formulation. Available at: <https://www.eisai.com/news/2020/news202004.html>. Accessed April 12, 2024.
18. Heugenhauer J, Iglseider S, Muigg A, Kerschbaumer J, Stockhammer G, Nowosielski M and Unterberger I: Perampnel in brain tumor and SMART-syndrome related epilepsy-A single institutional experience. *J Neurol Sci* 423: 117386, 2021.
19. Maschio M, Zarabla A, Maialelli A, Giannarelli D, Koudriavtseva T, Villani V and Zannino S: Perampnel in brain tumor-related epilepsy: Observational pilot study. *Brain Behav* 10: e01612, 2020.
20. Kusakabe K, Inoue A, Watanabe H, Nakamura Y, Nishikawa M, Ohtsuka Y, Ogura M, Shigekawa S, Taniwaki M, Kitazawa R and Kunieda T: Perioperative perampnel administration for early seizure prophylaxis in brain tumor patients. *Surg Neurol Int* 14: 287, 2023.
21. WHO Classification of Tumours Editorial Board. World Health Organization Classification of Tumours of the Central Nervous System. 5th edition. International Agency for Research on Cancer, 2021.
22. Common Terminology Criteria for Adverse Events (CTCAE). Version 5. Published: November 27. US Department of Health and Human Services, National Institutes of Health, National Cancer Institute, 2017.
23. Fisher RS, Cross JH, D'Souza C, French JA, Haut SR, Higurashi N, Hirsch E, Jansen FE, Lagae L, Moshé SL, *et al*: Instruction manual for the ILAE 2017 operational classification of seizure types. *Epilepsia* 58: 531-542, 2017.
24. von Elm E, Altman DG, Egger M, Pocock SJ, Gøtzsche PC and Vandenbroucke JP: STROBE Initiative: The strengthening the reporting of observational studies in epidemiology (STROBE) Statement: Guidelines for reporting observational studies. *BMJ* 335: 806-808, 2007.
25. Toledano Delgado R, García-Morales I, Parejo-Carbonell B, Jiménez-Huete A, Herrera-Ramírez D, González-Hernández A, Ayuga Loro F, Santamarina E, Toledo M, Ojeda J, *et al*: Effectiveness and safety of perampnel monotherapy for focal and generalized tonic-clonic seizures: Experience from a national multicenter registry. *Epilepsia* 61: 1109-1119, 2020.

26. Chinvarun Y: A retrospective, real-world experience of perampanel monotherapy in patient with first new onset focal seizure: A Thailand experience. *Epilepsia Open* 7: 67-74, 2022.
27. Gil-Nagel A, Burd S, Toledo M, Sander JW, Lebedeva A, Patten A and Laurenza A: Study 504 investigator group: A retrospective, multicentre study of perampanel given as monotherapy in routine clinical care in people with epilepsy. *Seizure* 54: 61-66, 2018.
28. Wechsler RT, Wheless J, Zafar M, Huesmann GR, Lancman M, Segal E, Chez M, Aboumatar S, Patten A, Salah A and Malhotra M: PROVE: Retrospective, non-interventional, phase IV study of perampanel in real-world clinical care of patients with epilepsy. *Epilepsia Open* 7: 293-305, 2022.
29. Greenhalgh J, Weston J, Dunder Y, Nevitt SJ and Marson AG: Antiepileptic drugs as prophylaxis for postcraniotomy seizures. *Cochrane Database Syst Rev* 5: CD007286, 2020.
30. Joiner EF, Youngerman BE, Hudson TS, Yang J, Welch MR, McKhann GM, Neugut AI and Bruce JN: Effectiveness of perioperative antiepileptic drug prophylaxis for early and late seizures following oncologic neurosurgery: A meta-analysis. *J Neurosurg* 130: 1274-1282, 2018.
31. Nossek E, Matot I, Shahar T, Barzilai O, Rapoport Y, Gonen T, Sela G, Korn A, Hayat D and Ram Z: Failed awake craniotomy: A retrospective analysis in 424 patients undergoing craniotomy for brain tumor. *J Neurosurg* 118: 243-249, 2013.
32. Dewan MC, Thompson RC, Kalkanis SN, Barker FG II and Hadjipanayis CG: Prophylactic antiepileptic drug administration following brain tumor resection: Results of a recent AANS/CNS section on tumors survey. *J Neurosurg* 126: 1772-1778, 2017.
33. Motomura K, Chalise L, Shimizu H, Yamaguchi J, Nishikawa T, Ohka F, Aoki K, Tanahashi K, Hirano M, Wakabayashi T and Natsume A: Intraoperative seizure outcome of levetiracetam combined with perampanel therapy in patients with glioma undergoing awake brain surgery. *J Neurosurg* 135: 998-1007, 2021.
34. Hildebrand J, Lecaillon C, Perennes J and Delattre JY: Epileptic seizures during follow-up of patients treated for primary brain tumors. *Neurology* 65: 212-215, 2005.
35. Yin X, Yang J, Zhang M, Wang X, Xu W, Price CH, Huang L, Liu W, Su H, Wang W, *et al*: Serum metabolic fingerprints on bowl-shaped submicroreactor chip for chemotherapy monitoring. *ACS Nano* 16: 2852-2865, 2022.
36. Zhu H, Yang C, Yan A, Qiang W, Ruan R, Ma K, Guan Y, Li J, Yu Q, Zheng H, *et al*: Tumor-targeted nano-adjuvants to synergize photomediated immunotherapy enhanced antitumor immunity. *View* 4: 20220067, 2023.
37. Tamura R: Drug repositioning for refractory benign tumors of the central nervous system. *Int J Mol Sci* 24: 12997, 2023.
38. Venkataramani V, Tanev DI, Strahle C, Studier-Fischer A, Fankhauser L, Kessler T, Körber C, Kardorff M, Ratliff M, Xie R, *et al*: Glutamatergic synaptic input to glioma cells drives brain tumour progression. *Nature* 573: 532-538, 2019.
39. Grossman SA, Ye X, Chamberlain M, Mikkelsen T, Batchelor T, Desideri S, Piantadosi S, Fisher J and Fine HA: Talampanel with standard radiation and temozolomide in patients with newly diagnosed glioblastoma: A multicenter phase II trial. *J Clin Oncol* 27: 4155-4161, 2009.
40. Salmaggi A, Corno C, Maschio M, Donzelli S, D'Urso A, Perego P and Ciusani E: Synergistic effect of perampanel and temozolomide in human glioma cell lines. *J Pers Med* 11: 390, 2021.
41. Heuer S, Burghaus I, Gose M, Kessler T, Sahm F, Vollmuth P, Venkataramani V, Hoffmann D, Schlesner M, Ratliff M, *et al*: PerSurge (NOA-30) phase II trial of perampanel treatment around surgery in patients with progressive glioblastoma. *BMC Cancer* 24: 135, 2024.
42. Tabaei Damavandi P, Pasini F, Fanella G, Cereda GS, Mainini G, DiFrancesco JC, Trinka E and Lattanzi S: Perampanel in brain tumor-related epilepsy: A systematic review. *Brain Sci* 13: 326, 2023.
43. Vivero M, Doyle LA, Fletcher CD, Mertens F and Hornick JL: GRIA2 is a novel diagnostic marker for solitary fibrous tumour identified through gene expression profiling. *Histopathology* 65: 71-80, 2014.
44. Sarver AE, Sarver AL, Thayanithy V and Subramanian S: Identification, by systematic RNA sequencing, of novel candidate biomarkers and therapeutic targets in human soft tissue tumors. *Lab Invest* 95: 1077-1088, 2015.
45. Masumoto N, Kato S, Aichi M, Hasegawa S, Sahara K, Suyama K, Sano A, Miyazaki T, Okudela K, Kaneko T and Takahashi T: AMPAR receptor inhibitors suppress proliferation of human small cell lung cancer cell lines. *Thorac Cancer* 14: 2897-2908, 2023.
46. Nygaard V, Prasmickaite L, Vasiliauskaite K, Clancy T and Hovig E: Melanoma brain colonization involves the emergence of a brain-adaptive phenotype. *Oncoscience* 1: 82-94, 2014.
47. Lynam LM, Lyons MK, Drazkowski JF, Sirven JI, Noe KH, Zimmerman RS and Wilkens JA: Frequency of seizures in patients with newly diagnosed brain tumors: A retrospective review. *Clin Neurol Neurosurg* 109: 634-638, 2007.
48. Riva M: Brain tumoral epilepsy: A review. *Neurol Sci* 26 (Suppl 1): S40-S42, 2005.



Copyright © 2024 Hino et al. This work is licensed under a Creative Commons Attribution-NonCommercial-NoDerivatives 4.0 International (CC BY-NC-ND 4.0) License.