

Comparison of the clinical value of multi-band mucosectomy versus endoscopic mucosal resection for the treatment of patients with early-stage esophageal cancer

ZI-YANG CHEN*, YUN-CHAO YANG*, LI-MEI LIU, XIAO-GANG LIU, YI LI,
LIANG-PING LI, XIAO HU, REN-YI ZHANG, YAN SONG and QIN QIN

Department of Digestion, Sichuan Academy of Medical Sciences and Sichuan Provincial People's Hospital,
Chengdu, Sichuan 610072, P.R. China

Received June 18, 2014; Accepted February 25, 2015

DOI: 10.3892/ol.2015.3098

Abstract. The present study aimed to compare the clinical value of multi-band mucosectomy (MBM) versus endoscopic mucosal resection (EMR) for the treatment of patients with early-stage esophageal cancer. Between January 2011 and December 2012, 68 patients with early-stage esophageal cancer who underwent MBM and EMR were enrolled into the present study. The curative resection rate, duration of surgery, complications and follow-up records were retrospectively analyzed. Of the 68 patients included, 33 were treated with MBM and 35 with EMR. There was no significant difference in the rate of complete resection between the MBM and EMR groups ($P>0.05$). The mean duration of surgery in the MBM group was statistically lower than that in the EMR group ($P<0.05$). There was no statistically significant difference in the intraoperative and post-operative complications between the MBM and EMR groups ($P>0.05$). Esophageal cancer reoccurred in 2 patients treated with MBM and 1 patient treated with EMR during the follow-up period (range, 3-24 months). Overall, MBM can be considered a better surgical option for the management of patients with early-stage esophageal cancer, as it offers higher histological curative resection rates and improved safety. However, further studies and a larger follow-up period are required to confirm the long-term curative effect.

Introduction

Esophageal cancer, which is malignant and occurs in the esophageal epithelium, is particularly associated with an increased risk of mortality if left untreated in its early stages (1). The 5-year survival rate has been shown to be $<20\%$, which is one of the lowest rates for all cancers (2,3). Early-stage esophageal cancer consists of cancer that has not spread beyond the mucosal lining of the esophagus or to the lymph nodes, or cancers that have not metastasized beyond the esophagus. Recent advances in endoscopic technology have increased the detection rate of early-stage esophageal cancer (4). Surgical esophagectomy has been the standard treatment offered to patients with malignant tumors in the digestive tract. Although this achieves a curative outcome in the majority of these patients, it is associated with considerable morbidity and mortality. During the last few decades, more and more early-stage esophageal lesions have been also treated using an endoscopic option along with endoscopic detection, which is targeted and minimally invasive. Recent studies have demonstrated 5-year survival rates of up to 95% (5-7). Compared with conventional esophagectomy, endoscopic therapies for early-stage esophageal cancer are viable alternatives, with significantly lower morbidity rates.

Recently, endoscopic mucosal resection (EMR) and multi-band mucosectomy (MBM) have been used for early-stage esophageal cancer. EMR has been widely used for early-stage esophageal cancer as a potentially curative treatment, while MBM has been demonstrated to allow safe and easy piecemeal resections, to save time and money, and to cause less bleeding (8). However, there are a limited number of control studies with regard to the comparative curative effects between these two techniques. The aim of the present retrospective study was to compare the EMR and MBM techniques for treating early-stage esophageal cancer.

Patients and methods

Clinical data. The study was approved by the Ethics Committee of Sichuan Academy of Medical Sciences and Sichuan Provincial People's Hospital (Chengdu, Sichuan, China), and written informed consent was obtained from all subjects. Between

Correspondence to: Dr Li-Mei Liu, Department of Digestion, Sichuan Academy of Medical Sciences and Sichuan Provincial People's Hospital, 32 West Second Section First Ring Road, Chengdu, Sichuan 610072, P.R. China
E-mail: liulimei66@yeah.net

*Contributed equally

Key words: multi-band mucosectomy, endoscopic mucosal resection, early-stage esophageal cancer

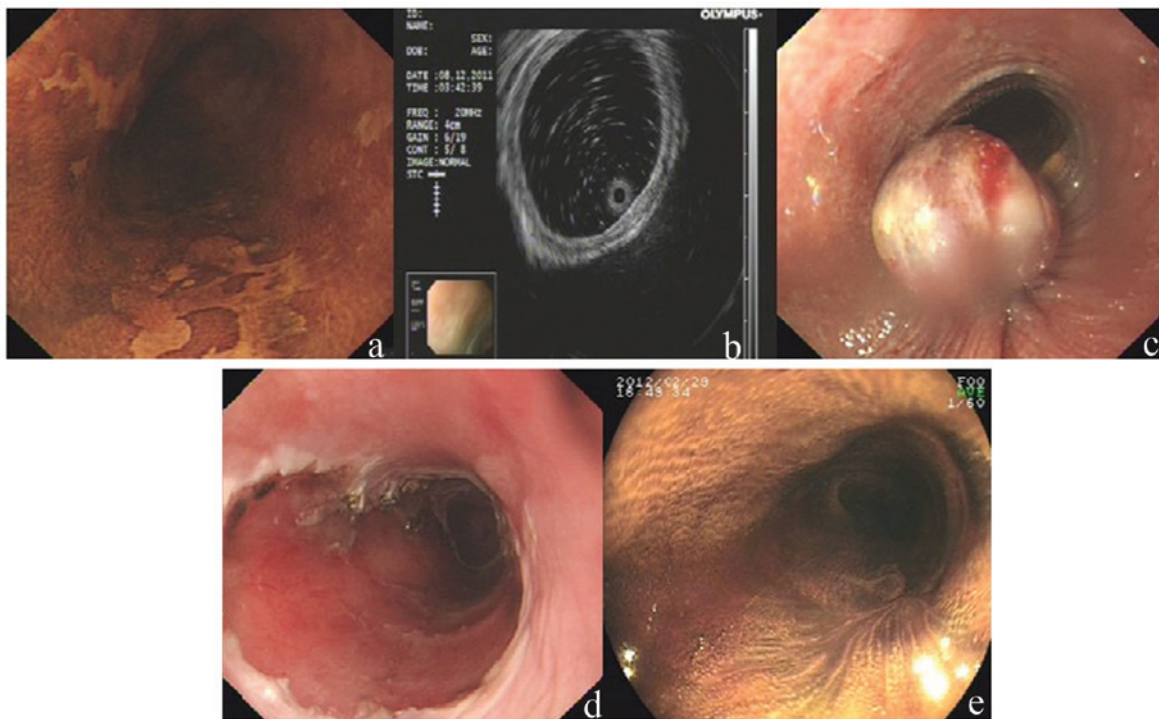


Figure 1. Endoscopic technique. (a) Endoscopic view following iodine spraying, showing iodine-unstained areas. (b) Endoscopic ultrasonic view following iodine spraying, showing the neoplastic areas. (c) Endoscopic view following multiple-band ligations. (d) Endoscopic appearance following the resection of the neoplastic lesion by multi-band mucosectomy. (e) Post-operative endoscopic view during the follow-up period.

January 2009 and June 2012, a total of 68 patients (51 males and 17 females; age range, 47-76 years) were referred for the treatment of early-stage esophageal cancer. Among them, 35 patients underwent MBM and the other 33 patients underwent EMR. All clinical and histological data were collected from the patients for this retrospective study. Gastroscopy was performed by skilled endoscopists. The chromoendoscopy was performed for the prediction of the nature of the lesion. Histopathological examination and biopsy were then performed, and endoscopic ultrasound was used for the evaluation of the infiltration depth of the lesion once early-stage esophageal cancer was diagnosed. Patients with lesions limited to the mucosal layer and no more than one-third of the submucosal layer were included in this study. Patients with lesions limited to the mucosal layer or less than one-third of the submucosal layer were excluded.

Surgical procedures

MBM procedure. MBM was performed with the patient placed under deep sedation using titrated intravenous propofol. Following plain endoscopy, staining with 1% Lugol's iodine was performed. Next, argon plasma coagulation (APC) was used to mark the neoplastic areas of the lesion, with a 2-mm margin. Next, MBM was performed with a ligator and a snare. A regular transparent cap with rubber bands was attached to two wires. The wires were fixed on the control handle by placing the cap onto the distal end of the endoscope and pulling the wires through the working channel with the aid of a loading catheter delivered with the Duette[®], Multi-Band Mucosectomy kit (Cook Medical, Limerick, Ireland). In this way, a pseudopolyp was created when the rubber band is released, while the mucosa is sucked into the cap. Pseudopolyps were resected with the snare by electric coagulation

(Fig. 1). No submucosal saline solution injection was required prior to ligation. The snare was placed below the rubber band. Following each resection, the resected specimen and the detached rubber band were pushed into the stomach by using the tip of the snare's catheter or were flushed down by a water jet from a pump machine connected to the accessory channel of the endoscope. Resections were subsequently performed in the same way.

EMR procedures. Briefly, EMR was performed with the patient placed under deep sedation with titrated intravenous propofol. Following plain endoscopy, 1% Lugol's iodine staining was performed. Next, APC was used to mark the neoplastic areas of the lesion, with a 2-mm margin. A submucosal injection of glycerin fructose, indigo carmine and epinephrine was then used to lift the lesion: Submucosal injection solution (100 ml saline + 5 ml indigo carmine + 1 ml epinephrine) was injected into the area around the lesion in order to lift it from the muscularis propria layer; the mucosa only, and not the tumor, was lifted. Next, a circumferential incision into the submucosa was performed around the lesion (with a 5-mm margin to the lesion) using an insulation-tipped electrosurgical (IT) knife (Olympus Corporation, Tokyo, Japan). Finally, the EMR procedure was performed, predominantly with the use of a Flex knife, Hook knife (Olympus Corporation), and IT knife. The solution was injected repeatedly during the dissection to avoid muscularis propria injury and perforation. Further resection was performed to ensure total removal of the lesion if necessary. Exposed vessels were coagulated with APC to prevent delayed bleeding. To control bleeding, APC or hot biopsy forceps and titanium clips were used as necessary. Following removal of the lesion, the en bloc pathological specimen was prepared for histological examination.

Table I. Clinical characteristics of the patients.

| Variables | MBM (n=35) | EMR (n=33) |
|---|------------|------------|
| Age ^a , years | 56.65±8.36 | 54.69±7.16 |
| Gender, n | | |
| Male | 25 | 26 |
| Female | 10 | 7 |
| Tumor location (<1/2 segment of esophagus), n (%) | 35 (100) | 33 (100) |
| Tumor size ^a , cm ² | 3.67±1.07 | 3.64±0.81 |

^aData presented as the mean ± standard deviation. MBM, multi-band mucosectomy; EMR, endoscopic mucosal resection.

Table II. Comparison of operation time and complete resection rate in two groups.

| Groups | n | Duration of surgery, min | Complete resection rate, % (n/total n) |
|----------|----|--------------------------|--|
| MBM | 35 | 31.31±4.04 ^a | 91.43 (32/35) |
| EMR | 33 | 47.18±4.57 ^a | 96.97 (32/33) |
| P-values | | <0.001 | 0.641 |

^aData presented as the mean ± standard deviation. MBM, multi-band mucosectomy; EMR, endoscopic mucosal resection.

Table III. Clinical outcomes.

| Outcome | MBM (n=35) | EMR (n=33) | P-values |
|---------------------------------------|-------------|-------------|----------|
| Perforation, n | 0 | 1 | 0.485 |
| Post-operative bleeding, n | 0 | 0 | |
| Post-operative esophageal stenosis, n | 5 | 3 | 0.710 |
| Recurrence rate, n/total n (%) | 2/35 (5.71) | 1/33 (3.03) | 0.608 |

MBM, multi-band mucosectomy; EMR, endoscopic mucosal resection.

Following the surgery, the patients were admitted to hospital for observation over 24 h, and received 40 mg of esomeprazole sodium (Nexium I.V.; AstraZeneca, Wilmington, DE, USA) once daily as an intravenous bolus injection, for 3-5 consecutive days. The patients fasted for 24 h, then consumed a liquid diet the following day and a semi-liquid diet the third day.

Post-operative treatment. Post-operatively, endoscopic ultrasonic examinations, computed tomography scans of the neck, chest and upper abdomen, routine blood examinations, coagulation tests, blood group tests and blood preparations were performed for risk evaluation of lymph nodes or distant metastases and the surgical outcomes or efficacy. Vital signs were monitored by electrocardiogram.

Histopathological assessment. MBM and EMR specimens were histopathologically assessed to ensure radical resection of a suspicious lesion with a disease-free margin. Pathological specimens were unfolded, fixed with 4% formaldehyde and vertically sectioned every 2-mm. A positive specimen exhibited tumor cell invasion at the lateral and basal margins.

Curative resections presented with a negative specimen, with tumor-negative surgical margins. Specimens that did not meet these conditions were considered to represent a non-curative resection.

Statistical analysis. SPSS software version 13.0 (SPSS Inc., Chicago, IL, USA) was used for data analysis. Qualitative data were expressed as a frequency and percentage. The χ^2 test was used to examine the correlation between qualitative variables. Normally distributed continuous data are presented as the mean ± standard deviation and were compared using Student's *t*-tests. Non-normally distributed continuous data are presented as the median and range, and were compared using the Wilcoxon rank sum test. $P < 0.05$ was considered to indicate a statistically significant difference.

Results

During the study period, 68 patients with early-stage esophageal cancer were enrolled; 35 patients underwent MBM and 33 patients underwent EMR. The mean ages of the

patients in the MBM and EMR groups were 56.65 ± 8.36 and 54.69 ± 7.16 years, respectively. In the MBM group, 25 of the patients were male (71.43%) and 10 were female (28.57%), while in the EMR group, 26 were male (78.79%) and 7 were female (21.21%). All surgeries were performed in the middle and lower segments of the esophagus. The mean size of the resected specimens was 3.67 ± 1.07 cm² for MBM group and 3.64 ± 0.81 cm² for the EMR group. No statistically significant difference was observed with regard to age, gender, tumor location and size of resected specimens between the two groups ($P > 0.05$) (Table I).

The mean duration of surgery was 31.31 ± 4.04 min for the MBM group and 47.18 ± 4.57 min for the EMR group ($P < 0.001$). The rate of complete resection was 91.43% (32/35) for patients undergoing MBM and 96.97% (32/33) for those receiving EMR resection ($P = 0.641$) (Table II).

The complications and recurrence rates are summarized in Table III. Perforations occurred in 1 out of 33 patients (3.03%) in the EMR group, which was higher compared with the perforation rate of 0 (0/35) in the MBM group ($P = 0.485$). None of the patients developed post-operative bleeding in the two groups. Esophageal stenosis occurred in 5 patients treated with MBM and in 3 patients treated with EMR. There was no statistically significant difference with regard to the intra-operative and post-operative complications between the two groups (Table III).

The mean follow-up period for patients undergoing MBM and EMR was 14 months (range, 6-24 months). Of the 68 patients, esophageal cancer reoccurred in 2 patients (5.71%) treated with MBM and 1 patient (3.03%) treated with EMR. No statistically significant difference was observed between the two groups ($P = 0.608$) (Table III).

Discussion

With the development of endoscopic technique in the last few decades, endoscopic therapy has become an alternative to surgery that has been proven to be safe and effective for the treatment of early-stage cancer in the alimentary tract, with an increasing detection rate (9). Commonly, early-stage esophageal cancer is limited to the mucosa and submucosa (i.e., m1-m3) without lymphatic/vascular invasion (10). Radical resection of early gastroesophageal neoplasia has become possible using an endoscopic technique. Endoscopic therapy with radical resection has become a viable alternative for patients with neoplasia or early-stage esophageal cancer due to the low rates of lymphatic or hematogenous dissemination (4,11), corroborated by the adverse effects of conventional esophagectomy. Endoscopic therapy offers minimally invasive treatment at a lower cost, but with improved post-operative recovery and less complications to surgery (12).

At present, the commonly used endoscopic techniques are endoscopic submucosal dissection (ESD), EMR, APC and radiofrequency ablation (RFA). APC and RFA are ablative approaches that use different energy sources to obliterate the lesions (4). This means that if these two techniques are used for the treatment of intramucosal cancer, there is no way to assess the depth of tumor invasion or to confirm that the tumor treated is actually confined to the mucosa. Therefore, the techniques are of limited use due to inherent weaknesses, such

as providing no tissue specimen for histopathological assessment and a higher rate of recurrence. With regard to EMR, the most prominent disadvantage appears to be that only small lesions with a diameter of < 20 mm can be resected (13), and this approach may not be preferred, as lesions arise from the submucosa and may be difficult to completely resect, with concerns over the presence of residual neoplasia and difficulties in planning future management (14). EMR is the most common endoscopic technique at present, with minimal invasiveness, complete resection and fewer complications (10,11). In 2007, MBM was compared with EMR in a retrospective study, and proved to be safer and have better curative resection rate in early-stage gastroesophageal neoplasia (8). This conclusion was confirmed by the subsequent studies by Bhat *et al* (15) and Herrero *et al* (16). In a previous study ($n = 72$), the cap technique with submucosal injection and the ligation technique without submucosa injection were found to be similar with respect to efficacy and safety in endoscopic resections of early-stage esophageal cancers (17). However, there are limited number of control studies comparing EMR and MBM.

To better understand the MBM approach for early-stage esophageal cancer, one of the key indicators for evaluation is the rate of curative resection. The results in the present study showed rates without significant differences in the EMR and MBM groups. No post-operative bleeding was encountered in either group, with a lower rate of esophageal stenosis, a complication that is common in traditional surgeries. The surgical process of MBM was also able to efficiently avoid intraoperative perforations as the submucosal lesions could be well isolated from the muscularis propria using the cranking device and transparent cap, and the possible suctioned muscularis propria could slip out of the rubber band due to the shuttle and gas injection of the snare. Therefore, MBM is a type of minimally invasive surgery with good safety. Meanwhile, the mean duration of surgery for MBM was significantly less than that for EMR, which would contribute to a reduction of total procedure costs and complications. MBM presents with clear advantages, and has been shown to be a safe technique that is easy to apply, requiring a relatively short period of time compared with EMR. MBM is therefore worthy of clinical application for early-stage esophageal cancer.

In conclusion, in the present study, the early-stage esophageal cancer patients exhibited a promising curative resection rate and a relative low rate of complications. This study showed that MBM is a greatly effective, technically feasible and relatively safe treatment for early-stage esophageal cancer. However, a larger sample size and prolonged follow-up time are required to assess the long-term effects.

References

1. McCann P, Stafinski T, Wong C and Menon D: The safety and effectiveness of endoscopic and non-endoscopic approaches to the management of early esophageal cancer: a systematic review. *Cancer Treat Rev* 37: 11-62, 2011.
2. Clifton JC, Finley RJ, Gelfand G, *et al*: Development and validation of a disease-specific quality of life questionnaire (EQOL) for potentially curable patients with carcinoma of the esophagus. *Dis Esophagus* 20: 191-201, 2007.
3. Yousef F, Cardwell C, Cantwell MM, *et al*: The incidence of esophageal cancer and high-grade dysplasia in Barrett's esophagus: a systematic review and meta-analysis. *Am J Epidemiol* 168: 237-249, 2008.

4. Li Q, Zhong Y, Chen W, *et al*: New endoscopic diagnosis and treatment options for early esophageal cancer. *J Gastroint Dig Syst* 2: 108, 2012.
5. Ell C, May A, Pech O, *et al*: Curative endoscopic resection of early esophageal adenocarcinomas (Barrett's cancer). *Gastrointest Endosc* 65: 3-10, 2007.
6. Pech O, Behrens A, May A, *et al*: Long-term results and risk factor analysis for recurrence after curative endoscopic therapy in 349 patients with high-grade intraepithelial neoplasia and mucosal adenocarcinoma in Barrett's oesophagus. *Gut* 57: 1200-1206, 2008.
7. Peters FP, Kara MA, Rosmolen WD, *et al*: Endoscopic treatment of high-grade dysplasia and early stage cancer in Barrett's esophagus. *Gastrointest Endosc* 61: 506-514, 2005.
8. Peters FP, Kara MA, Curvers WL, *et al*: Multiband mucosectomy for endoscopic resection of Barrett's esophagus: feasibility study with matched historical controls. *Eur J Gastroenterol Hepatol* 19: 311-315, 2007.
9. Hirooka Y, Itoh A, Kawashima H, *et al*: Contrast-enhanced endoscopic ultrasonography in digestive diseases. *J Gastroenterol* 47: 1063-1072, 2012.
10. Pouw RE and Bergman JJ: Endoscopic resection of early oesophageal and gastric neoplasia. *Best Pract Res Clin Gastroenterol* 22: 929-943, 2008.
11. Siriwardana HP, Harvey MH, Kadirkamanathan SS, *et al*: Endoscopic mucosal resection of a solitary metastatic tumor in the stomach: a case report. *Surg Laparosc Endosc Percutan Tech* 22: e132-e134, 2012.
12. Gotoda T and Jung HY: Endoscopic resection (endoscopic mucosal resection/endoscopic submucosal dissection) for early gastric cancer. *Dig Endosc* 25 Suppl 1: 55-63, 2013.
13. Burkitt MD and Pritchard DM: Review article: Pathogenesis and management of gastric carcinoid tumours. *Aliment Pharmacol Ther* 24: 1305-1320, 2006.
14. Hopper AD, Bourke MJ, Hourigan LF, *et al*: En-bloc resection of multiple type 1 gastric carcinoid tumors by endoscopic multi-band mucosectomy. *J Gastroenterol Hepatol* 24: 1516-1521, 2009.
15. Bhat YM, Furth EE, Brensinger CM and Ginsberg GG: Endoscopic resection with ligation using a multi-band mucosectomy system in Barrett's esophagus with high-grade dysplasia and intramucosal carcinoma. *Therap Adv Gastroenterol* 2: 323-330, 2009.
16. Herrero LA, Pouw RE, van Vilsteren FJ, *et al*: Safety and efficacy of multiband mucosectomy in 1060 resections in Barrett's esophagus. *Endoscopy* 43: 177-183, 2011.
17. May A, Gossner L, Behrens A, *et al*: A prospective randomized trial of two different endoscopic resection techniques for early stage cancer of the esophagus. *Gastrointest Endosc* 58: 167-175, 2003.