SPANDIDOS PUBLICATIONS

ONCOLOGY LETTERS 28: 500, 2024

Diagnostic difficulties in the differentiation between an ovarian metastatic low-grade appendiceal mucinous neoplasm and primary ovarian mucinous cancer: A case report and literature review

WERONIKA KAWECKA[1], ANETA ADAMIAK-GODLEWSKA[1], DOROTA LEWKOWICZ[2], KAROLINA URBAŃSKA[3] and ANDRZEJ SEMCZUK[1]

[1]The Second Department of Gynecological Surgery and Gynecological Oncology, University Clinical Hospital no. 4, Lublin Medical University, PL-20090 Lublin, Poland; [2]Department of Clinical Pathomorphology, Lublin Medical University, PL-20090 Lublin, Poland; [3]Students' Research Group at The Second Department of Gynecological Surgery and Gynecological Oncology, Lublin Medical University, PL-20090 Lublin, Poland

Received February 27, 2024; Accepted July 3, 2024

DOI: 10.3892/ol.2024.14633

Abstract. Low-grade appendiceal mucinous neoplasm (LAMN) is a tumor that primarily originates from the appendix and belongs to the family of appendiceal mucinous neoplasms (AMNs). In 50% of female patients, AMNs (particularly LAMNs) have a tendency to metastasize to organs in the genital tract, where the neoplasm can mimic the features of primary ovarian mucinous cancer (POMC). The present case report reviewed the difficulties in differentiating between these two types of tumors. In the present case report, a 61-year-old female patient was admitted to the Second Department of Gynecological Surgery and Gynecological Oncology, University Clinical Hospital no. 4 at Lublin Medical University (Lublin, Poland) with the diagnosis of a right ovarian mass. After performing ultrasound and computed tomography (CT) scans and laboratory analysis, the patient underwent total abdominal hysterectomy, bilateral salpingo-oophorectomy, omentectomy, appendectomy and resection of the Douglas peritoneum. Notably, the postoperative pathological assessment revealed LAMN with metastases to the right ovary and omentum. Immunohistochemically, cytokeratin 20 and caudal type homeobox 2 both stained positively, whereas paired box gene 8 stained negatively. After surgery, the patient received the recommended hyperthermic intraperitoneal chemotherapy at the Department of Surgical Oncology at Lublin Medical University. After 1 year, a CT scan was performed, which indicated no evidence of recurrent disease. In conclusion, observations from the present case report suggest that gynecologists should be conscious of the possibility of malignancies of gastrointestinal origin in cases of ovarian tumors instead of making direct assumptions of POMC. If the mucinous mass involves the base of the appendix or if there is a suspicion of positive margins, then cytoreductive surgery and right-sided hemicolectomy must be performed. In addition, identifying the origin of mucinous tumors in the right ovary and/or the appendix requires the histopathological examination of a panel of markers using immunohistochemistry.

Correspondence to: Professor Andrzej Semczuk, The Second Department of Gynecological Surgery and Gynecological Oncology, University Clinical Hospital no. 4, Lublin Medical University, 8 Jaczewski Street, PL-20090 Lublin, Poland
E-mail: andrzej.semczuk@umlub.pl

Abbreviations: AMN, appendiceal mucinous neoplasm; LAMN, low-grade appendiceal mucinous neoplasm; CT, computed tomography; IHC, immunohistochemistry; PMP, pseudomyxoma peritonei; HIPEC, hyperthermic intraperitoneal chemotherapy; POMC, primary ovarian mucinous cancer

Key words: LAMN, metastasis, PMP, mucinous neoplasm, appendiceal tumor, immunohistochemistry

Introduction

Low-grade appendiceal mucinous neoplasm (LAMN) is an epithelial, non-invasive tumor with any of the following features: loss of muscularis mucosae, fibrosis of submucosa and/or 'pushing invasion' (expansile or diverticulum-like growth) (1-3). LAMN is detected in 0.7-1.7% of all appendectomies. In particular, the 'pushing invasion' feature of LAMNs may increase the possibility of ovarian involvement. Ovarian metastases are found in ~50% of female patients with appendiceal tumors (4). Symptoms of this disease are non-specific, although abdominal pain in the right lower quadrant is the most common complaint (3). If ovarian metastasis occurs, a pelvic mass may become palpable during gynecological examination (2). The most common clinical manifestation of LAMN is an acute appendicitis combined with a perforation of the appendiceal wall (3).

Although preoperative diagnosis can be made by computed tomography (CT) examination (5-7), LAMN is mostly frequently identified intraoperatively or even postoperatively

incidentally. This issue particularly concerns female patients, since metastatic ovarian mucinous neoplasms also share similar atypical clinical manifestations and imaging findings (4). The most effective differential diagnostic technique known for LAMN is immunohistochemical examination. The most common immunohistochemistry (IHC) markers applied for diagnostic purposes include cytokeratin (CK)7, CK20, caudal type homeobox 2 (CDX2), paired box gene 8 (PAX8) and special AT-rich sequence-binding protein 2 (SATB2) (8-10).

The treatment method for LAMN typically depends on the tumor stage, whether perforation of the appendiceal wall has occurred, presence of metastases and the existence of peritoneal mucin spread. For localized LAMN, appendectomy is generally sufficient. In cases of metastases to the abdominal organs or the pseudomyxoma peritonei (PMP), cytoreductive surgery followed by hyperthermic intraperitoneal chemotherapy (HIPEC) is highly recommended (1,3,11-13). In particular, the most dangerous complication among the aforementioned is PMP, when the mucin from the appendix spreads to the peritoneum (1,14,15). The risk of developing PMP increases significantly when spontaneous perforation of the appendiceal wall has occurred (16).

There are only a few articles concerning this topic worldwide, and they generally focus on different aspects of this tumor from the surgical point of view. The lack of articles from the perspective of gynecologists indicates that further exploration of this topic is required. Therefore, the present report documents the case of the 61-year-old female patient who was diagnosed postoperatively with LAMN metastasizing to the right ovary and omentum. Diagnostic difficulties during the clinical course of this patient were summarized before differentiation between metastatic LAMN in the ovary and primary ovarian mucinous cancer (POMC).

Case report

A 61-year-old female patient was admitted to the Second Department of Gynecological Surgery and Gynecological Oncology, University Clinical Hospital no. 4, Lublin Medical University (Lublin, Poland) with the primary diagnosis of a right ovarian tumor in May, 2021. The condition manifested as chronic pelvic pain and pain after defecation lasting several weeks. The patient denied having other symptoms, illnesses or medicaments. According to the medical history of the patient, the last menstruation occurred 10 years ago, and the patient underwent two vaginal deliveries. The last cervical cytological examination was performed 3 years ago and was normal. The patient also suffered from hepatitis B at the age of 15 years old and chronic varices in both legs for >10 years.

On gynecological examination, the external genitalia, vagina and uterine cervix all revealed normal results. However, a palpable pathological mass in the lower-right abdomen was detected. The body of the uterus had an uneven surface and was painful on palpation. The left ovary was not palpable. Biochemical examination revealed cancer antigen 125 levels of 20.2 U/ml [reference range (RR) <35 U/ml], carcinoembryonic antigen levels of 7.7 ng/ml (RR <2.5 ng/ml in non-smoking patients) and a Risk of Ovarian Malignancy Algorithm index of 12.4% (RR <29.9% in postmenopausal women). On transvaginal ultrasound examination, a 16-cm-wide tumor in the right ovary with heterogenous echogenicity was observed (Fig. 1). Between the tumor and circumfluent lesions, a noticeable border was confirmed. The uterus and the left ovary were normal, where the endometrium thickness was 4 mm. A small quantity of ascites fluid was detected in the Douglas pouch, but distant metastases or pathological regional lymph nodes could not be identified.

Abdominal CT scans revealed a large polycystic, pathological mass in the lesser pelvis. The size of the tumor was 17.4x11.7x9.9 cm. No other abnormalities were found in the pelvis minor. The patient was then recommended for explorative laparotomy. In the abdominal cavity, a wide litho-cystic tumor (10x17 cm) originating from the right adnexa was found. The mass in the right ovary was in continuity with the appendiceal neoplasm, the appendiceal walls were thickened and the lesion was swollen. The size of the uterus was normal. Numerous lesions were found to be localized on the left ovary, Douglas peritoneum, greater omentum and both diaphragmatic of the domes. The patient underwent total abdominal hysterectomy, bilateral salpingo-oophorectomy, total omentectomy, appendectomy and resection of the Douglas peritoneum. The postoperative period was uneventful, and 5 days after the surgery the patient was discharged from the hospital in good condition.

Postoperative histopathological examination revealed a LAMN with metastases to the right ovary and omentum. Mucinous tumors were found in the Douglas peritoneum and in the 'free end' of the appendix (0.7 cm; Fig. 2). Wall perforation and neoplastic infiltration of the appendiceal mucosa were also observed (Fig. 3). For postoperative histopathological examination, the tissues were fixed with 10% formalin and embedded into paraffin blocks for 24-48 h at room temperature. Then, 5-μm sections were deparaffinized and rehydrated using routine techniques. Antigen retrieval by microwave and blocking of endogenous peroxidase activity (by 1% hydrogen peroxide in distillated water for 10 min at room temperature) was conducted before incubation with the following primary antibodies: CK20 (monoclonal mouse anti-human antibody; ready-to-use; cat. no. GA777; DAKO; Agilent Technologies, Inc.), CDX2 (monoclonal mouse anti-human antibody; ready-to-use; cat. no. GA080; DAKO; Agilent Technologies, Inc.) and PAX8 (monoclonal mouse anti-human antibody; ready-to-use; cat. no. 760-4618; Roche Diagnostics) at 4˚C overnight. The primary antibodies were then removed, and the slides were incubated for 30 min at room temperature with a biotin-free horseradish peroxidase enzyme-labelled polymer of the DAKO RealTM EnVisionTM/HRP detection system (DAKO; Agilent Technologies, Inc.). Next, following reaction with 3,3'-diaminobenzidine, the sections were counterstained with hematoxylin for 2 h at room temperature, dehydrated and cover-slipped. Appropriate positive and negative controls were also applied. Stained slides were carefully examined by two investigators by light microscopy. The results indicated CK20 (Fig. 4A) and CDX2 (Fig. 4B) positive staining in the right ovary and appendix, whereas PAX8 (Fig. 4C) staining was negative. The patient was then referred to the Department of Surgical Oncology, Lublin Medical University, where the patient underwent a one-time HIPEC procedure with 30 mg mitomycin C for 1 h at 43˚C. After HIPEC, the patient was discharged in good

Figure 1. Abdominal ultrasound scan showing an irregular 16-cm-wide mass with heterogenous echogenicity. The mass was preliminarily diagnosed as an right ovarian mucinous tumor.

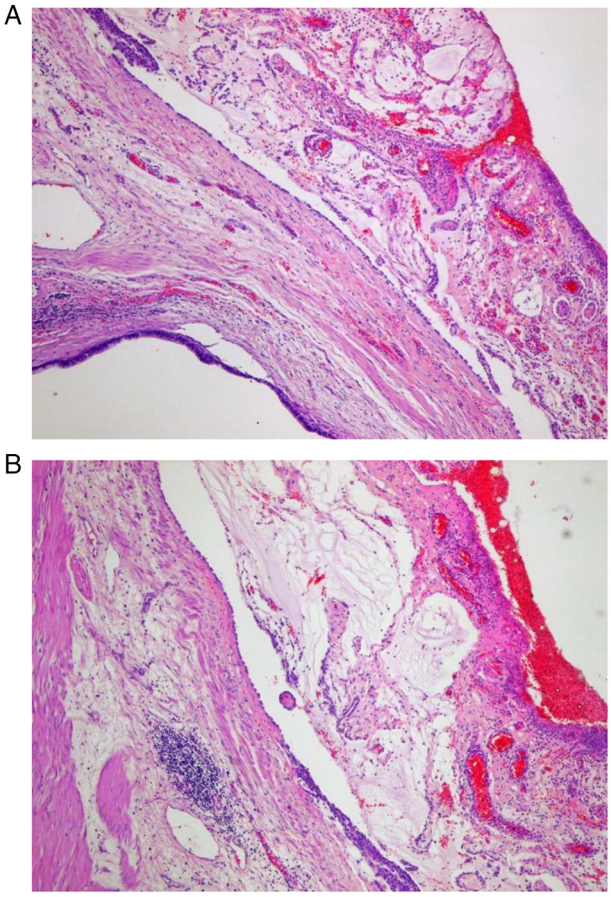

Figure 2. (A) Wall of the dilated appendix with neoplastic mucinous epithelial lining and extra-appendiceal mucus with serosal reaction, without infiltrative growth or desmoplastic reactions. H&E staining; magnification, x100. (B) Neoplastic cells of the dilated appendix containing abundant apical mucin and elongated nuclei with low grade nuclear atypia. H&E staining; magnification, x100.

condition. The recurrence of LAMN was not reported during the 1-year follow-up. After 1 year, a CT scan was performed, which revealed no evidence of recurrent disease. The patient remains in the follow-up program devised by the gynecological oncology specialists and remains asymptomatic.

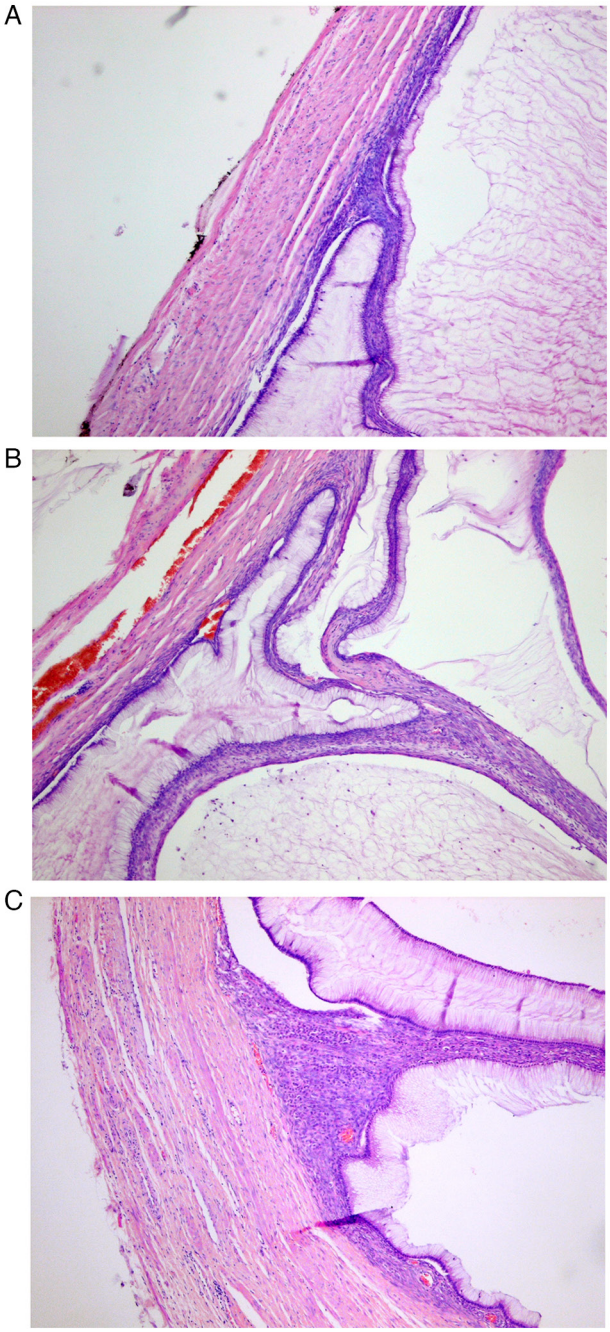

Figure 3. (A-C) Ovary with metastatic low-grade appendiceal mucinous neoplasm. Focally preserved ovarian stroma are visible around the cystic spaces, lined with mucinous epithelium. H&E staining; magnification, x100.

Discussion

One of the main difficulties with mucinous ovarian neoplasms is differentiating them from other types of metastatic tumor, particularly those originating from the gastrointestinal tract. POMCs represent 3% of all primary ovarian tumors, whereas metastatic ovarian tumors account for 5-30% of all ovarian malignancies. The majority of metastases to the ovaries arise from organs in the gastrointestinal tract, where those of appendiceal origin pertain to 13% of such cases (17-19).By gross morphology, ovarian metastases are generally smaller compared with those of primary neoplasms, with sizes typically

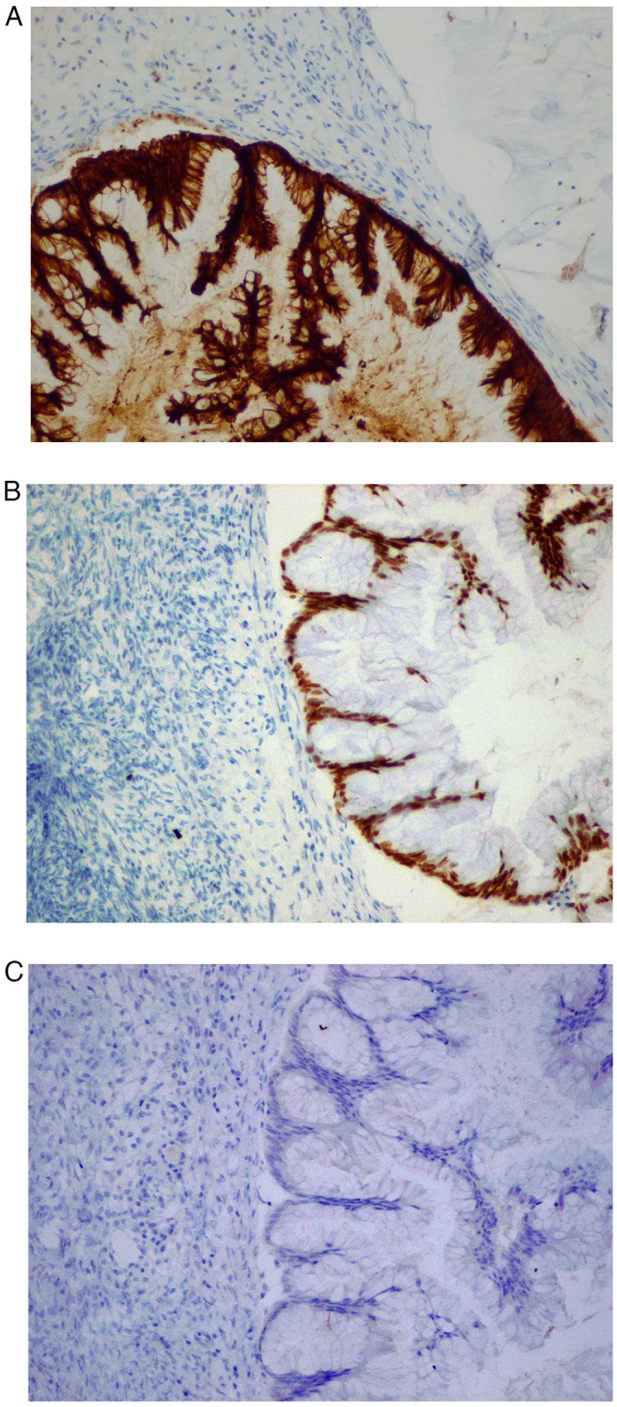

Figure 4. Right ovary with metastatic low-grade appendiceal mucinous neoplasm. Immunohistochemical staining for (A) caudal type homeobox 2, (B) cytokeratin 20 and (C) paired box gene 8. Magnification, x100.

Table I. A comparison between primary ovarian mucinous tumors and mucinous ovarian metastases.

Feature	Primary tumor	Metastatic tumor
Laterality	Unilateral	Bilateral
Size, cm	>10	<10
Age of patients, years	<50	>50
Presence of signet ring cells	Absent	Present
Type of invasion	Expansile	Infiltrative, vascular

Table II. Expression patterns of the most common immunohistochemistry markers depending on the origin of the tumor.

Marker	POMN, %	APE, %
CK7	90	26
CK20	65-70	92
PAX8	35	<5
CDX2	<50	97
SATB2	8	85-90

POMN, primary ovarian mucinous neoplasm origin; APE, appendiceal origin; CK, cytokeratin; PAX8, paired box gene 8; CDX2, caudal type homeobox 2; SATB2, special AT-rich sequence-binding protein 2.

Table III. Expression patterns of concomitant IHC markers in POMN and APE.

IHC markers	POMN, %	APE, %
CK7/CK20		
(+)/(+)	67	22
(-)/(+)	7	78
(+)/(-)	26	-
SATB2/CK20		
(+)/(+)	-	80
(+)/(-) or (-)/(+)	-	20
CDX2/CK20		
(+)/(+)	-	90
(+)/(-) or (-)/(+)	-	10

IHC, immunohistochemistry; POMN, primary ovarian mucinous neoplasm origin; APE, appendiceal origin; CK, cytokeratin; CDX2, caudal type homeobox 2; SATB2, special AT-rich sequence-binding protein 2.

≤10 cm in diameter (Table I) (2,13,16,19,20). Histologically, the growth pattern in secondary mucinous tumors is mostly infiltrative and may present as a nodular growth with or without single-cell invasion. In addition, metastases frequently show signs of lymphovascular space invasion, surface and hilar involvements, whilst primary tumors are generally characterized by the presence of microscopic cystic glands and expansive invasion patterns (2,18,19). Differentiating between POMC and ovarian metastases of gastrointestinal tract tumors involves the immunohistochemical assessment of several valuable markers, including SATB2, CDX2, CK7, CK20 and PAX8 (Table II) (17,19). POMC was found to express CK7, CK20 and PAX8 in 90, 65-70 and 35% of all cases assessed, respectively. In addition, the concomitant expression of

Table IV. Comparison between POMC and LAMN.

Feature	POMC	LAMN
Prevalence	3-12% of ovarian malignancies	1% of all appendectomies
Treatment	Staging surgery/cytoreductive surgery, appendectomy, consider HIPEC with cisplatin.	Appendectomy in localized LAMN, cytoreductive surgery and HIPEC with oxaliplatin and mitomycin C. In advanced stage, consider right-sided hemicolectomy.
Survival rate	90% in early-stage disease, 12-30 months in advance-stage.	80% in early-stage disease.

POMC, primary ovarian mucinous cancer; LAMN, low-grade appendiceal mucinous neoplasm; PMP, pseudomyxoma peritonei; HIPEC, hyperthermal intraperitoneal chemotherapy.

CK7 and CK20 is present in ~67% of all cases (9,17,20). By contrast, CDX2 expression is found in <50% of all cases of POMC, whereas expression in metastases of lower gastrointestinal tract origin is markedly more common, occurring in 90% of all tumors (17,20). SATB2 is a recently described marker that has been demonstrated to be a novel tool for the diagnosis of the gastrointestinal neoplasms. SATB2 positivity has been reported in 85-90% of all appendiceal tumors, where its expression is stronger and more specific compared with CDX2 (9,17,20-22). Generally, for POMC, CK7 is considered to be the most sensitive marker, whereas PAX8 is the most specific. Furthermore, CDX2 is considered to be the most sensitive marker for ovarian metastases of lower gastrointestinal tract origin, whilst SATB2 would appear to be the most specific (17,23). Although the aforementioned markers are invaluable diagnostic tools, they cannot be interpreted separately since tumors typically exhibit concomitant expression patterns of each of the individual markers. We recommended the analysis of expression of at least two independent immunohistochemical markers (Table III) (8,9,19,21-28).

The molecular mechanism underlying the growth of POMC and AMNs remains unresolved, since experimental data on these particular malignancies are still limited. KRAS and TP53 genetic alterations are the most frequent in POMCs, with their incidence accounting for 33-46 and 26-55% of cases, respectively (26-27,29).

The treatment strategy for LAMN depends on the clinical stage, histological grade, tumor invasion, the presence of metastases and the careful surgical management (3,28,30). There is an association between the expression profile of the IHC markers and histopathological parameters of the tumor. CDX2 expression has been found to be associated with histological grade and depth of tumor invasion, whilst loss of CK20 positivity has been reported to be associated with a higher histological grade of colorectal carcinoma (23). An appendectomy is typically sufficient for treating localized LAMN, whereas right-sided hemicolectomy should be considered if the positive margins persist after appendectomy (31). Metastases or PMP are generally treated with cytoreductive surgery and HIPEC, including oxaliplatin and mitomycin C. During cytoreductive operations, any suspicious lesions should be removed. However, if the tumor extends to the base of the appendix, then there would be a necessity to perform a caecal wedge resection. Peritoneal surfaces that must be inspected include the right iliac fossa, right paracolic gutter, right diaphragmatic surface, greater omentum and pelvic peritoneum (15). Ovarian metastases of appendiceal origin are reported in ~50% of patients, where they are generally metachronous. Both ovaries should be carefully investigated, in cases where malignancies are discovered, bilateral salpingo-oophorectomy is highly recommended, even in pre-menopausal patients (32-34).

In terms of the prognosis of patients with LAMN, namely overall and disease-free survival, it remains uncertain and depends on the clinical stage, presence of metastases, age and general health condition. However, the 5-year survival rate has been estimated to be 80%. Localized LAMN or PMP appear to have favorable clinical outcomes after complete resection of the primary tumor during early-stage disease, but caution must be taken due to data scarcity (35,36). By contrast, the prognosis for POMC depends on tumor staging and the subtype of cancer. Early-stage POMC has a 90% 5-year overall survival rate, though patients with metastatic mucinous ovarian cancer generally will not survive beyond 30 months (28). An abbreviated comparison between LAMN and POMC is shown in Table IV (4,15,28,31,35,36).

In conclusion, observations from the present case suggest that clinical specialists of gynecological oncology should remain conscious of the possibility of ovarian tumors of gastrointestinal origin in addition to POMC. If the mucinous mass involves the base of the appendix or if there is a suspicion of positive margins, detailed cytoreductive surgery combined with right-sided hemicolectomy is highly recommended. Differentiation of the origin of mucinous tumor in the area of the right ovary and/or the appendix requires histopathological and immunohistochemical examination using a panel of protein markers. In addition, molecular studies into LAMN and POMC are warranted to facilitate the development of novel diagnostic procedures in the future.

Acknowledgements

Not applicable.

Funding

The study was supported by a grant from Lublin Medical University, Lublin, Poland (grant no. Dz. St. 326/24).

Availability of data and materials

The data generated in the present study may be requested from the corresponding author.

Authors' contributions

WK made substantial contributions to conception and design, searched the articles and wrote the manuscript; AAG performed the surgery, collected medical records and wrote the manuscript; DL, as a pathologist, diagnosed the case and prepared the histopathological images; KU analyzed and interpreted the data and searched the articles; AS made substantial contribution to conception and design and edited the manuscript. All authors participated in the drafting of the manuscript. DL and AS confirm the authenticity of all the raw data. All authors read and approved the final version of the manuscript.

Ethics approval and consent to participate

Not applicable.

Patient consent for publication

Written informed consent was obtained from the patient for the publication of anonymized data and all accompanying images.

Competing interests

The authors declare that they have no competing interests.

References

1. Legué LM, Creemers GJ, de Hingh IHJT, Lemmens VEPP and Huysentruyt CJ: Pathologyand its clinical relevance of mucinous appendiceal neoplasms and pseudomyxoma peritonei. Clin Colorectal Cancer 18: 1-7, 2019.
2. Carr NJ, Bibeau F, Bradley RF, Dartigues P, Feakins RM, Geisinger KR, Gui X, Isaac S, Milione M, Misdraji J, *et al*: The histopathological classification, diagnosis and differential diagnosis of mucinous appendiceal neoplasms, appendiceal adenocarcinomas and pseudomyxoma peritonei. Histopathology 71: 847-858, 2017.
3. Shaib WL, Assi R, Shamseddine A, Alese OB, Staley C III, Memis B, Adsay V, Bekaii-SaabT and El-Rayes BF: Appendiceal mucinous neoplasms: Diagnosis and management. Oncologist 22: 1107-1116, 2017.
4. Perivoliotis K, Christodoulidis G, Samara AA, Sgantzou IK, Floros T, Volakakis G, Karasavvidou F and Tepetes K: Low-grade appendiceal mucinous neoplasm (LAMN) primarily diagnosed as an ovarian mucinous tumor. Case Rep Surg 22: 5523736, 2021.
5. Arshi J, Peter AD, Liang Y and Hao Y: Confined low grade appendiceal mucinous neoplasm with coexisting distant metastasis. In Vivo 38: 295-298, 2024.
6. Guzman GA, Montealegre I and Obando AM: Incidental diagnosis of a low-grade mucinous appendicular neoplasm: A case report. Int J Surg Case Rep 105998, 2021.
7. Yu X-R, Mao J, Tang W, Meng X-Y, Tian Y and Du Z-L: Low-grade appendiceal mucinous neoplasms confined to the appendix: Clinical manifestations and CT findings. J Invest Med 68: 75-81, 2020.
8. Schmoeckel E, Kirchner T and Mayr D: SATB2 is a supportive marker for the differentiation of a primary mucinous tumor of the ovary and an ovarian metastasis of a low-grade appendiceal mucinous neoplasm (LAMN): A series of seven cases. Pathol Res Pract 214: 426-430, 2018.
9. Aldaoud N, Erashdi M, Alkhatib S, Abdo N, Al-Mohtaseb A and Graboski-Bauer A: The utility of PAX8 and SATB2 immunohistochemical stains in distinguishing ovarian mucinous neoplasms from colonic and appendiceal mucinous neoplasm. BMC Res Notes 12: 770, 2019.
10. Borges AL, Reis-de-Carvalho C, Chorao M, Pereira H and Djokovic D: Low-grade mucinous appendiceal neoplasm mimicking an ovarian lesion: A case report and review of literature. World J Clin Cases 9: 2334-2343, 2021.
11. Yang W, Nie P, Liu X and Peng J: Comparative effectiveness of prophylactic hyperthermic intraperitoneal chemotherapy (HIPEC) for resected low-grade appendiceal ucinous neoplasm (LAMN). A protocol for systematic review and network meta-analysis. Medicine (Baltimore) 99: e22071, 2020.
12. Guaglio M, Sinukumar S, Kusamura S, Milione M, Pietrantonio F, Battaglia L, Guadagni S, Baratti D and Deraco M: Clinical surveillance after macroscopically complete surgery forlow-grade appendiceal mucinous neoplasms (LAMN) with or without limited peritoneal spread: Long-term results in a prospective series. Ann Surg Oncol 25: 878-884, 2018.
13. Istl AC, Gage MM, Esquivel J, Ahuja N, Greer JB and Johnston FM: Management of low-grade appendiceal mucinous neoplasms (LAMN): An international survey of surgeons performing CRS and HIPEC. Ann Surg Oncol 28: 3831-3837, 2021.
14. Watanabe H, Miyasaki Y, Watanabe K, Sakamoto I, Nakagomi H, Takano A, Ikegame K, Yamamoto A, Nakada H, Yosutome M, *et al*: Pseudomyxoma peritonei due to low-grade appendiceal mucinous neoplasm with symptoms of inguinal hernia and uterine prolapse: A case report and review of the literature. Int Cancer Conf J 6: 158-163, 2017.
15. Ceelen W, Man MD, Willaert W, H van Ramshorst G, Geboes K and Hoorens A: Incidentally found mucinous epithelial tumors of the appendix with or without pseudomyxoma peritonei: Diagnostic and therapeutic algorithms based on current evidence. Acta Chir Belg 121: 225-234, 2021.
16. Hegg KS, Mack LA, Bouchard-Fortier A, Temple WJ and Gui X: Macroscopic and microscopic characteristics of low grade appendiceal mucinous neoplasms (LAMN) on appendectomy specimens and correlations with pseudomyxoma peritonei development risk. Ann Diagn Pathol 48: 151606, 2020.
17. Dundr P, Singh N, Nozickova B, Nemejcova K, Bartu M and Struzinska I: Primary mucinous ovarian tumors vs. ovarian metastases from gastrointestinal tract, pancreas and biliary tree: A review of current problematics. Diagn Pathol 16: 20, 2021.
18. Mills AM and Shanes ED: Mucinous ovarian tumors. Surg Pathol Clin 12: 565-585, 2019.
19. Kubecek O, Laco J, Spacek J, Petera J, Kopecky J, Kubeckova A and Filip S: The pathogenesis, diagnosis, and management of metastatic tumors to the ovary: A comprehensive review. Clin Exp Metastasis 34: 295-307, 2017.
20. Vang R, Gown AM, Wu L-S-F, Barry TS, Wheeler DT, Yemelyanova A, Seidman JD and Ronnett BM: Immunohistochemical expression of CDX2 in primary ovarian mucinous tumors and metastatic mucinous carcinomas involving the ovary: Comparison with CK20 and correlation with coordinate expression of CK7. Mod Pathol 19: 1421-1428, 2006.
21. Li Z, Rock JB, Roth R, Lehman A, Marsh WL, Suarez A and Frankel WL: Dual stain with SATB2 and CK20/Villin is useful to distinguish colorectal carcinomas from other tumors. Am J Clin Pathol 149: 241-246, 2018.
22. Meagher NS, Wang L, Rambau PF, Intermaggio MP, Huntsman DG, Wilkens LR, El- Bahrawy MA, Ness RB, Odunsi K, Steed H, *et al*: A combination of the immunohistochemical markers CK7 and SATB2 is highly sensitive and specific for distinguishing primary ovarian mucinous tumors from colorectal and appendiceal metastases. Mod Pathol 32: 1834-1846, 2019.
23. Ilieva N, Tashkova D, Staykov D, Serteva D, Feodorova Y, Mehterov N, Mollova A and Bachurska S: Immunohistochemical expression of CK20, CK7, and CDX2 in colorectal carcinoma in correlation with pathomorphological characteristics. Folia Med (Plovdiv) 64: 214-220, 2022.
24. Bassiouny D, Ismiil N, Dube V, Han G, Cesari M, Lu FI, Slodkowska E, Parra-Herran C, Chiu HF, Naeim M, *et al*: Comprehensive clinicopathologic and updated immunohistochemical characterization of primary ovarian mucinous carcinoma. Int J Surg Pathol 26: 306-317, 2018.

25. Li Z, Roth R, Rock JB, Lehman A, Marsh WL, Suarez A and Frankel WL: Dual immunostain with SATB2 and CK20 differentiates appendiceal mucinous neoplasms from ovarian mucinous neoplasms. Am J Clin Pathol 147: 484-491, 2017.
26. Genestie C, Auguste A, Al Battal M, Scoazec JY, Gouy S, Lacroix L, Morice P, Pautier P, Leary A and Devouassoux-Shisheboran M: Histological classification of mucinous ovarian tumors: Inter-observer reproducibility, clinical relevance, and role of genetic biomarkers. Virchows Arch 478: 885-891, 2021.
27. Yanai Y, Saito T, Hayashi T, Akazawa Y, Yatagai N, Tsuyama S, Tomita S, Hirai S, Ogura K, Matsumoto T, *et al* Molecular and clinicopathological features of appendiceal mucinous neoplasms. Virchows Arch 478: 413-426, 2021.
28. Gorringe KL, Cheasley D, Wakefield MJ, Ryland GL, Allan PE, Alsop K, Amarasinghe KC, Ananda S, Bowtell DDL, Christie M, *et al*: Therapeutic options for mucinous ovarian carcinoma. Gynecol Oncol 156: 552-560, 2020.
29. Babaier A and Ghatage P: Mucinous cancer of the ovary: Overview and current status. Diagnostics (Basel) 10: 52, 2020.
30. Misdraji J: Mucinous epithelial neoplasms of the appendix and pseudomyxoma peritonei. Mod Pathol 28 (Suppl): S67-S79, 2015.
31. Ciarrocchi A, Rindi G and Pietroletti R: Diagnosis and treatment of primary tumors of the appendix: A critical review. J Gastrointest Cancer 52: 471-475, 2021.
32. Govaerts K, Lurvink RJ, De Hingh IHJT, Van der Speeten K, Villeneuve L, Kusamura S, Kepenekian V, Deraco M, Glehen O and Moran BJ; PSOGI: Appendiceal tumours and pseudomyxoma peritonei: Literature review with PSOGI/EURACAN clinical practiceguidelines for diagnosis and treatment. Eur J Surg Oncol 2021 47:11-35, 2021.
33. Auer RC, Sivajohanathan D, Biagi J, Conner J, Kennedy E and May T: Indications for hyperthermic intraperitoneal chemotherapy with cytoreductive surgery: A systematic review. Eur J Cancer 127: 76-95, 2020.
34. Li X, Zhou J, Dong M and Yang L: Management and prognosis of low-grade appendiceal mucinous neoplasms: A clinicopathologic analysis of 50 cases. Eur J Surg Oncol 44: 1640-1645, 2018.
35. Chen I, Liu X, Kovar-Peltz S, Conrad SJ, Chen HH and Liao X: Clinicopathological spectrums and prognosis of primary appendiceal adenocarcinoma, goblet cell adenocarcinoma, and low-grade appendiceal mucinous neoplasms. Pathology 55: 375-382, 2022.
36. Kohler F, Reese L, Hendricks A, Kastner C, Muller S, Lock JF, German C-T and Wiegering A: Low-grade mucinous neoplasms (LAMN) of the appendix in Germany between2011 and 2018: A nationwide analysis based on data provided by the German Center for Cancer Registry Data (ZfKD) at the Robert Koch Institute (RKI). Langenbecks Arch Surg 407: 3615-3622, 2022.

Copyright © 2024 Kawecka et al. This work is licensed under a Creative Commons Attribution-NonCommercial-NoDerivatives 4.0 International (CC BY-NC-ND 4.0) License.