SPANDIDOS PUBLICATIONS

ONCOLOGY LETTERS 28: 530, 2024

Male breast cancer metastasising to the liver: A case report

MINGMING JIANG, LINYUN LI, HONGJIE LIU and HUA XIE

Department of Oncology, Xuancheng Hospital Affiliated to Wannan Medical College, Xuancheng, Anhui 242000, P.R. China

Received February 24, 2024; Accepted July 19, 2024

DOI: 10.3892/ol.2024.14663

Abstract. Breast cancer (BC) remains one of the most common malignant diseases affecting female patients, and it can metastasize to nearly every part of the body. BC is rare in men, and therefore men rarely develop BC liver metastases (BCLMs). However, the present study reports a 55-year-old male patient who underwent surgery 5 years ago for BC. After treatment, the patient was actively followed up regularly. Recently, the patient was examined for chest tightness, and liver space-occupying lesions were found. The upper abdominal enhanced computed tomography images of the patient showed that the liver density was not uniform and that the liver had a mass. A crude needle biopsy was used to examine the liver tumour under the guidance of ultrasound. The pathology revealed that the patient was positive for E-cadherin, oestrogen receptor, progesterone receptor, human epidermal growth factor receptor 2, GATA binding protein 3 and CK7. The patient was subsequently diagnosed with BCLM. The patient was treated with doxorubicin hydrochloride, cyclophosphamide, Docetaxel and followed up regularly. The present case report emphasizes that BC is found not only in women but also in an increasing number of men, and that liver metastasis can occur in males with BC. BCLM is a complex process, and therefore it is hoped this case report will improve the understanding of male BCLM and the mechanism of this disease.

Introduction

Breast cancer (BC) is a prevalent malignant disease worldwide that mainly affects women (1). In the US, 30% of all new cancer cases among women are related to BC; in 2021, there were an estimated 281,550 newly diagnosed cases and 43,600 deaths from BC (2). Male BC cases (MBCs) are rare; in the US, they account for <1% of newly identified cases every year (3). Most cases of BC and the creation of new treatment options are directed towards female patients with BC due to the extremely low prevalence of MBC.

According to additional estimates, 3.7 million women in the US had BC in 2018 (4). Patients with early-stage BC that has not metastasized have a 5-year survival rate of >90%; however, once metastatic tumours have formed, the 5-year survival rate decreases to <20% (5), and ~50% of those diagnosed with BC will progress (6).

Although BC can spread to nearly every part of the body, it most commonly metastasizes to the cerebral cortex, liver, lymphatic system and bones (7). Among the most common sites of solid malignant tumour metastases is the liver. Globally, BC liver metastasis (BCLM) therapy is a major concern, and there is no standardized treatment (8). The use of chemotherapy, immunotherapy (for triple-negative disease), radiation, human epidermal growth factor receptor 2 (HER-2)-targeted treatment, endocrine therapy and palliative therapy are among the therapeutic options (9).

The present case report, a 55-year-old male patient diagnosed with BCLM 5 years after BC surgery is described. The present study aimed to assess the details of this MBC case and the possible underlying mechanism. Through this case, we hope to improve clinical understanding of BCLM and clinical experience and treatment.

Case report

A 55-year-old male patient presented to Xuanc Xuancheng Hospital Affiliated to Wannan Medical College (Xuancheng, China) in September 2023 and complained of fever, sputum and pressure in the chest for >10 days while coughing. The patient was administered postoperative routine chemotherapy (doxorubicin hydrochloride, cyclophosphamide, Docetaxel) after BC surgery 5 years ago. After BC surgery, the patient underwent breast examination every year. The patient had no history of any other significant illnesses. Upon examination, the right chest auscultation breath sound was quiet, and the percussion sound was loud. Besides the chest scars from the breast surgery, there were no other notable physical examination results.

After patient admission, the CEA levels were examined, which were elevated (9.34 μg/l; reference value, 0-0.5 μg/l). The other laboratory indicators showed no clinically significant abnormalities. Chest CT scans revealed that the right pleural effusion with expansion of the right lower lobe of the lung was not complete, the upper abdominal enhanced CT-visible liver density was not uniform and the liver had

Correspondence to: Dr Hua Xie, Department of Oncology, Xuancheng Hospital Affiliated to Wannan Medical College, 15 Huancheng North Road, Xuanzhou, Xuancheng, Anhui 242000, P.R. China
E-mail: xiehuaflewer@126.com

Key words: liver metastasis, breast cancer, breast cancer liver metastasis, metastases, case report

a mass (Fig. 1); therefore, further examination was recommended. Bone and CT scans of the abdomen demonstrated no notable abnormality.

A coarse needle biopsy of the liver masses was carried out under ultrasound guidance. Microscopically, invasive tumour cells in the stroma were detected by haematoxylin-eosin staining (Fig. 2). For 48 h, 4% formalin-fixed at 4°C. Deparaffinization and a 10-min wash with Xylene (Sigma-Aldrich; Merck KGaA). A two-minute wash cycle was performed on 100% ethanol (AppliChem, Darmstadt), 100, 97, 70% ethanol, and dH2O. Staining was performed for an hour at room temperature using hematoxylin solution. Sections were so washed for five minutes under running tap water. The slides were then rinsed with water after being incubated with eosin for one minute at room temperature. Digital images were captured by a light microscope and analysed by Axio Vision Rel 4.8 software (softadvice.informer.com/Axiovision_Rel_4.8_Software).

IHC staining was used to determine the amount and the localization of the target proteins 5 μm paraffin-embedded sections were deparaffinized, rehydrated and then immersed in citrate buffer (pH 6.0) in a steam cooker. Subsequently, endogenous peroxidases were blocked via immersing slides in 30% (H_2O_2) for 10 min. Next, 2.5% Goat Serum (Sigma, Steinheim, 12352203) was utilized to block nonspecific binding 30 min at room temperatures. All the marker antibodies E-cadherin (Sigma-Aldrich; Merck KGaA; cat. no. 12352202), GATA-3 (Abcam, ab268065), ER (Sigma, Steinheim, 51111800), PR (Sigma, Steinheim, 12352203), HER-2 (Abcam, ab219208) and CK7 (Sigma, Steinheim, 12352203) were diluted 1:200 in blocking solution and applied onto the surface of tissue sections overnight at 4°C in a humidified chamber. Following washing with PBST (PBS, 0.05% Tween 20) [slides were incubated with horseradish peroxidase (HRP)-linked secondary antibodies (Sigma, Steinheim, 32160702) for 2 h at room temperature. DAB, Sigma, Steinheim, 12352200] detection kit was used to stain HRP and nuclei were counterstained with Mayer's haematoxylin. Lastly, all stained slides were dehydrated through an increasing ethanol concentration for 2 min each and images were acquired using AxioVision 4.9 (Zeiss), and quantification of targeted signals was performed by ImageJ (NIH). Upon immunohistochemical examination of the liver biopsies, it was determined that the patient was positive for E-cadherin, GATA-3, ER, PR, HER-2 and CK7 (Fig. 3). The pathological and immunohistochemical results suggested that the patient had BCLM.

Following diagnosis, letrozole (2.5 mg oral administration, once/day) combined with palbociclib (125 mg oral administration, once a day) was administered orally for 3 weeks and discontinued for 1 week. Letrozole combined with percept treatment, not immunotherapy, is a recommended endocrine therapy for BC. Although the necessity of adjuvant endocrine therapy was repeatedly explained to the patient, the patient refused endocrine adjuvant therapy for economic reasons. The patient was then treated with standardized chemotherapy (Taxotere, 175 mg/m^2 combined with cyclophosphamide 600 mg/m^2 every 2 weeks for 6 cycles of treatment.) and the tumour index, liver function and routine blood tests were checked every month. The patient was followed up for six months. At the most recent follow-up, the condition was stable with no significant discomfort.

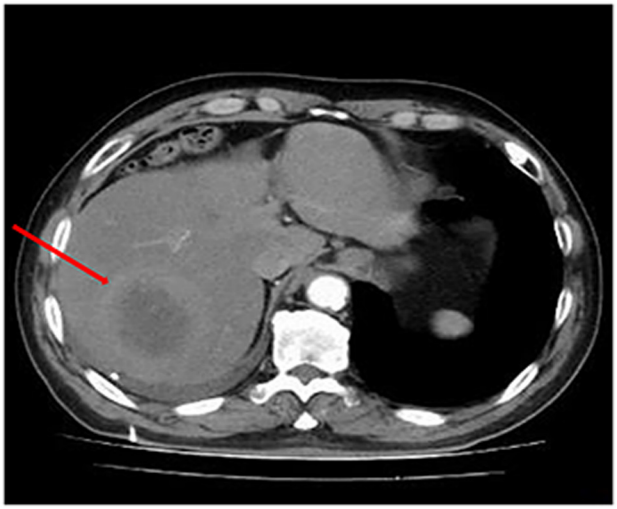

Figure 1. Results of the upper abdominal enhanced computed tomography examination in the patient following admission. Standing lesions can be observed on the liver (arrow).

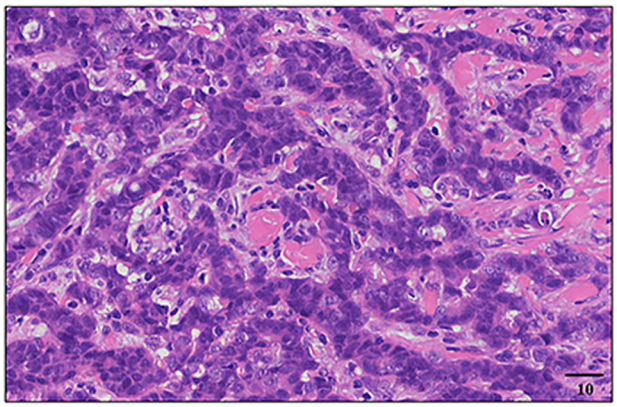

Figure 2. Haematoxylin-eosin staining results of the coarse needle liver biopsy. Microscopically, tumour cells formed invasively in the stroma (magnification, x10).

Discussion

The only cancer that affects women more frequently than BC is non-melanoma skin cancer (10). BC remains the leading contributor to cancer-related death worldwide for women and is the second-highest contributor to cancer-related death among women in the USA. Patients with metastatic disease have a shorter survival period (3). BC accounts for >1% of all male cancers and 1% of all cases of breast carcinoma, making it an uncommon disease (6).

Advanced age, sex, premature menarche, late menopause, nulliparity, no history of breastfeeding, family history of BC, hormone treatment and previous experience with chest radiation treatment may be risk factors associated with BC (11). However, certain men who develop BC do not have any known risk factors. Genetic factors, affecting ~1 per 1000 men, pose the greatest risk for developing MBC (12). A family history of

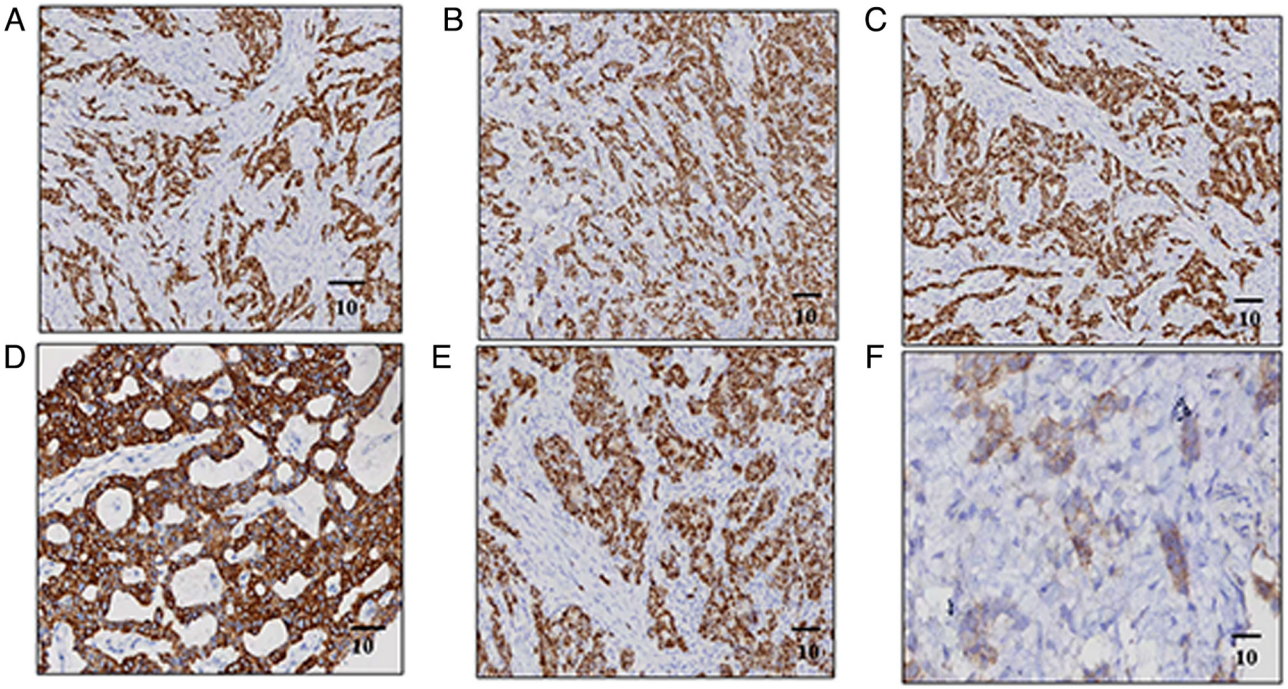

Figure 3. Pathological immunohistochemical examination results of the coarse needle liver biopsy. (A) oestrogen receptor, (B) progesterone receptor, (C) GATA binding protein 3, (D) CK7, (E) E-Cadherin and (F) human epidermal growth factor receptor 2 (magnification, x10).

BC is associated with a relative risk of 2.5% in male patients. Moreover, 20% of all men who have any type of cancer have a family history of BC (13).

In the present study, the case of a 55-year-old male patient with BCLM was reported. The patient underwent breast tumour surgery 5 years prior to presenting with new symptoms. After treatment, the patient was actively followed up regularly. Upon recent admission, a CT examination of the patient revealed a mass on the liver. A biopsy is necessary for confirming the accurate identification of any suspected mass, and the Her2-neu, PR and ER status should be examined. Laboratory evaluation, chest radiography, bone scans and CT scans of the abdomen and pelvis were performed as clinically appropriate. However, core biopsy is preferred as it enables a definitive diagnosis. As determined using microscopy, the tumour cells formed invasively in the stroma. MBCs typically express ER, PR and HER-2 (14). The patient in the present report tested positive for these biomarkers, and the E-cadherin positive result indicated that the type of cancer was ductal carcinoma. Additionally, the GATA-3 positive result indicated that the tumour was breast-derived, and the CK7 positive result indicated adenocarcinoma. Liver pathological examination suggested liver metastasis of BC.

One of the most common sites of solid malignant tumour metastases is the liver (15). After undergoing epithelial-to-mesenchymal transition, BC cells separate from the original tumour and enter the bloodstream by breaking through endothelial barriers (16). The hepatic microenvironment is pivotal for the invasion and proliferation of metastatic BC cells and thus for the formation of BCLMs (17). Xie *et al* (18) suggested that M1 to M2 repolarization of tumour-associated macrophages can prevent immunogenic and inflammatory responses while inducing neoangiogenesis and matrix remodelling, promoting BC progression and metastasis (18,19). Ingber *et al* (20) suggested that the relationship between resident cell types and BC cells is crucial for the regulation of the highly controlled hepatic milieu. Interactions between cancer stem cells and liver microenvironment cells promote metastasis. Additionally, the hepatic environment and stem cells from cancer can alter to promote metastasis (21). Liver sinusoidal endothelial cells serve as the first barrier that breast tumour cells encounter when they enter the liver microcirculation. Kupffer cells (KCs) can produce adhesion molecules, release proinflammatory cytokines and facilitate the extravasation of tumour cells into the hepatic parenchyma (22). In hepatocytes, tumour metastasis is inhibited and promoted in part by liver macrophages, KCs, stellate cells from the liver, myeloid-derived suppressive cells, regulatory T cells and neutrophils (23). In the present case, the patient underwent regular follow-up examinations and treatment for BC 5 years after surgery. The patient then presented with a liver tumour that was pathologically derived from the breast; therefore, considering the possible causes of the development of the tumour microenvironment, which may manifest 5 years after BC surgery, the development of a tumour microenvironment is the possible mechanism of tumour formation. However, more cases may be needed to confirm this.

The prognosis of female and male patients with BC is similar when treated via the same approach (24). BC in men is often diagnosed by histological criteria. Multimodal therapy involving chemotherapy, radiation and surgery has improved the long-term survival and the control of local disease in patients with MBC. In the present case, the patient underwent breast tumour surgery 5 years ago and refused further surgical treatment Hence, immunotherapy was administered as a neoadjuvant agent. Genetic testing of the BRCA gene has a notable

role in the diagnosis of BC. BRCA status is of great importance for the maintenance treatment of patients, especially high-risk patients. Therefore, patients should be recommended to undergo BRCA gene testing during subsequent treatment, however, the present patient was not tested due to economic reasons. In the present case, the patient declined genetic testing and was treated with letrozole combined with percept was administered orally for 3 weeks and then discontinued for 1 week. Because of the patient's ER, the PR was positive, thus, this therapy is a good option for treating BCLM in men.

In conclusion, liver metastasis in patients with BC is a multistep and multifactor process. The development of the premetastatic microenvironment, migration and metastasis centres in the liver are the three key stages of the BC metastatic pathway. Clinical symptoms, imaging and histology are typically used to diagnose BCLM. Surgical resection is the primary treatment, but it can also be paired with radiation therapy and chemotherapy.

Acknowledgements

Not applicable.

Funding

The present study was supported by the Anhui Province clinical medical research and transformation special project (grant no. 202304295107020071) and the Bethune Medical Research Fund (grant no. B19059ET).

Availability of data and materials

The data generated in the present study may be requested from the corresponding author.

Authors' contributions

MJ conceptualised and designed the study and drafted the manuscript. MJ, LL, HL and HX were involved in the patient treatment and confirm the authenticity of all the raw data. All authors read and approved the final version of the manuscript.

Ethics approval and consent to participate

Not applicable.

Patient consent for publication

Written informed consent was obtained from the patient for the publication of this case report and any accompanying images.

Competing interests

The authors declare that they have no competing interests.

References

1. Diaby V, Tawk R, Sanogo V, Xiao H and Montero AJ: A review of systematic reviews of the cost-effectiveness of hormone therapy, chemotherapy, and targeted therapy for breast cancer. Breast Cancer Res Treat 151: 27-40, 2015.
2. Tarver T: Breast cancer facts & figures 2021. American Cancer Society, Atlanta, GA, 2021.
3. Siegel RL, Miller KD, Fuchs HE and Jemal A: Cancer statistics, 2021. CA Cancer J Clin 71: 7-33, 2021.
4. National Cancer Institute. Cancer Stat Facts: Female Breast Cancer; National Cancer Institute: Bethesda, MD, USA, 2020.
5. Atalay G, Biganzoli L, Renard F, Paridaens R, Cufer T, Coleman R, Calvert AH, Gamucci T, Minisini A, Therasse P, *et al*: Clinical outcome of breast cancer patients with liver metastases alone in the anthracycline-taxane era: A retrospective analysis of two prospective, randomised metastatic breast cancer trials. Eur J Cancer 39: 2439-2449, 2003.
6. Torre LA, Bray F, Siegel RL, Ferlay J, Lortet-Tieulent J and Jemal A: Global cancer statistics, 2012. CA Cancer J Clin 65: 87-108, 2015.
7. Eckhardt BL, Francis PA, Parker BS and Anderson RL: Strategies for the discovery and development of therapies for metastatic breast cancer. Nat Rev Drug Discov 11: 479-497, 2012.
8. Alcantara SB, Reed W, Willis K, Lee W, Brennan P and Lewis S: Radiologist participation in multi-disciplinary teams in breast cancer improves reflective practice, decision making and isolation. Eur J Cancer Care (Engl) 23: 616-623, 2014.
9. Hortobagyi GN: Trastuzumab in the treatment of breast cancer. N Engl J Med 353: 1734-1736, 2005.
10. Trayes KP and Cokenakes SEH: Breast cancer treatment. Am Fam Physician 104: 171-178, 2021.
11. Loibl S, Poortmans P, Morrow M, Denkert C and Curigliano G: Breast cancer. Lancet 397: 1750-1769, 2021.
12. Giordano SH, Buzdar AU and Hortobagyi GN: Breast cancer in men. Ann Intern Med 137: 678-687, 2002.
13. Anderson WF, Jatoi I, Tse J and Rosenberg PS: Male breast cancer: A population-based comparison with female breast cancer. J Clin Oncol 28: 232-239, 2010.
14. Bartmann C, Wischnewsky M, Stüber T, Stein R, Krockenberger M, Häusler S, Janni W, Kreienberg R, Blettner M, Schwentner L, *et al*: Pattern of metastatic spread and subcategories of breast cancer. Arch Gynecol Obstet 295: 211-223, 2017.
15. Battistoni A, Lantier L, di Tommaso A, Ducournau C, Lajoie L, Samimi M, Coënon L, Rivière C, Epardaud M, Hertereau L, *et al*: Nasal administration of recombinant Neospora caninum secreting IL-15/IL-15Rα inhibits metastatic melanoma development in lung. J Immunother Cancer 11: e006683, 2023.
16. Nieto MA: Epithelial plasticity: A common theme in embryonic and cancer cells. Science 342: 1234850, 2013.
17. Ma R, Feng Y, Lin S, Chen J, Lin H, Liang X, Zheng H and Cai X: Mechanisms involved in breast cancer liver metastasis. J Transl Med 13: 64, 2015.
18. Xie L, Yang Y, Meng J, Wen T, Liu J and Xu H: Cationic polysaccharide spermine-pullulan drives tumor associated macrophage towards M1 phenotype to inhibit tumor progression. Int J Biol Macromol 123: 1012-1019, 2019.
19. Liu C, Mohan SC, Wei J, Seki E, Liu M, Basho R, Giuliano AE, Zhao Y and Cui X: Breast cancer liver metastasis: Pathogenesis and clinical implications. Front Oncol 12: 104377, 2022.
20. Ingber DE: Can cancer be reversed by engineering the tumour microenvironment? Semin Cancer Biol 18: 356-364, 2008.
21. Lau EY, Ho NP and Lee TK: Cancer stem cells and their microenvironment: Biology and therapeutic implications. Stem Cells Int 2017: 3714190, 2017.
22. Osborne N, Sundseth R, Gay MD, Cao H, Tucker RD, Nadella S, Wang S, Liu X, Kroemer A, Sutton L, *et al*: Vaccine against gastrin, a polyclonal antibody stimulator, decreases pancreatic cancer metastases. Am J Physiol Gastrointest Liver Physio 317: G682-G693, 2019.
23. Gucalp A, Traina TA, Eisner JR, Parker JS, Selitsky SR, Park BH, Elias AD, Baskin-Bey ES and Cardoso F: Male breast cancer: A disease distinct from female breast cancer. Breast Cancer Res Treat 173: 37-48, 2019.
24. Ou J, Peng Y, Deng J, Miao H, Zhou J, Zha L, Zhou R, Yu L, Shi H and Liang H: Endothelial cell-derived fibronectin extra domain A promotes colorectal cancer metastasis via inducing epithelial-mesenchymal transition. Carcinogenesis 35: 1661-1670, 2014.

Copyright © 2024 Jiang et al. This work is licensed under a Creative Commons Attribution-NonCommercial-NoDerivatives 4.0 International (CC BY-NC-ND 4.0) License.