

Octreotide acetate enables the administration of chemoradiotherapy, including the oral anticancer drug S-1, in gastric cancer patients with malignant gastrointestinal obstruction

TSUNEHIRO TAKAHASHI¹, YOSHIRO SAIKAWA², TAKAHIRO IGARASHI², SHINICHI TSUWANO², KOSHI KUMAGAI², RIEKO NAKAMURA², TAKASHI OOOYAMA², NORIHITO WADA², HIROYA TAKEUCHI², HIROMASA TAKAISHI¹ and YUKO KITAGAWA²

¹Keio Cancer Center, Keio University Hospital; ²Department of Surgery, School of Medicine, Keio University, Tokyo 160-8582, Japan

Received March 9, 2010; Accepted May 17, 2010

DOI: 10.3892/ol_00000118

Abstract. Advanced gastric cancer frequently results in the inability to ingest food or drink orally, a condition called malignant gastrointestinal obstruction (MGO). MGO is clinically defined as a gastrointestinal outlet obstruction caused by a large tumor, or malignant bowel obstruction with peritoneal dissemination. MGO impacts the quality of life by interfering with oral intake and by causing gastrointestinal symptoms, such as nausea, vomiting and abdominal pain. Octreotide acetate (OA) is an analogue of somatostatin which has been increasingly used to relieve gastrointestinal symptoms since it decreases the secretion of digestive juices and increases the absorption of water and electrolytes. In Japan, the oral anticancer drug S-1 was recently adopted as a key chemotherapeutic agent in advanced gastric cancer; however, its oral formulation precludes its utility in the MGO setting. This is a pilot study of chemoradiotherapy plus OA in gastric cancer with MGO. Patients were initially treated with OA to control gastrointestinal symptoms. Following resolution of their symptoms, the patients received chemotherapy with S-1 plus low-dose cisplatin and radiation. Irradiation was targeted at the primary tumor and surrounding lesions, including the lymph nodes. Grade 4 toxicity was observed in only 1 patient, and no treatment-related deaths were noted. After treatment, 3 patients achieved a partial response and 4 achieved stable disease. Of the 9 patients, 8 were able to tolerate solid food orally and were discharged. The outcomes of these cases suggest that OA is a useful adjunctive therapy

that enables advanced gastric cancer patients with MGO to receive S-1-containing chemotherapy.

Introduction

Advanced gastric cancer often results in the inability to ingest food or drink orally, a condition called malignant gastrointestinal obstruction (MGO). MGO is clinically defined as a gastrointestinal outlet obstruction (GOO) caused by a large tumor, or malignant bowel obstruction (MBO) with peritoneal dissemination (Fig. 1). MGO impacts the quality of life (QOL) of patients by precluding oral intake and by causing gastrointestinal symptoms, such as nausea, vomiting and abdominal pain.

MGO is a common clinical complication in patients with advanced abdominal malignancy, due to either a large primary tumor or intestinal involvement with peritoneal carcinomatosis. As previously mentioned, bowel obstruction negatively impacts QOL to a great extent by impeding oral intake and inducing gastrointestinal symptoms. Thus, the management of patients with MGO is a significant issue for oncologists. Due to the poor general condition of patients with MGO, surgical treatment, including bypass procedures, is generally not recommended. Furthermore, the placement of a nasogastric tube (NGT) to drain digestive secretions and other fluids does not always result in symptom resolution or QOL improvement in these patients due to the stress associated with NGT placement.

Previous reports demonstrated the efficacy of pharmacologic therapy consisting of analgetics, antiemetics and antisecretory drugs for patients with MGO (1). Octreotide acetate (OA) is an analogue of somatostatin that is increasingly used to relieve gastrointestinal symptoms in patients with MGO (1-6). By means of complex endocrine mechanisms, OA affects gastrointestinal function by reducing gastric and intestinal secretion and bile flow (7).

Orally administered S-1, currently the most effective chemotherapeutic agent for gastric cancer in Japan, cannot

Correspondence to: Dr Yoshiro Saikawa, Department of Surgery, School of Medicine, Keio University, 35 Shinanomachi, Shinjuku-ku, Tokyo 160-8582, Japan
E-mail: saiky@sc.itc.keio.ac.jp

Key words: gastric cancer, malignant gastrointestinal obstruction, chemoradiotherapy, S-1, octreotide acetate

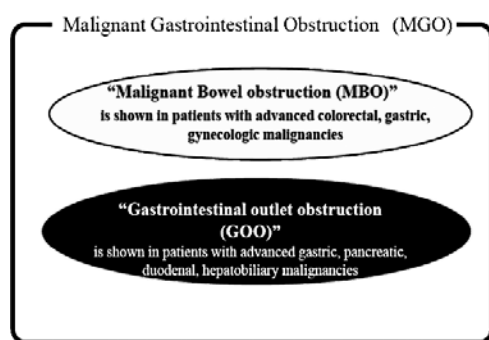


Figure 1. Definition of malignant bowel obstruction (MBO).

be used in patients with bowel obstruction (8-11). Previously the authors of this study reported on a patient with highly advanced gastric cancer with MBO, who was successfully treated with combination chemoradiotherapy, including S-1 and OA (12). The inclusion of OA in this regimen enabled the patient to tolerate oral S-1 chemotherapy.

This is a pilot study of advanced gastric cancer cases with MGO successfully treated with combination chemoradiotherapy that included S-1. Given the seriousness of MGO, the success of the OA-containing treatment regimen is noteworthy.

Materials and methods

Chemoradiotherapy using S-1 and cisplatin. The chemoradiotherapy regimen consisted of S-1 (Taiho Pharmaceutical Co., Ltd, Tokyo, Japan) and cisplatin (CDDP; Randa®, Nihon Kayaku Co., Ltd., Tokyo, Japan). S-1 was administered orally at a dose of 80 mg/m²/day on Days 1-21, while CDDP was infused at a dose of 6 mg/m²/day for 1 h on Days 1-5, 8-12 and 15-19. Radiation therapy (5 days/week) at 2 Gy/day was started concurrently with chemotherapy and was repeated hourly on Days 1-5, 8-12, 15-19 and 22-26. Irradiation was planned using a computed tomography (CT) simulator for two rectangular portals (anterior and left lateral) with a pair of 45°-wedge

filters, and was targeted at the primary tumor and surrounding lesions, including the lymph nodes. The study was approved by the ethics committee of our hospital, and all patients gave written informed consent.

Patient characteristics. Table I shows the clinicopathological findings of the patients. Gastric cancer staging and the effects of chemoradiotherapy were evaluated according to the criteria of the Japanese Research Society for Gastric Cancer (13). The mean age of the patients was 57 years (range 19-71) and there were 7 males and 2 females. All 24 patients complained of appetite loss and nausea caused by MGO. Due to the progression of peritoneal dissemination, 2 of 9 patients received chemoradiotherapy after non-curative resection due to positive lavage cytology (CY1). Only 1 patient had recurrence with peritoneal dissemination following curative surgical resection, and that patient received chemoradiotherapy 9 months after surgery. The analysis of the clinical response showed that partial response (PR) or stable disease (SD) was observed in 3 and 4 patients, respectively. Of a total of 9 patients, 8 were able to resume oral liquid or solid diet intake and were discharged from the hospital. The median duration of OA (Sandostatin®; Novartis Pharma K.K., Tokyo, Japan) treatment and hospital stay was 28 days (range 7-70) and 55 days (range 44-100), respectively. The patients continued to receive outpatient combination chemotherapy consisting of S-1 and CDDP, or other drugs. Grade 4 leukocytopenia was observed in only 1 patient and grade 3 toxicities of leukocytopenia, thrombocytopenia and anemia were observed in 3, 1 and 2 patients, respectively. No grade 3 or higher non-hematological toxicity was observed. The median survival time was 305 days.

Case reports

Case 1. A 55-year-old male presented at our hospital with vomiting and abdominal distension. A gastrointestinal endoscopy showed advanced gastric cancer with pyloric stenosis, while an abdominal CT revealed lymph node metastases, including nodes in the para-aortic region and multiple nodules plus ascites in the pelvic cavity (Fig. 2A and B). The clinical

Table I. Patient characteristics.

Case	Age/gender	Location	Stage	Hospital stay (days)	Clinical response (months)	Survival time
1	68/F	LD	T4N1H0P1M0, stage IV	47	SD	10, deceased
2	55/M	LD	T3N3H0P1M1, stage IV	40	PR	21, alive
3	58/M	UM	T4N3H0P1M0, stage IV	55	PR	10, deceased
4	70/M	MUL	T3N2H0P1M1, stage IV	42	SD	3, deceased
5	70/M	UE, LD	T4N0H0P1M0, stage IV	86	PR	11, deceased
6	64/F	LM	T4N2H0P0M0CY1, stage IV	55	PD	2, deceased
7	41/M	UML	T3N3H1P1M1, stage IV	63	PD	3, deceased
8	71/M	UML	T3N1H0P0M0CY1, stage IV	39	SD	17, alive
9	19/M	L	rec (T2N0H0P0M0CY0, stage IB)	100	SD	8, deceased

U, upper part of stomach; M, middle part of stomach; L, lower part of stomach; E, esophagus and D, duodenum. CY1, positive lavage cytology; rec, recurrence after surgery; SD, stable disease; PR, partial response; PD, progressive disease.

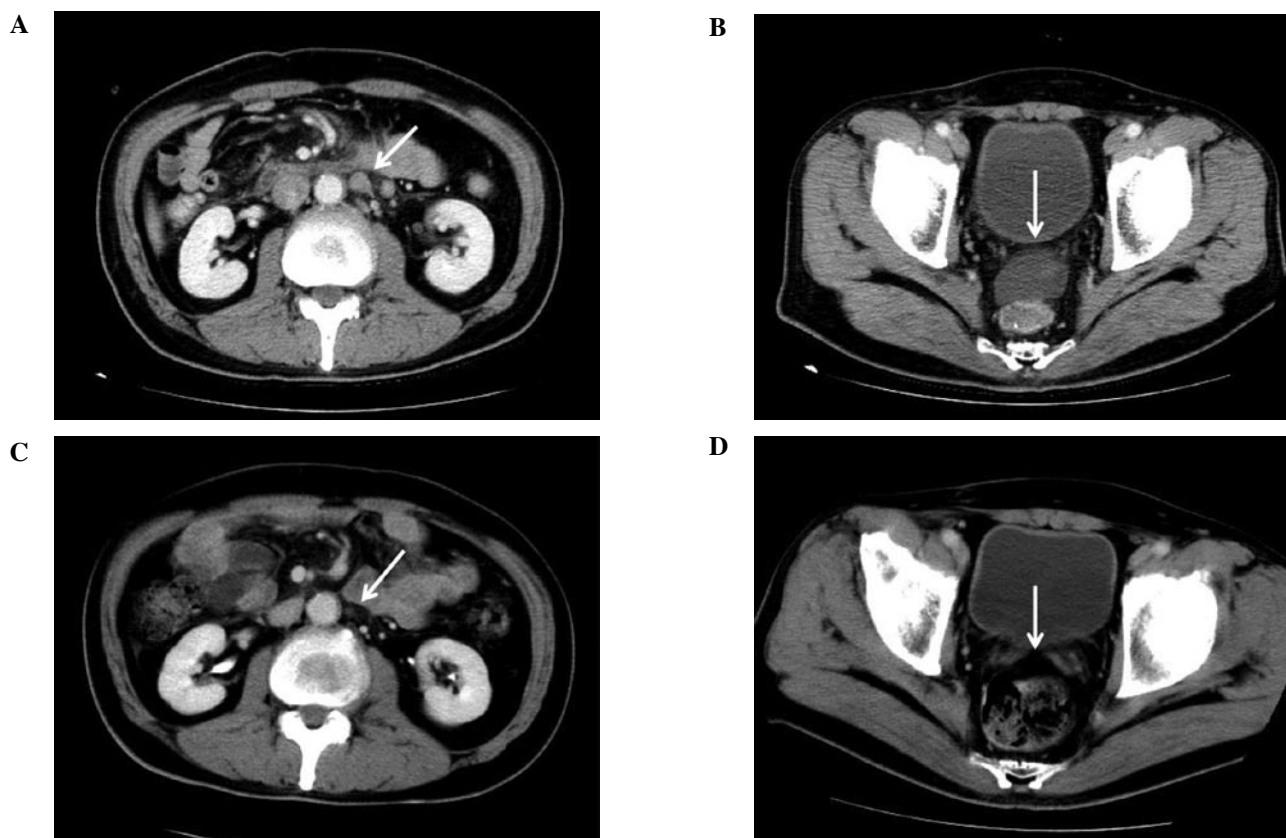


Figure 2. (A) Abdominal CT showed multiple lymph nodes metastases including a para-aortic region indicated by the white arrow. (B) A small amount of ascites was present in the pelvic cavity. (C) After chemoradiotherapy, the lymph nodes showed downsizing. Clinical efficacy was evaluated as PR. (D) Ascites disappeared after chemoradiotherapy.

diagnosis, according to the Japanese classification of gastric carcinoma (13), was stage IV (cT3, cN3, cH0, cP1, cM1) gastric cancer. Due to severe gastrointestinal symptoms caused by pyloric stenosis and peritoneal dissemination, the patient was treated with OA intravenously at 300 $\mu\text{g}/\text{day}$ to decrease bowel secretions.

After the improvement of the bowel obstruction symptoms, the patient was able to resume the intake of water 1 day after starting treatment with OA. After OA treatment resulted in sufficient oral intake, chemoradiotherapy with S-1 and CDDP commenced. Although Grade 3 leukopenia developed, it improved following the administration of granulocyte colony-stimulating factor (G-CSF). An abdominal CT following the last chemoradiotherapy cycle revealed that the ascites had almost completely disappeared and that the metastatic lymph nodes showed a reduction in size (Fig. 2C and D). The clinical response of the patient was determined to be PR. He was able to resume oral intake and was discharged 6 weeks after admission.

In a follow-up, 17 months after the initiation of treatment, the patient's peritoneal dissemination progressed. However, he remains on outpatient chemotherapy.

Case 2. A 58-year-old male with nausea and lower back pain was admitted to our hospital for further evaluation. Gastrointestinal endoscopy showed a type 3 tumor located on the upper and middle parts of the stomach. Abdominal CT revealed multiple lymph node metastases, peritoneal nodules plus ascites

and a large primary tumor (Fig. 3A and B). Hydronephrosis and acute renal dysfunction caused by the large tumor extending into the retroperitoneum resulted in a urinary tract stent being inserted prior to chemotherapy. In addition, to relieve gastrointestinal symptoms, the patient was treated with OA intravenously at a dose of 300 $\mu\text{g}/\text{day}$ to decrease bowel secretions.

Following improvement of the bowel obstruction symptoms, chemotherapy with half-dose S-1 (50 mg/body/day) was initiated 2 days after starting treatment with OA. The patient's renal dysfunction gradually improved. Subsequently, the S-1 dose was increased to a standard dose (100 mg/body/day), and low-dose CDDP and radiation were included. Grade 3 leukopenia developed, which resolved following G-CSF administration. An abdominal CT following the last chemoradiotherapy cycle revealed that the ascites had almost completely disappeared, and the tumor had decreased in size (Fig. 3C and D). The patient's clinical response was determined to be PR. He was able to resume oral intake and was discharged 8 weeks after admission.

An outpatient chemotherapy regimen was administered consisting of S-1 and biweekly CDDP. However, the patient succumbed to the disease 10 months after the initiation of therapy due to progression of the peritoneal dissemination.

Discussion

MBO is defined as a clinical syndrome in which a patient has obstructive symptoms due to the presence of carcino-

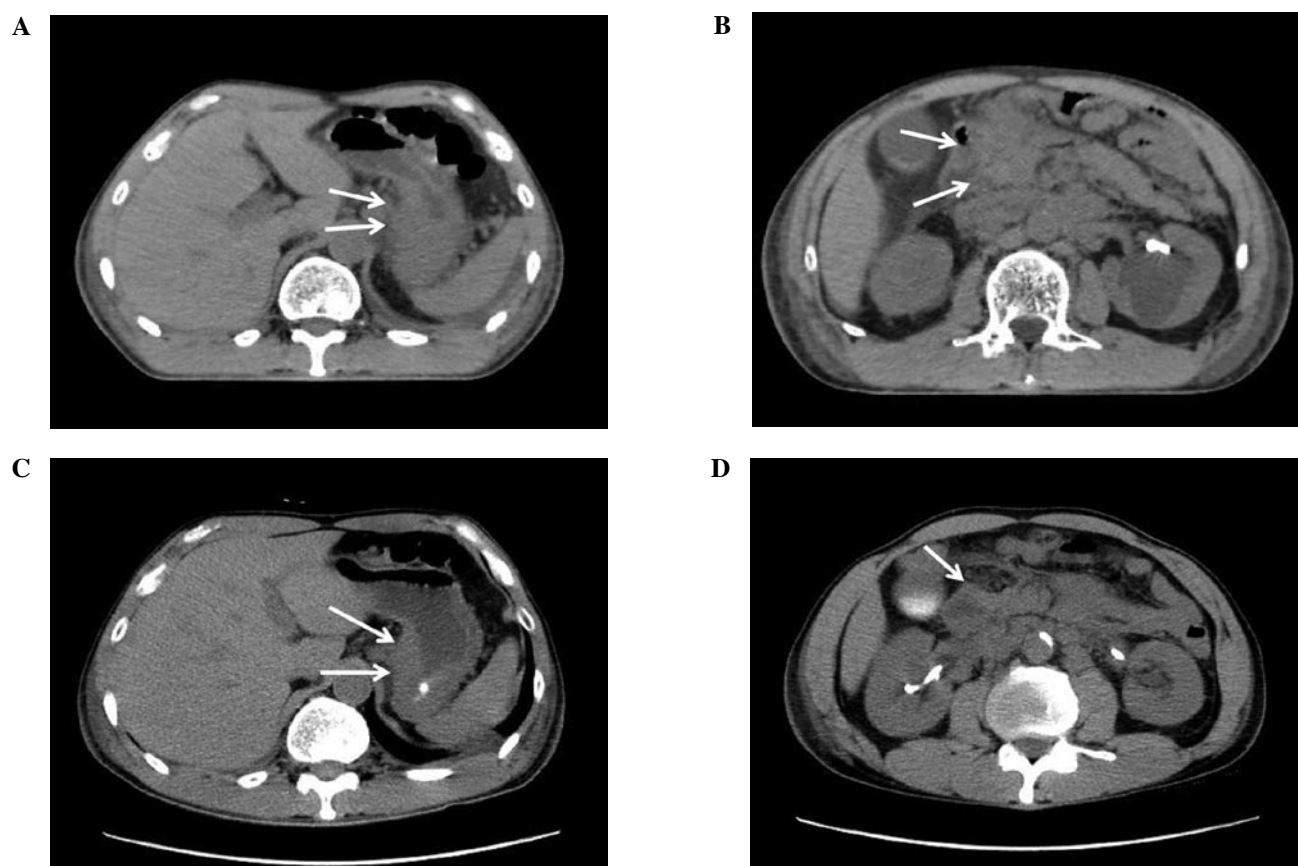


Figure 3. (A) Abdominal CT prior to chemoradiotherapy shows the wall thickness of the stomach. (B) A large tumor comprising a primary lesion, as well as regional lymph nodes are shown. (C) After chemoradiotherapy, the wall thickness of the stomach improved. (D) The size of the large tumor decreased. The clinical response was evaluated as PR.

matosis associated with abdominal or pelvic malignancy. Gastrointestinal symptoms are caused by an increase in the distension-secretion-motor activity of the obstructed bowel (14). As the luminal contents accumulate proximal to the obstruction, the bowel becomes distended, and the increase in intraluminal pressure stimulates intestinal fluid secretion, stretching the bowel wall even further. In addition, upper abdominal cancer, such as advanced gastric, pancreatic, duodenal and gallbladder cancer, may produce GOO. Both MBO and GOO are identified as MGO (Fig. 1).

Patients with MGO are usually not eligible for surgery since they present with multiple sites of obstruction and are generally in poor health. These patients cannot be managed adequately by conventional antiemetics, and NGT placement is often the only treatment option for such inoperable patients. While NGT placement may result in symptomatic relief in some patients with MGO, common complications occur, including mucosal erosion and hemorrhage, esophagitis and aspiration pneumonia.

The somatostatin analogue OA modulates gastrointestinal function by reducing gastric acid secretion, slowing intestinal motility, decreasing bile flow, increasing mucous production and decreasing splanchnic blood flow (15). The inhibitory effects of OA cause decreased water and sodium secretion by the intestinal epithelium, thereby reducing bowel distension. Previous reports showed that the relief of gastrointestinal

symptoms by OA contributes to the improvement of QOL in patients with MGO (3-6).

S-1 is an oral anticancer drug that combines tegafur, a prodrug of 5-fluorouracil (5FU), with 5-chloro-2,4-dihydropyrimidine (CDHP) and potassium oxonate. S-1 has several advantages, including its high efficacy, excellent tolerability, low side-effect profile and the convenience of outpatient administration (8,9). The Japan Clinical Oncology Group (JCOG) study (JCOG9912) reported that S-1 was well tolerated, with a median survival as long as that of 5FU alone (control treatment) in advanced gastric cancer (11). Therefore, in Japan, S-1 is identified as a first-line agent for treating unresectable, highly advanced gastric cancer. CDDP is another key chemotherapeutic agent used for the treatment of gastric cancer. Combination chemotherapy with CDDP and S-1 results in high efficacy and tolerable toxicity (16-18). In our clinical trial, radiation was added to S-1 combined with low-dose CDDP chemotherapy to achieve additional efficacy in patients with stage IV gastric cancer (19-21). However, the oral formulation of S-1 prevents it from being administered to numerous patients with MGO since they are unable to ingest even small capsules.

The clinical application of OA is somewhat limited in MGO since symptom relief is only temporary. However, for 4 patients described in this study, who were initially unable to take oral S-1 due to MGO, the administration of OA relieved

their bowel obstruction sufficiently to allow them to receive this valuable type of adjunctive therapy. The use of OA enabled these patients to complete an aggressive chemoradiotherapy regimen that included S-1. After chemoradiotherapy plus OA, patient oral intake and QOL substantially improved compared to their pre-treatment status. Consequently, these patients were discharged without any treatment-associated problems or NGT placement. Thus, in gastric cancer patients with MGO, OA appears to be useful for managing gastrointestinal symptoms and enabling patients to receive effective treatment for this disease, resulting in a relatively satisfactory QOL.

References

1. Mercadante S, Ferrera P, Villari P, *et al*: Aggressive pharmacological treatment for reversing malignant bowel obstruction. *J Pain Symptom Manage* 28: 412-416, 2004.
2. Dean A: The palliative effects of octreotide in cancer patients. *Chemotherapy* 47 (Suppl 2): 54-61, 2001.
3. Khoo D, Hall E, Motson R, *et al*: Palliation of malignant intestinal obstruction using octreotide. *Eur J Cancer* 30A: 28-30, 1994.
4. Watanabe H, Inoue Y, Uchida K, *et al*: Octreotide improved the quality of life in a child with malignant bowel obstruction caused by peritoneal dissemination of colon cancer. *J Pediatr Surg* 42: 259-260, 2007.
5. Shima Y, Ohtsu A, Shirao K, *et al*: Clinical efficacy and safety of octreotide (SMS201-995) in terminally ill Japanese cancer patients with malignant bowel obstruction. *Jpn J Clin Oncol* 38: 354-359, 2008.
6. Mercadante S, Spoldi E, Caraceni A, Maddaloni S and Simonetti M: Octreotide in relieving gastrointestinal symptoms due to bowel obstruction. *Palliat Med* 7: 295-299, 1993.
7. Marie TF: The physiology of somatostatin and its synthetic analogue, octreotide. *Eur J Palliative Care* 1: 20-22, 1994.
8. Sugimachi K, Maehara Y, Horikoshi N, *et al*: An early phase II study of oral S-1, a newly developed 5-fluorouracil derivative for advanced and recurrent gastrointestinal cancers. The S-1 Gastrointestinal Cancer Study Group. *Oncology* 57: 202-210, 1999.
9. Koizumi W, Kurihara M, Nakano S and Hasegawa K: Phase II study of S-1, a novel oral derivative of 5-fluorouracil, in advanced gastric cancer. For the S-1 Cooperative Gastric Cancer Study Group. *Oncology* 58: 191-197, 2000.
10. Sakuramoto S, Sasako M, Yamaguchi T, *et al*: Adjuvant chemotherapy for gastric cancer with S-1, an oral fluoropyrimidine. *N Eng J Med* 357: 1810-1820, 2007.
11. Boku N, Yamamoto S, Fukuda H, *et al*: Fluorouracil versus combination of irinotecan plus cisplatin versus S-1 in metastatic gastric cancer: a randomized phase 3 study. *Lancet Oncol* 10: 1063-1069, 2009.
12. Kumagai K, Saikawa Y, Fukuda K, *et al*: Octreotide acetate successfully treated a bowel obstruction caused by peritoneally disseminated gastric cancer, thereby enabling the subsequent use of oral S-1 chemotherapy. *Int J Clin Oncol* 14: 372-375, 2009.
13. Japanese Research Society for Gastric Cancer: Japanese Classification of Gastric Carcinoma. 2nd English edition. Kanehara, Tokyo, 1998.
14. Ripamonti C, Twycross R, Baines M, *et al*: Clinical-practice recommendations for the management of bowel obstruction in patients with end-stage cancer. *Support Care Cancer* 9: 223-233, 2001.
15. Mulvihill SJ, Pappas TN, Fonkalsrud EW and Debas HT: The effect of somatostatin on experimental intestinal obstruction. *Ann Surg* 207: 169-173, 1998.
16. Saikawa Y, Kubota T, Kitajima M, *et al*: Preoperative combination chemotherapy with S-1 and low-dose cisplatin against highly advanced gastric carcinoma. *Oncol Rep* 10: 381-386, 2003.
17. Koizumi W, Tanabe S, Saigenji K, *et al*: Phase I/II study of S-1 combined with cisplatin in patients with advanced gastric cancer. *Br J Cancer* 89: 2207-2212, 2003.
18. Koizumi W, Narahara H, Hara T, *et al*: S-1 plus cisplatin versus S-1 alone for first-line treatment of advanced gastric cancer (SPIRITS trial): a phase III trial. *Lancet Oncol* 9: 215-221, 2008.
19. Takahashi T, Saikawa Y, Kitajima M, *et al*: Histological complete response in a case of advanced gastric cancer treated by chemotherapy with S-1 plus low-dose cisplatin and radiation. *Jpn J Clin Oncol* 33: 584-588, 2003.
20. Saikawa Y, Kubota T, Kitajima M, *et al*: Is chemoradiation effective or harmful for stage IV gastric cancer patients? *Oncol Rep* 13: 865-870, 2005.
21. Saikawa Y, Kubota T, Kumagai K, *et al*: Phase II study of chemoradiotherapy with S-1 and low-dose cisplatin for inoperable advanced gastric cancer. *Int J Radiat Oncol Biol Phys* 71: 173-179, 2008.