ONCOLOGY REPORTS 16: 279-284, 2006

Thymidine phosphorylase expression as a prognostic marker for predicting recurrence in primary superficial bladder cancer

SHIGEYUKI AOKI, YOSHIAKI YAMADA, KOGENTA NAKAMURA
TOMOHIRO TAKI, MOTOI TOBIUME and NOBUAKI HONDA

Department of Urology, Aichi Medical University School of Medicine, Aichi, Japan

Received February 1, 2006; Accepted April 4, 2006

Abstract. No prognostic marker for predicting recurrence in primary superficial bladder cancer has been established. The aim of this study was to investigate the expression levels of thymidine phosphorylase (TP) by enzyme-linked immunosorbent assay (ELISA) and the immunohistological localization of TP in primary superficial bladder cancer tissue to assess its association with tumor recurrence and stage progression as well as the pathological parameters of the tumor. TP expression in cancer tissues from 77 patients was measured by sandwich-type ELISA. Clinicopathological factors and the clinical prognosis were examined in relation to the expression levels of TP. To clarify the clinicopathological implication of TP localization in primary superficial bladder cancer tissue, the immunohistochemically determined TP expression was assessed for histological grades 1-3. The TP expression in primary superficial bladder cancer significantly increased with the histological grade and stage. The TP expression in patients with a shift to invasive cancer was significantly higher than in those without invasive cancer. Patients with low TP expression had a significant longer postoperative tumor-free period than those with high TP expression (P=0.011). High TP expression was an independent prognostic factor for tumor recurrence (P=0.0441). Strong immunoreactivity for TP was observed in the cytoplasms of tumor cells and vascular endothelial cells. This study suggests that elevated TP expression may be a prognostic marker for predicting recurrence in primary superficial bladder cancer, and that high TP expression may be associated with the marked proliferation of tumor cells and increased vascular endothelial cells, showing strong immunoreactivity for TP.

Correspondence to: Dr Shigeyuki Aoki, Department of Urology, Aichi Medical University School of Medicine, 21 Karimata, Nagakute-cho, Aichi-gun, Aichi-ken 480-1195, Japan
E-mail: 105403@gk.amu.aichi-med-u.ac.jp

Key words: thymidine phosphorylase, prognostic marker, tumor recurrence, primary superficial bladder cancer, immunohistochemistry

Introduction

The prognosis for superficial bladder cancer including both stage pTa and pT1 tumors (1) according to the TNM system (2), which accounts for ~75-80% of all bladder cancer (3), is relatively good; however, two serious problems remain. One is the high incidence of recurrence following transurethral resection of the bladder tumor (TUR-Bt) and the other is that some cases show a shift to invasive cancer (stage pT2 or greater). Nevertheless, no prognostic biochemical marker for superficial bladder cancer has been established.

It is well known that malignant tumors depend on a process leading to the formation of new blood vessels (angiogenesis) for their growth and metastasis (4). Recently, it has been shown that platelet-derived endothelial cell growth factor (PD-ECGF) (5) is identical to TP (6,7), an enzyme involved in pyrimidine nucleoside metabolism. TP expression has been reported to be increased in various forms of malignant tumors compared with adjacent normal tissue (8,9). Concerning superficial bladder cancer, there are only a few reports on TP and the prognostic significance of this enzyme in superficial bladder cancer has not yet been thoroughly clarified.

In this study, TP expression levels were measured by ELISA in primary superficial bladder cancer tissue obtained surgically, and the correlation between the level of TP expression and tumor recurrence, and pathological parameters such as the grade, stage, multiplicity, tumor size, tumor shape, and shift to invasive cancer was examined statistically. In addition, to identify the clinicopathological implication of TP localization in primary superficial bladder cancer tissue, the immunohistochemically determined TP expression was assessed for histological grades 1-3.

Materials and methods

Patients. Tumor tissue was obtained from 77 patients with primary superficial bladder cancer. All patients underwent TUR-Bt alone at the Department of Urology, Aichi Medical University Hospital between May 1999 and November 2004. The study was approved by the local ethics committee and all experiments were performed after obtaining informed consent from patients according to institutional rules. The vivid portion of the resected tumor was immediately divided into two samples: one was embedded in optimum cutting tissue medium, snap frozen in liquid nitrogen, and stored at

Table I. Patient characteristics.

Patient no.	77
Age (years)	38-89 (65.4±10.9)
Sex (cases)	
Male	59
Female	18
Follow-up period (months)	36.4±12.4
Multiplicity	
Solitary	34
Multiple	43
Tumor grade	
G1+G2	64
G3	13
Tumor stage	
pTa	56
pT1	21
Tumor size	
<3 cm	53
≥3 cm	24
Tumor shape	
Pedunculated tumor	48
Sessile tumor	29
Recurrence	
No	48
Yes	29
Progression	
No	71
Yes	6

-80˚C, and the other was sent to the Pathology Division, Aichi Medical University Hospital for histological diagnosis. The histological grade and stage were classified according to the criteria of the Japanese Urological Association (1) and the TNM system (2). Table I shows the age, sex, follow-up period and clinicopathological findings, including recurrence and progression, of the 77 patients.

ELISA assay for TP. The frozen samples were thawed and homogenized in a 10-fold volume of 10 mM Tris-HCl buffer (pH 7.4) containing 15 mM NaCl, 1.5 mM $MgCl_2$ and 50 mM potassium phosphate with a glass homogenizer. The homogenates were then centrifuged at 10,000 x g for 15 min at 4˚C, and supernatants were used for ELISA assays. The protein concentration of the supernatant extracted from tumor tissue was determined with a DC Protein Assay Kit (Bio-Rad Laboratories, Hercules, CA, USA).

TP levels were measured by a sandwich-type ELISA assay with monoclonal antibodies (MoAbs) against human TP (10,11). In brief, a 96-well microtiter plate (Nunc-immunoplate Maxisorp, Nunc, Roskilde, Denmark) was incubated at 4˚C overnight with 10 μg/ml of the first MoAb 104B for TP in 10 mM phosphate-buffered saline (PBS pH 7.6). The plate coated with the antibody was then incubated with 3% (w/v) skim-milk in PBS (blocking buffer) for 1 h at room temperature, and washed with PBS containing 0.05% Tween-20 (washing buffer). Test samples and serially diluted standard solutions of TP were dispensed onto the antibody-coated plate, and incubated for 1 h at 37˚C. After washing, the plate was incubated with 1 μg/ml of the second MoAb 232-2 for TP in blocking buffer for 1 h at 37˚C. The plate was washed and incubated with 2,000-fold-diluted third antibody to MoAb 232-2 conjugated with horseradish peroxidase (Kirkegaad & Perry Laboratories, Inc. Gaithersburg, MD, USA) for 30 min at 37˚C. It was then washed again and incubated with a substrate solution containing 3,3',5,5'-tetramethyl-benzidine

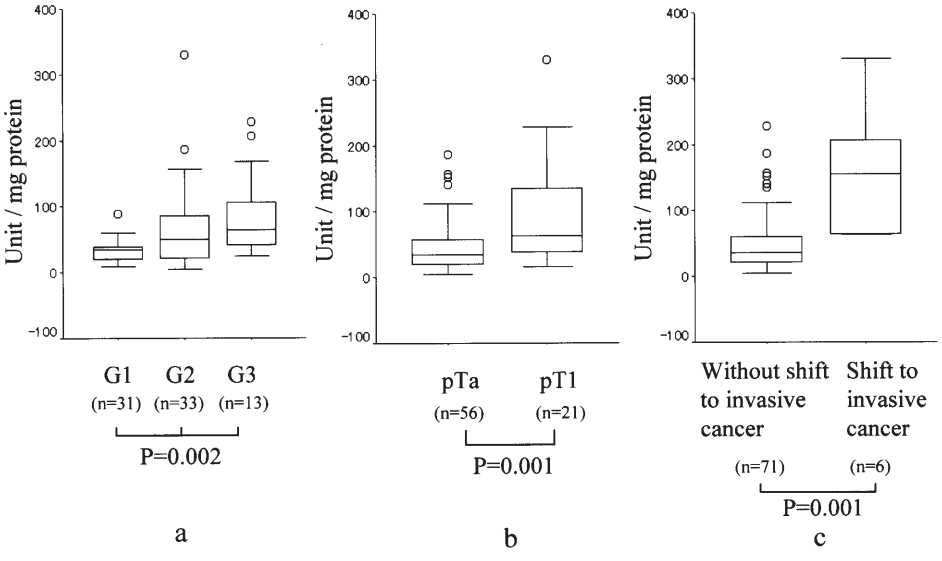

Figure 1. Relationship among TP expression and histological parameters, and shift to invasive cancer in primary superficial bladder cancer. TP expression significantly increased with the histological grade (a) and stage (b). TP expression in 6 cases showing a shift to invasive cancer was significantly higher than in 71 cases without invasive cancer (c).

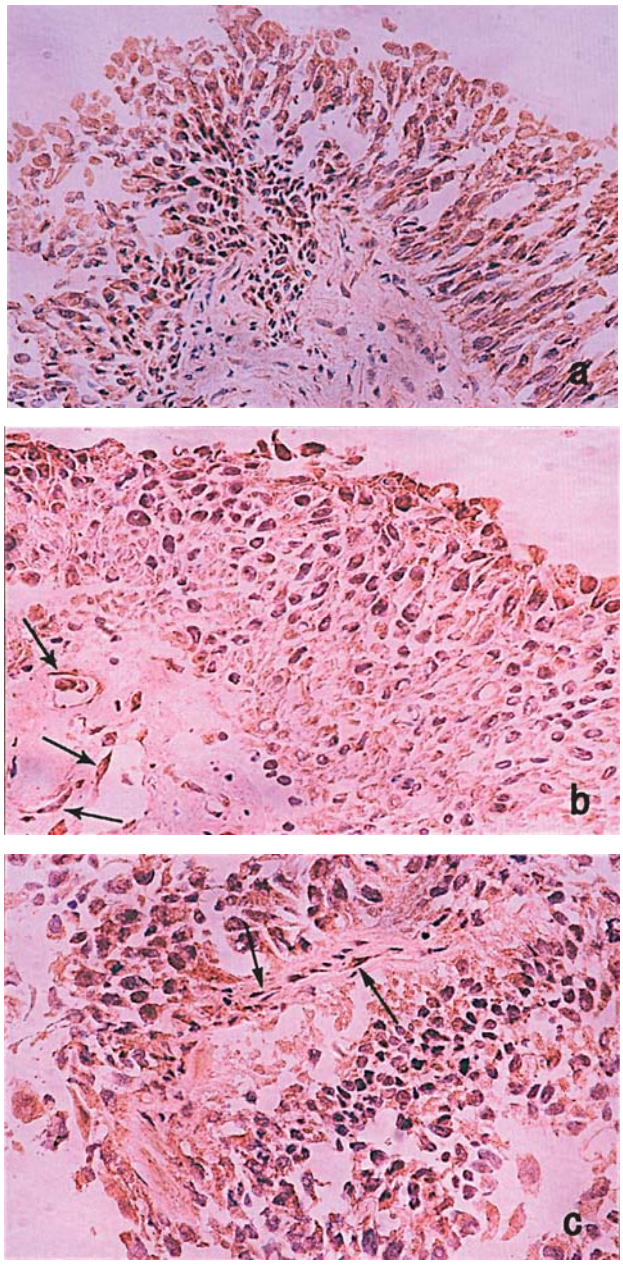

Figure 2. Immunohistochemical staining with the anti-TP antibody in grade 1 (a), grade 2 (b) and grade 3 (c) TCC. TP immunoreactivity was nuclear and cytoplasmic in cancer cells. However, the staining intensity of cytoplasms in TP-positive cancer cells was stronger than that of nuclei. Furthemore, strong immunoreactivity for TP was seen in vascular endothelial cells (b and c, arrows) (original magnification x 200).

(TMB) and H_2O_2 (TMB microwell peroxidase substrate system, KPL) for 10-20 min at room temperature. The peroxidase reaction was stopped by the addition of 1 M phosphate solution, and the amount of TP was estimated by measuring its absorbance at 450 nm with a plate reader.

Immunohistochemical staining of TP. Seventeen patients with primary superficial bladder cancer grades 1-3 with sufficient frozen samples after ELISA assay for cryostat tissue sections were selected from 77 patients who had been examined for TP expression levels. Cryostat tissue sections of 4-6 μm were treated with 0.3% H_2O_2 in absolute methanol for 20 min at room temperature to block endogenous peroxidase activity. After washing with PBS, the sections were treated with 3% (w/v) skim-milk in PBS at room temperature and incubated with mouse MoAb IC6-203 (Nippon Roche Research Center Kanagawa, Japan) (1 μg/ml) with recognized PD-ECGF/TP, at 4˚C overnight. After washing with PBS, they were incubated for 30 min with biotinylated anti-mouse IgG (Zymed, South San Francisco, CA, USA) at room temperature. After washing again with PBS, the sections were incubated with Avidin-Biotin Complex (Vectastain ABC kit, Vector, Burlingame, CA, USA) for 30 min at room temperature, and developed with 1 mg/ml diaminobenzidine tetrahydrochloride in Tris-buffered saline containing 0.03% (vol/vol) H_2O_2. The sections were counterstained with hematoxylin and mounted. As a control, normal mouse IgG was used instead of the primary antibody. Immunostaining was carried out on tissue from 17 patients with primary superficial bladder cancer (five grade 1, seven grade 2 and five grade 3). Microscopic qualitative observation of immunohistologically stained preparations was carried out mainly to identify TP localization.

Statistical methods. Statistical analysis was performed using the Mann-Whitney U-test (between two groups) or Kruskal-Wallis H-test (among three groups) to evaluate the significance of differences. The postoperative disease-free interval was determined by the Kaplan-Meier method, and statistical differences in recurrence between patients with low and high levels of TP expression were evaluated by the log-rank test. The risk for recurrence was studied with both univariate (log-rank test) and multivariate (Cox proportional hazard model) methods of analysis. A value of $P<0.05$ was considered significant. All statistical analyses were conducted using StatView software (version 5.0, SAS Institute Inc.).

Results

Levels of TP expression in primary superficial bladder cancer. TP expression shown as the mean ± SD was 58.7±57.7 unit/mg protein in primary superficial bladder cancer. TP expression in primary superficial bladder cancer significantly increased with the histological grade (P=0.002; Kruskal-Wallis H-test) (Fig. 1a). Increased TP expression was also observed as the tumor histological stage progressed. Namely, TP expression in stage pT1 was found to be significantly higher than in stage pTa (P=0.001; Mann-Whitney U test) (Fig. 1b). Regarding multiplicity, tumor size, and tumor shape, no significant correlation between TP expression and these prognostic parameters was observed using the Mann-Whitney U test (P=0.716 in multiplicity, P=0.549 in tumor size, P=0.0706 in tumor shape). Six of 77 patients with primary superficial bladder cancer developed invasive cancer within 1 year. The TP expression of these 6 cases showing a shift to invasive cancer was significantly higher than the remaining 71 cases (P=0.001; Mann-Whitney U test) (Fig. 1c).

Immunohistochemical localization of TP in primary superficial bladder cancer. Fig. 2 shows representative findings of immunohistologic staining of 17 patients with grade 1-3 superficial bladder cancer showing transitional cell carcinoma (TCC). In summary, microscopically, in grade 1 TCC, regular

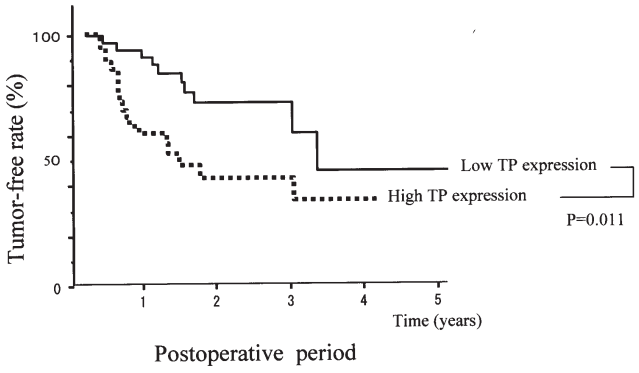

Figure 3. Postoperative tumor-free period of 77 patients with primary superficial bladder cancer. TP expression less than the median value was regarded as low expression and TP expression greater than the median value was regard as high expression. There was a significant difference in the tumor-free interval between the 2 groups. TP, thymidine phosphorylase. Low TP expression (n=38), high TP expression (n=39).

frond-like papillae covered by more than seven layers of uniform transitional epithelial cells were present throughout. Immunoreactivity for TP was nuclear and cytoplasmic in cancer cells but the cytoplasms of TP-positive carcinoma cells were more intensively stained than nuclei (Fig. 2a). In grade 2 TCC, the papillary configuration persisted, but there was crowding and layering of cells, enlargement and hyperchromasia of nuclei, and relatively numerous mitotic figures. Cancer cells showed a positive reaction in the nuclei and cytoplasms against TP. Furthermore, strong immunoreactivity for TP was found in vascular endothelial cells (Fig. 2b, arrows). In grade 3 TCC, papillary areas were still present but were irregularly distributed. Cellular atypia and plemorphism were seen with frequent mitotic figures. The cytoplasms of carcinoma cells showing cellularity were more strongly stained than the nuclei, and endothelial cells of capillaries compressed by proliferating cancer cells were also positively stained with the anti-TP antibody (Fig. 2c, arrows). In grade 1-3 tumors, non-cancerous cells positive for immunostaining with the anti-TP antibody were scattered in the stroma. These cells were macrophages and lymphocytes (data not shown) except for vascular endothelial cells as described above. A negative control stained with normal mouse IgG instead of the primary antibody was negative for immunostaining.

The prognostic relevance of TP expression in primary superficial bladder cancer. The postoperative tumor-free period was estimated by Kaplan-Meier analysis in 77 patients with primary superficial bladder cancer. Patients were divided into two groups, those with low TP expression [(less than the median value of 38.1 unit/mg protein)] and those with high TP expression (greater than the median value). Patients with low TP expression had a significantly longer tumor-free interval compared with those with high TP expression (P=0.011) (Fig. 3). Additionally, we investigated whether TP expression is an independent prognostic variable for recurrence using the Cox proportional hazard model. According to univariate analysis, TP expression (P=0.0143) was a significant prognostic factor (Table II). Multivariate analysis also showed that TP expression (P=0.0441) was a significant prognostic factor (Table III).

Table II. Univariate Cox proportional hazard analysis.

Prognostic factor	Hazard ratio	95% CI	p-value
Multiplicity			
Solitary	1.00		
Multiple	1.326	0.624-2.817	0.4629
Tumor grade			
G1+G2	1.00		
G3	2.304	0.844-6.294	0.1034
Tumor stage			
pTa	1.00		
pT1	1.47	0.642-3.366	0.362
Tumor size			
<3 cm	1.00		
≥3 cm	1.494	0.696-3.207	0.3025
Tumor shape			
Pedunculated	1.00		
Sessile	2.092	0.972-4.503	0.0591
TP expression			
Low	1.00		
High	2.649	1.215-5.775	0.0143

CI, confidence interval. Hazard ratio and 95% confidence intervals were obtained from the Cox proportional hazard model.

Table III. Multivariate Cox proportional hazard analysis.

Prognostic factor	Hazard ratio	95% CI	p-value
Tumor grade			
G1+G2	1.00		
G3	1.514	0.517-4.430	0.4491
Tumor shape			
Pedunculated	1.00		
Sessile	1.585	0.695-3.615	0.2732
TP expression			
Low	1.00		
High	2.294	1.022-5.149	0.0441

CI, confidence interval. Hazard ratio and 95% confidence intervals were obtained from the Cox proportional hazard model.

Discussion

In this study, it was revealed that TP expression in primary superficial bladder cancer increased with the histological grade and stage, and that superficial bladder cancer patients with low

TP expression had a significantly longer tumor-free interval compared with those with high TP expression. Furthermore, high TP expression was an independent prognostic factor for tumor recurrence by both univariate and multivariate analyses.

Approximately 75-80% of all bladder cancers are superficial at the first presentation (3). Superficial bladder cancers are usually managed by TUR-Bt and prognosis is relatively good. However, superficial bladder cancer recurs with high incidence. In addition, the risk of progression to invasive disease in high-grade superficial bladder cancer significantly increases (12). Several reports have already shown the correlation between TP and malignant behavior in tumor prognosis in various malignant tumors (13-16). With regard to TP in bladder cancer, there are only a few reports (17-20) and the prognostic significance of TP expression in bladder cancer has not yet been thoroughly clarified. Mizutani *et al* (21) reported that elevated TP expression by high performance liquid chromatography predicted early recurrence of Ta bladder carcinoma from the postoperative tumor-free period determined by the Kaplan-Meier method. On the other hand, TP expression by immunohistochemistry was reported to be not a predictive index of the recurrence-free rate for superficial bladder cancer (22). The difference between these findings may be attributed to the detection of TP expression by different methods. To date, no prognostic marker for predicting recurrence in all superficial bladder cancer including pTa and pT1 has been established. Our results using the Kaplan-Meier method and both univariate and multivariate analyses suggest that TP expression by ELISA may be a prognostic marker for predicting recurrence in primary superficial bladder cancer including both pTa and pT1. Therefore, the elevated TP expression by ELISA predicts poor prognosis due to recurrence in patients with primary superficial bladder cancer. The level of TP expression in invasive bladder cancer was reported to be significantly higher than that in superficial bladder cancer (23). In this study, after TUR-Bt, the TP expression of 6 patients who developed invasive carcinoma within 1 year was significantly higher than in the remaining 71 patients without a shift to invasive cancer. This result suggests that elevated levels of TP expression in superficial bladder cancer are associated with tumor characteristics of invasion. However, further study of more cases developing to invasive carcinoma is required to confirm the relationship between high TP expression and the shift to invasive cancer in primary superficial bladder cancer.

In this immunostaining, the cytoplasms of cancer cells were heavily stained in comparison with the nuclei of cancer cells, though TP immunoreactivity was seen in both nuclear and cytoplasmic elements. Furthermore, strong TP immunoreactivity was also observed in vascular endothelial cells. The immunohistochemical nuclear localization of TP has been reported (17,19,24,25); however, most reports on TP immunostaining described that TP was mainly localized in the cytoplasms of tumor cells. The TP sequence was 100% identical to the PD-ECGF sequence (residue 149-244) (6). Therefore, it is thought that the anti-TP antibody is able to react with vascular endothelial cells with PD-ECGF expression. By our qualitative observation of immunohistochemically stained preparations including grade 1-3 TCC, TP immunoreactivity in vascular endothelial cells derived from angiogenesis was found in both grades 2 and 3. These findings suggest that angiogenesis is associated with tumor malignancy since it has been shown to be necessary for tumor growth, invasion and metastasis (26).

Since TP expression in primary superficial bladder cancer increased with the histological grade and stage, elevated TP expression may predict recurrence in superficial bladder cancer, and TP having angiogenic activity (27,28) is able to promote tumor growth (29), a high TP expression in bladder cancer is considered to depend on the marked proliferation of tumor cells and an increase in vascular endothelial cells showing strongly positive immunostaining, which are associated with tumor characteristics of malignant potential and invasion.

In conclusion, this study suggests that TP expression may be an independent prognostic indicator of tumor recurrence in primary superficial bladder cancer. High TP expression in superficial bladder cancer may be associated with the marked proliferation of tumor cells and increased vascular endothelial cells showing strongly positive immunostaining.

References

1. Fukushima S and Furusato M: Pathological matters. In: General Rule for Clinical and Pathological Studies on Bladder Cancer. (in Japanese). Kamidono S (ed). 3rd edition. Kanehara Press, Tokyo, pp43-74, 2001.
2. TNM Classification of Malignant Tumours. Sobin LH and Wittekind CH (eds). 5th edition. Wiley-Liss, New York, pp187-190, 1997.
3. Li S, Nomata K, Sawase K, Noguchi M, Kanda S and Kanetake H: Prognostic significance of platelet-derived endothelial cell growth factor/thymidine phosphorylase expression in stage pT1 G3 bladder cancer. Int J Urol 8: 478-482, 2001.
4. Streeter ED and Harris AL: Angiogenesis in bladder cancer-prognostic marker and target for future therapy. Surg Oncol 11: 85-100, 2002.
5. Ishikawa F, Miyazono K, Hellman U, *et al*: Identification of angiogenic activity and the cloning and expression of platelet-derived endothelial cell growth factor. Nature 338: 557-562, 1989.
6. Furukawa T, Yoshimura A, Sumizawa T, Haraguchi M and Akiyama S: Angiogenic factor. Nature 356: 668, 1992.
7. Usuki K, Saras J, Waltenberger J, *et al*: Platelet-derived endothelial cell growth factor has thymidine phosphorylase activity. Biochem Biophys Commun 184: 1311-1316, 1992.
8. Yoshimura A, Kuwazuru Y, Furukawa T, Yoshida H, Yamada K and Akiyama S: Purification and tissue distribution of human thymidine phosphorylase; high expression in lymphocytes, reticulocytes, and tumors. Biochim Biophys Acta 1034: 107-113, 1990.
9. Takebayashi Y, Yamada K, Miyadera K, *et al*: The activity and expression of thymidine phosphorylase in human solid tumours. Eur J Cancer 32A: 1227-1232, 1996.
10. Nishida M, Hino A, Mori K, Matsumoto T, Yoshikubo T and Ishituka H: Preparation of anti-human thymidine phosphorylase monoclonal antibodies useful for detecting the enzyme levels in tumor tissues. Biol Pharm Bull 19: 1407-1411, 1996.
11. Mori K, Hasegawa M, Nishida M, *et al*: Expression levels of thymidine phosphorylase and dihydropyrimidine dehydrogenase in various human tumor tissues. Int J Oncol 17: 33-38, 2000.
12. Kaubisch S, Lum BL, Reese J, Freiha F and Torti FM: Stage T1 bladder cancer: grade is the primary determinant for risk of muscle invasion. J Urol 146: 28-31, 1991.
13. Takano S, Takebayashi Y, Che X, *et al:* Expression of thymidine phosphorylase is associated with a poor prognosis in patients with ductal adenocarcinoma of the pancreas. Clin Cancer Res 4: 1619-1624, 1998.
14. Yoshikawa T, Suzuki K, Kobayashi O, *et al*: Thymidine phosphorylase/platelet-derived endothelial cell growth factor is upregulated in advanced solid types of gastric cancer. Br J Cancer 79: 1145-1150, 1999.

15. Toi M, Hoshina S, Taniguchi T, Yamamoto Y, Ishitsuka H and Tominaga T: Expression of platelet-derived endothelial cell growth factor/thymidine phosphorylase in human breast cancer. Int J Cancer 64: 79-82, 1995.
16. Yasuno M, Mori T, Koike M, *et al*: Importance of thymidine phosphorylase expression in tumor stroma as a prognostic factor in patients with advanced colorectal carcinoma. Oncol Rep 13: 405-412, 2005.
17. O'Brien TS, Fox SB, Dickinson AJ, *et al*: Expression of the angiogenic factor thymidine phosphorylase/platelet-derived endothelial cell growth factor in primary bladder cancers. Cancer Res 56: 4799-4804, 1996.
18. Kubota Y, Miura T, Moriyama M, Noguchi S, Matsuzaki J, Takebayashi S and Hosaka M: Thymidine phosphorylase activity in human bladder cancer: difference between superficial and invasive cancer. Clin Cancer Res 3: 973-976, 1997.
19. Tanaka T, Yoshiki T, Arai Y, *et al*: Expression of platelet-derived endothelial cell growth factor/thymidine phosphorylase in human bladder cancer. Jpn J Cancer Res 90: 1344-1350, 1999.
20. Hirano Y, Kageyama S, Ushiyama T, Suzuki K and Fujita K: Clinical significance of thymidine phosphorylase and dihydropyrimidine dehydrogenase expression in transitional cell cancer. Cancer Chemother Pharmacol 51: 29-35, 2003.
21. Mizutani Y, Okada Y and Yoshida O: Expression of platelet-derived endothelial cell growth factor in bladder carcinoma. Cancer 79: 1190-1194, 1997.
22. Shimabukuro T, Matsuyama H, Baba Y, *et al*: Expression of thymidine phosphorylase in human superficial bladder cancer. Int J Urol 12: 29-34, 2005.
23. Arima J, Imazono Y, Takebayashi Y, *et al*: Expression of thymidine phosphorylase as an indicator of poor prognosis for patients with transitional cell carcinoma of the bladder. Cancer 88: 1131-1138, 2000.
24. Sawase K, Nomata K, Kanetake H and Saito Y: The expression of platelet-derived endothelial cell growth factor in human bladder cancer. Cancer Lett 130: 35-41, 1998.
25. Stavropoulos NE, Bouropoulos C, Ioachim E, *et al*: Prognostic significance of thymidine phosphorylase in superficial bladder carcinoma. Int Urol Nephrol 37: 55-60, 2005.
26. Streeter EH and Crew JP: Angiogenesis, angiogenic factor expression and prognosis of bladder cancer. Anticancer Res 21: 4355-4364, 2001.
27. Haraguchi M, Miyadera K, Uemura K, *et al*: Angiogenic activity of enzymes. Nature 368: 198, 1994.
28. Miyadera K, Sumizawa T, Haraguchi M, *et al*: Role of thymidine phosphorylase activity in the angiogenic effect of platelet-derived endothelial cell growth factor/thymidine phosphorylase. Cancer Res 55: 1687-1690, 1995.
29. Moghaddam A, Zhang H-T, Fan T-PD, *et al:* Thymidine phosphorylase is angiogenic and promotes tumor growth. Proc Natl Acad Sci USA 92: 998-1002, 1995.