

# Progress in research on intracranial multiple dural arteriovenous fistulas (Review)

YUNBAO GUO<sup>1\*</sup>, JING YU<sup>2\*</sup>, YING ZHAO<sup>3</sup> and JINLU YU<sup>1</sup>

<sup>1</sup>Department of Neurosurgery; <sup>2</sup>Operating Room; <sup>3</sup>Training Department, The First Hospital of Jilin University, Changchun, Jilin 130021, P.R. China

Received October 12, 2017; Accepted November 3, 2017

DOI: 10.3892/br.2017.1021

**Abstract.** Intracranial multiple dural arteriovenous fistulas (MDAVFs) are rare lesions that are difficult to treat. The key factors involved in the development of MDAVFs remain unknown. At present, the majority of reports on intracranial MDAVFs are confined to case reports and small case series, and thus understanding of MDAVFs is limited. The current review assesses the available literature to date with the aim of reviewing the progress in research on intracranial MDAVFs. Intracranial MDAVFs may be divided into two types: Synchronous and metachronous. While the exact pathogenesis of MDAVFs is unknown, a number of possible mechanisms are considered relevant. The first is that MDAVFs develop following recanalization of a large sinus thrombosis that involves several sinuses. The second possibility is that a pre-existing DAVF may induce sinus thrombosis or venous hypertension, resulting in a new MDAVF. The third is that MDAVFs are caused by increased angiogenic activity, which may induce the development of MDAVFs. Intracranial MDAVFs have a malignant clinical course, and their symptoms generally rapidly progress following onset. It is therefore important to identify intracranial MDAVFs at an early stage. A number of imaging technologies, including computed tomography (CT), magnetic resonance imaging (MRI), digital subtraction angiography (DSA) and single-photon emission computed tomography (SPECT), may be used to detect MDAVFs. Of these, CT and MRI provide information on brain morphology, SPECT provides brain blood flow information, and DSA is the gold standard that may be used to identify angioarchitecture and hemodynamics. MDAVFs require timely and aggressive treatment, which may include endovascular embolization, surgical resection, radiosurgery

and conservative treatment, and in some cases, combined treatments are required. Appropriate and aggressive treatment regimens can markedly improve neurological deficits and cognitive function in patients with MDAVFs.

## Contents

1. Introduction
2. Definition and classification
3. Pathogenesis
4. Angioarchitecture and hemodynamics
5. Clinical features
6. Imaging examinations
7. Treatment
8. Prognosis
9. Conclusion

## 1. Introduction

Intracranial multiple dural arteriovenous fistulas (MDAVFs) are difficult to treat and pose a challenge for neurosurgeons. Intracranial MDAVFs are also rare, with an incidence rate of 6-9% among all cranial DAVFs reported in Korea, Canada and the USA (1-3). As few cases have been reported, understanding of intracranial MDAVFs is limited. At present, the pathogenesis underlying MDAVF development is not well understood, though there is a consensus that three mechanisms are possible: i) MDAVFs may develop following establishment of a sinus thrombosis involving several sinuses; ii) pre-existing DAVFs may induce sinus thrombosis or venous hypertension, resulting in the formation of MDAVFs; and iii) MDAVFs may be caused by increased angiogenic activity and technical problems that are associated with transvenous embolization (4). In addition, angiogenic factors, hemodynamic disruption and congenital factors may be involved in MDAVF pathogenesis (1-3,5,6).

In clinical terms, intracranial MDAVFs are considered to follow a relatively malignant evolution, and their hemodynamics, angioarchitecture and imaging manifestations are complex (7,8). Affected patients exhibited higher incidence rates of hemorrhage and neurological deficits, and aggressive treatments should therefore be used for therapy (2,9). At present, a number of approaches are used to treat intracranial MDAVFs. These include endovascular embolization,

---

*Correspondence to:* Dr Jinlu Yu, Department of Neurosurgery, The First Hospital of Jilin University, 71 Xinmin Avenue, Changchun, Jilin 130021, P.R. China  
E-mail: jlyu@jlu.edu.cn

\*Contributed equally

**Key words:** multiple dural arteriovenous fistulae, intracranial, research progress

surgical resection, radiosurgery and conservative treatment, although in more aggressive cases, combined treatments are required (10,11).

However, it is currently unknown which treatment is most effective or which therapeutic principle should be followed. Although progress has been made in diagnosing and evaluating MDAVFs, generally through hemodynamic studies and improved imaging techniques, understanding of DAVFs remains limited. As the majority of reports on intracranial MDAVFs are confined to case reports and small case series, the present review sought to assess the available literature published to date. ‘Multiple dural arteriovenous fistulas’ and ‘multiple dural arteriovenous malformations’ were used as search terms in PubMed (<https://www.ncbi.nlm.nih.gov/pubmed>) and Web of Science (<https://www.isiknowledge.com>) databases to identify relevant English-language studies. Reports among this relevant literature were presently reviewed to highlight the extent of progress in research into intracranial MDAVFs.

## 2. Definition and classification

Multiple intracranial MDAVFs may occur simultaneously or develop over time in a single patient (1). The type of each MDAVF should therefore be defined with regard to its time of onset and location (7). Multiple MDAVFs that occur simultaneously are referred to as ‘synchronous’, these types of MDAVF may overlap, leading to difficulty in distinguishing them from other lesions (2). Conversely, when independent MDAVFs develop over time in the same patient, for instance, *de novo* fistulas that develop in different locations in a temporal sequence, they are referred to as ‘metachronous’ (2).

A previous literature review noted that the majority of reports on intracranial MDAVFs described synchronous-type fistulas, while those on metachronous MDAVFs were rare. One report that included increased cases of metachronous MDAVFs was published by Ha *et al* (2) in 2012, in which 14 intracranial MDAVFs were described, including 7 cases of metachronous-type MDAVF. The specific causes of synchronous-type MDAVFs are unknown, though they are all induced by a single initiating process (12). Conversely, for metachronous-type MDAVFs, the first DAVF may induce development of the others (13). However, in diagnosing intracranial MDAVFs, it is frequently difficult to determine which type of intracranial MDAVFs the patient is presenting with, as is not possible to distinguish whether synchronous-type lesions developed from the metachronous-type (14).

## 3. Pathogenesis

The exact pathogenesis underlying the development of single intracranial MDAVFs remains unknown. It has been suggested that MDAVFs share the same pathogenesis as single DAVFs, and that venous sinus thrombosis, congenital development, head trauma and surgical procedures may therefore be involved in the development of MDAVFs (15). In addition, conditions including infections, postpartum status and coagulopathies may provide a conducive environment for MDAVFs (16,17). These incidents cause closed preexisting arteriovenous channels to become enlarged (18). However, in MDAVFs, multiple

regions are simultaneously involved, and thus the mechanisms likely differ from those underlying the development of single DAVFs.

*Venous sinus thrombosis.* Of all potential causes, venous hypertension following venous sinus thrombosis has been proposed to be a critical pathogenic factor (19-21). If sinus thromboses are simultaneous and extensive, they may form MDAVFs that can be identified following recanalization of the thrombosed sinuses (22). For instance, in the report by Ha *et al* (2), 71.4% of intracranial MDAVFs exhibited extensive dural sinus thrombosis. The mechanisms involved in venous sinus thrombosis leading to MDAVFs are complex. Inflammation may serve an important role by upregulating the release of angiogenic growth factors to cause neovascularization of the affected sinus wall (16).

*Angiogenic factors.* Numerous angiogenic factors, including platelet-derived endothelial-cell growth factor, fibroblast growth factor and transforming growth factor- $\beta$  may also provide a conducive environment for the development of intracranial single DAVFs (5). The production of angiogenic factors may be induced by infections, postpartum status, a state of hypercoagulability, a vascular proliferative state, arthritis, psoriasis and hemangiomas, in which strong angiogenic stimuli overcome homeostatic barriers, resulting in unabated vascular proliferation and eventually DAVFs (23). Additionally, angiogenic factors affect the dural venous sinuses, which may explain why certain patients present with numerous individual DAVFs (24). The hypothesis that angiogenic factors are a causative factor is particularly convincing when considering patients with MDAVFs that simultaneously involve cranial and spinal areas (11). In such a pathological state, targeted anti-angiogenic therapy may promote the spontaneous obliteration of MDAVFs and prevent their recurrence following successful treatment (5,25).

*Disturbance of hemodynamics.* When the first intracranial DAVF develops, the hemodynamics of the venous system in the brain is disturbed, and this may induce the development of new DAVFs, eventually resulting in the formation of metachronous-type MDAVFs (1,2). It has been hypothesized that the following two mechanisms are involved in this process: i) Venous drainage caused by an established DAVF may cause turbulent flow or stagnation in the distant venous sinus, resulting in thrombosis of the sinus and development of additional DAVFs; ii) venous hypertension may cause the development of a DAVF, and the elevation in sinus pressure caused by the initial DAVF may result in the formation of multiple new DAVFs at other sites (1-3).

For instance, Kubota *et al* (13) described a 43-year-old woman presenting with a cavernous DAVF following transvenous embolization, who subsequently developed a new DAVF around the jugular valve. A change in hemodynamics was considered the cause, as venous pressure was elevated and prolonged by the shunted venous flow. Thus, a transvenous approach for DAVF may result in the formation of a new DAVF (13). In addition to treatment for DAVF, treatments for other intracranial vascular diseases may also cause the formation of new intracranial DAVFs. For instance,

Bai *et al* (26) in 2012 treated a pediatric case of high-flow pial AVF using embolization, after which a *de novo* DAVF and a small arteriovenous malformation developed as a result of changes in hemodynamics that occurred following the embolization.

**Congenital factors.** In addition to MDAVFs caused by acquired factors, certain intracranial MDAVFs may be congenital in origin, particularly those observed in children. In these cases, MDAVFs are often associated with a developmental malformation in the venous sinus (6). For instance, Vilela *et al* (27) described a 5-year-old patient with MDAVFs who also presented with status epilepticus resulting from severe venous congestive encephalopathy, occlusion of the right sigmoid sinus, absence of cavernous sinuses and stenosis in the left sigmoid sinus-jugular bulb. In another case reported by Ushikoshi *et al* (28), a 5-year-old boy presented with an infantile-type DAVF in a dilated anterior part of the superior sagittal sinus and two other adult-type DAVFs. In addition to MDAVFs that are caused by developmental malformation of the venous sinus, intracranial MDAVFs may be accompanied by other congenital diseases. For instance, on assessment of a 46-year-old man with Cowden syndrome, Prats-Sánchez *et al* (29) suggested that phosphatase and tensin homolog gene mutations were the underlying cause for intracranial MDAVFs.

In summary, the exact pathogenesis underlying the development of intracranial MDAVFs remains unclear, though venous sinus thrombosis, angiogenic factors, disturbed hemodynamics and congenital factors are considered to be potential causes. However, for the majority of intracranial MDAVFs, there is no evidence of an underlying pathogenesis (16,30,31). Thus, identification of the causes of intracranial MDAVFs is required to aid prevent their progression.

#### 4. Angioarchitecture and hemodynamics

At present, understanding of the angioarchitecture of intracranial MDAVFs is based on single DAVFs (7). However, MDAVFs present with more complex angioarchitecture and hemodynamics; when intracranial MDAVFs develop, they may overlap, which causes the architecture of the feeding arteries to become more complex (9). Venous hypertension caused by a single DAVF may be enhanced by the presence of the other DAVFs, and compensatory blood flow throughout the brain may be disturbed, causing the condition of the patient to rapidly deteriorate (32). Under these circumstances, it is important to distinguish which DAVFs are the major implicated fistulas, which should be the DAVFs with a higher Borden/Cognard classification (33,34). Determining which are the responsible DAVFs requires selective artery angiography.

For intracranial MDAVFs, the angioarchitecture and hemodynamics of the MDAVFs may be more dependent on the pattern of involvement of the venous system (35). In MDAVFs, retrograde leptomeningeal venous drainage serves a critical role, MDAVFs increase the pressure in the venous sinus and the resistance to blood flow to the sinus (15). Thus, in patients with more than a single DAVF, the rate of cortical venous drainage reflux is higher. For instance, Van Dijk *et al* (3) in 2002 reported that cortical venous reflux

was present in 84% of MDAVF patients. Therefore, MDAVFs may be associated with a high risk of intracranial hemorrhage or venous ischemia.

Furthermore, in MDAVFs, venous hypertension occurs more frequently in the deep venous system. The deep white matter is therefore vulnerable to venous congestion, which can cause leukoaraiosis (36). Additionally, in children with intracranial MDAVFs, developmental malformations are often observed in the venous sinus, and these may increase complexity of the hemodynamics (37). Therapeutic decisions, such as whether the feeding arteries are of sufficient thickness to perform an embolization via a transarterial approach or whether a draining sinus with stenosis can be dilated using stenting angioplasty via a transvenous approach, should be determined based on a complete understanding of the angioarchitecture and hemodynamics of the intracranial MDAVFs.

#### 5. Clinical features

Single intracranial DAVFs typically present as a spectrum of benign symptoms, including headache, murmur, pulsatile tinnitus and eye symptoms, though they may occasionally present with increased intracranial pressure or even fatal hemorrhage (38). However, intracranial MDAVFs differ markedly from single lesions, as MDAVFs may alter the dynamics of venous flow throughout the brain, which impairs cerebral circulation by causing severe venous hypertensive encephalopathy (14). Thus, MDAVFs have greater probability of presenting with hemorrhage, infarction or neurological deficit and to run a malignant course (30). The clinical features of intracranial MDAVFs are subsequently described.

**General characteristics.** As current understanding of intracranial MDAVFs is derived from data on DAVFs, it may be speculated that the clinical characteristic of MDAVFs are similar to those commonly observed in DAVFs. Martinez-Burbano *et al* (9) reviewed the literature and identified that intracranial MDAVFs were slightly more predominant in females, at a ratio of 1.65:1 (women: men), and that the average age of onset was approximately 60 years old. Similar results have been reported previously. For instance, Fujita *et al* (4) observed that in patients with MDAVFs, ages ranged from 43 to 75-years-old (mean, 57.4-years-old), and that the population distribution had a female predominance. Additionally, DAVFs occurred primarily in the cavernous sinuses, while other locations included the transverse and sigmoid sinuses (4). These results are similar to those obtained in studies of single DAVFs (39,40). However, to date, few cases of intracranial MDAVFs have been reported. Thus, evaluations of their general characteristics may be inaccurate.

**Rapid progression of symptoms.** As there is severe cortical venous reflux in MDAVFs, the compensation of blood flow tends to cause disequilibrium, which leads to venous hypertension (41). When venous hypertensive encephalopathy develops alongside MDAVFs, this has been associated with aggressive initial symptoms, including neurological deficits, seizures and hemorrhage (2). This rapid progression of symptoms is a characteristic of intracranial MDAVFs that distinguishes them from single DAVFs. In addition to the aforementioned

common symptoms, intracranial MDAVFs may present with higher-order brain dysfunctions, including progressive dementia, cognitive decline and progressive memory loss, and are an indicator of dysfunction throughout the brain (42,43). For instance, Abe *et al* (44) in 2014 described a 67-year-old female presenting with intracranial MDAVFs that manifested as dementia, which rapidly progressed over 2 months. In certain cases, rapidly progressive dementia has been associated with extrapyramidal motor symptoms, including parkinsonism (45).

*Symptoms in the spinal cord.* DAVFs may occur in the cranial dura and also in the spinal dura, while MDAVFs occur in the spinal dura (1). Van Dijk *et al* (3) reported that spinal MDAVFs comprised 2% of all spinal DAVFs. Therefore, when intracranial MDAVFs develop, if a patient presents with myelopathy and this symptom cannot be explained by an intracranial MDAVF, spinal MDAVFs should be considered as they may be caused by venous congestion of the spinal cord (46). Shankar *et al* (11) reported a 61-year-old man with two intracranial DAVFs that were associated with four cervical DAVFs.

*Symptoms of pediatric MDAVFs.* Intracranial pediatric MDAVFs differ from adult intracranial MDAVFs; their clinical manifestations are distinct and may be summarized as symptoms that are caused by high-flow dural arteriovenous fistulas (47). Affected patients often present with symptoms including hyperdynamic heart failure, increased intracranial pressure, macrocrania, neurocognitive delay and seizures (6). The symptoms of retrograde venous drainage include hemorrhage and neurological deficits, and symptoms associated with cavernous sinus involvement and hydrocephalus, among other indications (6).

## 6. Imaging examinations

*Computed tomography (CT) imaging.* Brain CT is advantageous as it enables the presence of hemorrhaging to be evaluated in a patient, unlike other examination techniques (48). It may also be used to identify venous hypertension and sinus thrombosis (49). Flat panel CT analysis and three-dimensional angiographic reconstructions are particularly useful for increasing understanding of the complex anatomy and relationships of intracranial MDAVFs (50). In Fig. 1A and B, typical images of MDAVF imaging with brain CT are presented.

*Magnetic resonance imaging (MRI).* In assessing intracranial MDAVFs, MRI is primarily used to evaluate changes in brain structures, and identifies a reduction in diffuse white matter fluid based on inversion recovery time and signal abnormalities, hyperintense changes (leukoaraiosis) and restricted diffusion in the bilateral corona radiata, and extensive enlarged serpentine vascular flow voids, which are caused by venous thrombosis and venous hypertension (44). In addition, MRI may be used to determine the progression of intracranial MDAVFs. For instance, if signal abnormality or hyperintensity improves, it indicates improvement in intracranial venous hypertension. This may implicate MRI as a more convenient technique in these cases (30). In Fig. 1C-F, typical images of MDAVF detection by brain MRI are presented.

*Digital subtraction angiography (DSA) imaging.* A DSA examination is considered the gold standard imaging technique and may be used to identify the site of a cerebral parenchyma, fistula or arterial feeders, the pattern and direction of venous drainage, and the morphology and diameter of the venous sinus in MDAVFs (51,52). In certain cases, pseudophlebitic patterns of venous drainage that typically indicate severe venous hypertension have also been observed (53). As intracranial MDAVFs are more complex, may overlap and are difficult to visualize or distinguish from other DAVFs, selective injections of different feeding arteries are often necessary during DSA to identify each DAVF (52). Typical images of MDAVF imaging with DSA are presented in Fig. 2.

*Blood flow examination.* When intracranial MDAVFs develop as a result of venous hypertension, the atrial blood flow of the whole brain is decreased. During this time, it is recommended that brain blood perfusion should be examined in affected patients using single-photon emission computed tomography (SPECT). This technique has previously been demonstrated to identify marked decreases in cerebral blood flow throughout the majority of the brain (44).

## 7. Treatment

Intracranial MDAVFs may critically disturb blood flow to the brain, and therefore treatment is crucial (16). Radical treatment is considered more appropriate, as partial obliteration of the DAVFs increases the difficulty of subsequent therapy (54). In the treatment of MDAVFs, a number of principles are generally followed: One priority of treatment is to target fistulas with cortical venous reflux with a higher Borden/Cognard classification; additionally, treatment for a DAVF is performed in multiple stages, and focuses on decreasing venous hypertension and improving cerebral hemodynamics rather than completely obliterating all fistulas (9,11). It is important to obtain a precise understanding of each DAVF's vascular anatomy, as not all fistulas contribute to venous hypertension (24,30,55). At present, treatment for intracranial MDAVFs may include endovascular treatment, microsurgery, stereotactic radiosurgery or a combination of several methods(3).

*Endovascular embolization.* Intracranial MDAVFs are not typically located in the same or adjacent regions, and thus it is difficult to expose them in a single operating field. Therefore, an endovascular approach is advantageous as it allows access to all MDAVFs. Endovascular embolization is currently the first-line standard of care for intracranial MDAVFs. The target of this treatment regimen is complete occlusion of the fistula with cortical venous reflux (24). During endovascular embolization, if the embolic agent completely occludes the fistula by crossing into the immediate receptive venous structure, an adequate outcome can be achieved (56). Endovascular embolization may be performed using different types of embolic agents and a variety of routes. Different embolic agents include coils, n-butyl cyanoacrylate and Onyx, and routes of access include transarterial and transvenous approaches; which agent and route are chosen depends on the angioarchitecture of the intracranial MDAVFs (40,57).



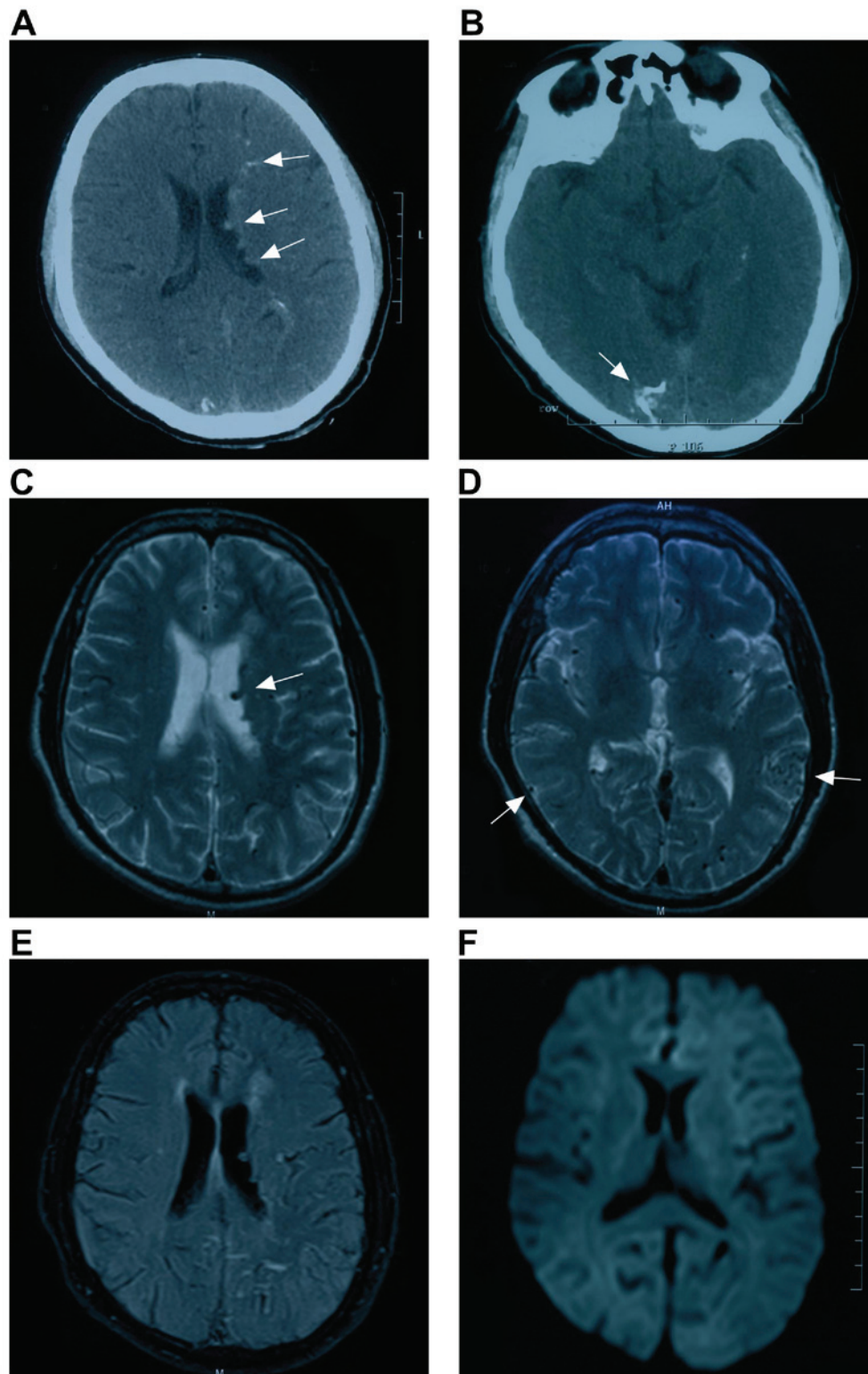


Figure 1. Brain CT and MRI images. Representative images from a patient admitted to the First Hospital of Jilin University (Changchun, China) in May 2015 presenting with multiple dural arteriovenous fistulas are shown. All images were reproduced with the consent of the patient. (A and B) CT detected multiple high-density lesions that were considered as calcification lesions in the (A) lateral ventricle and (B) tentorium (white arrows). (C and D) Axial MRI of T2 weighted images identified dilated vessels in the (C) lateral ventricle and (D) brain surface (white arrows); (E) axial MRI of a fluid-attenuated inversion recovery image identified no infarction; (F) axial MRI of a diffusion-weighted image also identified no infarction. CT, computed tomography; MRI, magnetic resonance imaging.

When the main feeding arteries are of sufficient thickness, high-grade MDAVFs are limited within a region and do not become involved in anastomosis, and transarterial approaches

are therefore recommended (58). In cases when the feeding arteries are substantially thinner and associated with venous sinus stenosis, or when multiple DAVFs are involved in the

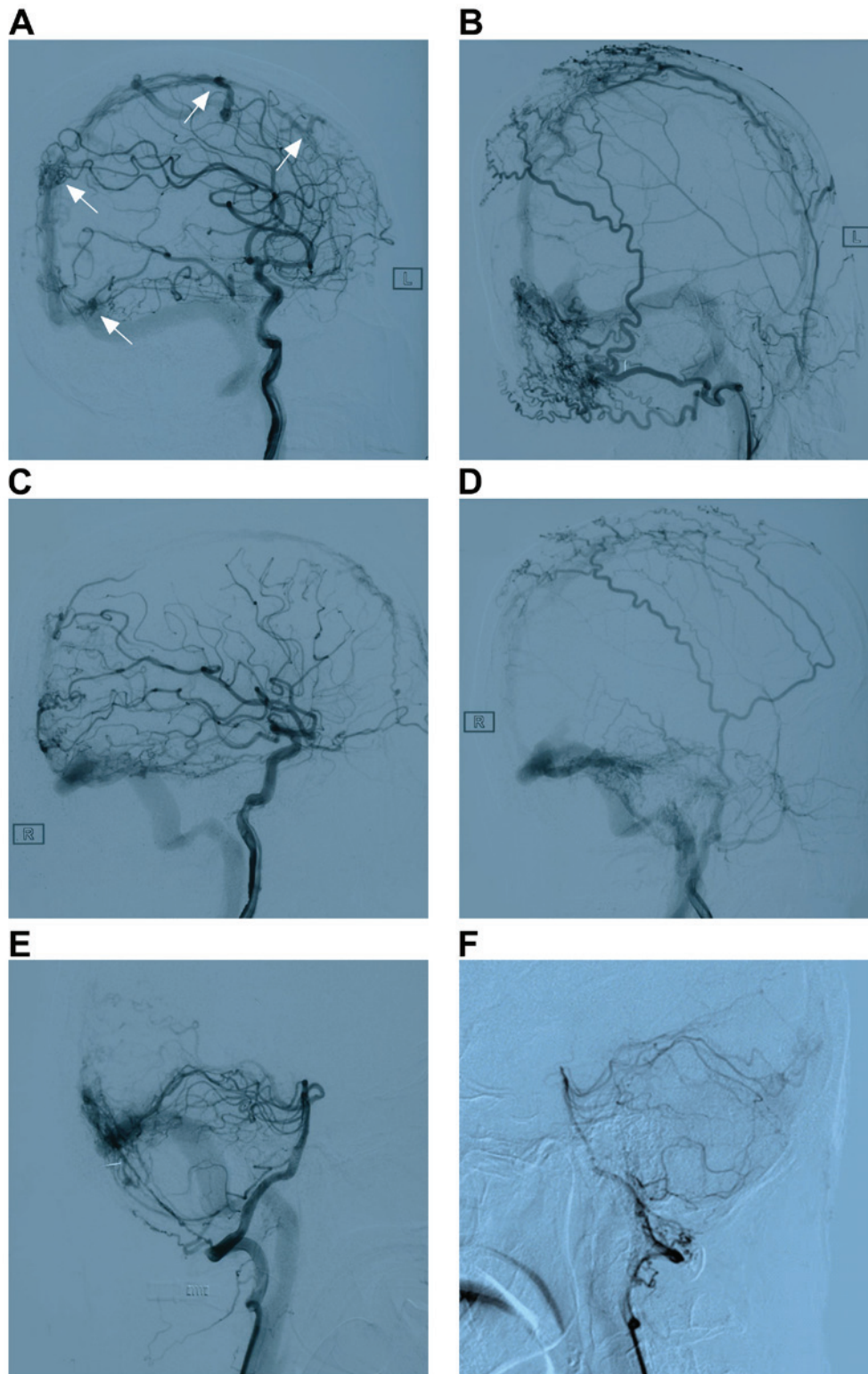


Figure 2. DSA images from the same patient in Fig. 1. (A) DSA of the left internal carotid artery detected direct arteriovenous shunts that were considered MDAVFs around the superior sagittal sinus and lateral sinus (white arrows); (B-D) DSA identified that these MDAVFs had feeding arteries from the (B) left external carotid artery, (C) right internal carotid artery and (D) right external carotid artery; (E and F) DSA identified that the DAVF in the lateral sinus had feeding arteries from the vertebral arteries. R and L denote the right and left sides. DSA, digital subtraction angiography; MDAVF, multiple dural arteriovenous fistula.

same sinus, a transvenous embolization is an appropriate method (59). For instance, Saito *et al* (19) treated a 55-year-old man with two isolated DAVFs that were located in the anterior superior sagittal sinus and transverse sinus, and achieved

complete embolization by directly packing the isolated sinuses via the superior sagittal sinus.

However, when treating multiple MDAVFs, it should be considered whether multiple sinus occlusion can be tolerated,

particularly when both the sagittal and transverse-sigmoid sinuses, which are the most appropriate candidates for transvenous embolization, are affected in patients with cortical venous drainage and normal veins through which the brain tissues are not draining into the affected sinus (54). When treating intracranial MDAVFs, a multi-stage intervention may be effective for embolizing the multiple shunts and cortical refluxes. For instance, Abe *et al* (44) successfully treated patients with two intracranial MDAVFs by performing four endovascular procedures at approximate 1-week intervals over 5 weeks.

**Microsurgical resection.** At present, although endovascular embolization is considered a first-line standard for intracranial MDAVFs, for certain dysplastic MDAVFs and in those in which the main feeding arteries are thin or the venous sinus has a thrombosis or stenosis, endovascular treatments are difficult (54). For these cases, microsurgical resection is considered an appropriate method of treatment, microsurgery may be used to remove or clip the shunt between the feeding artery and draining vein (60). During microsurgical resection and clipping, the following two operative techniques can be used: First, an en bloc DAVF and parent sinus resection can be performed to treat a sinus DAVF; second, selective arteriovenous disconnection may be used to treat cortical DAVFs with direct leptomeningeal venous drainage (24). When treatments are performed that do not include resection of the involved sinuses, they do not consistently cure the pathology, thus, the first method is recommended (23).

Microsurgical resection is a higher risk method compared with endovascular embolization as it is difficult to expose the DAVF and may result in blood loss (60). For DAVFs with a deep-seated location, such as the tentorium or sigmoid sinus, the operation may be complex and associated with high risk (61). Although the operation is difficult, a detailed operating plan and appropriate case choice may achieve a satisfactory outcome. Indeed, success with this method has been observed in previous decades: In 1986, Al-Mefty *et al* (62) treated a pediatric case of extensive DAVF of the sigmoid sinus and bilateral occlusion of the transverse sinus using microsurgery, and the prognosis was acceptable.

**Radiation therapy.** Radiation therapy is considered a safe and effective method, and may serve substantial role, in the treatment of DAVFs that involve a large dural sinus. In these cases, isolated use of radiosurgery has been described (63). Thus, for intracranial MDAVFs, certain DAVFs with a low Borden/Cognard classification or residual lesions following a prior resection or endovascular treatment may be treated using radiation therapy (64). As using radiation to obliterate DAVFs generally requires a 1 to 3-year treatment regimen, it is important to treat the most unstable fistulas first using endovascular or surgical approaches to avoid intracranial hemorrhage (65).

**Combined therapy.** As several locations are involved in MDAVFs, which have a complex angioarchitecture and hemodynamics and may be associated with pial AVFs, it is difficult to resolve all fistulas using a single method (15). A combination of approaches including endovascular treatment, microsurgery and stereotactic radiosurgery typically achieves the most effective outcomes (3). For instance, a combined

strategy was used by Mitsuhashi *et al* (10) to treat a 70-year-old man with MDAVFs involving the superior sagittal sinus and bilateral transverse-sigmoid sinuses, and an occlusion of the right jugular vein. They first surgically isolated the superior sagittal sinus, then performed a transvenous embolization in the right transverse-sigmoid sinus DAVF, and finally performed Gamma Knife radiosurgery to remove the residual DAVFs. The patient's symptoms including headache and tinnitus improved following the treatments (10). Therefore, a combined treatment regimen should be recommended.

**Other approaches.** When aggressively treating intracranial MDAVFs, it is important to consider that certain low-flow DAVFs may spontaneously heal or exhibit changed patterns on follow-up DSA (30). Thus, persistent low-risk lesions without retrograde cortical venous drainage do not consistently require treatment (66). Furthermore, in addition to blocking the fistulas using a transarterial or transvenous route, dredging is also a viable strategy. Vilela *et al* (27) described a 5-year-old patient with MDAVFs presenting with status epilepticus resulting from severe venous congestive encephalopathy, as well as an occlusion in the right sigmoid sinus, an absence of cavernous sinuses and substantial stenosis in the left sigmoid sinus-jugular bulb. Venous sinus angioplasty and stent placement were performed, and the child recovered without neurological deficit (27). For intracranial MDAVFs with sinus thrombosis, anticoagulatory therapy may also be attempted (42).

## 8. Prognosis

If intracranial MDAVFs are left untreated, the angiographic and clinical prognoses are poor (9). Generally, appropriate treatment leads to marked improvement or even complete resolution of encephalopathy and neurological deficits and improved cognition (30). For instance, Abe *et al* (44) reported a 67-year-old female who presented with intracranial MDAVFs that manifested as dementia, which rapidly progressed over 2 months. Following treatment, the dementia had been resolved, and the patient remained in stable condition without recurrence. However, when brain circulation decompensates or the MDAVFs are resistant to treatment, even the most appropriate treatments are unable to block progression, and satisfactory outcomes are unattainable. This was demonstrated by Friedman *et al* (67), who treated a 31-year-old man presenting with intracranial MDAVFs after trauma, the patient underwent more than 20 treatments, including transarterial embolization, transvenous embolization, stereotactic radiosurgery and craniotomy; however, the MDAVFs continued to progress, and the patient succumbed to the disease following a course of almost 5 years. In certain cases, despite treatments for intracranial MDAVFs achieving satisfactory effects, MDAVFs may recur. For instance, Mirza and Fraser (17) treated a 24-year-old patient presenting with MDAVFs, and after 2 months of radiation therapy, one of the DAVFs recurred; however, after 6 months of therapy, no recurrence was detected. When considering the potential recurrence of a DAVF, a transvenous approach may be effective, as sinus occlusion may be associated with the progression of DAVFs (68).



## 9. Conclusion

Intracranial MDAVFs are a challenge for neurosurgeons due to potential undetermined factors involved. Intracranial MDAVFs may be divided into synchronous-type and metachronous-type. At present, the pathogenesis underlying MDAVF development is not well understood. Intracranial MDAVFs run a malignant clinical course, and patients generally experience symptoms that rapidly progress following onset. A number of imaging techniques may be used to detect MDAVFs, including CT, MRI, DSA and SPECT. Of these, CT and MRI provide information regarding brain morphology, SPECT provides information regarding brain blood flow, and DSA is currently the gold standard and may be used to evaluate angioarchitecture and hemodynamics. MDAVFs should be treated aggressively, and treatment should include endovascular embolization, surgical resection, radiosurgery and conservative methods, as combined treatments are typically required to achieve sufficient clinical outcome. Through administering appropriate and aggressive treatment regimens, neurological deficits and cognitive functions may be markedly improved.

## References

- Barnwell SL, Halbach VV, Dowd CF, Higashida RT, Hieshima GB and Wilson CB: Multiple dural arteriovenous fistulas of the cranium and spine. *AJNR Am J Neuroradiol* 12: 441-445, 1991.
- Ha SY, Kwon YS, Kim BM, Kim DI and Kim DJ: Clinical and angiographic characteristics of multiple dural arteriovenous shunts. *AJNR Am J Neuroradiol* 33: 1691-1695, 2012.
- van Dijk JM, TerBrugge KG, Willinsky RA and Wallace MC: Multiplicity of dural arteriovenous fistulas. *J Neurosurg* 96: 76-78, 2002.
- Fujita A, Nakamura M and Tamaki N: Multiple dural arteriovenous fistulas involving both the cavernous sinus and the posterior fossa: Report of two cases and review of the literature. *No Shinkei Geka* 29: 1065-1072, 2001.
- Folkman J: Successful treatment of an angiogenic disease. *N Engl J Med* 320: 1211-1212, 1989.
- Yu J, Lv X, Li Y and Wu Z: Therapeutic progress in pediatric intracranial dural arteriovenous shunts: A review. *Interv Neuroradiol* 22: 548-556, 2016.
- Fudaba H, Kubo T, Goda M, Sugita K, Morishige M, Onishi K, Ishii K, Anan M, Nagai Y and Fujiki M: The Potentiality for development of multiple dural arteriovenous fistulas after ligation of the internal jugular vein. A case report. *NMC Case Rep J* 4: 71-73, 2017.
- Oh SJ, Chon YI, Kong SK and Goh EK: Multiple dural arteriovenous fistulas presenting as pulsatile tinnitus treated with external manual compression. *J Audiol Otol* 21: 156-159, 2017.
- Martinez-Burbano B, Correa Diaz EP and Jácome Sánchez C: Evolutionary history of multiple dural fistula. *J Investig Med High Impact Case Rep* 4: doi: 10.1177/2324709616683722, 2016.
- Mitsuhara T, Ikawa F, Ohbayashi N, Shirozu H, Abiko M and Ichinose N: A case of multiple dural arteriovenous fistulas treated by multiple modalities. *No Shinkei Geka* 39: 575-580, 2011.
- Shankar JJ, Karel Terbrugge and Krings T: Multiple spinal and cranial dural arteriovenous fistulas. *J Neurosurg Spine* 15: 113-116, 2011.
- Spittau B, Millán DS, El-Sherifi S, Hader C, Singh TP, Motschall E, Vach W, Urbach H and Meckel S: Dural arteriovenous fistulas of the hypoglossal canal: Systematic review on imaging anatomy, clinical findings, and endovascular management. *J Neurosurg* 122: 883-903, 2015.
- Kubota Y, Ueda T, Kaku Y and Sakai N: Development of a dural arteriovenous fistula around the jugular valve after transvenous embolization of cavernous dural arteriovenous fistula. *Surg Neurol* 51: 174-176, 1999.
- Rahmanian A, Farrokhi MR, Alibai EA and Masoudi MS: Multiple intracranial dural arteriovenous fistula. *J Res Med Sci* 18: 360-362, 2013.
- Minamide H, Hayashi Y and Uchiyama N: Multiple tentorial dural arteriovenous fistulas with acquired pial arteriovenous fistula presented with unilateral eye symptoms successfully treated by transarterial embolization and direct surgery. A case report. *No Shinkei Geka* 45: 239-245, 2017.
- Kusaka N, Sugiura K, Katsumata A, Nakashima H, Tamiya T and Ohmoto T: The importance of venous hypertension in the formation of dural arteriovenous fistulas: A case report of multiple fistulas remote from sinus thrombosis. *Neuroradiology* 43: 980-984, 2001.
- Mirza FA and Fraser JF: Multiple dural and pial arteriovenous fistulae in a twenty-four-year-old woman in the setting of superior sagittal sinus thrombosis: Case report and review of literature. *J Stroke Cerebrovasc Dis* 25: e192-e199, 2016.
- Nishijima M, Takaku A, Endo S, Kuwayama N, Koizumi F, Sato H and Owada K: Etiological evaluation of dural arteriovenous malformations of the lateral and sigmoid sinuses based on histopathological examinations. *J Neurosurg* 76: 600-606, 1992.
- Saito A, Takahashi N, Furuno Y, Kamiyama H, Nishimura S, Midorikawa H and Nishijima M: Multiple isolated sinus dural arteriovenous fistulas associated with antithrombin III deficiency. A case report. *Neurol Med Chir (Tokyo)* 48: 455-459, 2008.
- Desal HA, Lee SK, Kim BS, Raoul S, Tymianski M and TerBrugge KG: Multiple de novo vascular malformations in relation to diffuse venous occlusive disease. A case report. *Neuroradiology* 47: 38-42, 2005.
- Matsubara S, Satoh K, Satomi J, Shigeikiyo T, Kinouchi T, Miyake H and Nagahiro S: Acquired pial and dural arteriovenous fistulae following superior sagittal sinus thrombosis in patients with protein S deficiency: A report of two cases. *Neurol Med Chir (Tokyo)* 54: 245-252, 2014.
- Sugiura Y, Miyamoto T, Takehara S, Sumiya K and Nozaki T: Multiple dural arteriovenous fistulas following extensive sinus thrombosis. A case report. *No Shinkei Geka* 24: 379-383, 1996.
- Aoun SG, Bendok BR and Batjer HH: Acute management of ruptured arteriovenous malformations and dural arteriovenous fistulas. *Neurosurg Clin N Am* 23: 87-103, 2012.
- Russell SM, Woo HH and Nelson PK: Transarterial wedged-catheter, flow-arrest, N-butyl cyanoacrylate embolization of three dural arteriovenous fistulae in a single patient. *Interv Neuroradiol* 9: 283-290, 2003.
- Chaloupka JC, Marx WF and Kallmes DF: Dural arteriovenous fistulas. *J Neurosurg* 94: 858-861, 2001.
- Bai Y, He C, Zhang H and Ling F: De novo multiple dural arteriovenous fistulas and arteriovenous malformation after embolization of cerebral arteriovenous fistula. A case report. *Childs Nerv Syst* 28: 1981-1983, 2012.
- Vilela P, Willinsky R and Terbrugge K: Treatment of intracranial venous occlusive disease with sigmoid sinus angioplasty and stent placement in a case of infantile multifocal dural arteriovenous shunts. *Interv Neuroradiol* 7: 51-60, 2001.
- Ushikoshi S, Kikuchi Y and Miyasaka K: Multiple dural arteriovenous shunts in a 5-year-old boy. *AJNR Am J Neuroradiol* 20: 728-730, 1999.
- Prats-Sánchez LA, Hervás-García JV, Becerra JL, Lozano M, Castaño C, Munuera J, Escudero D and García-Esperón C: Multiple intracranial arteriovenous fistulas in Cowden syndrome. *J Stroke Cerebrovasc Dis* 25: e93-e94, 2016.
- Gist TL, Rangel-Castilla L, Krishna C, Roman GC, Cech DA and Diaz O: Endovascular management of six simultaneous intracranial dural arteriovenous fistulas in a single patient. *J Neurointerv Surg* 6: e16, 2014.
- Li M, Lin N, Wu J, Liang J and He W: Multiple intracranial aneurysms associated with multiple dural arteriovenous fistulas and cerebral arteriovenous malformation. *World Neurosurg* 77: 398, 2012.
- Pascoe HM, Lui EH, Mitchell P and Gaillard F: Progressive subcortical calcifications secondary to venous hypertension in an intracranial dural arteriovenous fistula. *J Clin Neurosci* 39: 98-101, 2017.
- Borden JA, Wu JK and Shucart WA: A proposed classification for spinal and cranial dural arteriovenous fistulous malformations and implications for treatment. *J Neurosurg* 82: 166-179, 1995.
- Cognard C, Gobin YP, Pierot L, Bailly AL, Houdart E, Casasco A, Chiras J and Merland JJ: Cerebral dural arteriovenous fistulas: Clinical and angiographic correlation with a revised classification of venous drainage. *Radiology* 194: 671-680, 1995.



35. Dogan M, Kahraman AS, Firat C, Ak M, Yildirim O and Dogan DG: Multiple dural arteriovenous fistulas involving the cavernous sinus, transverse sinus, sigmoid sinus and spinal drainage: CT angiography findings in 14-year-old boy. *Eur Rev Med Pharmacol Sci* 16: 1305-1306, 2012.
36. Zeidman SM, Monsein LH, Arosarena O, Aletich V, Biafore JA, Dawson RC, Debrun GM and Hurko O: Reversibility of white matter changes and dementia after treatment of dural fistulas. *AJNR Am J Neuroradiol* 16: 1080-1083, 1995.
37. Iizuka Y, Rodesch G, Garcia-Monaco R, Alvarez H, Burrows P, Hui F and Lasjaunias P: Multiple cerebral arteriovenous shunts in children: Report of 13 cases. *Childs Nerv Syst* 8: 437-444, 1992.
38. Signorelli F, Gory B, Maduri R, Guyotat J, Pelissou-Guyotat I, Chirchiglia D, Riva R and Turjman F: Intracranial dural arteriovenous fistulas: A review of their current management based on emerging knowledge. *J Neurosurg Sci* 61: 193-206, 2017.
39. Serulle Y, Miller TR and Gandhi D: Dural arteriovenous fistulae: Imaging and management. *Neuroimaging Clin N Am* 26: 247-258, 2016.
40. Tsai LK, Liu HM and Jeng JS: Diagnosis and management of intracranial dural arteriovenous fistulas. *Expert Rev Neurother* 16: 307-318, 2016.
41. Awad IA, Little JR, Akarawi WP and Ahl J: Intracranial dural arteriovenous malformations: Factors predisposing to an aggressive neurological course. *J Neurosurg* 72: 839-850, 1990.
42. Mendonça N, Santos G, Duro D, Machado E, Goulão A and Santana I: Multiple dural arteriovenous fistulas presenting as rapidly progressive dementia. *Neurologist* 18: 130-132, 2012.
43. Netravathi M, Pal PK, Bharath RD and Ravishankar S: Intracranial dural arteriovenous fistula presenting as parkinsonism and cognitive dysfunction. *J Clin Neurosci* 18: 138-140, 2011.
44. Abe K, Okuda O, Ohishi H, Sonobe M and Arai H: Multiple dural arteriovenous fistulas causing rapid progressive dementia successfully treated by endovascular surgery. A case report. *Neurol Med Chir (Tokyo)* 54: 145-149, 2014.
45. Mejia P, Piedra LM and Merchan-Del Hierro X: Rapidly progressive dementia and parkinsonism associated to multiple dural arteriovenous fistulas. *Rev Neurol* 64: 214-218, 2017.
46. Takai K, Komori T and Taniguchi M: Microvascular anatomy of spinal dural arteriovenous fistulas: Arteriovenous connections and their relationships with the dura mater. *J Neurosurg Spine* 23: 526-533, 2015.
47. Hetts SW, Moftakhar P, Maluste N, Fullerton HJ, Cooke DL, Amans MR, Dowd CF, Higashida RT and Halbach VV: Pediatric intracranial dural arteriovenous fistulas: Age-related differences in clinical features, angioarchitecture, and treatment outcomes. *J Neurosurg Pediatr* 18: 602-610, 2016.
48. Alerhand S and Lay C: Spontaneous intracerebral hemorrhage. *Emerg Med Clin North Am* 35: 825-845, 2017.
49. Kunz WG, Schuler F, Sommer WH, Fabritius MP, Havla L, Meinel FG, Reiser MF, Ertl-Wagner B and Thierfelder KM: Wavelet-based angiographic reconstruction of computed tomography perfusion data: Diagnostic value in cerebral venous sinus thrombosis. *Invest Radiol* 52: 302-309, 2017.
50. Okamura A, Nakaoka M, Ohbayashi N, Yahara K and Nabika S: Intraoperative cone-beam computed tomography contributes to avoiding hypoglossal nerve palsy during transvenous embolization for dural arteriovenous fistula of the anterior condylar confluence. *Interv Neuroradiol* 22: 584-589, 2016.
51. Lescher S, Gehrlich S, Klein S and Berkefeld J: Time-resolved 3D rotational angiography: Display of detailed neurovascular anatomy in patients with intracranial vascular malformations. *J Neurointerv Surg* 9: 887-894, 2017.
52. Azuma M, Hirai T, Shigematsu Y, Kitajima M, Kai Y, Yano S, Nakamura H, Makino K, Iryo Y and Yamashita Y: Evaluation of intracranial dural arteriovenous fistulas: Comparison of unenhanced 3T 3D time-of-flight MR angiography with digital subtraction angiography. *Magn Reson Med Sci* 14: 285-293, 2015.
53. Willinsky R, Terbrugge K, Montanera W, Mikulis D and Wallace MC: Venous congestion: An MR finding in dural arteriovenous malformations with cortical venous drainage. *AJNR Am J Neuroradiol* 15: 1501-1507, 1994.
54. Ushikoshi S, Kikuchi Y, Houkin K, Saito H and Abe H: Multiple dural arteriovenous fistulas. *Neurol Med Chir (Tokyo)* 38: 478-484, 1998.
55. Fiumara E, Tumbiolo S, Bellomonte ML, Savatteri P, Finazzo F and La Gattuta F: Resection of the transverse sinuses and confluence of sinuses for treatment of multiple dural arteriovenous fistulas. A case report. *J Neurosurg* 100: 348-352, 2004.
56. Sato K, Matsumoto Y, Endo H and Tominaga T: A hemorrhagic complication after Onyx embolization of a tentorial dural arteriovenous fistula: A caution about subdural extension with pial arterial supply. *Interv Neuroradiol* 23: 307-312, 2017.
57. Luo CB, Chang FC and Teng MM: Update of embolization of intracranial dural arteriovenous fistula. *J Chin Med Assoc* 77: 610-617, 2014.
58. Watanabe T, Matsumaru Y, Sonobe M, Asahi T, Onitsuka K, Sugita K, Takahashi S and Nose T: Multiple dural arteriovenous fistulae involving the cavernous and sphenoparietal sinuses. *Neuroradiology* 42: 771-774, 2000.
59. Nakamura M, Tamaki N, Hara Y and Nagashima T: Two unusual cases of multiple dural arteriovenous fistulas. *Neurosurgery* 41: 288-292; discussion 292-283, 1997.
60. Lin N, Brouillard AM, Mokin M, Natarajan SK, Snyder KV, Levy EI and Siddiqui AH: Direct access to the middle meningeal artery for embolization of complex dural arteriovenous fistula: A hybrid treatment approach. *J Neurointerv Surg* 7: e24, 2015.
61. Vougioukas VI, Coulin CJ, Shah M, Berlis A, Hubbe U and Van Velthoven V: Benefits and limitations of image guidance in the surgical treatment of intracranial dural arteriovenous fistulas. *Acta Neurochir (Wien)* 148: 145-153, discussion 153, 2006.
62. Al-Mefty O, Jinkins JR and Fox JL: Extensive dural arteriovenous malformation. A case report. *J Neurosurg* 65: 417-420, 1986.
63. Yen CP, Lanzino G and Sheehan JP: Stereotactic radiosurgery of intracranial dural arteriovenous fistulas. *Neurosurg Clin N Am* 24: 591-596, 2013.
64. Dmytriw AA, Schwartz ML, Cusimano MD, Mendes Pereira V, Krings T, Tymianski M, Radovanovic I and Agid R: Gamma Knife radiosurgery for the treatment of intracranial dural arteriovenous fistulas. *Interv Neuroradiol* 23: 211-220, 2017.
65. Bertalanffy A, Dietrich W, Kitz K and Bavinzski G: Treatment of dural arteriovenous fistulae (dAVF's) at the superior sagittal sinus (SSS) using embolisation combined with micro- or radiosurgery. *Minim Invasive Neurosurg* 44: 205-210, 2001.
66. Kim DJ, terBrugge K, Krings T, Willinsky R and Wallace C: Spontaneous angiographic conversion of intracranial dural arteriovenous shunt: Long-term follow-up in nontreated patients. *Stroke* 41: 1489-1494, 2010.
67. Friedman JA, Meyer FB, Nichols DA, Coffey RJ, Hopkins LN, Maher CO, Meissner ID and Pollock BE: Fatal progression of posttraumatic dural arteriovenous fistulas refractory to multimodal therapy. A case report. *J Neurosurg* 94: 831-835, 2001.
68. Torok CM, Nogueira RG, Yoo AJ, Leslie-Mazwi TM, Hirsch JA, Stapleton CJ, Patel AB and Rabinov JD: Transarterial venous sinus occlusion of dural arteriovenous fistulas using ONYX. *Interv Neuroradiol* 22: 711-716, 2016.



This work is licensed under a Creative Commons Attribution-NonCommercial-NoDerivatives 4.0 International (CC BY-NC-ND 4.0) License.