

Identifying the association between interleukin-6 and lichen planus: A meta-analysis

MENG YIN¹, GUIFENG LI², HUI SONG¹ and SONG LIN³

¹School of Dentistry, Shandong University, Shandong Provincial Key Laboratory of Oral Tissue Regeneration, Jinan, Shandong 250014; ²Department of Orthodontics, Nanjing Stomatological Hospital, Nanjing, Jiangsu 210009
³Department of Pediatric Dentistry, Jinan Stomatological Hospital, Jinan, Shandong 250002, P.R. China

Received December 6, 2016; Accepted March 2, 2017

DOI: 10.3892/br.2017.887

Abstract. Numerous studies have examined the association between interleukin-6 and the pathogenesis of lichen planus (LP)/oral LP (OLP) in various populations; however, there is a lack of systematic analysis. The aim of the present study was to assess this association more precisely, thus a meta-analysis was performed. Case-control studies, which were published up to December 2015, were obtained from PubMed, Embase and the China National Knowledge Infrastructure databases. Data were extracted and pooled mean differences (MDs) with 95% confidence intervals (CIs) were calculated. Ultimately, eight studies were included, comprising 299 LP/OLP cases and 231 control subjects. Overall, the pooled MD for IL-6 was 16.24 (95% CI, 9.84-22.64; $I^2=99%$ for heterogeneity). In the subgroup analysis by ethnicity, a significant increase of the IL-6 expression level was identified among Asian individuals, but not in Caucasian individuals. Thus, IL-6 may be significant in the pathogenesis of LP. However, further studies are required to validate these associations.

Introduction

Lichen planus (LP) is a chronic inflammatory disease that affects the squamous cell layer, including the skin and mucosal membranes (1). Certain studies revealed that ~1.9% of the population affected by LP presented with LP confined to the oral cavity (termed oral LP; OLP) and women were the

susceptible population (63-70% of cases) (2). Degeneration of basal cells and infiltration of inflammatory cells into the subepithelial layer of connective tissue are regarded as the pathological characteristics of LP/OLP (3).

The aetiology and pathogenesis of LP are not fully understood, although it is widely agreed that immunological response is important in the process (4). Previous studies indicated that the subepithelial inflammatory infiltrate cells, which characterize LP/OLP were predominantly composed of T cells that locally present in the involved epithelium and under epithelial tissues (5). Most lymphocytes in the lamina propria are CD4⁺ T cell clones with helper activity, or CD4⁺ T cell clones that lack cytotoxic activity, while the majority of intraepithelial lymphocytes in LP/OLP are CD8⁺ T cells (6-9). Keratinocytes in LP/OLP submit major histocompatibility complex class II antigens to CD4⁺ T cells causing secretion of the cytokines, interleukin-2 (IL-2) and interferon- γ (INF- γ) that are associated with type 1 T helper cells. IL-2 and INF- γ in turn activate the CD8⁺ T cells leading to keratinocyte apoptosis via tumor necrosis factor- α (TNF- α) (10). TNF- α promotes the activation of nuclear factor- κ B in subepithelial T cells, and causes increased expression of proinflammatory cytokines, such as IL-6 (11-13).

IL-6 is a type of proinflammatory cytokine produced in LP lesions that exerts effects on humoral and cellular immunities. It promotes B cell differentiation, stimulates immunoglobulin G secretion, T cell growth and differentiation, and cytotoxic T cell differentiation (14). IL-6 is generated by activated monocytes, macrophages, endothelial cells, and activated T and B cells that respond to a variety of stimuli, including infection and trauma (15).

Numerous studies have identified that the IL-6 concentration in the serum of LP patients was higher than that in the healthy control subjects, particularly in the severe forms of LP. Furthermore, serum IL-6 concentrations were identified to be particularly valuable for monitoring disease activity and treatment response (15,16). However, there is currently a lack of systematic analysis between IL-6 and LP/OLP. Consequently, a meta-analysis of all eligible studies was performed in the present study to obtain a more precise analysis of the association between IL-6 and LP/OLP.

Correspondence to: Professor Hui Song, School of Dentistry, Shandong University, Shandong Provincial Key Laboratory of Oral Tissue Regeneration, 44-1 Wenhua Road, Jinan, Shandong 250014, P.R. China
E-mail: songhui@sdu.edu.cn

Dr Song Lin, Department of Pediatric Dentistry, Jinan Stomatological Hospital, 101 Jingliu Road, Jinan, Shandong 250002, P.R. China
E-mail: is196868@163.com

Key words: interleukin-6, lichen planus, oral lichen planus, meta-analysis

Materials and methods

Study identification and selection. To identify correlative literature, bibliographical searches were performed in the China National Knowledge Infrastructure (CNKI, <http://www.cnki.net>), PubMed (<http://www.ncbi.nlm.nih.gov/pubmed>) and Embase (<http://www.elsevier.com/solutions/embase-biomedical-research>) databases using the following terms: 'Lichen planus', 'oral lichen planus' and 'interleukin-6 (IL_6)'. The upper date was limited to 20 December 2015. The search was focused towards studies that had been conducted in humans. Full-text articles published in English and Chinese were included, and the most complete research and recent study was selected when one author had published various articles using the same patient data.

Inclusion criteria. The inclusion criteria of the current meta-analysis were as follows: i) IL-6 and the pathology of LP or OLP were evaluated; ii) case-control studies; iii) ELISA was used to determine serum IL-6 levels; iv) contained sufficient data.

Data extraction. The studies were reviewed by two investigators, disagreement around eligibility were resolved by discussion between the two investigators. The following details were obtained from each article: First author's name, publication date, ethnicity, sample numbers of cases and control subjects, and the IL-6 expression level in each group (mean \pm standard deviation; SD).

Statistical analysis. Mean differences (MDs) and SDs were used to summarize data with continuous outcomes. MDs with 95% confidence intervals (CIs) were used to determine the strength of the association between IL-6 and LP/OLP. The pooled MDs for the LP/OLP associated with IL-6 were calculated. Subgroup analyses were performed by ethnicity. Heterogeneity assumptions were assessed using the I^2 test and an I^2 value $<50\%$ indicated a lack of heterogeneity among the studies. Therefore, the pooled odds ratio estimate of each study was calculated using the fixed-effects model (17) or the random-effects model was used (18). All statistical analyses for the current study were performed using RevMan 5.3 software (Cochrane Collaboration; <http://www.cochrane-net.org/revman>).

Results

Study characteristics. A total of eight studies involving 299 LP/OLP cases and 231 control subjects met the inclusion criteria and were analyzed (12,13,19-24). The authors and year of publication, country, ethnicity of the study populations, and subtypes of OLP and LP were included. The number of cases and control subjects in each study are presented in Table I. Of the eight publications, five comparisons were performed in Asian individuals (13,20,22-24) and three were in Caucasian individuals (19,12,21). One study was performed among LP patients (21), five were performed in OLP patients (12,20,22-24), while two were performed in mixed LP disease (the patients that have both skin and oral mucosal lesions) (13,19). Of all the OLP patients, four studies referred to erosive OLP (EOLP)

and none EOLP (NEOLP) (13,22-24), one study referred to EOLP (20) and one to NEOLP (12).

Meta-analysis. The heterogeneity for the eight comparisons were analyzed (Fig. 1). The I^2 value was 99% ($P<0.00001$), indicating the presence of heterogeneity. Therefore, the random-effects model was selected to synthesize the data and the MD was 16.24 (95% CI=9.84-22.64). The outcomes indicate that the serum IL-6 concentrations were statistically higher in the LP patients when compared with those in the healthy group.

Subgroup analysis. Subgroup analyses were performed according to ethnicity (Fig. 2). A significantly increased level of IL-6 (MD=26.48, 95% CI=11.73-41.23; $P=0.0004$) was identified among Asian individuals, while no significant increase among Caucasian individuals was observed (MD=1.01, 95% CI=-0.78-2.79; $P=0.27$).

Publication bias. A funnel plot was constructed and Egger's test was performed to assess the publication bias of the studies. The funnel plots (Fig. 3) demonstrated marked asymmetry. These results indicate that there was publication bias in the current meta-analysis.

Discussion

IL-6 is a type of cytokine that has multiple functions. Numerous types of cell, including macrophage cells, neutrophils and fibroblasts synthesize IL-6 in response to stimulation, such as infection and trauma (25,26). IL-6 cell signals are sent through a receptor expressed in various types of cells that stimulate numerous biological progresses, including antibody and autoantibody production, T cell activation, B cell differentiation and acute-phase protein augmentation (27,28). As a result of the IL-6 versatility, the differences in synthesizing and releasing IL-6 may regulate the susceptibility, development, and progression of autoimmune and inflammatory diseases due to the individual variability (29-32). According to a previous study, many common oral diseases, such as periodontal diseases, LP and oral cancer are associated with IL-6 deregulation (33).

LP is a chronic inflammatory mucocutaneous disorder with unknown etiology (34). Clinical and immunohistochemical studies strongly support the role of immune deregulation in the pathogenesis of LP. Dysregulation specifically involves the cellular immune system and a complex cytokine network (35-37). Cytokines are a type of low-weight soluble protein produced by different cells in the innate and adaptive immune system. They transmit signals through receptors on the cell surface to activate, differentiate or mature immune cells, and are important in the activation and modulation of the immune system (38). Therefore, levels of ILs in lesions, saliva and serum of LP patients are considered to be a credible indicator of therapeutic reactions on a molecular basis (15,36,39).

Certain studies identified an increased serum IL-6 level in LP patients when compared with control groups (24,40,41). In addition, a decreased serum IL-6 concentration was identified in LP patients subsequent to therapy (36). Furthermore, it has

Table I. Characteristics of the eight case-control studies included in the current meta-analysis.

Author, year	Country study was performed in	Ethnicity of population	Disease	Type	Age (year)		Cases/controls (n)	Analysis Method	Analysis (Refs.)
					Case	Control			
Abdel-Haq, 2014	Poland	Caucasian	LP, OLP	-	52±15	41±13	56/56	ELISA	(19)
Zhang, 2008	China	Asian	LP, OLP	Mixed LP	54±17	40±16	30/30	ELISA	(13)
Gu, 2004	America	Caucasian	OLP	NEOLP	61.4±9.0	62.5±8.8	10/30	ELISA	(12)
Goel, 2015	India	Asian	OLP	EOLP	46.95±11.96	-	42/10	ELISA	(20)
Toruniowa, 1995	Poland	Caucasian	LP	-	-	-	20/14	ELISA	(21)
Zhang, 2004	China	Asian	OLP	Mixed OLP	40±10	39±11	60/30	ELISA	(22)
Wang, 2014	China	Asian	OLP	Mixed OLP	45.8±13.4	44.8±12.8	50/50	ELISA	(23)
Su, 2014	China	Asian	OLP	Mixed OLP	-	-	31/31	ELISA	(24)

LP, lichen planus; OLP, oral LP; EOLP, erosive OLP; NEOLP, none EOLP.

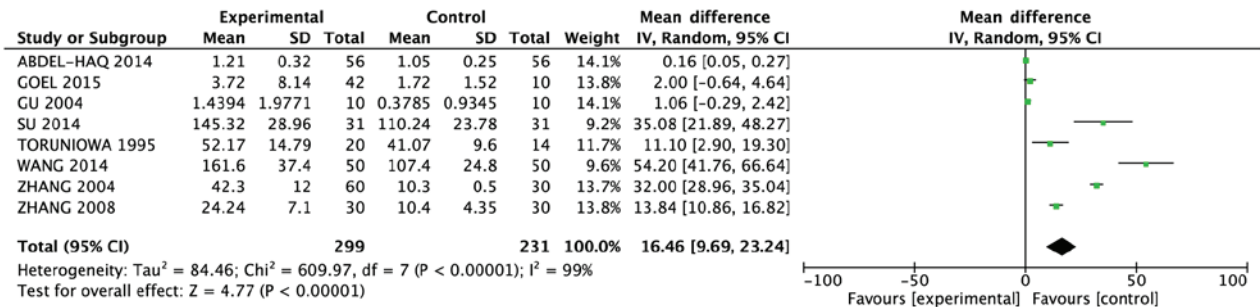


Figure 1. Meta-analysis with a random-effects model for the association between lichen planus and interleukin-6 concentration levels. SD, standard deviation; CI, confidence interval.

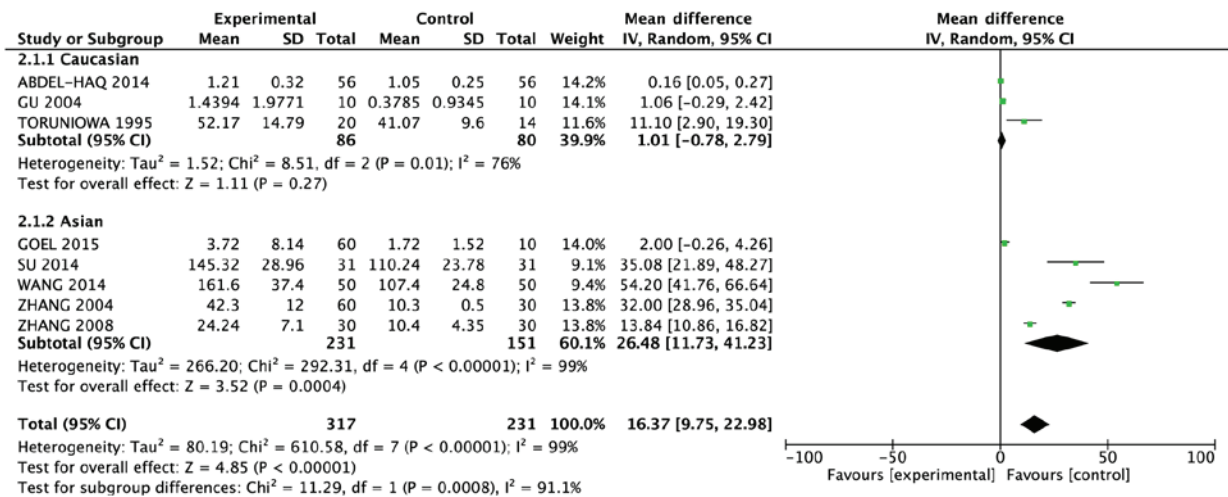


Figure 2. Subgroup analysis by ethnicity. SD, standard deviation; CI, confidence interval.

been found that higher salivary IL-6 levels may primarily be due to keratinocytes, tissue-infiltrating mononuclear cells and fibroblasts of LP lesions. The elevated serum IL-6 concentration may primarily due to peripheral blood mononuclear cells (PBMCs) and endothelial cells. The locally secreted IL-6 may diffuse into blood capillaries or be drained into the lymphatic

vessels, which finally empty into the blood circulation. Together, the locally secreted IL-6 and the systemically produced IL-6 by PBMCs and endothelial cells are the possible reason for the elevated serum IL-6 concentration in LP patients (15).

In the current study, a distinct association between the concentrations of IL-6 and LP was identified during the

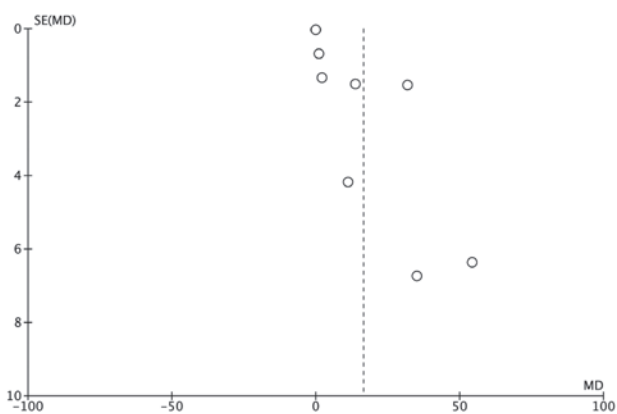


Figure 3. Funnel plot to establish publication bias in the selection of studies. SE, standard error; MD, mean difference.

total combined analysis. These results indicated that the IL-6 serum levels were significantly higher in patients with LP/OLP than in the control group patients. When stratified according to ethnicity, the Asian patients demonstrated significantly increased serum levels of IL-6, while no significant increase was observed among the Caucasian individuals.

There were certain limitations of the present meta-analysis. Firstly, although the publications were carefully searched, definite criteria were set, and strict data extraction and analysis were performed to minimize the likelihood of heterogeneity, it existed in almost every comparison. Only published studies were included in the current analysis, while the negative or non-significant findings were ignored. This may have contributed to the publication bias. However, the limited number of studies included in the investigation together with the small sample sizes may have resulted in an insufficient ability to evaluate a statistically significant effect. Furthermore, subgroup analysis eliminated age, gender, and other factors due to the impossibility of extracting relevant data from primary publications. In addition, certain associated studies may have been neglected, as only publications written in Chinese and English were selected from the chosen databases. Consequently, the outcome of the current meta-analysis should be explicated carefully. Future studies that incorporate age, gender, and other factors may provide further information for confirming the underlying mechanism of IL-6 in LP.

Despite the above-mentioned limitations, the current study indicates that IL-6 is associated with the pathogenesis of LP. The concentration level of IL-6 was increased in LP patients from the Asian population, although no significant associations were observed in Caucasian populations. Large sample studies using standardized, unbiased methods and well-matched controls are required in the future.

Acknowledgements

The present study was supported by the Natural Science Foundation of Shandong Province (grant no. ZR2015HM019) and the Science and Technology Development Plan of Shandong Province (grant no. 2010GSF10270).

References

- Carrozzo M, Uboldi de Capei M, Dametto E, Fasano ME, Arduino P, Broccoletti R, Vezza D, Rendine S, Curtoni ES and Gandolfo S: Tumor necrosis factor-alpha and interferon-gamma polymorphisms contribute to susceptibility to oral lichen planus. *J Invest Dermatol* 122: 87-94, 2004.
- Silverman S Jr, Bahl S: Oral lichen planus update: Clinical characteristics, treatment response, and malignant transformation. *Am J Dent* 10: 259-263, 1997.
- Boyd AS and Nelder KH: Lichen planus. *J Am Acad Dermatol* 25: 593-619, 1991.
- Payeras MR, Cherubini K, Figueiredo MA and Salum FG: Oral lichen planus: Focus on etiopathogenesis. *J Oral Biol* 58: 1057-1069, 2013.
- Lodi G, Scully C, Carrozzo M, Griffiths M, Sugerman PB and Thongprasom K: Current controversies in oral lichen planus: Report of an international consensus meeting. Part 2. Clinical management and malignant transformation. *Oral Surg Oral Med Oral Pathol Oral Radiol Endod* 100: 164-178, 2005.
- Matthews JB, Scully CM and Potts AJ: Oral lichen planus: An immunoperoxidase study using monoclonal-antibodies to lymphocyte subsets. *Br J Dermatol* 111: 587-595, 1984.
- Ishii T: Immunohistochemical demonstration of T cell subsets and accessory cells in oral lichen planus. *J Oral Pathol* 16: 356-361, 1987.
- Kilpi AM, Rich AM, Radden BG and Reade PC: Direct immunofluorescence in the diagnosis of oral mucosal diseases. *Int J Oral Maxillofac Surg* 17: 6-10, 1988.
- Sugerman PB, Savage NW and Seymour GJ: Phenotype and suppressor activity of T-lymphocyte clones extracted from lesions of oral lichen planus. *Br J Dermatol* 131: 319-324, 1994.
- Roopashree MR, Gondhalekar RV, Shashikanth MC, George J, Thippeawamy SH and Shukla A: Pathogenesis of oral lichen planus-a review. *J Oral Pathol Med* 39: 729-734, 2010.
- Sugerman PB, Satterwhite K and Bigby M: Autocytotoxic T-cell clones in lichen planus. *Br J Dermatol* 142: 449-456, 2000.
- Gu GM, Martin MD, Darveau RP, Truelove E and Epstein J: Oral and serum IL-6 levels in oral lichen planus patients. *Oral Surg Oral Med Oral Pathol Oral Radiol Endod* 98: 637-678, 2004.
- Zhang Y, Lin M, Zhang S, Wang Z, Jiang L, Shen J, Bai J, Gao F, Zhou M and Chen Q: NF-kappaB-dependent cytokines in saliva and serum from patients with oral lichen planus: A study in an ethnic Chinese population. *Cytokine* 41: 144-149, 2008.
- Hibi M, Nakajima K and Hirano T: IL-6 cytokine family and signal transduction: A model of the cytokine system. *J Mol Med (Berl)* 74: 1-12, 1996.
- Sun A, Chia JS, Chang YF and Chiang CP: Serum interleukin-6 level is a useful marker in evaluating therapeutic effects of levamisole and Chinese medicinal herbs on patients with oral lichen planus. *J Oral Pathol Med* 31: 196-203, 2002.
- Rhodus NL, Cheng B, Bowles W, Myers S, Miller L and Ondery F: Proinflammatory cytokine levels in saliva before and after treatment of (erosive) oral lichen planus with dexamethasone. *Oral Dis* 12: 112-116, 2006.
- Mantel N and Haenszel W: Statistical aspects of the analysis of data from retrospective studies of disease. *J Natl Cancer Inst* 22: 719-748, 1959.
- DerSimonian R and Laird N: Meta-analysis in clinical trials. *Contemp Clin Trials* 45: 139-145, 2015.
- Abdel-Haq A, Kusnierz-Cabala B, Darczuk D, Sobuta E, Dumnicka P, Wojas-Pelc A and Chomyszyn-Gajewska M: Interleukin-6 and neopterin levels in the serum and saliva of patients with lichen planus and oral lichen planus. *J Oral Pathol Med* 43: 734-739, 2014.
- Goel S, Marwah A, Kaushik S, Garg VK and Gupta S: Role of serum interleukin-6 in deciding therapy for multidrug resistant oral lichen planus. *J Clin Exp Dent* 7: e477-e482, 2015.
- Toruniowa B, Krasowska D, Kozioł M, Książek A and Pietrzak A: Serum levels of IL-6 in Mycosis Fungoides, Psoriasis, and lichen planus. *Ann N Y Acad Sci* 762: 432-434, 1995.
- Zhang Z, Zhang Q, Wang Y and Zhang W: Correlations between serum levels of interleukin-2, interleukin-4, interleukin-6 and clinical symptoms in patients with oral lichen planus. *J Dent Prev Treat* 12: 96-98, 2004 (In Chinese).
- Wang YM, Fu S, Zhou B, Wang C and Zhou J: Analysis of Th1/Th2 in the use of hormone therapy in patients with OLP when T cell response patterns and correlation. *Chin J Front Med Sci (Electronic Version)* 6: 30-33, 2014 (In Chinese).

24. Kui SU and Hong Xu: The effects of thymopeptides enteric-coated tablets on oral lichen planus and the expression of related cytokines. *J Pract Stomatol* 30: 429-431, 2014.
25. Kishimoto T, Akira S, Narazaki M and Taga T: Interleukin-6 family of cytokines and Gp130. *Blood* 86: 1243-1254, 1995.
26. Matsuki Y, Yamamoto T and Hara K: Detection of inflammatory cytokine messenger-RNA (mRNA)-expressing cells in human inflamed gingiva by combined in situ hybridization and immunohistochemistry. *Immunology* 76: 42-47, 1992.
27. Hirano T, Matsuda T, Turner M, Miyasaka N, Buchan G, Tang B, Sato K, Shimizu M, Maini R, Feldmann M, *et al*: Excessive production of interleukin 6/B cell stimulatory factor-2 in rheumatoid arthritis. *Eur J Immunol* 18: 1797-1801, 1988.
28. Ridker PM, Cushman M, Stampfer MJ, Tracy RP and Hennekens CH: Inflammation, aspirin, and the risk of cardiovascular disease in apparently healthy men. *N Engl J Med* 336: 973-979, 1997.
29. Moreau P, Harousseau JL, Wijdenes J, Morineau N, Milpied N and Bataille R: A combination of anti-interleukin 6 murine monoclonal antibody with dexamethasone and high-dose melphalan induces high complete response rates in advanced multiple myeloma. *Br J Haematol* 109: 661-664, 2000.
30. Park MC, Lee SW, Choi ST, Park YB and Lee SK: Serum leptin levels correlate with interleukin-6 levels and disease activity in patients with ankylosing spondylitis. *Scand J Rheumatol* 36: 101-106, 2007.
31. Packard RR and Libby P: Inflammation in atherosclerosis: From vascular biology to biomarker discovery and risk prediction. *Clin Chem* 54: 24-38, 2008.
32. Nishimoto N: Interleukin-6 as a therapeutic target in candidate inflammatory diseases. *Clin Pharmacol Ther* 87: 483-487, 2010.
33. Nibali L, Fedele S, D'Aiuto F and Donos N: Interleukin-6 in oral diseases: A review. *Oral Dis* 18: 236-243, 2012.
34. Agha-Hosseini F, Mirzaii-Dizgah I, Mikaili S and Abdollahi M: Increased salivary lipid peroxidation in human subjects with oral lichen planus. *Int J Dent Hyg* 7: 246-250, 2009.
35. Hu JY, Zhang J, Cui JL, Liang XY, Lu R, Du GF, Xu XY and Zhou G: Increasing CCL5/CCR5 on CD4+ T cells in peripheral blood of oral lichen planus. *Cytokine* 62: 141-145, 2013.
36. Agha-Hosseini F and Mirzaii-Dizgah I: p53 as a neoplastic biomarker in patients with erosive and plaque like forms of oral lichen planus. *J Contemp Dent Pract* 14: 1-3, 2013.
37. Agha-Hosseini F, Mirzaii-Dizgah I, Farmanbar N and Abdollahi M: Oxidative stress status and DNA damage in saliva of human subjects with oral lichen planus and oral squamous cell carcinoma. *J Oral Pathol Med* 41: 736-740, 2012.
38. Postal M and Appenzeller S: The role of Tumor Necrosis Factor-alpha (TNF- α) in the pathogenesis of systemic lupus erythematosus. *Cytokine* 56: 537-543, 2011.
39. Nibali L, Fedele S, D' Aiuto F and Donos N: Interleukin-6 in oral disease: A review. *Oral Dis* 18: 236-243, 2012.
40. Yamamoto T, Yoneda K, Ueta E and Osaki T: Serum cytokines, interleukin-2 receptor, and soluble intercellular adhesion molecule-1 in oral disorders. *Oral Surg Oral Med Oral Pathol* 78: 727-735, 1994.
41. Karagouni EE, Dotsika EN and Sklavounou A: Alteration in peripheral blood mononuclear cell function and serum cytokines in oral lichen planus. *J Oral Pathol Med* 23: 28-35, 1994.