SPANDIDOS PUBLICATIONS

BIOMEDICAL REPORTS 21: 163, 2024

Acute organic solvent toxic encephalopathy: A case report and literature review

YINJIAO WANG and PENG DU

Department of Radiology, The Second Affiliated Hospital of Xuzhou Medical University, Xuzhou, Jiangsu 221000, P.R. China

Received July 3, 2024; Accepted August 5, 2024

DOI: 10.3892/br.2024.1851

Abstract. Organic solvents are a class of volatile, lipophilic substances that can easily enter the human body through skin and mucous membrane contact as well as air inhalation, and can lead to toxic encephalopathy (TE), especially after entering the lipid-rich nervous system. The present case reports a patient with acute organic solvent toxic encephalopathy (AOSTE), which may have been caused by occasional ink leakage from Xuzhou (Jiangsu, China). By summarizing the history the patient to exposure to organic solvents, clinical manifestations, radiology findings and relevant laboratory tests, we hypothesize that a history of ink exposure, brain magnetic resonance imaging findings and hippuric acid testing were indispensable factors in the diagnosis of AOSTE. After neurological treatment, the patient experienced notable improvement in symptoms. The present study reports on its clinical features, imaging features, treatment and follow-up, and review relevant literature to summarize its clinical experience, hoping to improve our understanding of AOSTE.

Introduction

Toxic encephalopathy (TE) is a type of disease that results from long-term or excessive exposure to toxic substances, causing damage to the central nervous system. Diffuse white matter lesions and myelin sheath destruction are the main pathological manifestations. Acute organic solvent toxic encephalopathy (AOSTE) usually onsets within days or weeks (1). On magnetic resonance imaging (MRI) images, acute and subacute OSTE are mainly characterized by bilateral symmetrical diffuse involvement of white matter areas, basal ganglia and dentate nuclei. Some cases may involve cerebellar white matter and the brainstem, and some severe cases can manifest as whole brain swelling, shallow cerebral sulcus, extensive symmetrical white matter edema and an unclear gray white matter boundary (2,3).

Early diagnosis and treatment play a significant role in improving the prognosis of AOSTE patients. Due to the lack of effective treatments, the prevention of OSTE is particularly significant. It is necessary to further improve occupational health laws and regulations, strictly control the exposure of harmful substances in the production environment, and improve the on-site working environment (4). The present study reports on the diagnosis and treatment processes of a patient with AOSTE, which may have been caused by occasional ink leakage (Xuzhou, Jiangsu China), and conducted a combined literature review analysis to provide reference for the diagnosis and treatment of this disease.

Case description

A 42-year-old male patient from Xuzhou (Jiangsu, China), visited The Second Affiliated Hospital of Xuzhou Medical University (Xuzhou, China) in April 2023, due to sudden dizziness with unstable walking for 24 h, which was aggravated for 2 h. The patient experienced dizziness 24 h ago during work with no apparent reason, accompanied by unstable walking, leaning to one side while walking and symptoms such as slow reaction and limb weakness. The patient has been engaged in handling work in a printing factory for 3 years and did not come into contact with printing ink on weekdays, so he was not classified as a toxic worker. The patient was in good health, with no history of infectious disease, surgery, blood transfusion or family history.

Neurological examination on admission: Clear mind, slow reaction, decreased intelligence and lack of cooperation in physical examination; bilateral Babinski sign was not extracted, Romberg sign was not cooperating, finger-nose test was accurate, neck was soft and Kernig sign was negative.

Electroencephalogram (EEG) examination: Numerous paroxysmal medium-to-high amplitude θ waves in all leads.

Laboratory examination: Serum amyloid protein A, >200.00 mg/l (reference range, <10.00); D-dimer, 457.00 ng/ml (reference range, 0.00-243.00); alanine aminotransferase, 159 U/l (reference range, ≤55.00); aspartate aminotransferase, 67 U/l (reference range, 5.00-34.00); R-glutamyltransferase, 168 U/l (reference range, 10.00-50.00); Urocholenogen (++); hippuric acid (HA), 1,700 μg/ml (reference range, 40.00-70.00);

Correspondence to: Professor Peng Du, Department of Radiology, The Second Affiliated Hospital of Xuzhou Medical University, 32 Meijian Road, Xuzhou, Jiangsu 221000, P.R. China
E-mail: dupeng0516@126.com

Key words: toxic encephalopathy, acute organic solvent toxic encephalopathy, neurological damage, central nervous system, white matter lesions, occupational health, case report

blood routine (-); tumor markers (-); serum Li, 1.60 μg/l (reference range, 0.00-72.00); Mg, 1.72 mmol/l (reference range, 1.12-2.06); Ca, 1.68 mmol/l (reference range, 1.50-2.50); Mn, 14.98 μg/l (reference range, 3.00-36.00); Fe, 7.29 mmol/l (reference range, 4.91-9.47); Cu, 22.11 μmol/l (reference range, 6.30-28.35); Zn, 99.20 μmol/l (reference range, 47.33-103.00); Se, 127.81 μg/l (reference range, 69.01-147.00); Cd, 1.77 μg/l (reference range, 0.00-5.00); Hg, 1.69 μg/l (reference range, 0.00-14.90); Pb, 15.58 μg/l (reference range, 0.00-100.00); V, 0.76 μg/l (reference range, 0.00-5.00); Cr, 1.04 μg/l (reference range, 0.00-10.00); Co, 0.19 μg/l (reference range, 0.00-3.00); As, 0.75 μg/l (reference range, 0.00-23.00); Sr, 17.68 μg/l (reference range, 10.00-45.00); Mo, 0.89 μg/l (reference range, 0.00-3.30).

Radiological examination: Non-contrast brain computed tomography (2023-04) revealed multiple ill-defined symmetrical patchy low-density shadows in bilateral basal ganglia, bilateral frontal parietal temporal occipital white matter areas and bilateral cerebellar dentate nuclei. Non-contrast brain MRI (2023-04) revealed the presence of multiple symmetrical patchy T1-weighted imaging (T1WI) hypo-intensity, T2-weighted imaging (T2WI) hyper-intensity, T2-fluid attenuated inversion recovery hyper-intensity, diffusion-weighted imaging (DWI) hyper-intensity, with blurred edges, in bilateral basal ganglia (outer capsule and globus pallidus), thalamus, frontal parietal temporal occipital white matter area and bilateral cerebellar dentate nuclei (Fig. 1).

Based on the symptoms and signs, laboratory examinations and radiological examinations of the patient, a preliminary diagnosis of TE was made. As disclosed by the supervisor of the patient's printing factory, ink leakage may occurred recently in the printing house due to reasons like machine aging. The ink composition was as follows: 30% polyurethane resin liquid, 30% titanium dioxide, 10% ternary chlorine resin liquid, 7% isopropyl alcohol, 7% n-propyl acetate and 16% ethyl acetate. Combined with an abnormally elevated HA on urinalysis, the patient was ultimately diagnosed with AOSTE.

The patient received the following treatment measures, including: i) Hyperbaric oxygen therapy to increase blood oxygen levels; ii) dehydration of mannitol and glycerol fructose to reduce intracranial pressure; iii) antioxidants to protect the brain and nerve cells and promote brain function recovery; iv) high dose B vitamins to nourish nerves; v) Butylphthalide to improve mitochondrial metabolism, and Edaravone to eliminate free radicals; vi) antibiotics to prevent secondary infections; and vii) potassium chloride and sodium chloride to maintain water electrolyte and acid-base balance.

Non-contrast brain MRI (2023-04) revealed reductions in the extent of the abnormal signal in the brain and in the DWI intensity of the lesion compared with the MRI performed on 2023-04 (Fig. 2). After 14 days of treatment, the symptoms of dizziness and unstable walking in the patient improved, but there were still symptoms such as decreased memory and delayed reactions, and the patient requested discharge.

After discharge, the patient took medicine regularly: Butylphthalein soft capsules for 2 capsules/Tid; Coenzyme Q10 for 1 capsule/Tid; and Mecobalamin capsules for 1 capsule/Tid. After 1 month of discharge, the patient was followed up at the outpatient department, and his symptoms such as dizziness, unstable walking and decreased memory improved. Non-contrast brain MRI (2023-05) revealed reductions in the extent of the abnormal signal in the brain and in the DWI intensity of the lesion compared with the MRI performed on 2023-04 (Fig. 3). At 6 months of discharge, the patient was followed up at the outpatient department, and his symptoms such as dizziness, unstable walking and decreased memory significantly improved. Non-contrast brain MRI (2023-10) revealed the decreased range of abnormal signals in the brain compared with the MRI performed on (2023-05), and the DWI signal of the lesion tended to be normal, with no new lesions being observed (Fig. 4).

The most recent follow-up of the patient was in April 2024. The patient has resigned from the printing factory and become a mall cleaner. The patient's symptoms such as dizziness, unstable walking and decreased memory have basically disappeared. The patient only underwent EEG examination in April 2024, and the result was negative. We will conduct long-term follow-up on this patient and strengthen the management of similar patients.

Discussion

TE is a disease caused by long-term or excessive exposure to toxic substances, which can lead to damage to the central nervous system (CNS). It mainly displays the pathological manifestations of diffuse white matter lesions and myelin sheath destruction (1,2). OSTE is a subtype of TE. Organic solvents are volatile at room temperature and show strong lipophilicity (4). They can enter human body through respiratory inhalation and direct contact with skin and mucous membranes, and are easily deposited in the lipid-rich brain tissue through the blood-brain barrier, thereby causing damage to the myelin sheath (3,4).

The common organic solvent components with CNS toxicity include alkanes, alcohols, esters, ethers, ketones, nitrosamines and aldehydes. In most cases, organic solvents exist in the form of composite components. Organic solvents can cause lipid peroxidation and excessive generation of free radicals in metabolism, thereby disrupting the stability of cell membranes and leading to myelin degeneration (5,6). Organic solvents can also directly interfere with the function of central neurons and induce acute CNS damage (7,8). OSTE lacks specific clinical symptoms, and is determined by the specific damaged brain area, while the severity of symptoms mainly depends on the concentration and duration of exposure to toxins (9).

Referring to the brain biopsy results of some cases of OSTE (10), some patients have white matter atrophy, patchy myelin sheath loss and granular inclusions with birefringence in macrophages under periodic acid-Schiff staining (7). No significant axonal loss was observed using the modified Bielschewsky method and immunofluorescence neurofilament staining (11). Glial fibrillary acidic protein immunofluorescence and modified phosphotungstic acid hematoxylin staining (12,13) showed small astrocyte microfilaments, indicating mild chronic reactive astrocyte proliferation. Partial pathological results still show lymphocyte infiltration in the white matter of the brain and slight Purkinje cell loss in the vermis of the cerebellum.

The patient in the present case was a porter from a printing factory and does not belong to the category of toxic workers. It is hypothesized that the illness in this patient is

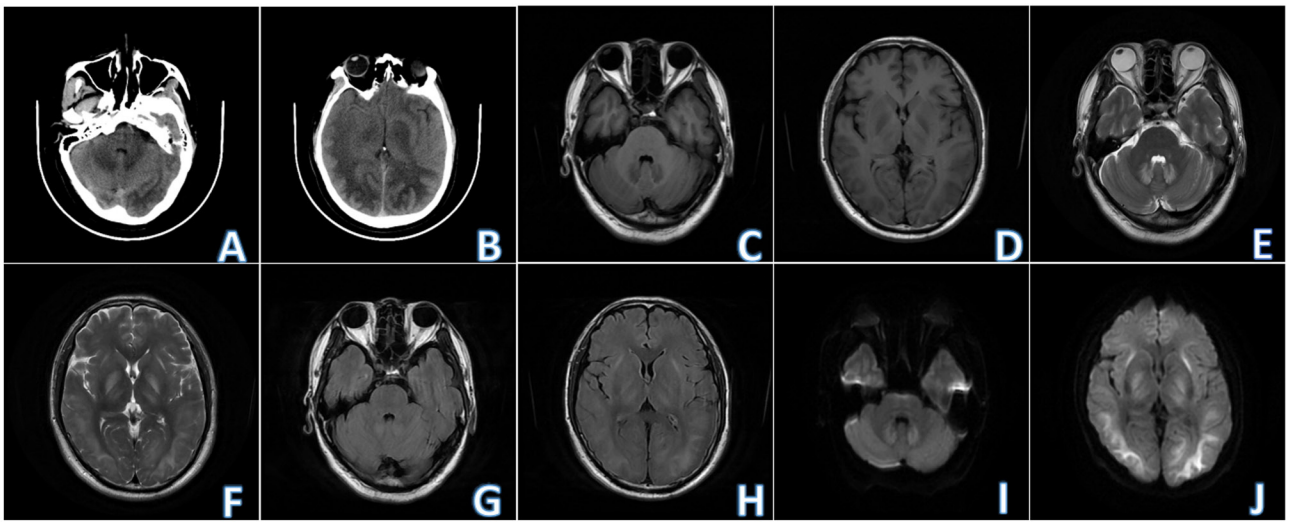

Figure 1. Non-contrast brain CT and MRI (2023-04). (A and B) Non-contrast brain CT showed multiple symmetrical patchy low-density shadows with unclear boundaries in bilateral basal ganglia, bilateral frontal parietal temporal occipital white matter areas and bilateral cerebellar dentate nuclei. (C-J) Non-contrast brain MRI revealed multiple symmetrical patchy T1WI hypo-intensity; T2WI hyper-intensity; T2-FLAIR hyper-intensity; DWI hyper-intensity with blurred edges in the bilateral basal ganglia (outer capsule and globus pallidus), thalamus, frontal parietal temporal occipital white matter area and bilateral cerebellar dentate nucleus. CT, computer tomography; MRI, magnetic resonance imaging; T1WI, T1-weighted imaging; DWI, diffusion-weighted imaging.

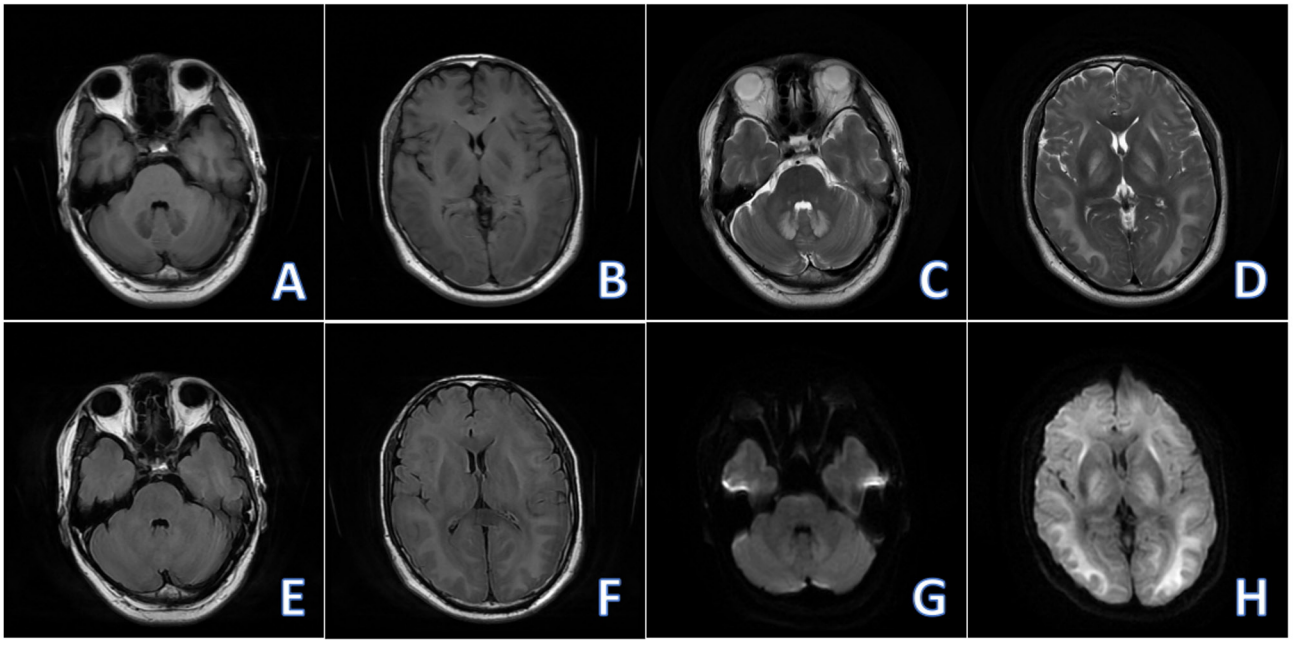

Figure 2. Non-contrast brain MRI (2023-04). (A-H) There were reductions in the extent of the abnormal signal in the brain and in the DWI intensity of the lesion compared with the earlier scans (at 11 days post-admission). MRI, magnetic resonance imaging; DWI, diffusion-weighted imaging.

that the printing factory may have recently experienced ink leakage, and the organic solvent component toluene in the ink can be directly absorbed into the bloodstream through the respiratory tract, finally causing damage to the CNS. The absorbed toluene can be metabolized into benzoic acid via a mixed oxidase system, and it then combines with glycine to produce the product HA, which is excreted into urine (8). Therefore, the concentration of HA in urine can indirectly reflect the level of toluene exposure (14,15). EEG can display the electrical activity of the brain, and patients with OSTE may experience whole brain or focal slow waves, which may serve as an auxiliary means for early diagnosis (16). MRI is an important tool for the diagnosis of OSTE, especially in the acute and subacute stages. MRI can display bilateral symmetrical or diffuse white matter damage and involvement of gray matter nuclei. In addition, imaging changes may partially or completely recover after the improvement of the patient's clinical symptoms (17). In the present case, the non-contrast brain MRI of the patient revealed symmetrical abnormal signals in the bilateral basal ganglia, thalamus, frontal parietal temporal occipital white matter area, and bilateral cerebellar dentate nuclei. As the symptoms

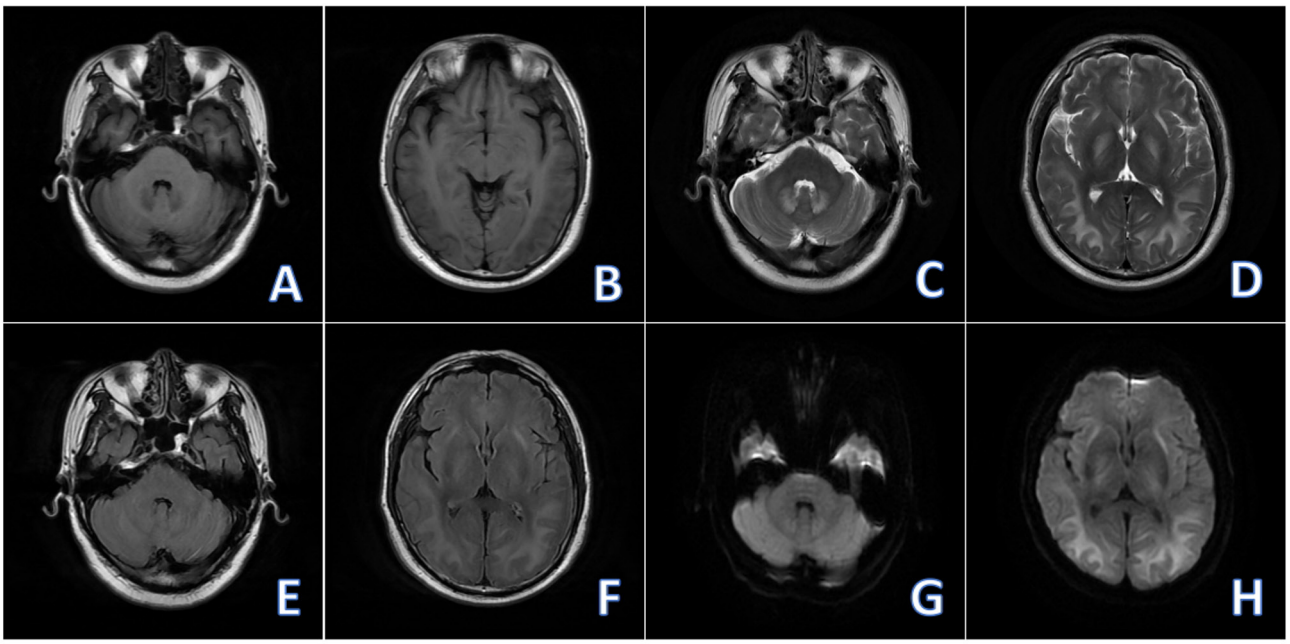

Figure 3. Non-contrast brain MRI (at 15 days post-admission). (A-H) There were reductions in the extent of the abnormal signal in the brain and in the DWI intensity of the lesion, compared with (at 11 days post-admission). MRI, magnetic resonance imaging; DWI, diffusion-weighted imaging.

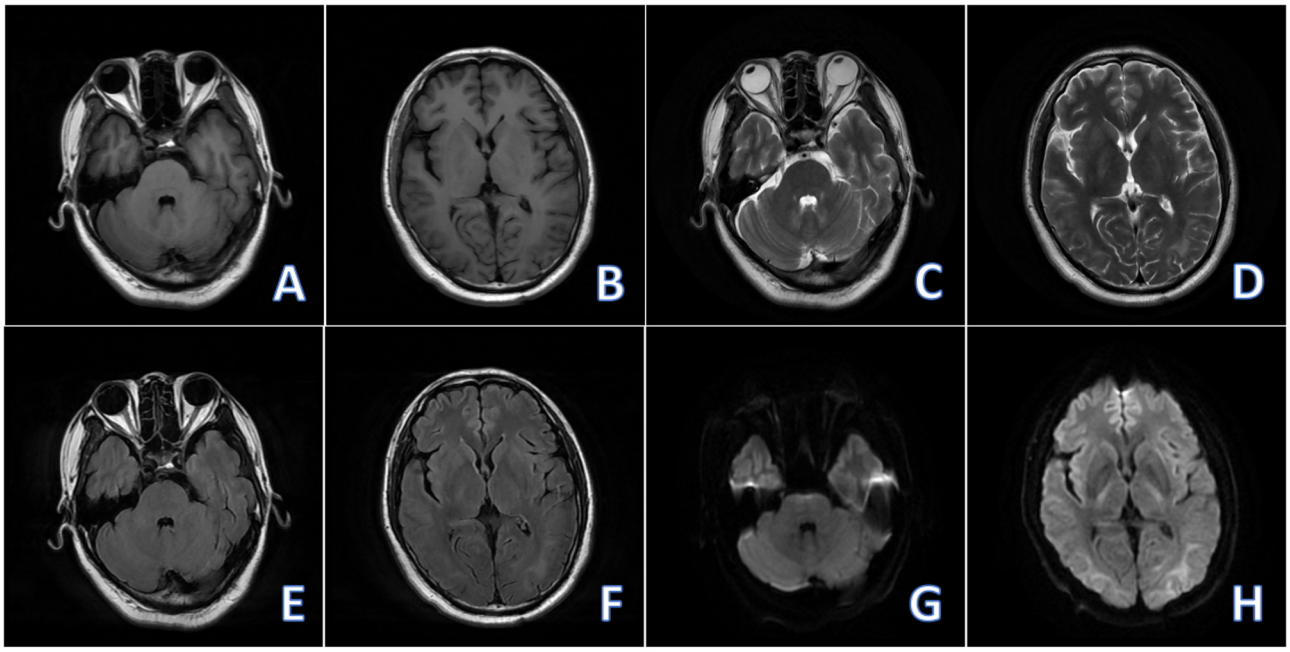

Figure 4. Non-contrast brain MRI (at 164 days post-admission). (A-H) The range of abnormal signals in the brain has decreased compared to (at 15 days post-admission), and the DWI signal of the lesion tends to be normal, with no new lesions observed. MRI, magnetic resonance imaging; DWI, diffusion-weighted imaging.

improved after treatment, the abnormal signal range and signal intensity on the MRI images gradually decreased.

The symptoms of AOSTE usually develop a few days or weeks after contracting the disease. Mild cases may present with symptoms including headache, dizziness, nausea and vomiting, fatigue, delayed response, and ataxia, while severe cases may experience symptoms such as blurred consciousness, epileptic seizures, coma and even death (18-20). Mahavar *et al* (21) reported a case of bilateral basal ganglia cerebral hemorrhage caused by accidental ingestion of toluene, and the patient ultimately died of cardiac arrest. Although AOSTE can cause severe damage to the CNS in the short term, most patients have a good prognosis so long as the exposure to toxins is removed early and appropriate treatment is received. Therefore, timely detection and identification of AOSTE and targeted treatment for patients are of particular significance (22). The patients reported in the present article had an improved prognosis thanks to timely diagnosis and treatment.

Acute and subacute OSTE are mainly characterized by bilateral symmetrical, diffuse involvement of white matter areas, basal ganglia and dentate nuclei on MRI images. Some cases may involve cerebellar white matter and the brainstem, and some severe cases can manifest as whole brain swelling, shallow cerebral sulcus, extensive symmetrical white matter edema and unclear gray white matter boundary. As the clinical symptoms in the patient improve, the aforementioned radiological manifestations can partially or completely disappear (23). Chronic OSTE is mainly featured by mild to moderate cortical and cerebellar atrophy on MRI images, multifocal white matter damage mainly involving the paraventricular and semi-oval center or diffuse symmetrical supratentorial white matter lesions (24,25). The degree of imaging damage is positively correlated with the duration of exposure to toxins (17,26).

Based on the analysis of clinical data from five patients with subacute OSTE and neurological injury, He *et al* (27) assumed that the latent period of subacute neurological injury caused by OSTE is mostly 3 months, with a short exposure time and hidden onset. Therefore, for organic solvent workers with central and peripheral nervous system injuries, the first physician should closely monitor the patient's occupational exposure history to avoid misdiagnosis and missed diagnosis.

The diagnosis of AOSTE is mainly based on a clear history of organic solvent exposure, acute onset, clinical symptoms such as headache, dizziness, drowsiness, blurred consciousness, coma and epileptic seizures, combined with radiological features such as bilateral symmetrical white matter damage, involvement of gray matter nuclei or diffuse involvement of the whole brain, while excluding other triggers including infection, medication, and cerebrovascular accidents (28).

Additionally, the diagnosis of chronic OSTE mainly relies on a clear long-term history of exposure to organic solvents, symptoms and signs of CNS damage, corresponding radiological manifestations and the exclusion of other diseases that may cause similar clinical or radiological manifestations (29). In line with the diagnostic criteria established by the World Health Organization in 1985, chronic OSTE is diagnosed based on the following four criteria (30): i) A clear history of exposure to neurotoxic organic solvents, with a certain incubation period before the onset of neurological symptoms; ii) typical subjective symptoms of CNS damage, such as decreased memory and attention, depression, irritability, sleep disorders and fatigue; iii) objective evidence of decreased memory and attention found from standard neuropsychological tests; and iv) exclusion of primary organic or primary psychiatric symptoms. In 2012, a European conference consensus proposed that the diagnosis of chronic OSTE should encompass at least 5-10 years of exposure to organic solvents, and objective examination of cognitive function and quantitative evaluation of clinical symptoms should be emphasized during diagnosis (31). Meanwhile, joint evaluation by neurologists, occupational disease specialists and neuropsychologists is warranted before the diagnosis is made. If necessary, the participation of psychiatrists and toxicologists is also required (31).

Zheng (32) retrospectively analyzed the radiology characteristics of eight patients with acute/subacute OSTE and concluded that acute/subacute OSTE extensively affects white matter, but the lateral ventricles, corpus callosum, and temporal polar white matter are not easily affected. This may be a key point in distinguishing it from other TE on radiology examinations.

The MRI manifestations of AOSTE are similar to those caused by various diseases, therefore, differential diagnosis should be conducted as follows (33): i) Wernicke's encephalopathy: A metabolic disorder of the CNS caused by vitamin B1 deficiency due to chronic alcoholism, which mainly affects the white matter around the third ventricle and midbrain aqueduct. ii) Carbon monoxide toxic encephalopathy: Can be divided into three types, including mainly involving white matter, mainly involving neural nuclei and mainly involving the cortex. MRI findings are characterized by limited diffusion of bilateral pallidum, and the disease can be distinguished based on a history of toxic contact (34). iii) Neuronal intranuclear inclusion body disease (NIBD): MRI manifestations of adult NIBD show a high DWI signal at the corticomedullary junction, which appears as 'serrated' or 'flame-like', but does not involve the deep white matter (35). iv) Hepatolenticular degeneration (HLD): Clinical manifestations include progressive liver damage, neuropsychiatric disorders and corneal pigment ring (36). Brain MRI findings reveal a low intensity on T1WI image and a high intensity on T2WI image of the lenticular nucleus, age-unmatched brain atrophy and brainstem atrophy (mainly medullary atrophy), while white matter lesions of OSTE are mainly characterized by atrophy (37). In addition, the 'panda face sign' in the midbrain is a specific radiological manifestation of HLD (38).

At present, due to the lack of corresponding antidotes, there is no specific treatment for OSTE. Typically, early diagnosis and treatment play a significant role in improving the prognosis of patients with AOSTE. In this regard, it is necessary to strengthen the understanding of AOSTE in medical personnel, especially emergency medical personnel. When receiving patients with suspected OSTE, it is necessary to inquire if they have a history of exposure to organic solvents, such as those working in the chemical or printing industry, understand the types of organic solvents the patients have been exposed to, the exposure time, environmental ventilation and personal protective measures, and ask if the patients have symptoms such as dizziness, headache, nausea, fatigue and lack of concentration (39,40). Besides, it is important to detect the metabolites of organic solvents, such as HA (an indicator of toluene exposure), methylhippuric acid (an indicator of xylene exposure) and 2-thiothiazolidine-4-carboxylic acid (an indicator of carbon disulfide exposure), by using biological samples including blood and urine, so as to assess the patients' recent exposure to organic solvents (41,42).

The treatment principles for TE mainly include removing the cause, reducing cerebral edema, improving cerebral circulation and protecting nerve cells. Notably, comprehensive treatment measures such as hyperbaric oxygen therapy, hormone anti-inflammatory therapy, dehydration and intracranial pressure reduction, have important application value in the treatment of TE. For patients with acute onset, symptomatic supportive treatment remains the main approach. For those with severe conditions, the early application of high-dose glucocorticoids and sufficient treatment duration of mannitol can timely control symptoms and prevent disease deterioration.

For patients with combined emotional disorders and sleep disorders, symptomatic treatment should be given (43).

Due to the lack of effective treatments, the prevention of OSTE is particularly significant. It is necessary to further improve occupational health laws and regulations, strictly control the exposure of harmful substances in the production environment and improve the on-site working environment. Meanwhile, it is necessary to strengthen safety protection and regular health checks for toxic workers. In addition, it is also greatly needed to enhance occupational health promotion, raise workers' awareness of protection and reduce exposure to toxic substances. Once suspicious symptoms appear, one should immediately leave the relevant work environment and receive early diagnosis and treatment (44).

The main clinical manifestations of the present patient were dizziness with unstable walking, and non-contrast brain MRI showed symmetrical abnormal signals in the bilateral basal ganglia, thalamus, frontal parietal temporal occipital white matter area and bilateral cerebellar dentate nuclei. In laboratory tests, the level of HA significantly increased, indirectly reflecting the exposure level of toluene (an organic solvent component in ink). Therefore, in this case, a possible history of ink exposure, brain MRI findings and HA testing were indispensable factors in the diagnosis.

In summary, AOSTE should be a part of the differential diagnosis in any patient with acute neurobehavioral and neurological deficits. Brain MRI and urine testing are important for diagnosis. In addition, early diagnosis and treatment play a significant role in improving the prognosis of patients with AOSTE. Therefore, when AOSTE is detected and recognized in a timely manner, patients should be treated with strategies such as hyperbaric oxygen, anti-inflammatory, cranial pressure lowering and neurotrophic therapy.

Acknowledgements

Not applicable.

Funding

This work was supported by the Key R&D Project of Xuzhou Science and Technology Bureau (grant no. KC23208).

Availability of data and materials

The data generated in the present study may be requested from the corresponding author.

Authors' contributions

YW and PD conceived and designed the study, collected and assembled the data and wrote and revised the manuscript. All authors contributed to the article and read and approved the final manuscript. YJW and PD confirm the authenticity of all the raw data.

Ethics approval and consent to participate

The study involving human participant was reviewed and approved by Ethics Committee of The Second Affiliated Hospital of Xuzhou Medical University (grant no. KY-20241201). The patient provided his written informed consent to participate in this study.

Patient consent for publication

The patient provided consent for his/her information to be published.

Competing interests

The authors declare that they have no competing interests.

References

1. Dobbs MR: Toxic encephalopathy. Semin Neurol 31: 184-193, 2011.
2. Agarwal A and Vancil T: Toxic encephalopathy. J Gen Intern Med 27: 876-877, 2012.
3. Li XL, Zhao HT, Han J, Yan ZR and Wang HY: Toxic encephalopathy induced by radix Sophorae tonkinensis. Acta Neurol Belg 122: 855-858, 2022.
4. Sainio MA Sr: Neurotoxicity of solvents. Handb Clin Neurol 131: 93-110, 2015.
5. Ikeda M: Public health problems of organic solvents. Toxicol Lett 64-65: 191-201, 1992.
6. Hedström AK, Hössjer O, Katsoulis M, Kockum I, Olsson T and Alfredsson L: Organic solvents and MS susceptibility: Interaction with MS risk HLA genes. Neurology 91: e455-e462, 2018.
7. Filley CM, Halliday W and Kleinschmidt-DeMasters BK: The effects of toluene on the central nervous system. J Neuropathol Exp Neurol 63: 1-12, 2004.
8. Win-Shwe TT and Fujimaki H: Neurotoxicity of toluene. Toxicol Lett 198: 93-99, 2010.
9. Greenberg MM: The central nervous system and exposure to toluene: A risk characterization. Environ Res 72: 1-7, 1997.
10. Ridgway P, Nixon TE and Leach JP: Occupational exposure to organic solvents and long-term nervous system damage detectable by brain imaging, neurophysiology or histopathology. Food Chem Toxicol 41: 153-187, 2003.
11. Eaker EY, Shaw G and Sninsky CA: Neurofilament immunoreactivity in myenteric neurons differs from that found in the central nervous system. Gastroenterology 99: 1364-1371, 1990.
12. Heimfarth L, Passos FRS, Monteiro BS, Araújo AAS, Quintans Júnior LJ and Quintans JSS: Serum glial fibrillary acidic protein is a body fluid biomarker: A valuable prognostic for neurological disease-A systematic review. Int Immunopharmacol 107: 108624, 2022.
13. Shum MW and Hon JK: A modified phosphotungstic acid haematoxylin stain for formalin-fixed tissues. J Med Lab Technol 26: 38-42, 1969.
14. Oginawati K, Anka AAH, Susetyo SH, Febriana SA, Tanziha I and Prakoeswa CRS: Urinary hippuric acid level as a biological indicator of toluene exposure on batik workers. Heliyon 7: e07775, 2021.
15. Shan X, Zhang L, Ye H, Shao J, Shi Y, Tan S, Zhang L and Su K: Analytical techniques for monitoring of toluene and xylene exposure biomarkers hippuric acid and methylhippuric acid in human urine samples. Bioanalysis 13: 1569-1584, 2021.
16. Keski-Säntti P, Kovala T, Holm A, Hyvärinen HK and Sainio M: Quantitative EEG in occupational chronic solvent encephalopathy. Hum Exp Toxicol 27: 315-320, 2008.
17. Aydin K, Sencer S, Demir T, Ogel K, Tunaci A and Minareci O: Cranial MR findings in chronic toluene abuse by inhalation. AJNR Am J Neuroradiol 23: 1173-1179, 2002.
18. Mi T, Han C, Wang Y, Ma H, Jia J, Ding Y, Esmail F, Chen J, Peng L, Xu J and Sun YX: Acute toxic leukoencephalopathy in migrant workers exposed to organic solvents in construction materials. Occup Environ Med 70: 435-436, 2013.
19. Liu JR, Fang S, Ding MP, Chen ZC, Zhou JJ, Sun F, Jiang B and Huang J: Toxic encephalopathy caused by occupational exposure to 1, 2-Dichloroethane. J Neurol Sci 292: 111-113, 2010.
20. Dick FD: Solvent neurotoxicity. Occup Environ Med 63: 221-179, 2006.

21. Mahavar S, Chaturvedi A, Singh A, Kumar R, Dariya SS and Sharma R: Toluene poisoning presenting as bilateral basal ganglia haemorrhage. J Assoc Physicians India 66: 93-94, 2018.
22. Basant N, Gupta S and Singh KP: Predicting the acute neurotoxicity of diverse organic solvents using probabilistic neural networks based QSTR modeling approaches. Neurotoxicology 53: 45-52, 2016.
23. Gaosheng X, Tao J and Min M: The analysis of clinical and imaging features in 15 patients with occupational organic solvent poisoning. Stroke Nervous Dis 28: 672-675, 2021 (In Chinese).
24. Liu J, Zhang L, He B, Zhuang JH, Xu J, Huang LY and Peng H: Roles of neuroimage in toxic encephalopathy induced by 1, 2-Dichloroethane. Clin Neurol Neurosurg 184: 105398, 2019.
25. Dietemann JL, Botelho C, Nogueira T, Vargas MI, Audibert C, Abu Eid M, Bogorin A, Bernardo R, Jacques C, Kremer S and Zöllner G: Imagerie des encephalopathies toxiques aigues Imaging in acute toxic encephalopathy. J Neuroradiol 31: 313-326, 2004 (In French).
26. Keski-Säntti P, Mäntylä R, Lamminen A, Hyvärinen HK and Sainio M: Magnetic resonance imaging in occupational chronic solvent encephalopathy. Int Arch Occup Environ Health 82: 595-602, 2009.
27. He L, Kong D and Jing H: Analysis on clinical characteristics of five cases of sub-acute organic solvent poisoning nervous system injuries. Chin J Industrial Med 36: 326-328, 2023 (In Chinese).
28. Donoghue AM, Dryson EW and Wynn-Williams G: Contrast sensitivity in organic-solvent-induced chronic toxic encephalopathy. J Occup Environ Med 37: 1357-1363, 1995.
29. Seo S and Kim J: An aggravated return-to-work case of organic solvent induced chronic toxic encephalopathy. Ann Occup Environ Med 30: 27, 2018.
30. Baker EL: Chronic toxic encephalopathy caused by occupational solvent exposure. Ann Neurol 63: 545-547, 2008.
31. Van Valen E, van Thriel C, Akila R, Nilson LN, Bast-Pettersen R, Sainio M, van Dijk F, van der Laan G, Verberk M and Wekking E: Chronic solvent-induced encephalopathy: European consensus of neuropsychological characteristics, assessment, and guidelines for diagnostics. Neurotoxicology 33: 710-726, 2012.
32. Zheng X: Imaging features of acute and subacute toxic encephalopathy induced by organic solvents. J Practical Radiology 40: 19-21, 2024.
33. Biswas S, Pendharkar HS and Murumkar VS: MRI Spectrum of toxic encephalopathy-an institutional experience. Neurol India 70: 1525-1533, 2022.
34. Wang X, Li Z, Berglass J, He W, Zhao J, Zhang M, Gao C, Zhang C, Zhang H and Yi X: MRI and clinical manifestations of delayed encephalopathy after carbon monoxide poisoning. Pak J Pharm Sci 29 (Suppl 6): S2317-S2320, 2016.
35. Sone J, Mori K, Inagaki T, Katsumata R, Takagi S, Yokoi S, Araki K, Kato T, Nakamura T, Koike H, *et al*: Clinicopathological features of adult-onset neuronal intranuclear inclusion disease. Brain 139: 3170-3186, 2016.
36. Mulligan C and Bronstein JM: Wilson disease: An overview and approach to management. Neurol Clin 38: 417-432, 2020.
37. Bandmann O, Weiss KH and Kaler SG: Wilson's disease and other neurological copper disorders. Lancet Neurol 14: 103-113, 2015.
38. Panda AK, Mehta VJ, Dung AA and Kushwaha S: Face of giant panda sign in Wilson's disease. J Assoc Physicians India 62: 707-708, 2014.
39. Haibing Z, Guilan O, Yanwei L: Clinical characteristics of occupational acute organic solvent poisoning encephalopathy. J Gannan Med Univ 40: 891-895, 2020.
40. Chuan F and Xianwen C: Research progress on organic solvent toxic encephalopathy. Chin J Neurol 47: 55-58, 2014.
41. Mestdagh I, van Bergen L, Kocken C, Heyvaert V, Cras P and Van Den Eede F: Diagnosing solvent-induced chronic toxic encephalopathy: The effect of underperformance in neuropsychological testing. Int J Psychiatry Clin Pract 23: 171-177, 2019.
42. Dryson EW and Ogden JA: Organic solvent induced chronic toxic encephalopathy: Extent of recovery, and associated factors, following cessation of exposure. Neurotoxicology 21: 659-665, 2000.
43. Van Valen E, van Hout ES, Wekking EM, Lenderink AF, van der Laan G and Hageman G: Brain damage caused by exposure to organic solvents; diagnostics and disease course of chronic solvent-induced encephalopathy. Ned Tijdschr Geneeskd 159: A9431, 2015.
44. Van Valen E, Wekking E, van der Laan G, Sprangers M and van Dijk F: The course of chronic solvent induced encephalopathy: A systematic review. Neurotoxicology 30: 1172-1186, 2009.

Copyright © 2024 Wang and Du. This work is licensed under a Creative Commons Attribution-NonCommercial-NoDerivatives 4.0 International (CC BY-NC-ND 4.0) License.