SPANDIDOS PUBLICATIONS

BIOMEDICAL REPORTS 21: 190, 2024

Musculoskeletal ultrasound of the shoulder in patients with adhesive capsulitis

ADIPA MOLEESAIDE, JITTIMA SAENGSUWAN and PATPIYA SIRASAPORN

Department of Rehabilitation Medicine, Srinagarind Hospital, Faculty of Medicine, Khon Kaen University, Khon Kaen 40002, Thailand

Received July 8, 2024; Accepted October 3, 2024

DOI: 10.3892/br.2024.1878

Abstract. Adhesive capsulitis is a common pathological condition of the shoulder that affects the general population. The aim of the present study was to explore shoulder ultrasonographic findings in patients with adhesive capsulitis. A cross-sectional descriptive study was conducted on 96 patients with adhesive capsulitis. Abnormal shoulder ultrasonographic findings were found in all participants. The top three abnormal ultrasonographic imaging features were biceps tendon effusion (71.8%), positive dynamic supraspinatus impingement (56.2%) and subdeltoid-subacromial bursitis (47.9%). By assessing the relationship between limited functional shoulder range of motion (ROM) and abnormal shoulder ultrasonographic findings, limited passive ROM (PROM) with shoulder flexion of ≤120 degrees was found to be significantly associated with positive dynamic supraspinatus impingement. Similarly, limited PROM in shoulder abduction of ≤130 degrees was found to be significantly associated with subdeltoid and subacromial bursitis, as well as positive dynamic supraspinatus impingement. In addition, limited PROM with shoulder internal rotation of ≤60 degrees was significantly associated with positive dynamic supraspinatus impingement. Varying abnormal shoulder ultrasonographic findings were obtained in patients with adhesive capsulitis. Therefore, it should be cautioned that relying solely on physical examination may not accurately indicate true shoulder pathology and it is suggested that the final diagnosis should be based on a combination of the patients' clinical and overall ultrasonographic findings.

Correspondence to: Dr Patpiya Sirasaporn, Department of Rehabilitation Medicine, Srinagarind Hospital, Faculty of Medicine, Khon Kaen University, 123 Moo 16 Mittapap Road, Muang, Khon Kaen 40002, Thailand
E-mail: spatpiya@kku.ac.th

Key words: adhesive capsulitis, ultrasonography, biceps tendon effusion, dynamic supraspinatus impingement, subdeltoid-subacromial bursitis

Introduction

Adhesive capsulitis, also known as frozen shoulder, is a common pathological condition of the shoulder that affects 2-5% of the general population (1,2). The etiology is still unknown but risk factors include female sex, age >40 years, preceding trauma, human leukocyte antigen-B27 positivity and prolonged immobilization (3). Systemic diseases associated with adhesive capsulitis are diabetes mellitus, stroke, thyroid disorders and Parkinson's disease (4). Most patients with adhesive capsulitis present with pain and development of functional restriction of both active and passive glenohumeral joint motions, which causes shoulder stiffness (5). These symptoms typically begin gradually, worsen over time and then resolve, usually within one to three years (5). The pathology of adhesive capsulitis remains unclear but may include a chronic inflammatory response with fibroblastic proliferation, which may be immunomodulated and which induces capsule thickening and tightening around the shoulder joint, thus restricting its movement (6).

Patients with adhesive capsulitis present with insidious onset, dull and aching pain, which is often worse at night and associated with movement and restricted passive and active range of motion (ROM) of the shoulder in all directions, particularly external rotation (7). Physical examination shows diffuse tenderness over the glenohumeral joint and limited passive and active shoulder ROM. There are three phases of frozen shoulder: Phase I, the painful or pain-dominant phase; Phase II, the adhesive or stiffness phase; and Phase III, the resolution or thawing phase (1,8). The management of adhesive capsulitis includes analgesic medications, physical modalities, ROM exercises, manipulation under anesthesia and surgical intervention (2,9).

Adhesive capsulitis is usually diagnosed based on history and physical examination. There are few specific laboratory tests that may be performed if concern for an underlying systemic disease contributes to the condition or radiological markers for adhesive capsulitis diagnosis. Plain radiograph, which mainly displays the bony structure, cannot rule out other pathologies that present with shoulder pain and limit ROM that mimic frozen shoulder, such as biceps tendinopathy, rotator cuff tendinopathy or tear, and subacromial and subdeltoid bursitis. These conditions can mimic frozen shoulder, but may also occur concomitantly and cannot be differentiated by physical examination. Thus, further investigations, such as

magnetic resonance imaging (MRI), ultrasound or arthroscopy, should be considered for evaluating soft tissue shoulder structure (4,10).

Numerous studies have reported on the concomitant pathophysiology associated with primary frozen shoulder by MRI or arthrography findings. The pathology has been attributed to structures such as the subacromial bursa, joint capsule, coraco-humeral ligament and synovial joint (10).

Musculoskeletal ultrasound (MSK US) is mostly used for investigating soft tissue lesions, such as tendinopathy, synovitis and bursitis. It has numerous advantages, such as shorter examination times, lower cost and wider availability to patients compared with non-MRI-compatible implants (11). Ultrasound is a noninvasive, radiation-free diagnostic test and it does not have any contraindications. Ultrasound imaging provides simultaneous comparison between multiple regions and can be used to facilitate interventional procedures (12). In previous studies, ultrasound examinations of patients with adhesive capsulitis have revealed increased thickness of the inferior glenohumeral capsule, coracohumeral ligament (CHL), soft tissue in rotator interval and axillary recess capsule (ARC) thickness (13-15). The diagnostic cutoff values for adhesive capsulitis showed that the CHL thickness had a sensitivity of 77-74-95% and a specificity of 88-99%, while the ARC thickness had a sensitivity of 68.9-93.8% and a specificity of 90.2-98% (11,16,17). Doppler signals and hypoechoic echotexture in the rotator interval demonstrated high sensitivity (97%) and specificity (100%) for the diagnosis of adhesive capsulitis (18). Ultrasound has also identified common soft tissue pathologies in patients with shoulder pain, both with and without limited range of motion, such as subacromial bursitis and rotator cuff tendinopathy (15). A study exploring the prevalence of subacromial-subdeltoid bursitis found that effusion in the subacromial-subdeltoid bursa was frequently associated with shoulder pain, often independently from the underlying pathology (19). An evaluation of rotator cuff pathology in stiff shoulder by MRI and ultrasound found that the severity of the ROM limitation did not correspond to the severity of the rotator cuff tear (20). Al Khayyat *et al* (17) found that using MSK US as a first-line imaging modality was as reliable as MRI for diagnosing adhesive capsulitis. This conclusion was based on the evaluation of combined ultrasound parameters, including grey-scale changes, thickening of shoulder ligaments, axillary pouch thickening, alterations in the long head of the biceps tendon sheath, and changes in the supraspinatus and infraspinatus. These findings assist physicians in everyday clinical practice (17). Numerous studies have evaluated shoulder structure in adhesive capsulitis and shoulder pain by ultrasound. However, they only evaluated and reported on thickness of ligament, capsule and soft tissue in the rotator interval. Only a small number of studies have used MSK ultrasound to evaluate rotator cuff disorders (19-21). The aim of the present study was to use ultrasound to evaluate pathologies that can occur concomitantly with adhesive capsulitis.

Patients and methods

Study design and participants. This study was designed as a cross-sectional descriptive study. We enrolled 96 patients with adhesive capsulitis diagnoses from the rehabilitation or orthopedics clinic at Srinagarind Hospital, Faculty of Medicine, Khon Kaen University (Khon Kaen, Thailand). The inclusion criteria were a patient age of >18 years, unilateral local shoulder pain for >3 months and >50% limitation in active and passive glenohumeral joint ROM in comparison to the uninvolved shoulder for greater than or equal to two directions (21,22). Exclusion criteria were clinical evidence of significant cervical spine disease, history of significant trauma to the shoulder, prior surgery, dislocation or fractures on the affected shoulder, inability to cooperate during the examination and inability to sit in a chair for >30 min.

The sample was estimated size based on the standard formula for prevalence studies,

$$n = \frac{Z^2 P\,(1-P)}{d^2},$$

where P is the expected prevalence of 0.493 based on a previous study (19), Z is the test statistic corresponding to a 95% confidence interval and d is the required precision of 0.1. This gave a sample size estimate of 96 participants.

Data collection. All patients were assessed clinically and by ultrasonographic examination of their affected shoulders. Prior written informed consent was obtained from all patients. Demographic data collected included age, gender, body weight and height, underlying disease, duration of shoulder pain, site of pain, handedness and occupation. Occupation was classified according to work demands. Home and office work was considered light work, while farming and technical work were considered heavy work (23). Shoulder pain severity was assessed using a numerical rating scale, with 0 indicating no pain and 10 representing the most severe pain. Medical treatments, including medications (analgesics or muscle relaxants) and types of physical therapy (physical modalities and range-of-motion exercises) were recorded. All participants were requested to complete the Thai Shoulder Pain and Disability Index (SPADI) questionnaire [Phongamwong and Choosakde (24)], which demonstrates excellent validity and reliability. The internal consistency of the pain subscale, disability subscale and total scale was outstanding, with Cronbach's α coefficients of 0.92, 0.94 and 0.95, respectively, closely matching the original English version by Roach *et al* (25) (Cronbach's α=0.95). The Thai SPADI (24) was chosen for the present study due to its cultural relevance, language specificity and greater applicability to the local population in Thailand. All of this information was obtained by a physician who was not a musculoskeletal ultrasonographic examiner.

Patients' affected shoulders were examined to identify the area of maximal tenderness by palpating anterior, posterior, medial and lateral shoulder sites. Both passive and active ROM for the affected shoulders were tested. Limited functional shoulder (ROM was defined as passive shoulder forward flexion of 120 degrees or less, abduction of 130 degrees or less and internal and external rotation of 60 degrees or less (26-28).

MSK US was performed on the affected shoulder by a specialist in rehabilitation medicine who had >10 years' experience in MSK US and was blinded to the clinical diagnoses. The ultrasonography protocol followed standard practice with the GE LOGIQ™ e Ultrasound System (GE Healthcare) and used a 9L-D linear array transducer to

Table I. Baseline characteristics.

Characteristic	Value
Sex	
Male	32 (33.3)
Female	64 (66.6)
Age, years	59.0±11.8
BMI, kg/m^2	23.3±3.4
Underweight	4 (4.1)
Normal	39 (40.6)
Overweight	28 (29.1)
Obese	25 (26.0)
Handedness	
Right	77 (81.0)
Left	18 (18.9)
Underlying diseases	70 (72.9)
DM	19 (19.7)
HT	29 (30.2)
DLP	27 (28.1)
Others	39 (40.6)
Occupation	
Light work (home and office work)	29 (30.2)
Heavy work (farming or technician)	50 (52.0)
None	17 (17.7)

Values are expressed as n (%) or the mean ± standard deviation. DM, diabetes mellitus; HT, hypertension; DLP, dyslipidemia; BMI, body mass index.

Table II. Shoulder characteristics.

Characteristic	Value
Shoulder pain site	
Dominant	55 (57.2)
Non-dominant	41 (42.7)
Duration of pain, months	4 (3-6)
Severity on the NRS	6.8±2.0
Previous treatment	
None	17 (17.7)
Self-exercise	9 (9.3)
Medications (analgesic or muscle relaxant)	27 (28.1)
Physical therapy: Modality + ROME	18 (18.7)
Medication and physical therapy	25 (26.0)
Area of maximal tenderness	
None	14 (14.5)
Anterior	65 (67.7)
Posterior	11 (11.4)
Lateral	6 (6.2)
Active/passive ROM	
Forward flexion	130.9±32.8/139.3±31.0
Abduction	117.1±42.1/126.1±40.2
Internal rotation	34.2±21.6/40.3±23.0
External rotation	71.1±16.0/74.7±16.1
SPADI score	54.3±17.8
Mild (0-20)	2 (2.0)
Moderate (21-40)	20 (20.8)
Severe (41-60)	35 (36.4)
Very severe (61-80)	32 (33.3)
Extremely severe (81-100)	7 (7.2)

Values are expressed as n (%), the mean ± standard deviation or the median (interquartile range). NRS, numeric rating scale; ROME, range of motion exercise; ROM, range of motion; SPADI, Shoulder Pain and Disability Index.

collect images. Participants sat upright in a chair during the ultrasonographic examination. Ultrasound abnormalities and characteristics of the biceps tendon, supraspinatus tendon, subdeltoid-subacromial bursa, subscapularis tendon, infraspinatus tendon, acromioclavicular joint and glenohumeral joint were documented according to the guidelines of The European Society of Musculoskeletal Radiology (29). The definitions of ultrasonographic pathology were based on international guidelines of The Outcomes Measures in Rheumatology (OMERACT 7) (26).

Statistical analysis. For all statistical analyses, Stata software v.13 (StataCorp LP) was utilized. Continuous data were expressed as the mean ± standard deviation (SD) if the data were normally distributed and median with interquartile range if the data were not normally distributed. Ordinal and categorical data were presented as frequencies and percentages. Chi-squared tests were conducted to determine the association between limited functional shoulder ROM and abnormal ultrasonographic findings.

Results

Baseline characteristics. Of the 96 patients enrolled in the present study, 64 (66.6%) were female. The age of the patients (mean ± SD) was 59.0±11.8 years. Most patients were right-handed (81.0%) and most did heavy work (52.0%) and had a normal body mass index (40.6%) (Table I).

Shoulder pain characteristics. Table II shows that most shoulder pain occurred on the dominant side (57.2%). The median duration of shoulder pain was 4 months. The mean numeric pain severity rating was 6.8 (severe pain). A large majority, (82.1%), of patients had experienced previous treatments, including medications and/or physical therapy and/or exercise, before their ultrasonographic examination. The most common area of maximal tenderness was the anterior region. A sizeable number of patients had SPADI scores in the severe range (36.4%) and very severe range (33.3%).

Shoulder ultrasound findings. Abnormal shoulder ultrasound findings were found in all 96 cases (100%). On ultrasonographic imaging, the top three abnormalities were biceps

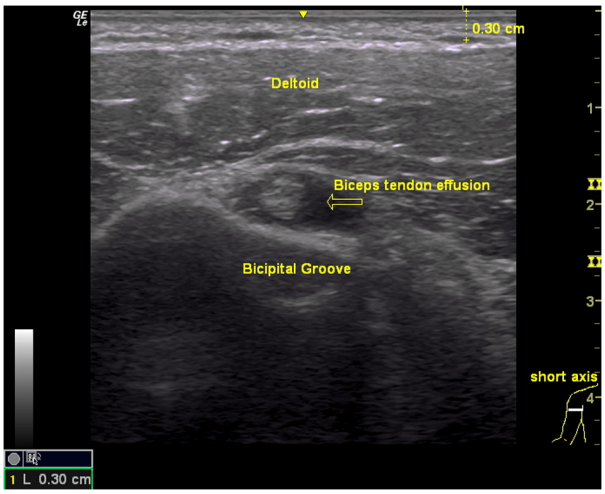

Figure 1. Short-axis view of the biceps tendon showing an effusion, as indicated by the arrow.

tendon effusion (71.8%) (Fig. 1), positive dynamic supraspinatus impingement (56.2%) and subdeltoid-subacromial bursitis (47.9%) (Table III) The relationship between limited functional shoulder ROM and common abnormal ultrasonographic findings was analyzed. The results showed that a limited passive ROM (PROM) in shoulder flexion of ≤120 degrees was significantly associated with positive dynamic supraspinatus impingement. Similarly, a limited PROM in shoulder abduction of ≤130 degrees was significantly associated with subdeltoid and subacromial bursitis, as well as positive dynamic supraspinatus impingement. In addition, a limited PROM in shoulder internal rotation of ≤60 degrees was significantly associated with positive dynamic supraspinatus impingement (Table IV).

Discussion

The present study was the first to evaluate both rotator cuff and non-rotator cuff parameters, including acromioclavicular joint, biceps tendon, subscapularis tendon, supraspinatus tendon, subdeltoid-subacromial bursa, infraspinatus tendon, glenohumeral joint and the dynamic supraspinatus impingement test. As expected, abnormal ultrasound findings were present in all of the cases, as most had severe shoulder pain. A sizeable number of patients had SPADI scores in the severe range and most did heavy work. The most common abnormal ultrasonographic finding in the present cohort of patients with adhesive capsulitis was biceps tendon effusion. This was consistent with the most common physical examination finding of maximal tenderness in the anterior shoulder region, also found in previous studies (30,31). In cases of adhesive capsulitis, effusion can be easily detected in the region of the long head of the biceps tendon, often appearing as a target sign. However, glenohumeral joint effusion may be most reliably detected and quantified in the posterior glenohumeral joint recess, where it is typically found less frequently than in the long head of the biceps tendon region (30,32). According to the present results, effusion is detected more frequently in the region of the long head of the biceps tendon (71.8%) than in the glenohumeral joint (7.2%). Park *et al* (30) suggested biceps tendon effusion may be due to joint shrinkage in adhesive capsulitis pushing the joint fluid to another space, such as the biceps long head tendon sheath. However, biceps tendon effusion is not associated with biceps pathology alone and may also be found in rotator cuff disease (33) or subacromial impingement (34). Therefore, it is essential to correlate these findings with physical examinations simultaneously.

The second most common abnormal ultrasonographic finding in the present study was positive dynamic

Table III. Ultrasound findings.

Structural feature	Value
Biceps tendon	
Normal echogenicity	27 (28.1)
Effusion	69 (71.8)
Calcification	2 (2.0)
Subscapularis tendon	
Normal echogenicity	85 (88.5)
Tendinosis	6 (6.2)
Partial rupture	1 (1.0)
Calcification	4 (4.1)
Acromioclavicular joint	
Normal echogenicity	88 (91.6)
Effusion	3 (3.1)
Calcification	4 (4.1)
Increase vascularity	1 (1.0)
Supraspinatus tendon	
Normal echogenicity	48 (50.0)
Tendinosis	37 (38.5)
Partial rupture	7 (7.2)
Full rupture	1 (1.0)
Calcification	10 (10.4)
Irregular cortex	1 (1.4)
Subdeltoid-subacromial bursa	
Normal echogenicity	50 (52.0)
Bursitis	46 (47.9)
Infraspinatus tendon	
Normal echogenicity	82 (85.4)
Tendinosis	2 (2.0)
Partial rupture	2 (2.0)
Calcification	8 (8.3)
Effusion	2 (2.0)
Glenohumeral joint	
Normal echogenicity	79 (82.2)
Effusion	7 (7.2)
Calcification	11 (11.4)
Dynamic supraspinatus impingement	
Negative	38 (39.5)
Positive	54 (56.2)
Non-applicable	4 (4.1)

Values are expressed as n (%).

Table IV. Relationship between limited functional ROM and abnormal ultrasound.

ROM limit/abnormal ultrasound finding	Yes	No	P-value
Flexion (PROM ≤120)	36 (37.5)		
Biceps tendon effusion	25 (69.4)	11 (30.6)	0.68
Supraspinatus tendon - tendinosis	15 (41.7)	21 (58.3)	0.63
Subdeltoid-subacromial bursa - bursitis	15 (41.7)	21 (58.3)	0.34
Dynamic supraspinatus impingement positive	25 (57.6)	8 (24.2)	0.013
Abduction (PROM ≤130)	50 (52.0)		
Biceps tendon effusion	33 (66.0)	17 (34.0)	0.18
Supraspinatus tendon-tendinosis	18 (36.0)	32 (64.0)	0.59
Subdeltoid-subacromial bursa - bursitis	19 (38.0)	31 (62.0)	0.043
Dynamic supraspinatus impingement positive	34 (72.3)	13 (27.7)	0.007
Internal rotation (PROM ≤60)	81 (84.3)		
Biceps tendon effusion	60 (74.0)	21 (35.9)	0.27
Supraspinatus tendon-tendinosis	30 (37.0)	51 (63.0)	0.48
Subdeltoid-subacromial bursa - bursitis	40 (49.4)	41 (50.6)	0.50
Dynamic supraspinatus impingement positive	51 (62.4)	27 (34.6)	0.002
External rotation (PROM ≤60)	25 (26.0)		
Biceps tendon effusion	15 (60.0)	10 (40.0)	0.13
Supraspinatus tendon - tendinosis	10 (40.0)	15 (60.0)	0.86
Subdeltoid-subacromial bursa - bursitis	10 (40.0)	15 (60.0)	0.36
Dynamic supraspinatus impingement positive	17 (73.9)	6 (26.1)	0.09

Values are expressed as n (%). ROM, range of motion; PROM, passive ROM.

supraspinatus impingement. There were 3 cases exhibiting severe limitations in abduction ROM and 1 case diagnosed with a full-thickness tear of the supraspinatus tendon. More than half of the patients in the present study had a positive dynamic impingement test, consistent with Tandon *et al* (14), who found high sensitivity for dynamic supraspinatus impingement in adhesive capsulitis. Kim *et al* (35) also found that subacromial gliding limitation of the supraspinatus tendon is associated with decreased shoulder joint capacity, an important feature of adhesive capsulitis. However, positive dynamic supraspinatus impingement findings are known to occur in numerous other pathologies, such as rotator cuff tears, impingement syndromes, tendinitis and subacromial bursitis (14). Therefore, it is important to compare ultrasound results with physical examinations to identify a possible diagnosis.

Stella *et al* (31) found subacromial-subdeltoid bursitis in 11.3% of patients with adhesive capsulitis, whereas in the present study, the extent of bursitis was 42.2%. However, their study did not include patients' occupations. The difference between the two studies may arise from the fact that the majority of patients in the present study engaged in heavy work, potentially resulting in repetitive severe trauma to the shoulder with a higher prevalence of subdeltoid-subacromial bursitis.

The relationship between limited functional shoulder ROM and abnormal ultrasonographic findings was also investigated in the present study. It was hypothesized that limited shoulder flexion may result from pathology in the biceps tendon, as the biceps tendon plays a significant role in this motion (36). The present study showed that limited shoulder flexion was associated with positive dynamic supraspinatus, which differed from the initial hypothesis of the present study. If patients present with limited shoulder flexion, the pathology may involve not only the biceps tendon but also positive dynamic supraspinatus impingement. Restricted shoulder abduction could also result from supraspinatus tendon pathology and nearby structures, as this tendon plays an important role in this motion (37). This aligns with the findings of the present study, which showed that limited shoulder abduction was significantly associated with subdeltoid and subacromial bursitis, as well as positive dynamic supraspinatus impingement. It resembles the assessment of specific tests, such as the Jobe test (38). It has also been previously reported that posterior capsule shoulder thickening, as well as muscle spasm of the posterior deltoid, infraspinatus and teres minor can cause internal rotation limitation (39). The coraco-humeral ligament, which is usually the first structure to be affected in adhesive capsulitis, restricts mainly external rotation and additionally internal rotation of the shoulder joint (40). However, in the present study, it was found that the most common ultrasonographic abnormality in limited shoulder internal rotation was positive dynamic supraspinatus impingement. The results of the present study thus differed from the initial hypothesis. Therefore, it should be cautioned that relying solely on physical examination may not accurately indicate the true pathology. It may be recommended to combine physical examination with simultaneous ultrasound for a more comprehensive diagnosis of any shoulder abnormalities.

The study by Malavolta *et al* (41) from 2018 found that Asian ethnicity is an independent risk factor for the development of adhesive capsulitis. However, there is no published study showing any inter-ethnic difference in the MSK US examination result in patients with adhesive capsulitis. This provides an interesting area for future research. In the present study, all patients had abnormal ultrasound findings, and it was therefore not possible to comparatively analyze factors associated with shoulder ultrasonographic abnormalities. It may be recommended that ultrasound should ideally be conducted in every case of adhesive capsulitis and it is important to compare ultrasound results with physical examinations to identify a possible diagnosis.

The present study had certain limitations that are worth mentioning. First, the cross-sectional design limits the determination of the temporal relationship of adhesive capsulitis with the development of ultrasonographic abnormalities and it also lacks a comparison group. Further studies are required with a cohort of patients from multiple hospitals and potentially multiple countries. Furthermore, most patients had undergone prior treatments that could have influenced the ultrasound findings. In addition, the associations between shoulder ultrasound abnormalities and severity of their underlying disease or various psychosocial factors such as anxiety, stress and poor sleep were not determined in the present study. Consequently, future research should address these variables to assess their potential impact on shoulder pain or shoulder ultrasound abnormalities and should also compare them to gold standard tests such as arthroscopy or MRI in controlled trials with a larger sample size than that of the present study. Furthermore, in the present study, MSK US was performed by only one specialist, which is a limitation due to the absence of confirmation from a second specialist. It may be encouraged that physicians perform ultrasound in patients with adhesive capsulitis and compare ultrasound results with physical examinations to identify a possible diagnosis. However, it should be noted that an abnormal ultrasonographic finding is not a definite diagnosis for adhesive capsulitis in each patient, and the final diagnosis should be based on the individual patient's clinical and overall ultrasonographic findings.

In conclusion, in the present study, abnormal shoulder ultrasonographic findings were found to be prevalent in individuals with adhesive capsulitis. The most common abnormal ultrasonographic imaging findings in adhesive capsulitis were biceps tendon effusion, positive dynamic supraspinatus impingement and subdeltoid-subacromial bursitis.

Acknowledgements

The authors would like to acknowledge Professor John F Smith for editing the manuscript via the KKU Publication Clinic, Srinagarind Hospital, Faculty of Medicine, Khon Kaen University, Khon Kaen, Thailand.

Funding

This study was supported by the Faculty of Medicine Research Fund, Khon Kaen University (grant no. IN66032).

Availability of data and materials

The data generated in the present study may be requested from the corresponding author.

Authors' contributions

AM and PS confirm the authenticity of all the raw data. AM, JS and PS designed the study. AM and JS interpreted the data. AM and PS wrote the manuscript. AM and JS performed statistical analysis. All authors have read and approved the final manuscript.

Ethics approval and consent to participate

The study was reviewed and approved by the Khon Kaen University Ethics Committee for Human Research (approval no. HE651371). All participants provided written informed consent to participate in the study.

Patient consent for publication

Not applicable.

Competing interests

The authors declare they have no competing interests.

References

1. Dias R, Cutts S, and assoud S: Frozen shoulder. BMJ 331: 1453-1456, 2005.
2. Safran O, El-Haj M, Leibowitz G, Beyth S, Furman Z, Milgrom C and Kandel L: Should patients with frozen shoulder be screened for diabetes mellitus? Orthop J Sports Med 5: 2325967117716450, 2017.
3. Le HV, Lee SJ, Nazarian A and Rodriguez EK: Adhesive capsulitis of the shoulder: Review of pathophysiology and current clinical treatments. Shoulder Elbow 9: 75-84, 2017.
4. Mezian K, Coffey R and Chang KV: Frozen Shoulder. In: StatPearls. StatPearls Publishing, Treasure Island, FL, 2024. Available from: https://www.ncbi.nlm.nih.gov/books/NBK482162/.
5. Hannafin JA and Chiaia TA: Adhesive capsulitis. A treatment approach. Clin Orthop Relat Res 372: 95-109, 2000.
6. Hand GC, Athanasou NA, Matthews T and Carr AJ: The pathology of frozen shoulder. J Bone Joint Surg Br 89: 928-932, 2007.
7. Walmsley S, Osmotherly PG and Rivett DA: Movement and pain patterns in early stage primary/idiopathic adhesive capsulitis: A factor analysis. J Physiother 100: 336-343, 2014.
8. Brun S: Idiopathic frozen shoulder. Aust J Gen Pract 48: 757-761, 2019.
9. Redler LH and Dennis ER: Treatment of adhesive capsulitis of the shoulder. J Am Acad Orthop Surg 27: e544, 2019.
10. Ryan V, Brown H, Minns Lowe CJ and Lewis JS: The pathophysiology associated with primary (idiopathic) frozen shoulder: A systematic review. BMC Musculoskele Disord 17: 340, 2016.
11. Fields BKK, Skalski MR, Patel DB, White EA, Tomasian A, Gross JS and Matcuk GR Jr: Adhesive capsulitis: Review of imaging findings, pathophysiology, clinical presentation, and treatment options. Skeletal Radiol 48: 1171-1184, 2019.
12. Özçakar L, Kara M, Chang KV, Çarl AB, Akkaya N, Tok F, Chen WS, Wang TG, Tekin L, Ulaşl AM, *et al*: Nineteen reasons why physiatrists should do musculoskeletal ultrasound: EURO-MUSCULUS/USPRM recommendations. Am J Phys Med Rehabil 94: e45-49, 2015.
13. Homsi C, Bordalo Rodrigues M, da Silva JJ and Stump XM: Ultrasound in adhesive capsulitis of the shoulder: Is assessment of the coracohumeral ligament a valuable diagnostic tool? Skelet Radiol 35: 673-678, 2006.

14. Tandon A, Dewan S, Bhatt S, Jain AK and Kumari R: Sonography in diagnosis of adhesive capsulitis of the shoulder: A case-control study. J Ultrasound 20: 227-236, 2017.
15. Jiang L, He J, Chen CPC, Xie D, Mai Y, Yue B and Dou Z: The ultrasonographic features of shoulder pain patients in a tertiary hospital in South China. Biomed Res Int 2020: e3024793, 2020.
16. Do JG, Hwang JT, Yoon KJ and Lee YT: Correlation of ultrasound findings with clinical stages and impairment in adhesive capsulitis of the shoulder. Orthop J Sports Med 9: 23259671211003675, 2021.
17. Al Khayyat SG, Falsetti P, Conticini E, Frediani B, Galletti S and Stella SM: Adhesive capsulitis and ultrasound diagnosis, an inseparable pair: A novel review. J Ultrasound 26: 369-384, 2023.
18. Lee JC, Sykes C, Saifuddin A and Connel D: Adhesive capsulitis: Sonographic changes in the rotator cuff interval with arthroscopic correlation. Skelet Radiol 34: 522-527, 2005.
19. Draghi F, Scudeller L, Draghi AG and Bortolotto C: Prevalence of subacromial-subdeltoid bursitis in shoulder pain: An ultrasonographic study. J Ultrasound 18: 151-158, 2015.
20. Ueda Y, Sugaya H, Takahashi N, Matsuki K, Kawai N, Tokai M, Onishi K and Hoshika S: Rotator cuff lesions in patients with stiff shoulders: A prospective analysis of 379 shoulders. J Bone Joint Surg Am 97: 1233-1237, 2015.
21. El Naggar TEDM, Maaty AIE and Mohamed AE: Effectiveness of radial extracorporeal shock-wave therapy versus ultrasound-guided low-dose intra-articular steroid injection in improving shoulder pain, function, and range of motion in diabetic patients with shoulder adhesive capsulitis. J Shoulder Elbow Surg 29: 1300-1309, 2020.
22. Çelik D and Kaya Mutlu E: Does adding mobilization to stretching improve outcomes for people with frozen shoulder? A randomized controlled clinical trial. Clin Rehabil 30: 786-794, 2016.
23. Abate M, Schiavone C and Salini V: Sonographic evaluation of the shoulder in asymptomatic elderly subjects with diabetes. BMC Musculoskelet Disord 11: 278, 2010.
24. Phongamwong C and Choosakde A: Reliability and validity of the Thai version of the Shoulder Pain and Disability Index (Thai SPADI). Health Qual Life Outcomes 13: 136, 2015.
25. Roach KE, Budiman-Mak E, Songsiridej N and Lertratanakul Y: Development of a shoulder pain and disability index. Arthritis Care Res 4: 143-149, 1991.
26. Wakefield RJ, Balint PV, Szkudlarek M, Filippucci E, Backhaus M, D'Agostino MA, Sanchez EN, Iagnocco A, Schmidt WA, Bruyn GA, *et al*: Musculoskeletal ultrasound including definitions for ultrasonographic pathology. J Rheumatol 32: 2485-2487, 2005.
27. Namdari S, Yagnik G, Ebaugh DD, Nagda S, Ramsey ML, Williams GR Jr and Mehta S: Defining functional shoulder range of motion for activities of daily living. J Shoulder Elbow Surg 21: 1177-1183, 2012.
28. Doğan M, Koçak M, Onursal Kılınç Ö, Ayvat F, Sütçü G, Ayvat E, Kılınç M, Ünver Ö and Aksu Yıldırım S: Functional range of motion in the upper extremity and trunk joints: Nine functional everyday tasks with inertial sensors. Gait Posture 70: 141-147, 2019.
29. Klauser AS, Tagliafico A, Allen GM, Boutry N, Campbell R, Court-Payen M, Grainger A, Guerini H, McNally E, O'Connor PJ, *et al*: Clinical indications for musculoskeletal ultrasound: A Delphi-based consensus paper of the European Society of musculoskeletal Radiology. Eur Radiol 22: 1140-1148, 2012.
30. Park I, Lee HJ, Kim SE, Bae SH, Lee KY, Park KS and Kim YS: Evaluation of the effusion within biceps long head tendon sheath using ultrasonography. Clin Orthop Surg 7: 351-358, 2015.
31. Stella SM, Gualtierotti R, Ciampi B, Trentanni C, Sconfienza LM, Del Chiaro A, Pacini P, Miccoli M and Galletti S: Ultrasound features of adhesive capsulitis. Rheumatol Ther 9: 481-495, 2022.
32. Zubler V, Mamisch-Saupe N, Pfirrmann CW, Jost B and Zanetti M: Detection and quantification of glenohumeral joint effusion: Reliability of ultrasound. Eur Radiol 21: 1858-1864, 2011.
33. Hanusch BC, Makaram N, Utrillas-Compaired A, Lawson-Smith MJ and Rangan A: Biceps sheath fluid on shoulder ultrasound as a predictor of rotator cuff tear: Analysis of a consecutive cohort. J Shoulder Elbow Surg 25: 1661-1667, 2016.
34. Chang KV, Wu WT and Özçakar L: Association of bicipital peritendinous effusion with subacromial impingement: A dynamic ultrasonographic study of 337 shoulders. Sci Rep 6: 38943, 2016.
35. Kim I, Yi JH, Lee J, Bae JH, Lim JK, Yoon JP and Jeon IH: Limited subacromial gliding of the supraspinatus tendon during dynamic ultrasonography can predict a decrease in capacity and MR arthrographic features of the shoulder joint. Eur Radiol 22: 2365-2370, 2012.
36. Diplock B, Hing W and Marks D: The long head of biceps at the shoulder: A scoping review. BMC Musculoskelet Disord 24: 232, 2023.
37. Jeno SH, Munjal A and Schindler GS: Anatomy, Shoulder and Upper Limb, Arm Supraspinatus Muscle. In: StatPearls. StatPearls Publishing, Treasure Island, FL, 2024.
38. Gillooly JJ, Chidambaram R and Mok D: The lateral Jobe test: A more reliable method of diagnosing rotator cuff tears. Int J Shoulder Surg 4: 41-43, 2010.
39. Saldiran TC and Yilmaz O: Which one is the most limited movement in restricted shoulder joint. J Hum Mov 20: 72-78, 2019.
40. Cho CH, Kim DH, Kim DH, Choi BC, Kim SG, Lee DG and Cho JH: Comparative efficacy of rotator interval versus posterior capsule approach intraarticular corticosteroid injections for primary frozen shoulder: A single-blind, Randomized trial. Pain Physician 25: 313-321, 2022.
41. Malavolta EA, Gracitelli MEC, Ribeiro Pinto GM, Freire da Silveira AZ, Assunção JH and Ferreira Neto AA: Asian ethnicity: A risk factor for adhesive capsulitis? Rev Bras Ortop 53: 602-606, 2018.

Copyright © 2024 Moleesaide et al. This work is licensed under a Creative Commons Attribution-NonCommercial-NoDerivatives 4.0 International (CC BY-NC-ND 4.0) License.