

‘Malignant melanoma microecosystem’: Immunohistopathological insights into the stromal cell phenotype (Review)

PASCALE QUATRESOOZ, MARIE-ANNICK REGINSTER and GÉRALD E. PIÉRARD

Department of Dermatopathology, University Hospital of Liège, BE-4000 Liège, Belgium

Received December 9, 2010; Accepted February 14, 2011

DOI: 10.3892/etm.2011.221

Abstract. Cutaneous malignant melanoma (MM) is rooted in the dermal connective tissue, which consists of apparently unremarkable stromal cells as they appear upon regular histopathological examination. However, a number of *in vitro* studies have shown that these cells produce diverse types of cytokines, growth factors and enzymes in excess. In addition, they store and probably release various structural components of the extracellular matrix (ECM). Most of the current information comes from *in vitro* experiments, and these findings do not always correlate with investigations carried out using excised human MM tissue. The MM-stroma connection appears crucial to the regulation of neoplastic growth, invasiveness and initial metastatic spread. However, little is known about the *in vivo* intracellular storage and extracellular deposits of specific ECM macromolecules located inside and around MM lesions. This review summarizes various distinct features of the peri-MM stroma, which shows an intracytoplasmic abundance of Factor XIIIa, versican and various α (IV) collagen chains. The area exhibiting such changes corresponds to the location where neoangiogenesis commonly develops and where extravascular unicellular metastatic MM lesions are possibly found. Some of these inconspicuous migratory malignant melanocytes may actually correspond to MM stem cells. Their presence was found to be significantly associated with an increased risk for distant metastases, particularly in the sentinel lymph nodes. Although much remains to be learned, active intervention of the ECM appears likely in the inconspicuous early dermal metastatic migration of MM cells.

Contents

1. Introduction
2. Materials and methods
3. Malignant melanoma micrometastases

4. Stroma immunohistochemistry beneath malignant melanoma
5. Discussion
6. Conclusion

1. Introduction

Cutaneous malignant melanoma (MM) is basically an uncontrolled overgrowth of neoplastic melanocytes. At some stage of its progression, the neoplasm exhibits a high metastatic potential. It proves to be resistant to drug-induced apoptosis, which is believed to underlie the resistance of MM to conventional chemotherapy and radiotherapy (1,2). Various interactions exist between MM cells and other biological systems, including immune cells, vascularity, contiguous stromal cells and the dermal extracellular matrix (ECM). Certain aspects of MM-stroma interactions are thought to be associated with disease prognosis (3). In addition, environmental influences, including ultraviolet (UV) light, are probably responsible for MM initiation and may support its progression along with the intervention of diverse autocrine and paracrine factors (4). In particular, a number of growth factors and specific enzymes are released in the MM microenvironment (5-7).

The participation of the host in the ‘cancer microecosystem’ basically involves the microvasculature, stromal cells and specific immune reactions (8-10). Angiogenesis is a typical host-mediated response to many cancers. It appears crucial for cancer progression, as blood vessels deliver nutrients and oxygen to neoplastic cells (11). Furthermore, the microvasculature likely allows communication between the primary MM and its metastases. Pro-angiogenic molecules originate from cancer cells as well as from the stroma. The relative contribution of both compartments is likely to change with MM type and site, and is balanced by other factors as well (11,12).

Cross-talk between MM and stromal cells may be mediated through direct heterotypic cell-cell contacts, adhesion molecules, signaling factors, and other secreted molecules consisting of growth factors, cytokines, chemokines, ECM proteins, proteinases, proteinase inhibitors and lipid products (13). Conceptually, the MM microenvironment is crucial for the maintenance of cellular functions and tissue integrity, suggesting that a cancer-induced change in the ECM may contribute to cancer invasion (14). Any alteration in the MM stroma may be due to an imbalance in the cytokine profile, resulting from oncogenic changes in the cancer cells. In

Correspondence to: Dr Gérald E. Piérard, Department of Dermatopathology, CHU Sart Tilman, BE-4000 Liège, Belgium
E-mail: gerald.pierard@ulg.ac.be

Key words: malignant melanoma, fibroblast, collagen, versican, dermal extracellular matrix, cancer, metastasis

particular, experimental animal models have demonstrated that cancer invasion is stimulated by the wound-healing stroma (15).

Both stromal cells and the ECM located beneath primary MM lesions are therefore likely involved in the process of invasion of the neoplasm and in the early dissemination of micrometastases associated or not with neoangiogenesis (2,10,16-19). These characteristics are possibly associated with phenotypic changes in the stromal cells in the MM vicinity. In recent years, tumor growth regulation by ECM components has been one of the main topics of neoplastic biology research.

2. Materials and methods

This study is a review of current peer-reviewed publications admixed with personal original findings from a series of 400 MM cases with a thickness ranging between 0.4 and 1.0 mm (median 0.83) that were retrieved from our files. The microscopic diagnosis was previously established by a group of three dermatopathologists. Immunohistochemistry was performed as previously described (20-23). In short, samples were fixed in buffered formalin and embedded in paraffin. A series of 6- μ m sections were prepared for immunohistochemistry. The avidin-biotin peroxidase method was used with the antibodies listed in Table I. After 1 h of incubation with each primary antibody, the slides were washed in Tris-buffered saline (TBS) and incubated for 30 min with the secondary antibody (biotinylated swine anti-rabbit, 1:300; Dakopatts Glostrup, Denmark). Slides were rinsed in TBS and covered by the EnVision (Dakopatts) polymer-based revelation system. After TBS washings, Fast Red (Dakopatts) was used as the chromogen substrate. The final steps consisted of counterstaining with Mayer's hemalum and mounting in glycerin mounting medium (Dakopatts). Negative immunohistochemical controls were performed by omitting or substituting the primary and the secondary antibodies from the laboratory procedure.

3. Malignant melanoma micrometastases

A typical biological feature of human MM is the tremendous impact of the primary lesion thickness on prognosis. Primary MM <1 mm in thickness is associated with a high cure rate, sharply contrasting with thicker lesions associated with poorer prognosis. The apparent breakpoint beyond an ~1-mm thickness is a discouraging factor in disease outcome. One possible reason appears to be linked to vascularization patterns of MM (11,12). Such an anatomic argument is persuasive, but it is by no means the only one.

MM cells apparently fail to form metastases unless they present the genotypic and phenotypic information allowing them to effectively migrate in the ECM, intravasate, extravasate, cross interstitial basement membranes and proliferate in distant tissue sites. These characteristics are expressed by variant subpopulations of metastatically competent MM cells present in primary neoplasms (2). These subpopulations probably acquire a growth advantage at the primary site over time, so that they become a dominant proliferating population. At this stage, the MM truly expresses overt malignancy. As a result of this process of clonal dominance

Table I. Panel of antibodies.

Antigen	Dilution	Source
α 1 (IV) collagen	1:25	Arnold I Caplan
α 5 (IV) collagen	1:25	Weiselab
Elafin	1:500	Santa Cruz Biotechnology
Factor XIIIa	1:100	Neomarkers
Lysozyme	1:300	Dako
Versican	1:500	Seikagaku Corp.

of metastatically competent cells, it is possible that most thin primary MM lesions contain very few, if any, metastatically competent cells, whereas thicker MM lesions may contain significant proportions of such cells. It is possible that the stromal microenvironment plays a role in such a shift in the biological profile of MM (24).

The four metastatic routes. In order to form metastases at distant sites, MM cells must acquire certain functions and properties in an ordered sequence referred to as the MM metastatic cascade. In order to form overt metastasis, this process must encompass hyperproliferation, detachment from the primary neoplasm, invasion into the peritumoral stroma and possibly penetration into blood and lymphatic vessels, survival in the circulation, adhesion to a vessel wall at the site of the final metastatic deposition, extravasation and proliferation (3).

The specific function involved in the metastatic cascade combines intrinsic characteristics of various MM cells and regulatory influences from the microenvironment. Indeed, MM cells and their surrounding stroma jointly form a microecosystem receptive or not to early inconspicuous metastatic spread.

Early MM micrometastases are not discernable upon regular clinical or dermoscopic examination. They are disclosed under the microscope, particularly after highlighting their presence using immunohistochemistry (2,17). They are found in four distinct locations, namely i) inside lymph vessels, ii) inside blood vessels, iii) in a perivascular location just adjacent to the outer area of the endothelial lining, and iv) dispersed inside the stroma (10,16,18). The latter eventuality is not infrequently associated with neoangiogenesis, and an enhanced neoplastic generative pool is commonly found (10,19).

The active migration of metastatic MM cells in the peritumoral stroma is probably a complex process. It involves the active mobility of MM cells and changes in the neoplastic cell adherence systems with ECM components.

Melanoma stem cells. The presence of MM stem cells is an important consideration when investigating the characteristics of MM micrometastases and their relationship with the peritumoral stroma (10,22,25-27). Similar to physiological stem cells, cancer stem cells are capable of self-renewal and differentiation, and have the potential for indefinite proliferation, a function linked to MM growth (2,22,28). Although conventional anticancer treatments may eradicate most malignant cells, they are potentially ineffective against chemoresistant cancer stem cells, which are ultimately responsible for tumor recurrence and

progression (2,10,25). MM shows tumor heterogeneity, undifferentiated molecular signatures and increased tumorigenicity of MM subsets with embryonic-like differentiation plasticity. This strongly suggests the presence and involvement of MM stem cells in the initiation and propagation of this malignancy (25-27,29-32). The ECM structure and biologic activity may influence the invasiveness and propagation of MM stem cells.

Micrometastases and the peri-melanoma stroma. When present, interstitial unicellular MM micrometastases are frequently found and confined to the perineoplastic stroma. Their presence is significantly correlated with the risk of involvement of the sentinel lymph node (17).

4. Stroma immunohistochemistry beneath malignant melanoma

Upon standard histopathological examination, stromal cells appear normal underneath primary MM lesions when partial regression is not operative. However, their differentiation as revealed by immunohistochemistry appears altered when compared to the surrounding skin. In particular, phenotypic changes are noted when identifying the transglutaminase Factor XIIIa, α (IV) collagen chains, as well as elafin and versican. It is possible, although not yet proven, that transforming growth factor (TGF)- β 1 and platelet-derived growth factor (PDGF) may play a role in the alteration of the stromal host compartment in MM.

Factor XIIIa-enriched stromal cells. Factor XIIIa-enriched stromal cells are commonly identified as dermal dendrocytes (DDs). They are preferentially found adjacent to superficial microvasculature (24,33-35). Increased numbers of Factor XIIIa-positive DDs are often found in the vicinity of most invasive cutaneous neoplasms. In our experience, Factor XIIIa-positive DDs are numerous; they neighbor and infiltrate most thin MM lesions (24). By contrast, they are present in few numbers or even absent in thick primary MM lesions and their metastases (36-38). Circumstantial evidence indicates that the density of Factor XIIIa-positive DDs is correlated with a low proliferative rate of MM cells. Thus, Factor XIIIa-positive DDs may not be passive bystanders in MM (24,34,36). Their function may differ based on whether they are located in the stroma or inside the neoplasm (24). Intratumoral DDs may be associated with a growth-restricting role. By contrast, stromal DDs may help in the invasiveness and metastatic spread of MM cells.

Collagen IV-enriched stromal cells. In malignant neoplasms, basement membranes (BMs) are composite structures synthesized by tumor cells or stromal cells; either by one of these two cell types yet dependent on the interactions between them, or a mixture from both origins. These tumoral BMs are often abnormal in their composition and ultrastructural features (39,40). BM material appears to accompany malignant cells rather than to prevent invasion as a physical barrier. Nevertheless, active interactions between neoplastic cells and stroma, in particular the ECM, play a key role in neoplastic progression leading to invasion and metastasis (41). Several BM components have been identified surrounding MM cells, including collagen IV (39,42-44). In the skin,

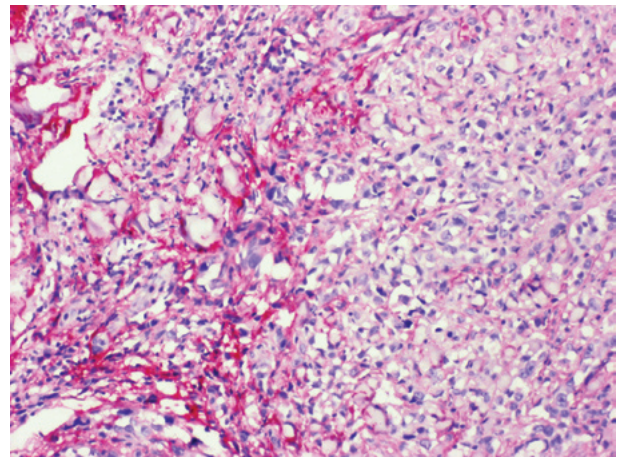


Figure 1. Versican immunoreactivity in stromal cells adjacent to MM.

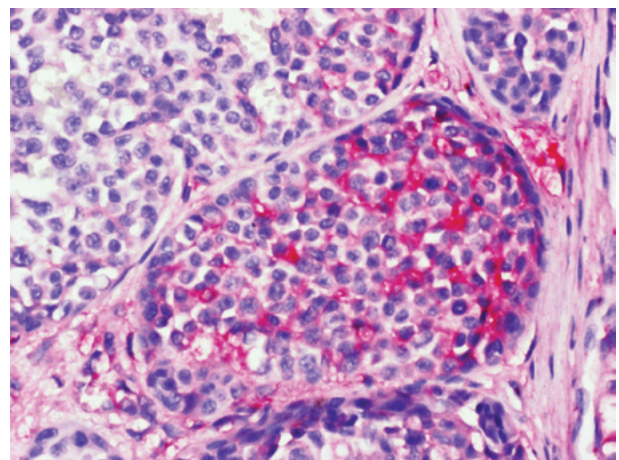


Figure 2. Versican immunoreactivity in a nest of MM cells.

collagen IV represents an assembly of α 1 (IV) and α 5 (IV) collagen chains. In MM, some neoplastic and stromal cells exhibit intracytoplasmic immunolabeling for α 1 (IV) chains (44). The pattern is heterogeneous. BM components, including collagen IV, gradually disappear during the dermal ingrowth of MM cells. Notably, a minority of MM cases without any identifiable micrometastasis and a majority of MM with cutaneous micrometastasis show discrete cytoplasmic positivity for the α 5 (IV) collagen chain (44).

Distribution of the α 1 (IV) collagen chain in MM highlights the heterogeneity in both cell differentiation and stroma-MM interactions. Thus, MM cells appear to have their own individual potential to be enclosed by a BM and to interact with the stroma. This biological aspect may be related to neoplastic progression and may influence inconspicuous metastatic potential.

Versican-enriched stromal cells. Versican is a large proteoglycan normally present inside the stromal cells of the skin. The molecule belongs to the chondroitin sulfate family of the hyalectan group, named for its ability to bind hyaluronan (45). In mammals, versican appears as four possible spliced isoforms, V0 to V3. Little is known concerning the differential regulation of the isoforms or about their respective roles in

the ECM either normal or peritumoral. Versican production is deregulated in several types of human cancer (46). As it is largely expressed in rapidly growing neoplastic cells, it has been suggested that versican plays a direct role in cell proliferation and other cell functions (45). It appears to be particularly abundant in the stromal cell population underlying MM (Fig. 1) (46-49). Versican overexpression was found to sharply circumscribe to a cup-shaped structure cuffing the bottom of MM lesions. In addition, some nests of MM cells were found to be strongly labeled with the anti-versican antibody (Fig. 2). This finding contrasts with another study reporting the absence of versican immunoreactivity in neoplastic melanocytes (49). In addition, versican expression is not correlated with Breslow tumor thickness and Clark's level (49).

Elafin-, versican- and lysozyme-loaded ECM. Elastic fibres are coated with distinct molecules following chronic UV exposure (50-53). The serine anti-leukoprotease elafin, as well as versican and lysozyme, bind to elastin preventing elastolytic degradation by elastases on sun-exposed areas exhibiting solar elastosis (51,53,54). Under these conditions, the labeling was found to range from partial, moderate to strong. In addition, inhibition of elastase may decrease the adhesion of cancer cells to endothelial cells (55).

In addition, elafin was reported to elicit p53-dependent apoptosis in cultured MM cells transfected by a plasmid-producing elafin under doxycycline boosting (56). In contrast to these *in vitro* experiments, immunohistochemistry did not disclose an intratumoral cell presence of elafin in human MM. Rather, keratinocytes covering MM overexpressed elafin in their cytoplasm. Of note, Western blotting and reverse transcription analyses indicated transcriptional elafin repression in MM cells (56).

The implication of elafin in other diseases, such as psoriasis and graft-versus-host reaction, indicates its distinct importance in skin biology (57,58).

5. Discussion

This review highlights the existence of a distinct region of the dermis adjacent to the base of a primary MM lesion. Stromal cells exhibit particular phenotypic features suggesting altered functionality. The involved territory appears to be conducive to micrometastatic spread. Some of these cells survive singly, and due to their manner of migration to other organs may represent MM stem cells.

In addition to the importance of MM vascularization for tumor growth, invasiveness and metastatic spread (10-12,19,59), numerous other roles are ascribed to the tumoral stroma. This structure is involved in a constant remodeling following degradation and repair of the ECM. Notably, immunohistochemistry highlights the direct implication of MM cells in the synthesis and/or storage of certain ECM molecular components.

The immunohistochemical characterization of MM cells is important (20,22,60-64), yet should be extended to the peritumoral stroma, including the microvasculature (10-12,59) and other ECM components. A comprehensive mapping of MM immunohistochemical characteristics should aid in identifying relevant targeted therapies (63-66).

Inflammatory cells and immunocytes represent another class of host cells that are regulated by the balance of cytokines. They perform counter-current invasion, from the circulation into the tumor, and provide routes for MM cell invasion. It is important for our understanding of MM stroma turnover that tumor-infiltrating leukocytes produce proteinases.

6. Conclusion

Interaction between MM and its stroma is evident during the invasive and metastatic stages of disease progression. Stromal cells are known to secrete metalloproteinases and their inhibitors, growth factors, the scatter factor/hepatocyte growth factor and other factors, as well as participate in the growth and mobility of MM cells. In addition, other molecules are synthesized and overexpressed by stromal cells and/or MM cells. Immunohistochemistry has identified Factor XIII-a, $\alpha 1$ and $\alpha 5$ (IV) collagen chains, versican, elafin and lysozyme. These possibly influence the migration of MM cells, including their stem cells.

While MM cell motility cannot be directly assessed, there is circumstantial evidence indicating that motility is essential to MM progression and possibly of prognostic significance. Apart from the secretion and activation of enzymes altering the ECM, a variety of stromal alterations occur following overexpression of diverse ECM components. Molecular morphology yields evidence suggesting that the MM stroma plays an integral role in MM. Although much remains to be determined, the findings as described in the present review may have diagnostic and prognostic significance, which warrant further investigation.

Acknowledgements

This study was supported by a grant from the 'Fonds d'Investissement de la Recherche Scientifique' of the University Hospital of Liège. No other sources of funding were used to assist in the preparation of this manuscript. The authors appreciate the excellent secretarial assistance of Mrs. Ida Leclercq and Mrs. Marie Pugliese.

References

1. Dean M, Fojo T and Bates S: Tumour stem cells and drug resistance. *Nat Rev Cancer* 5: 275-284, 2005.
2. Quatresooz P and Piérard GE: Malignant melanoma: from cell kinetics to micrometastases. *Am J Clin Dermatol*: Dec. 13, 2010 (E-pub ahead of print).
3. Smolle J, Hofmann-Wellenhof R and Fink-Puches R: Melanoma and stroma: an interaction of biological and prognostic importance. *Semin Cutan Med Surg* 15: 326-335, 1996.
4. Bennett DC: Ultraviolet wavebands and melanoma initiation. *Pigment Cell Melanoma Res* 21: 520-524, 2008.
5. Brenner M, Degitz K, Besch R and Berking C: Differential expression of melanoma-associated growth factors in keratinocytes and fibroblasts by ultraviolet A and ultraviolet B radiation. *Br J Dermatol* 153: 733-739, 2005.
6. Philips N, Keller T and Holmes C: Reciprocal effects of ascorbate on cancer cell growth and the expression of matrix metalloproteinases and transforming growth factor-beta. *Cancer Lett* 256: 49-55, 2007.

7. Philips N, Conte J, Chen YJ, Natrajan P, Taw M, Keller T, Givant J, Tuason M, Dulaj L, Leonardi D and Gonzalez S: Beneficial regulation of matrix-metalloproteinases and their inhibitors, fibrillar collagens and transforming growth factor- β by *Polypodium leucotomos*, directly or in dermal fibroblasts, ultraviolet-radiated fibroblasts, and melanoma cells. *Arch Dermatol Res* 301: 487-495, 2009.
8. Dvorak HF: Tumors: wounds that do not heal. *N Engl J Med* 315: 1650-1659, 1986.
9. De Wever O and Mareel M: Role of tissue stroma in cancer cell invasion. *J Pathol* 200: 429-447, 2003.
10. Quatresooz P, Piérard-Franchimont C, Paquet P and Piérard GE: Angiogenic fast-growing melanomas and their micrometastases. *Eur J Dermatol* 20: 302-307, 2010.
11. Piérard GE and Piérard-Franchimont C: Stochastic relationship between the growth fraction and vascularity of thin malignant melanomas. *Eur J Cancer* 33: 1888-1892, 1997.
12. Piérard-Franchimont C, Henry F, Heymans O and Piérard GE: Vascular retardation in dormant growth-stunted malignant melanomas. *Int J Mol Med* 4: 403-406, 1999.
13. Wernert N: The multiple roles of tumour stroma. *Virchows Arch* 430: 433-443, 1997.
14. Liotta LA and Kohn EC: The microenvironment of the tumour-host interface. *Nature* 411: 375-379, 2001.
15. Dingemans KP, Zeeman-Boeschoten IM, Keep RF and Das PK: Transplantation of colon carcinoma into granulation tissue induces an invasive morphotype. *Int J Cancer* 54: 1010-1016, 1993.
16. Lugassy C and Barnhill RL: Angiotropic malignant melanoma and extravascular migratory metastasis: description of 26 cases with emphasis on a new mechanism of tumor spread. *Pathology* 36: 485-490, 2004.
17. Claessens N, Piérard GE, Piérard-Franchimont C, Arrese JE and Quatresooz P: Immunohistochemical detection of incipient melanoma micrometastases. Relationship with sentinel lymph node involvement. *Melanoma Res* 15: 107-110, 2005.
18. Lugassy C and Barnhill RL: Angiotropic melanoma and extravascular migratory metastasis. A review. *Adv Anat Pathol* 14: 195-201, 2007.
19. Quatresooz P, Piérard GE, Piérard-Franchimont C, Humbert P and Piérard S: Introduction to the spectral analysis of microvasculature in primary cutaneous melanoma. *Pathol Biol*: Feb, 2010 (E-pub ahead of print).
20. Quatresooz P, Arrese JE, Piérard-Franchimont C and Piérard GE: Immunohistochemical aid at risk stratification of melanocytic neoplasms. *Int J Oncol* 24: 211-216, 2004.
21. Quatresooz P, Piérard-Franchimont C and Piérard GE: Highlighting the immunohistochemical profile of melanocytomas. *Oncol Rep* 19: 1367-1372, 2008.
22. Quatresooz P, Piérard GE, Piérard-Franchimont C and the Mosan Study Group of Pigmented Tumors: Molecular pathways supporting the proliferation staging of malignant melanoma. *Int J Mol Med* 24: 295-301, 2009.
23. Quatresooz P, Piérard-Franchimont C, Piérard GE and the Mosan Study Group of Pigmented Tumors: Molecular histology on the diagnostic cutting edge between malignant melanomas and cutaneous melanocytomas. *Oncol Rep* 22: 1263-1267, 2009.
24. Piérard-Franchimont C, Arrese JE, Nikkels AF, Al Saleh W, Delvenne P and Piérard GE: Factor XIIIa-positive dermal dendrocytes and proliferative activity of cutaneous cancers. *Virchows Arch* 429: 43-48, 1996.
25. Schatton T and Franck MH: Cancer stem cells and human malignant melanoma. *Pigment Cell Melanoma Res* 21: 39-55, 2007.
26. Rappa G, Fodstad O and Lorico A: The stem cell-associated antigen CD133 (Prominin-1) is a molecular therapeutic target for metastatic melanoma. *Stem Cells* 26: 3008-3017, 2008.
27. Schatton T, Murphy GF, Frank NY, *et al*: Identification of cells initiating human melanomas. *Nature* 451: 345-349, 2008.
28. Cramer SF: Stem cells for epidermal melanocytes. A challenge for students of dermatopathology. *Am J Dermatopathol* 31: 331-341, 2009.
29. Fang D, Nguyen TK, Leishear K, Finko R, Kulp AN, Hotz S, van Belle PA, Xu X, Elder DE and Herlyn M: A tumorigenic subpopulation with stem cell properties in melanomas. *Cancer Res* 65: 9328-9337, 2005.
30. Grichnik JM, Burch JA, Schulteis RD, Shan S, Liu J, Darrow TL, Vervaert CE and Seigler HF: Melanoma, a tumor based on a mutant stem cell? *J Invest Dermatol* 126: 142-153, 2006.
31. Buac K and Pavan WJ: Stem cells of the melanocyte lineage. *Cancer Biomark* 3: 203-209, 2007.
32. Klein WM, Wu BP, Zhao S, Wu H, Klein-Szanto AJ and Tahan SR: Increased expression of stem cell markers in malignant melanoma. *Mod Pathol* 20: 102-107, 2007.
33. Arrese Estrada J and Piérard GE: Factor XIIIa-positive dendrocytes and the dermal microvascular unit. *Dermatologica* 180: 51-53, 1990.
34. Quatresooz P, Paquet P, Hermanns-Lê T and Piérard GE: Molecular mapping of Factor XIIIa-enriched dendrocytes in the skin. *Int J Mol Med* 22: 403-409, 2008.
35. Quatresooz P and Piérard GE: Immunohistochemical clues at aging of the skin microvascular unit. *J Cutan Pathol* 36: 39-43, 2009.
36. Fullen DR and Headington JT: Factor XIIIa-positive dermal dendritic cells and HLA-DR expression in radial versus vertical growth-phase melanomas. *J Cutan Pathol* 25: 553-558, 1998.
37. Denton KJ, Cotton DW, Wright A and Hird P: Factor XIIIa in nodular malignant melanoma and Spitz naevi. *Br J Dermatol* 12: 783-786, 1990.
38. Polak ME, Johnson P, Di Palma S, Higgins B, Hurren J, Borthwick NJ, Jager MJ, McCormick D and Cree IA: Presence and maturity of dendritic cells in melanoma lymph node metastases. *J Pathol* 207: 83-90, 2005.
39. Lugassy C, Eyden BP, Christensen L and Escande JP: Angio-tumoral complex in human malignant melanoma characterized by free laminin: ultrastructural and immunohistochemical observations. *J Submicrosc Cytol Pathol* 29: 19-28, 1997.
40. Schaumburg-Lever G, Lever I, Fehrenbacher B, Möller H, Bischof B, Kaiserling E, Garbe C and Rassner G: Melanocytes in naevi and melanomas synthesize basement membrane and basement membrane-like material. An immunohistochemical and electron microscopic study including immunoelectron microscopy. *J Cutan Pathol* 27: 67-75, 2000.
41. Van Duinen CM, Fleuren GJ and Bruijn JA: The extracellular matrix in pigmented skin lesions: an immunohistochemical study. *Histopathology* 24: 33-40, 1994.
42. Lugassy C, Kickersin GR, Christensen L, Karaoli T, Le Charpeniter M, Escande JP and Barnhill RL: Ultrastructural and immunohistochemical studies of the periendothelial matrix in malignant melanoma: evidence for an amorphous matrix containing laminin. *J Cutan Pathol* 26: 78-83, 1999.
43. Lugassy C, Shahsafaie A, Bonitz P, Busam KJ and Barnhill RL: Tumor microvessels in melanoma express the beta-2 chain of laminin. Implications for melanoma metastasis. *J Cutan Pathol* 26: 222-226, 1999.
44. Quatresooz P and Piérard GE: Immunohistochemical investigation of $\alpha 1$ (IV) and $\alpha 5$ (IV) collagen chains in a broad spectrum of melanocytic tumours. *Melanoma Res* 15: 161-168, 2005.
45. Wight TN: Versican: a versatile extracellular matrix proteoglycan in cell biology. *Curr Opin Cell Biol* 14: 617-623, 2002.
46. Serra M, Miquel L, Domenzain C, Docampo MJ, Fabra A, Wight TN and Bassols A: V3 versican isoform expression alters the phenotype of melanoma cells and their tumorigenic potential. *Int J Cancer* 114: 879-886, 2005.
47. Touab M, Villena J, Barranco C, Arumi-Uria M and Bassols A: Versican is differentially expressed in human melanoma and may play a role in tumor development. *Am J Pathol* 160: 549-557, 2002.
48. Docampo MJ, Rabanal RM, Miquel-Serra L, Hernandez D, Domenzain C and Bassols A: Altered expression of versican and hyaluronan in melanocytic tumors of dogs. *Am J Vet Res* 68: 1376-1385, 2007.
49. Gambichler T, Kreuter A, Grothe S, Altmeyer P, Brockmeyer HN and Rotterdam S: Versican overexpression in cutaneous malignant melanoma. *Eur J Med Res* 13: 500-504, 2008.
50. Seité S, Moyal D, Richard S, de Rigal J, Lévêque JL, Hourseau C and Fournatier A: Effects of repeated suberythral doses of UVA in human skin. *Eur J Dermatol* 7: 204-209, 1997.
51. Seité S, Zucchi H, Septier D, Igondjo-Tchen S, Senni K and Godeau G: Elastin changes during chronological and photo-ageing: the important role of lysozyme. *J Eur Acad Dermatol Venereol* 20: 980-987, 2006.
52. Piérard-Franchimont C, Uhoda I, Saint Léger D and Piérard GE: Androgenic alopecia and stress-induced premature senescence by cumulative ultraviolet light exposure. *Exog Dermatol* 1: 203-206, 2002.

53. Muto J, Kuroda K, Wachi H, Hirose S and Tajima S: Accumulation of elafin in actinic elastosis of sun-damaged skin: elafin binds to elastin and prevents elastolytic degradation. *J Invest Dermatol* 127: 1358-1366, 2007.
54. Williams SE, Brown TI, Roghanian A and Sallenave JM: SLPI and elafin: one glove, many fingers. *Clin Sci* 110: 21-35, 2006.
55. Nozowa F, Hirota M, Okabe A, Shibata M, Iwamura T, Haga Y and Ogawa M: Elastase activity enhances the adhesion of neutrophil and cancer cells to vascular endothelial cells. *J Surg Res* 94: 153-158, 2000.
56. Yu KS, Lee Y, Kim CM, Park EC, Choi J, Lim DS, Chung YH and Koh SS: The protease inhibitor, elafin, induces p53-dependent apoptosis in human melanoma cells. *Int J Cancer* 127: 1308-1320, 2010.
57. Kamsteeg M, Jansen PA, van Vlijmen-Willems IM, van Erp PE, Rodij-Olthuis D, van der Valk PG, Feuth T, Zeeuwen PL and Schalkwijk J: Molecular diagnostics of psoriasis, atopic dermatitis, allergic contact dermatitis and irritant contact dermatitis. *Br J Dermatol* 162: 568-578, 2010.
58. Paczesny S, Braun TM, Levine JE, *et al*: Elafin is a biomarker of graft-versus-host disease of the skin. *Sci Transl Med* 2: 13ra2, 2010.
59. Marcoval J, Moreno A, Graells J, Vidal A, Escriba JM, Garcia-Ramirez JM and Fabra A: Angiogenesis and malignant melanoma. Angiogenesis is related to the development of vertical (tumorigenic) growth phase. *J Cutan Pathol* 24: 212-218, 1997.
60. Alonso S, Ortiz P, Pollan M, Pérez-Gomez B, Sanchez L, Acuna MJ, Pajares R, Martinez-Tello FJ, Hortelano CM, Piris MA and Rodriguez-Peralto JL: Progression in cutaneous malignant melanoma is associated with distinct expression profiles. A tissue microarray-based study. *Am J Pathol* 164: 193-203, 2004.
61. Fecher LA, Cummings SD, Keefe MJ and Alani RM: Toward a molecular classification of melanoma. *J Clin Oncol* 25: 1606-1620, 2007.
62. Plaza JA, Suster D and Perez-Montiel D: Expression of immuno-histochemical markers in primary and metastatic malignant melanoma: a comparative study in 70 patients using a tissue microarray technique. *Appl Immunohistochem Mol Morphol* 15: 421-425, 2007.
63. Ohsie SJ, Sarantopoulos GP, Cochran AJ and Binder SW: Immunohistochemical characteristics of melanoma. *J Cutan Pathol* 35: 433-444, 2008.
64. Hamza S: Prognostic parameters of malignant melanoma. *Diagn Histopathol* 16: 330-336, 2010.
65. Schopfer G, Wellbrock C and Marais R: Melanoma biology and new targeted therapy. *Nature* 445: 851-857, 2007.
66. Piérard GE, Quatresooz P, Rorive A, Piérard-Franchimont C and Groupe Mosan d'Etude des Tumeurs Pigmentaires: Malignant melanoma: conceptual and therapeutic innovations based on translational research. *Rev Med Liège* 63: 579-584, 2008.
67. Basu B, Biswas S, Wrigley J, Sirohi B and Corrie P: Angiogenesis in cutaneous malignant melanoma and potential therapeutic strategies. *Exp Rev Anticancer Ther* 9: 1583-1598, 2009.
68. Sullivan RJ and Atkins MB: Molecular-targeted therapy in malignant melanoma. *Exp Rev Anticancer Ther* 9: 567-581, 2009.
69. Kerbel RS, Kobayashi H, Graham CH and Lu C: Analysis and significance of the malignant 'eclipse' during the progression of primary cutaneous human melanomas. *J Invest Dermatol Symp Proc* 1: 183-187, 1996.