

Treatment of condyloma acuminata in pregnant women with cryotherapy combined with proanthocyanidins: Outcome and safety

LI-JUAN YANG¹, DONG-NING ZHU¹, YAN-LING DANG¹ and XIONG ZHAO²

¹Department of Dermatology, Maternal and Child Health Hospital of Shaanxi, Xi'an, Shaanxi 710003;

²Department of Orthopedics, Xijing Hospital, The Fourth Military Medical University, Xi'an, Shaanxi 710032, P.R. China

Received January 11, 2015; Accepted February 25, 2016

DOI: 10.3892/etm.2016.3207

Abstract. Patients with condyloma acuminata (CA) during pregnancy represent a special risk group. The outcomes of many treatment methods for such cases are not satisfactory. The purpose of the present study was to evaluate the treatment outcome and safety of cryotherapy combined with proanthocyanidins (PCs) for CA in pregnant women. In this study, 46 pregnant women with CA were treated with cryotherapy combined with PCs. The lesions were sprayed with liquid nitrogen until the color of the wart changed from flesh colored to purple. A PC-containing formulation was then sprayed onto a non-woven fabric or single-layer gauze and applied to the affected area. The PC treatment was applied for 20 min, 2 or 3 times per day. All patients were followed up at 1 and 3 months. No visible warts remained after the cryotherapy and PC treatment. At the 1-month follow-up, only 1 case of recurrence was identified. At 3 months, 5 cases of recurrence were identified, and the recurrence rate was 10.9%. The satisfaction rate of the patients was 94% at 1 month and 87% at 3 months after treatment. All pregnancies resulted in healthy live births without delivery complications. Cryotherapy combined with PCs is indicated to be a safe and effective procedure and may serve as a treatment option for pregnant women with CA.

Introduction

Condyloma acuminata (CA) are symptomatic genital lesions caused by human papilloma virus (HPV). Patients who have CA during pregnancy are a particular risk group. During pregnancy, vaginal secretions contacting the skin and mucous membranes are more abundant (1), meaning that the vulva will remain in a moist and immersed state, which would be problematic for CA

patients. Several factors associated with pregnancy can promote the growth of HPV-induced lesions, for example, pregnancy hormones and reduced immunoresponsiveness. Cases of CA in pregnancy are normally characterized by fast-growing warts, and a reduced tolerance and poor compliance to treatment (2).

Only a small number of treatments have been tested and recommended in pregnancy; at present, bi- and tri-chloroacetic acid (BCA/TCA), cryotherapy, electrocautery and surgical excision, including laser treatment, are the only recommended treatments. In addition to high recurrence rates, significant side effects have been observed for these methods, including local ulceration and scar formation, which may reduce a patient's compliance with treatment requirements (3). Moreover, medicine could potentially cause fetal malformation and laser treatment and surgical excision may cause uterine contraction, or even abortion (1,4).

Cryotherapy is widely used for the treatment of CA. During the cryotherapy procedure, liquid nitrogen freezes the tissue and thereby causes necrosis; the treatment also stimulates specific immune responses, such as an immunomodulatory action of T lymphocytes against the remaining viable wart tissue (5,6). The advantages of cryotherapy are that it is simple, inexpensive, rarely causes scarring or depigmentation, and is safe for use in pregnancy.

Proanthocyanidins (PCs), extracted from ginkgo leaves, lotus and other plants, are plant polyphenols with strong antioxidant effects. PCs have been reported to exert antibacterial, antiallergic and antigenotoxic effects, and to inhibit platelet aggregation and capillary permeability (7-11). Studies have shown that PCs can be safely used to treat infants, pregnant women and the elderly, and are safe for application to the face, perineum and breasts (12,13). PCs have been found to be effective against redness, swelling, exudate, itching and other symptoms associated with inflammation (14).

In the present study, liquid nitrogen cryotherapy combined with PC treatment was applied to pregnant women with CA, and the safety and efficacy of the treatment was investigated.

Materials and methods

Study group. This retrospective study analyzed the records of 46 pregnant women who presented with CA (localized or

Correspondence to: Dr Xiong Zhao, Department of Orthopedics, Xijing Hospital, The Fourth Military Medical University, 17 Changlexi Road, Xi'an, Shaanxi 710032, P.R. China
E-mail: zhaoxiong314@163.com

Key words: condyloma acuminata, cryotherapy, proanthocyanidin, human papilloma virus, pregnancy

extended) that were treated with liquid nitrogen cryotherapy combined with PC. The patients were recruited from the dermatology clinic of the Maternal and Child Health (MCH) Hospital of Shaanxi Province (Xi'an, China) from May 2010 to February 2013. The mean age of the treated patients was 27 years (range, 23-34 years) and the patients were diagnosed with CA at a mean of 18 weeks (range, 10-26 weeks) gestation. CA was confirmed by the acetic acid white assay (15). The patients were made aware of the advantages of liquid nitrogen cryotherapy combined with PC treatment, and strongly requested to use it following the consideration of abortion, long-term fertility problems, and other relevant risks.

The study was approved by the Ethics Committee of the Maternal and Child Health (MCH) Hospital of Shaanxi Province. All participants signed an informed consent to participate in the research.

Lesion characteristics. The number of lesions treated for each case ranged from 5 to 18, with an average of 12.2 ± 5.5 lesions per patient. The warts differed in size, but each exhibited a broad pedicle, with a clear boundary and smooth, moist surface. In certain cases, fused lesions were present. The majority of lesions were gray-brown in color, while a few were dark red. There were 12 cases of lesions with a diameter >4 cm. The study group included 14 patients who were treatment naive, while the remainder had received repeated freezing, laser therapy, electrocautery and/or other treatments, including 5% Imiquimod cream, surgery and interferon, for 2-10 months. Scar formation was evident in 4 cases. Patients at risk of abortion were excluded from the study.

Treatment of the lesions. The lesions were first swabbed with 0.02% povidone-iodine solution. Then, liquid nitrogen was sprayed onto the lesions using a HX17-YDQ-500 liquid nitrogen gun (Far Western Science and Technology Co. Ltd., Beijing, China). The distance from the nozzle to lesions was 2-3 cm and the spray time was >60 sec and continued until the nozzle frosted (~ 2 min) and the nitrogen spray was no longer able to focus on the lesions. Spraying was also stopped if the patient felt pain. When the pain had lessened, the lesions were sprayed again until the color of the wart changed from flesh colored to purple. The Velvet Feeling (comprising PCs as the active ingredient; Lanke Hengye Medical Technology Co. Ltd., Changchun, China) was sprayed onto non-woven fabric or single-layer gauze was then applied to the affected area for 20 min, 2-3 times a day and for a period of one week.

Before the patient left the clinic, the clinician confirmed that the patient was able to see their lesions, and that examination with a hand-held mirror was possible. The patients were informed that they should examine the treated areas daily and advised to look for any symptoms of infection, including increased redness, swelling or discharge, with malodorous discharge or any other sign of infection, including fever, to be reported to the clinician immediately.

In the majority of cases, the necrotic tissue of the wart began to drop off 3 days after the treatment and the wart had completely dropped off by 1 week. In cases where the wart had not dropped off, varying degrees of narrowing of the wart were observed, and the clinician administered repeated treatments

Table I. Clinical characteristics of pregnant women with CA.

Clinical characteristic	Number of patients (%)
Delivery mode	
Natural childbirth	19 (41.3)
Cesarean section	27 (58.7)
Birth weight, g	
$<2,500$	1 (2.2)
2,500-4,000	41 (89.1)
$>4,000$	4 (8.7)
Gestational age, weeks	
<36	4 (8.7)
37-41	39 (84.8)
>42	3 (6.5)
Cases of recurrence	
1 month	1 (2.2)
3 month	5 (10.9)
CA, condyloma acuminata.	

using the aforementioned method. The treatment was stopped when no wart was detectable.

Patient follow-up. Photographic images of the lesions were captured prior to treatment and at each return visit. At 1 and 3 months following the liquid nitrogen cryotherapy, the patients were followed up for clinical evaluation. This included checking for lesion recurrence, encrustation, scab detachment, scar formation, changes in skin pigmentation and tolerance to pain. At each of these visits, the patient's satisfaction with the treatment results was surveyed. Each patient was asked to state whether they considered the treatment to be 'very satisfactory', 'fairly satisfactory' or 'unsatisfactory'.

Results

In general, the lesions were healed 5 days after the treatment. All patients reported no discomfort, with the exception of mild-to-moderate pain. No visible warts remained following the treatment. All patients were able to follow the treatment protocol, and responded to the survey with 94% satisfaction at 1 month and 87% satisfaction at 3 months after the completion of treatment. The patients who answered 'very satisfactory' and 'fairly satisfactory' were included in these calculations.

In some patients, various degrees of edema and erythema accompanied by mild-to-moderate burning pain occurred around the treatment area. However, the patients were able to tolerate these symptoms and successfully completed the treatment. Blisters in the treated area ruptured in 4 patients. The ruptured tissues healed within 4 days after the PC treatment. These events did not affect any subsequent treatments.

No depigmentation or scar formation was observed, and no patients reported any severe adverse events. Each pregnancy resulted in a healthy live birth without delivery complications. The therapeutic efficacy is demonstrated for two specific patients by photographic images in Figs. 1 and 2.

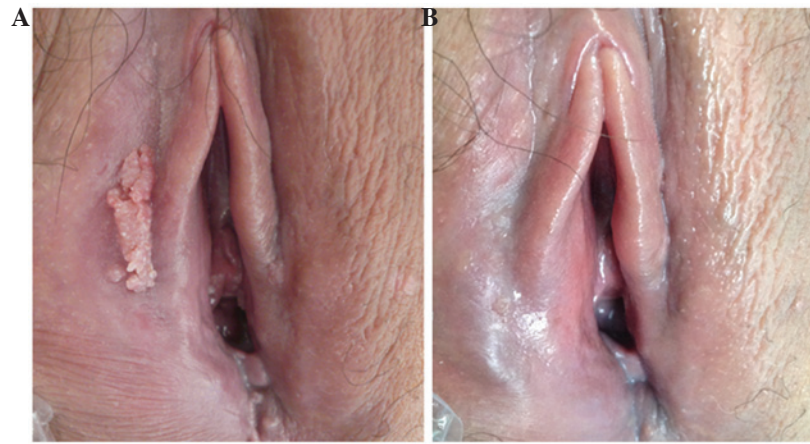


Figure 1. Lesions of case 1. (A) Prior to treatment and (B) after cryotherapy and treatment with proanthocyanidins.

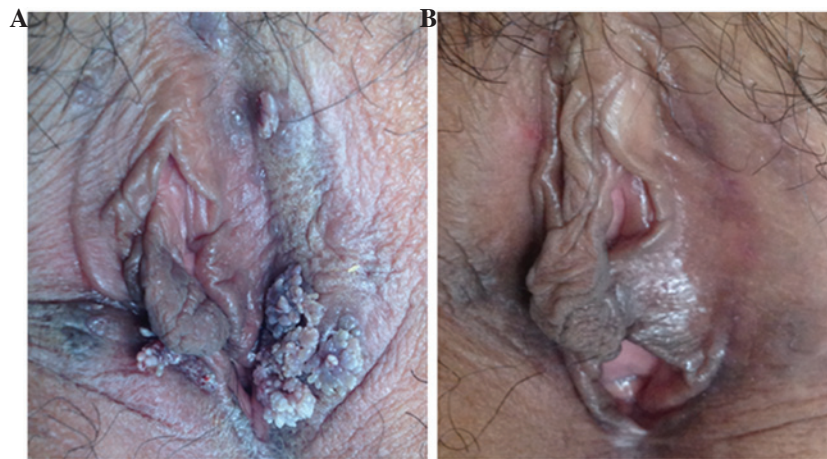

Figure 2. Lesions of case 2. (A) Prior to treatment and (B) after cryotherapy and treatment with proanthocyanidins.

At the 1-month follow-up, only 1 case of recurrence was identified, corresponding to a recurrence rate of 2.2%. At 3 months, 5 cases of recurrence were identified, and the recurrence rate was 10.9%. These results are summarized in Table I.

Discussion

In pregnancy, CA is characterized by the rapid growth of warts and adverse responses to treatments have greater severity compared with those in non-pregnant patients. This may be because of reduced immunity during pregnancy, changes in hormone levels (for example, elevated progesterone levels), and increased vaginal discharge resulting in a more moist local environment (16).

The few treatments that have been tested and recommended for use in pregnancy are BCA/TCA, cryotherapy, electrocautery and surgical excision, including laser treatment. One of the treatment options for CA is imiquimod, an immunomodulatory agent; however, treatment with 5% imiquimod cream has been associated with mild to severe erythema, localized erosion, itching and burning sensations; in addition, irritation, induration, scabbing, tenderness and pain are less frequently reported adverse effects (17). In clinical trial subjects treated with 5% imiquimod cream, recurrences were

reported in 13-19% of cases (18). The safety of imiquimod treatment during pregnancy has not been clarified.

Treatment options further include topical therapies, for example, with salicylic acid, cantharidin, podophyllotoxin, 5-fluorouracil or bleomycin; other immunomodulatory treatments (interferons); physical destruction (surgical excision, cryotherapy, electrodesiccation or laser therapy) and homoeopathic therapy (19-21). Cryotherapy causes tissue necrosis and stimulates a specific immune responses (19,20). As aforementioned, cryotherapy is a simple, inexpensive treatment that rarely causes scarring or depigmentation, and is safe in pregnancy.

In the present study, the spray freezing method was used to treat the warts. The liquid nitrogen injection time and dose were easily controlled, with a longer freezing time providing more thorough removal of the wart. During treatment, liquid nitrogen came into contact with normal skin and mucous membranes. This did not cause severe damage; only minor swelling and very superficial erosion were observed. The wart undergoes necrosis at low temperatures. In addition, cryotherapy treatment is able to induce an antigen-specific immune response and cytokine release (16).

PCs extracted from ginkgo leaves, lotus, grape seed and other plants, are plant polyphenols with strong antioxidant

effects. Studies have shown that PCs can inhibit nuclear factor- κ B DNA binding activity, and thereby block inflammatory cellular pathways to achieve anti-inflammatory effects (22,23). Structurally, PCs comprise at least one aromatic ring and at least one hydroxyl group, which can readily combine with free radicals to form resonance-stabilized phenoxyl radicals (24). As aforementioned, PCs have been demonstrated to be safe for use in pregnant women, and to be effective against redness, swelling, exudate, itching and other symptoms of inflammation.

In the present study, all warts were removed following the treatments. The recurrence rates were 2.2% at 1 month after treatment and 10.9% at 3 months of follow-up. No ulcers or scars were observed in any of the cases, which further confirmed the safety of this combination therapy. In addition, an 87% patient satisfaction rate was achieved at 3 months after treatment.

This study had certain limitations. Firstly, the medical records were reviewed retrospectively, and patients were not seen at final follow-up specifically for this study. Secondly, the follow-up ranged from 1.2 to 3.4 years, and so the long-term clinical outcome is not known in terms of recurrence rate, and other possible problems.

In conclusion, liquid nitrogen cryotherapy combined with PC appears to be an effective treatment for pregnant women with CA. The results of this study showed that the recurrence rate of CA was relatively low, and no effect was evident on the fetus. Liquid nitrogen cryotherapy combined with PC may serve as a treatment option for pregnant women with CA.

References

- Cohen E, Levy A, Holcberg G, Wiznitzer A, Mazor M and Sheiner E: Perinatal outcomes in condyloma acuminata pregnancies. *Arch Gynecol Obstet* 283: 1269-1273, 2011.
- Wiley DJ, Douglas J, Beutner K, Cox T, Fife K, Moscicki AB and Fukumoto L: External genital warts: Diagnosis, treatment and prevention. *Clin Infect Dis* 35 (Suppl 2): S210-S224, 2002.
- Lacey CJ and Fairley I: Medical therapy of genital human papilloma virus-related disease. *Int J STD AIDS* 6: 399-407, 1995.
- Yang YG, Zou XB, Zhao H, Zhang YJ and Li HJ: Photodynamic therapy of condyloma acuminata in pregnant women. *Chin Med J (Engl)* 125: 2925-2928, 2012.
- Gilson RJ, Ross J, Maw R, Rowen D, Sonnex C and Lacey CJ: A multicentre, randomised, double-blind, placebo controlled study of cryotherapy versus cryotherapy and podophyllotoxin cream as treatment for external anogenital warts. *Sex Transm Infect* 85: 514-519, 2009.
- Mi X, Chai W, Zheng H, Zuo YG and Li J: A randomized clinical comparative study of cryotherapy plus photodynamic therapy vs. cryotherapy in the treatment of multiple condylomata acuminata. *Photodermatol Photoimmunol Photomed* 27: 176-180, 2011.
- Li S, Chen L, Yang T, Wu Q, Lv Z, Xie B and Sun Z: Increasing antioxidant activity of procyanidin extracts from the pericarp of *Litchi chinensis* processing waste by two probiotic bacteria bioconversions. *J Agric Food Chem* 61: 2506-2512, 2013.
- Llópiz N, Puiggròs F, Céspedes E, Arola L, Ardévol A, Bladé C and Salvadó MJ: Antigenotoxic effect of grape seed procyanidin extract in Fao cells submitted to oxidative stress. *J Agric Food Chem* 52: 1083-1087, 2004.
- Oyedemi SO and Afolayan AJ: Antibacterial and antioxidant activities of hydroalcoholic stem bark extract of *Schotia latifolia* Jacq. *Asian Pac J Trop Med* 4: 952-958, 2011.
- Dauer A, Hensel A, Lhoste E, Knasmüller S and Mersch-Sundermann V: Genotoxic and antigenotoxic effects of catechin and tannins from the bark of *Hamamelis virginiana* L. in metabolically competent, human hepatoma cells (Hep G2) using single cell gel electrophoresis. *Phytochemistry* 63: 199-207, 2003.
- Chang WC and Hsu FL: Inhibition of platelet aggregation and arachidonate metabolism in platelets by procyanidins. *Prostaglandins Leukot Essent Fatty Acids* 38: 181-188, 1989.
- Schmidt CA, Murillo R, Heinzmann B, Laufer S, Wray V and Merfort I: Structural and conformational analysis of proanthocyanidins from *Parapiptadenia rigida* and their wound-healing properties. *J Nat Prod* 74: 1427-1436, 2011.
- Khanna S, Venojärvi M and Roy S, Sharma N, Trikha P, Bagchi D, Bagchi M and Sen CK: Dermal wound healing properties of redox-active grape seed proanthocyanidins. *Free Radic Biol Med* 33: 1089-1096, 2002.
- Jhun JY, Moon SJ and Yoon BY, Byun JK, Kim EK, Yang EJ, Ju JH, Hong YS, Min JK, Park SH, Kim HY and Cho ML: Grape seed proanthocyanidin extract-mediated regulation of STAT3 proteins contributes to Treg differentiation and attenuates inflammation in a murine model of obesity-associated arthritis. *PLoS One* 8: e78843, 2013.
- Wikström A, Hedblad MA, Johansson B, Kalantari M, Syrjänen S, Lindberg M and von Krogh G: The acetic acid test in evaluation of subclinical genital papillomavirus infection: a comparative study on penoscopy, histopathology, virology and scanning electron microscopy findings. *Genitourin Med* 68: 90-99, 1992.
- Le Poole C, Denman CJ and Arbiser JL: Immunosuppression may be present within condyloma acuminata. *J Am Acad Dermatol* 59: 967-974, 2008.
- Edwards L, Ferenczy A, Eron L, Baker D, Owens ML, Fox TL, Hougham AJ and Schmitt KA: Self-administered topical 5% imiquimod cream for external anogenital warts. HPV Study Group. *Human PapillomaVirus. Arch Dermatol* 134: 25-30, 1998.
- Buck HW, Fortier M, Knudsen J and Paavonen J: Imiquimod 5% cream in the treatment of anogenital warts in female patients. *Int J Gynaecol Obstet* 77: 231-238, 2002.
- Lopaschuk CC: New approach to managing genital warts. *Can Fam Physician* 59: 731-736, 2013.
- Stefanaki C, Katzouranis I, Lagogianni E, Hadjivassiliou M, Nicolaidou E, Panagiotopoulos A, Anyfantakis V, Bethimoutis G, Rallis E, Antoniou C and Katsambas A: Comparison of cryotherapy to imiquimod 5% in the treatment of anogenital warts. *Int J STD AIDS* 19: 441-444, 2008.
- Simonart T and de Maertelaer V: Systemic treatments for cutaneous warts: A systematic review. *J Dermatolog Treat* 23: 72-77, 2012.
- Subarnas A and Wagner H: Analgesic and anti-inflammatory activity of the proanthocyanidin shelleaguein A from *Polypodium feei* METT. *Phytomedicine* 7: 401-405, 2000.
- Ahmad SF, Zoheir KM, Abdel-Hamied HE, Ashour AE, Bakheet SA, Attia SM and Abd-Allah AR: Grape seed proanthocyanidin extract has potent anti-arthritis effects on collagen-induced arthritis by modifying the T cell balance. *Int Immunopharmacol* 17: 79-87, 2013.
- Puiggròs F, Llópiz N, Ardévol A, Bladé C, Arola L and Salvadó MJ: Grape seed procyanidins prevent oxidative injury by modulating the expression of antioxidant enzyme systems. *J Agric Food Chem* 53: 6080-6086, 2005.