

Correlation between genotype and phenotype in three families with Peutz-Jeghers Syndrome

YANLI ZHANG^{1*}, YAO KE^{2*}, XUENI ZHENG¹, QING LIU² and XIAOHONG DUAN¹

¹State Key Laboratory of Military Stomatology, National Clinical Research Center for Oral Diseases, Shaanxi Key Laboratory of Oral Diseases, Department of Oral Biology, Clinic of Oral Rare and Genetic Diseases;

²State Key Laboratory of Military Stomatology, National Clinical Research Center for Oral Diseases, Shaanxi Clinical Research Center for Oral Diseases, Department of Oral Medicine, School of Stomatology, The Fourth Military Medical University, Xi'an, Shaanxi 710032, P.R. China

Received June 29, 2016; Accepted November 30, 2016

DOI: 10.3892/etm.2016.3980

Abstract. Peutz-Jeghers syndrome (PJS) is a hereditary disorder characterized by mucocutaneous pigmentations, gastrointestinal (GI) polyposis and an increased risk of certain malignancies. Little is known about the causative genes of PJS, or their association with the clinical phenotypes of PJS. The present study reports the results of clinical and genetic analysis of three Chinese families with PJS. In addition, the medical histories and clinical manifestations of these families were compared. DNA was collected from the blood samples of patients with PJS and controls. Serine/threonine kinase 11 (*STK11*), olfactory receptor family 4 subfamily C member 45 (*OR4C45*) and zonadhesin (*ZAN*) were amplified by polymerase chain reaction, and analyzed by sequencing and cloning. Two PJS-affected members of one family had a *de novo* single base deletion (NM_000455.4:c.842delC) in the *STK11* gene, and their clinical presentations reflected the quantity of mutant *STK11* copies in a dose-dependent manner. No pathogenic variants of *OR4C45* or

ZAN were found in the patients with PJS, although a new single nucleotide polymorphism (NM_003386.2:c.5768delG) of *ZAN* was identified. The results of the current study identified that a *STK11* mutation dose-dependent genotype-phenotype relationship exists in patients with PJS. In addition, an early onset and high severity of oral pigmentations in PJS was indicative of serious GI phenotypes. These findings may aid the diagnosis and treatment of PJS.

Introduction

Peutz-Jeghers syndrome (PJS) is a rare autosomal dominant disease, which is characterized by mucocutaneous pigmentations and gastrointestinal (GI) hamartomatous polyposis (1). The incidence of PJS has been estimated to be between 1/50,000 and 1/200,000 live births (2).

Mucocutaneous pigmentations are present in ~95% of patients with PJS, typically arising during the first decade of life, although there have been cases in newborns (3). These pigmentations may be the first sign of PJS (4). Mucocutaneous pigmentations primarily present as dark brown or blue-brown spots, which may fade during adolescence (5). They tend to accumulate on the lips, oral mucosa, such as the buccal and palate mucosa, and nostrils. In addition, they have been reported on the fingers, toes, palms, soles, anal area and intestinal mucosa.

Diverse GI complications are observed in patients with PJS, including GI bleeding, anemia and abdominal pain, due to intussusception, obstruction, infarction or pathological hamartomatous polyps. Polyps are frequently detected in patients with PJS, primarily in the small bowel (96%), followed by the colon and the stomach (6). In addition, patients with PJS have an increased risk of developing GI, pancreatic, breast and gynecological cancers (7). A number of cases of patients with sporadic PJS suffering from lung, testicular or ovarian cancers have been reported (5).

By the age of 10 years, >1/3 of patients with PJS begin to show initial symptoms, with half of these presenting with further symptoms by the age of 20-25 (5,7,8). Mucocutaneous pigmented lesions appear in infancy or early childhood, while GI polyps arise between the second and third decade of life in 80-100% of patients with PJS (6).

Correspondence to: Professor Xiaohong Duan, State Key Laboratory of Military Stomatology, National Clinical Research Center for Oral Diseases, Shaanxi Key Laboratory of Oral Diseases, Department of Oral Biology, Clinic of Oral Rare and Genetic Diseases, School of Stomatology, The Fourth Military Medical University, 145 West Changle Road, Xi'an, Shaanxi 710032, P.R. China
E-mail: xhduan@fmmu.edu.cn

Dr Qing Liu, State Key Laboratory of Military Stomatology, National Clinical Research Center for Oral Diseases, Shaanxi Clinical Research Center for Oral Diseases, Department of Oral Medicine, School of Stomatology, The Fourth Military Medical University, 145 West Changle Road, Xi'an, Shaanxi 710032, P.R. China
E-mail: liuqing@fmmu.edu.cn

*Contributed equally

Key words: Peutz-Jeghers syndrome, genotype-phenotype analysis, serine/threonine kinase 11, olfactory receptor family 4 subfamily C member 45, zonadhesin

Mutations in a number of genes have been identified in patients with PJS, including serine/threonine kinase 11 (*STK11*) (9,10), olfactory receptor family 4 subfamily C member 45 (*OR4C45*) (11) and zonadhesin (*ZAN*) (11). In addition, 19q13.4 (12), chromosome 1p and a pericentric inversion in chromosome 6 (13) are regarded as the locations of PJS-causative genes. Mutations in the *STK11* gene are considered the primary cause of PJS (14). A previous study reported that 27% of *STK11* mutations in patients with PJS were missense (15). Other *STK11* mutations found in PJS include splice-junction alterations, insertions, and nucleotide or whole gene deletions (14). These mutations may cause frameshift or nonsense changes, leading to an abnormal truncated protein and the loss of kinase activity. Furthermore, the site and type of mutation has also been associated with cancer risk in various reports, as indicated in a recent review (14).

Correlations between *STK11* mutations and clinical characteristics in PJS have previously been described. Missense mutations in *STK11* typically lead to a later onset of PJS, while truncating mutations may cause an earlier onset, compared with missense or non-detectable mutations (15). In addition, the frequency of GI polyps and the occurrence of cancer appear to be positively correlated with truncating mutations of *STK11* (16). Patients with PJS with *STK11* mutations have a higher risk of developing cancer, with a risk of 81% at the age of 70 years (17). However, the genotype-phenotype correlation of PJS remains poorly understood.

The present study reports the results of clinical and genetic analysis of three Chinese families with PJS, in order to elucidate the genetic profiles of Chinese patients with PJS, and explore the association between gene variants and clinical phenotypes, such as mucocutaneous and GI features, in PJS.

Materials and methods

Clinical diagnosis and evaluation of PJS. Six patients with PJS in three families (F_a , F_b and F_c ; 2 males and 4 females) were enrolled from the Clinic of Oral Rare Diseases and Genetic Diseases, School of Stomatology at the Fourth Military Medical University (Xi'an, China), between September 2012 and April 2014. Five family members (F_{aI_1} , 40, male; F_{bI_1} , 35, male; F_{cI_1} , 32, male; F_{cII_1} , 6, female; F_{cII_2} , 2, female) without PJS also participated in this study. The diagnosis of PJS was made on the presence of mucocutaneous pigmentations, typical PJS polyps and a family history (4). Clinical symptoms of all participants were examined and assessed by three different clinicians. The following clinical features were measured: Medical and family histories; quantity, size and distribution of mucocutaneous pigmentations; and the presence of characteristic PJS polyps. Pedigrees of the three families are shown in Fig. 1. The study protocol was approved by the Ethics Committee of the School of Stomatology, Fourth Military Medical University (approval no. 2013-011). Informed consent was obtained from patients and healthy controls prior to participation. For those under the age of 18, consent was obtained from their legal guardians.

DNA preparation and amplification. Of the six patients who participated in this study, four were enrolled in genetic analysis, as one died prior to this stage and another refused

to be enrolled in genetic analysis. Total genomic DNA was obtained from whole blood samples of four (F_{aI_2} , F_{aII_1} , F_{bII_1} , F_{cI_2}) patients with PJS and their family members using the QIAamp DNA Blood Mini kit (cat. no. 51106; Qiagen, Inc., Valencia, CA, USA), according to the manufacturer's protocol. As a control, a total of 50 unrelated healthy controls were enrolled in this study in April 2014, which included 25 males and 25 females. The age of these controls ranged between 20 and 25 years, with a mean of 23.2 years.

The coding exons of *STK11*, *OR4C45* and *ZAN* were then amplified using polymerase chain reaction (PCR). Primer sequences and PCR product sizes for individual amplicons are shown in Table I. Each PCR mixture (50 μ l) contained 10 mM Tris-HCl (pH 8.3), 50 mM KCl, 1.5 mM MgCl₂, 50 mM dNTPs, 0.25 μ M of each primer, 200 ng genomic DNA and 1 unit Taq DNA polymerase (RUNDE Biotechnology Co., Ltd., Xi'an China). PCR thermal cycling conditions were as follows: Denaturation for 3 min at 93°C; 30 cycles of 30 sec at 94°C; 30 sec at 55°C; and 1 min at 72°C. PCR products were purified using the MicroElute DNA Clean-Up kit (cat no: D2500-01; Omega Bio-Tek, Inc., Norcross, GA, USA) following the manufacturer's instructions.

DNA sequencing and analysis. PCR products were sequenced using an ABI 3500 Genetic Analyzer (Applied Biosystems; Thermo Fisher Scientific, Inc., Waltham, MA, USA). Sequence electropherograms produced were analyzed using Sequencher software (version 5.0; Gene Codes Corporation, Ann Arbor, MI, USA).

Plasmid constructs and sequence analysis. In order to examine the mutant copies of *STK11* exon 6 identified in F_a , purified PCR products were inserted into the pMD18-T vector (Takara Biotechnology Co., Ltd., Dalian, China), producing the recombinant vector pMD18-T-*STK11*-exon 6. Briefly, purified exon 6 of *STK11* (150 ng) and pMD18-T vector (50 ng) were mixed in a final volume of 10 μ l, incubated at 16°C for 30 min and then transformed into 100 μ l competent DH5a *Escherichia coli* (Takara Biotechnology Co., Ltd.). For transformation, the DNA/*E.coli* mixture (150 ng/100 μ l) was incubated on ice for 30 min, heat shocked at 42°C for 30 sec and placed on ice for 5 min. Lysogeny broth (LB) medium (400 μ l; 1 l of LB containing 10 g tryptone, 5 g yeast extract, 10 g NaCl) was added to the reaction and the solution incubated at 37°C for 1 h. Then, 200 μ l of the *E. coli* mixture was spread onto LB plates containing ampicillin (60 μ g/ml) and left to grow overnight at 37°C. For each patient, the successful transformation of *E. coli* was confirmed in 10 randomly selected colonies by PCR and the pMD18-T-*STK11*-exon 6 in these colonies was then isolated using the Plasmid Mini kit I (cat. no. D6943-01; Omega Bio-Tek, Inc.). The purified products were sequenced and analyzed as previously described.

Results

Clinical features. The pedigree plot revealed a typical autosomal dominant pattern of inheritance in F_a and F_b (Fig. 1). There was no obvious Mendelian inheritance of PJS in F_c (Fig. 1). The clinical characteristics of the six patients with PJS (4 females, F_{aI_2} , F_{aII_1} , F_{bI_2} and F_{cI_2} ; 2 males, F_{bII_1} and F_{bII_2})

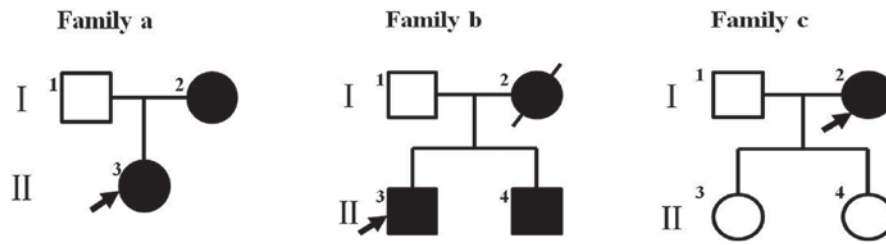


Figure 1. Pedigrees of the three families with Peutz-Jeghers syndrome. Family a and family b showed autosomal dominant heredity, whilst there was no obvious Mendelian inheritance in family c. The unfilled and black shapes represent unaffected and affected family members, respectively. Squares represent males and circles represent females. The black arrow indicates the proband.

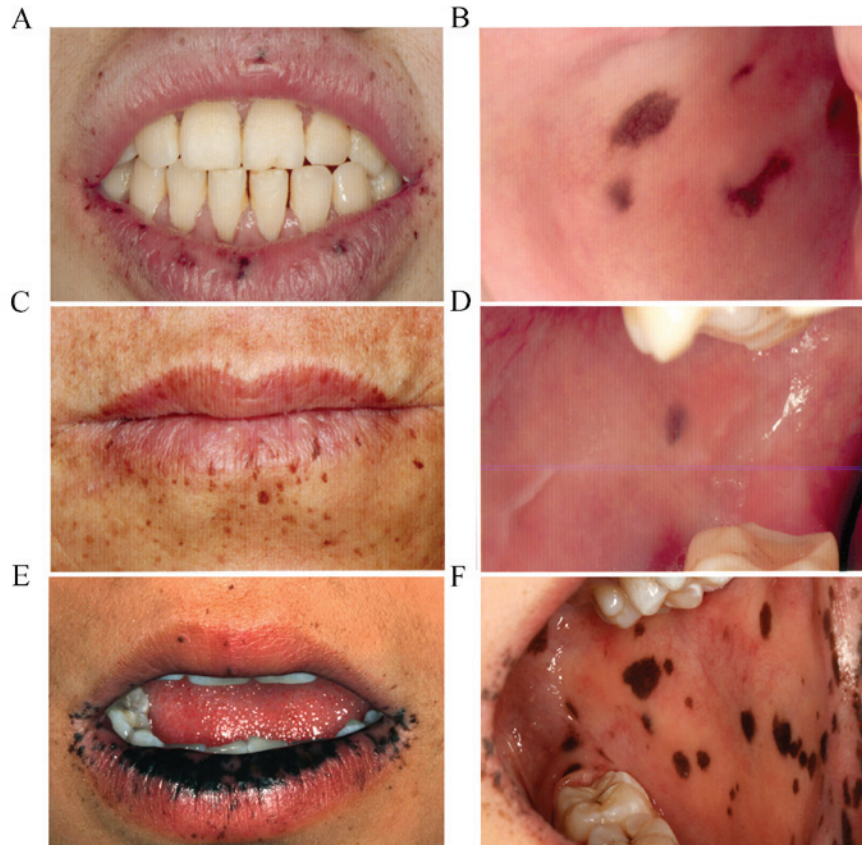


Figure 2. Examples of oral pigmentations observed in the families with Peutz-Jeghers syndrome. Melanotic pigmentations in F_aII_1 presented as dark-brown macules, of between 1 and 5 mm in diameter, located on (A) the lips and perioral area and (B) buccal mucosa. Melanotic pigmentations in F_aI_2 were dark-brown macules on (C) the lips and perioral area and (D) buccal mucosa of between 1 and 2 mm in diameter. Melanotic pigmentation in F_bII_1 , presenting as dark-brown macules of between 3 and 8 mm in diameter on (E) the lips and perioral area and (F) the buccal mucosa. F_a , family a; F_b , family b; F_c , family c.

are summarized in Table II. Their initial symptoms appeared from between 2 and 30 years of age. Mucocutaneous pigmentations in the oral mucosa and perioral areas were observed in all patients. In F_a , F_aII_1 (Fig. 2A and B) had more severe and conspicuous hyperpigmentations compared with F_aI_2 (Fig. 2C and D). The most serious case, F_bII_1 , exhibited a black lower lip (Fig. 2E and F). In addition, areas of pigmentation were present on the fingers and toes of two patients (F_aI_2 and F_aII_1 ; Fig. 3A and B).

Four participants exhibited GI polyps (F_aI_2 , F_aII_1 , F_bI_2 and F_cI_2). Three of these (F_aI_2 , F_aII_1 and F_bI_2) had a history of recurrent masses, having had a total of <5 (F_aI_2), 15 (F_aII_1) and >20 (F_bI_2) polyps. The polyps occurred in the stomach, small intestine and colon (Fig. 3C and D). The most frequent GI symptom

in these patients was abdominal pain (n=3). In addition, one patient with GI polyps (F_cI_2) complained of constipation, and two severe cases suffered from polyp-related intussusception and infarction. One patient succumbed to GI adenocarcinoma at 35 years of age.

Genetic analysis. Two patients with PJS in F_a (F_aI_2 and F_aII_1) showed a single base deletion at nucleotide 842 (NM_000455.4:c.842delC) in exon 6 of the *SKT11* gene, corresponding to amino acid 281 of the STK11 protein. This deletion causes a frameshift, resulting in a truncated protein due to a premature termination codon at amino acid 286 (Fig. 4).

In order to compare the proportion of copies of *SKT11* with this mutation, subcloning was carried out. Among the 10

Table I. Primers used in PCR and product size.

Gene/position	Forward primer (5'-3')	Reverse primer (5'-3')	Product size (bp)
<i>STK11</i>			
Exon 1	CGTTTGCTCCTGGGACAG	GGTCCAGCTCAGGGTGTT	969
Exon 2	GGTACGCCACTTCCACAG	CTCGTGGCCAGTCTCCT	302
Exon3	GGGGACTTTGCTTCTAAGG	GAATATCAGGACAAGCAGTG	612
Exon 4	GCCTGGACTTCTGTGACTT	ATGTCCACCTTGAAGCC	449
Exon 5	CCTCAAAATCTCCGACC	CTCGGAGTGTGCGTGT	289
Exon 6	CGGCTTCAAGGTGGACAT	TCCTTGGTGTCTGGGCTC	294
Exon 7	GAGCGTCCAGGTATCACC	AGGACACTGCCAGAGAC	345
Exon 8	TGGGTTCGAAAAGTGGAC	TTTGGGGACGTGGGATTG	381
Exon 9	TAAGTTCGTCCTCCGTTGTT	TGGCATCCAGGCGTTGTC	355
<i>OR4C45</i>			
c.767-768	ATGAACAATGTAACAGAATTCATCC	AATCACACATAAAGTGGTTCGATGAC	526
<i>ZAN</i>			
c.5767	AAAGGCCACATCTTGAGT	TGCAGCAGAGTTACCAGTC	574

PCR, polymerase chain reaction; *STK11*, serine/threonine kinase 11; *OR4C45*, olfactory receptor family 4 subfamily C member 45; *ZAN*, zonadhesin.

Table II. Clinical features of six patients with PJS in three families.

Features	Patients					
	F _a I ₂	F _a II ₁	F _b I ₂	F _b II ₁	F _b II ₂	F _c I ₂
Age at onset of PJS (years)	15	10	11	7	2	24
Age at diagnosis of PJS (years)	40	23	25	7	2	30
Mucocutaneous pigmentations	+	++	++	+++	+	+
Number of GI polyps	<5	15	>20	0	0	1
Constipation	Y	N	N	N	N	N
Abdominal pain	Y	Y	Y	N	N	N
GI bleeding	N	Y	Y	N	N	N
GI intussusception	N	Y	Y	N	N	N
Anemia	N	Y	Y	N	N	N
Cancer	N	N	Y	N	N	N

+, small and few; ++, medium and many; +++, large (cover >1/2 the lower lip). Y, yes; N, no; PJS, Peutz-Jeghers syndrome; F_a, family a; F_b, family b; F_c, family c; *STK11*, serine/threonine kinase 11; *OR4C45*, olfactory receptor family 4 subfamily C member 45; *ZAN*, zonadhesin; GI, gastrointestinal.

Table III. Summary of the genetic analysis of four PJS patients.

Gene/mutation	Patients			
	F _a I ₂	F _a II ₁	F _b II ₁	F _c I ₂
<i>STK11</i> (c.842delC)	+	+	-	-
<i>OR4C45</i> (c.767-768)	-	-	-	-
<i>ZAN</i> (c.5767)	-	-	-	-
<i>ZAN</i> (c.5768delG)	+	+	+	+

PJS, Peutz-Jeghers syndrome; F_a, family a; F_b, family b; F_c, family c; *STK11*, serine/threonine kinase 11; *OR4C45*, olfactory receptor family 4 subfamily C member 45; *ZAN*, zonadhesin; GI, gastrointestinal.

randomly selected colonies that were analyzed, this deletion was found in 100% from F_aII₁ and 10% from F_aI₂, compared with 0% from the healthy control F_aI₁. The F_a member with more severe PJS symptoms, F_aII₁, showed a significantly higher proportion of mutant copies than F_aI₂.

Two previously reported PJS-associated mutations (*OR4C45* c.767-768 and *ZAN* c.5767) were not found in any of the patients tested (Table III). A single base deletion at nucleotide 5768 (NM_003386.2:c.5768delG) of the *ZAN* gene was detected in four patients with PJS and three unaffected family members (3/5, 60%). This variant was also found in 30 out of 50 (60%) healthy controls. To the best of our knowledge, this variant is a novel single nucleotide polymorphism (SNP).

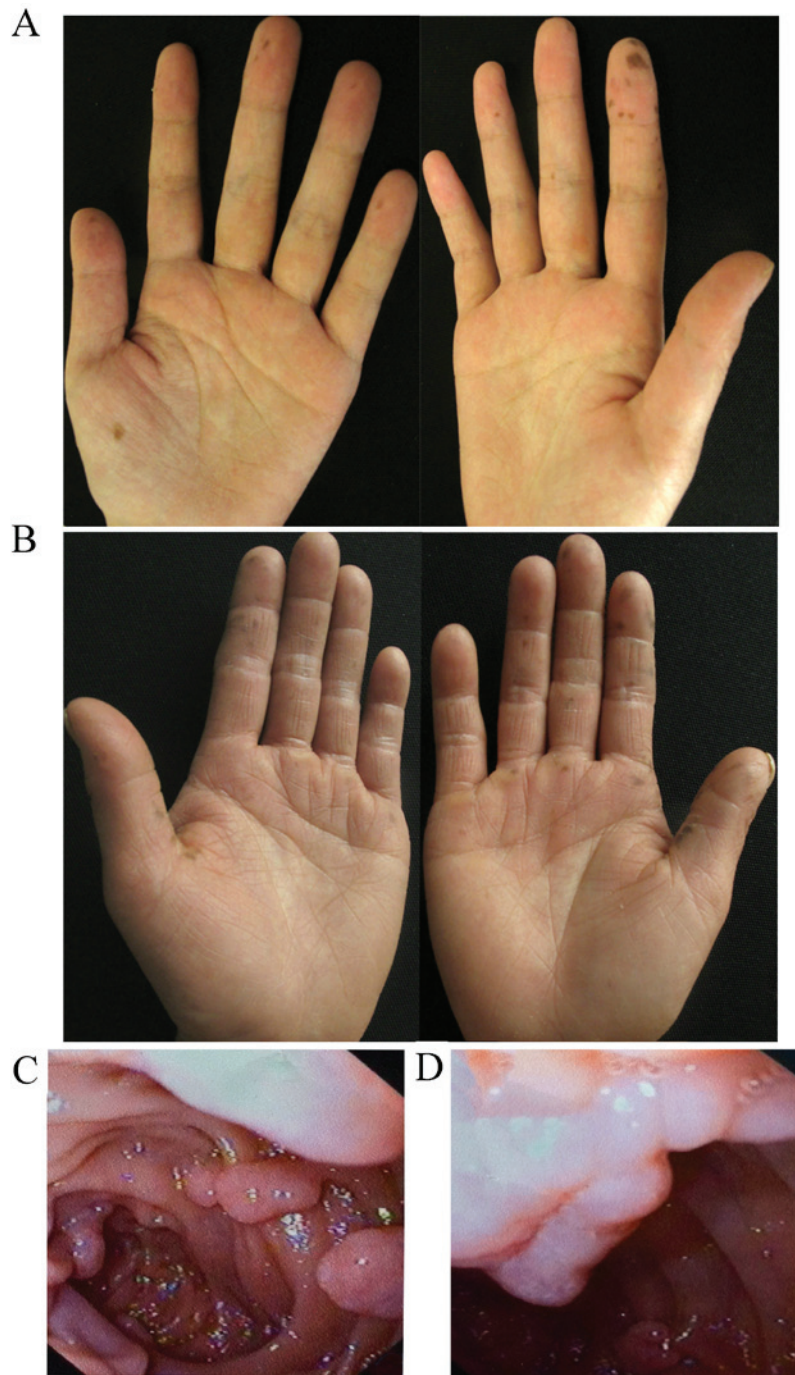


Figure 3. Examples of pigmentations on the hands and hamartomatous GI polyps in the families with Peutz-Jeghers syndrome. Hyperpigmentation on the fingers and palms of (A) F_aI_2 and (B) F_aII_1 . Enteroscopic images of hamartomatous polyps in the superior part of duodenum (C) and the descending part of duodenum (D) of F_aII_1 . GI, gastrointestinal; F_a , family a; F_b , family b; F_c , family c.

Discussion

Since the first PJS case was described in 1921 (4), there has been an increasing awareness of this disease. The characteristic symptoms of PJS are mucocutaneous pigmentations and GI disorders. GI symptoms, such as intussusception or bleeding, typically occur in early life and there is an increased risk of cancer in later life. The majority of genetic analyses in patients with PJS have focused on the patterns of alteration, malignancy risk, and the type and locus of potential causative genes. In the present study, all patients with PJS exhibited mucocutaneous

pigmentations and 66.7% had a history of GI hamartomatous polyps.

The primary causative gene of PJS has been identified as the *STK11* gene located on chromosome 19p13 (1). Germline mutations in *STK11* are considered to cause a predisposition to PJS (4). *STK11* mutations have been detected in 80-94% of patients with PJS, with ~150 different mutations in the *STK11* gene associated with PJS (4). A recent survey in 133 Chinese patients with PJS from 28 families found that *STK11* is the primary causative gene of PJS in the Chinese population (18). Consistent with these reports, 2 out of 4 (50%) patients with

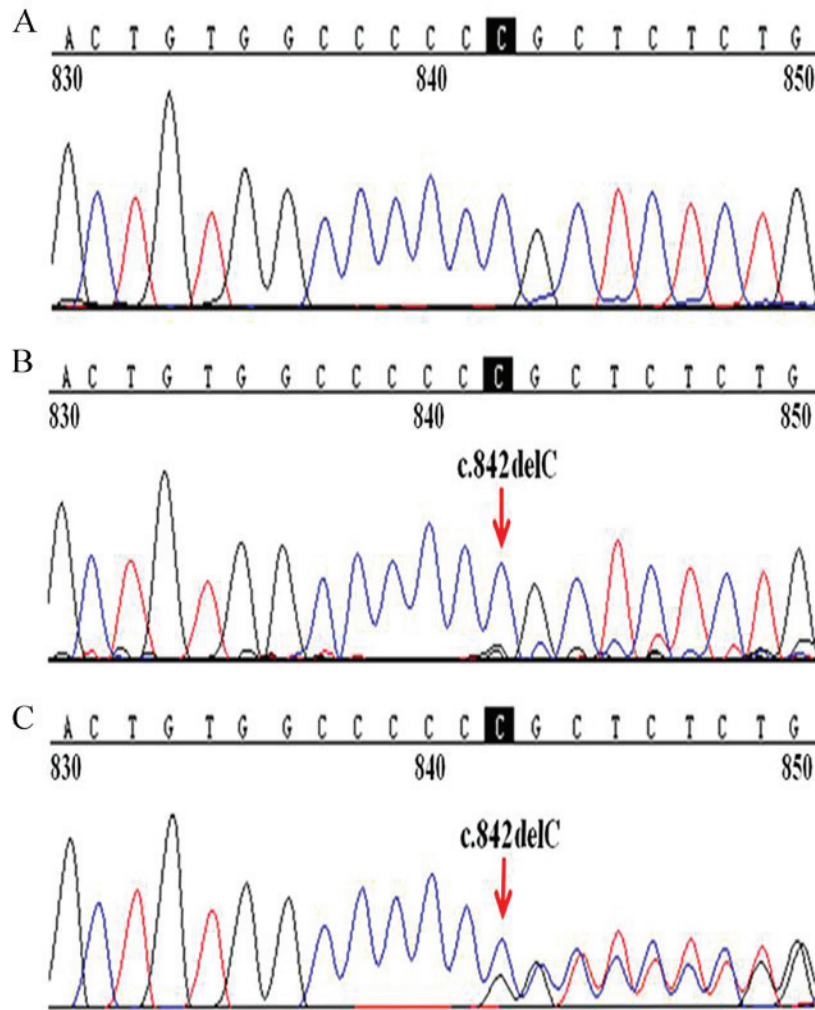


Figure 4. Sequencing results of the mutation in *STK11* in F_a with genomic DNA. Sequencing analysis of (A) F_aI_1 , (B) F_aI_2 and (C) F_aII_1 . F_aI_2 and F_aII_1 showed a single base deletion (NM_000455.4:c.842delC) in exon 6 of *STK11*, indicated by the red arrow. *STK11*, serine/threonine kinase 11; F_a , family a.

PJS in the present study were identified to have germline *STK11* mutations.

Pathogenic roles of *STK11* variants have previously been explored. Mutations in exon 6 of *STK11* were found to be associated with a higher cancer risk in patients with PJS (19). Schumacher *et al* (20) determined that missense mutations in *STK11* were primarily located in the C terminus and VIB-VIII regions. In-frame deletions and splice site mutations were rarely associated with malignancies (20). However, in a survey of 419 patients with PJS, cancer risks were similar in patients with PJS and *STK11* mutations and those without detectable mutation, suggesting that the type or site of *STK11* mutation did not have a significant influence on the risk of malignancy (21). In the current study, neither of the patients with *STK11* mutations (F_aI_2 and F_aII_1) had cancer of GI or any other system, while the patient with PJS who had GI cancer exhibited no pathogenic mutation in the *STK11* gene. The results of the present study did not find an association between *STK11* mutations and carcinogenesis.

The association between other clinical features of PJS and *STK11* mutations was investigated. A missense mutation in *STK11* has been connected with a later onset of PJS symptoms (15). In the current study, two patients with the

same mutation (NM_000455.4:c.842delC; F_aI_2 and F_aII_1) in *STK11* showed oral and GI manifestations of PJS to varying degrees of severity. Compared with F_aI_2 , F_aII_1 developed oral and GI symptoms earlier, presented an increased quantity and size of oral pigmentations, had an increased quantity of GI polyps, and more frequent and severe GI complications. Notably, F_aII_1 showed a markedly higher quantity of mutant *STK11* copies (100%) than F_aI_2 (10%), suggesting that there is a correlation between the severity of PJS phenotypes and the number of mutant *STK11* copies. In addition, this indicates that there was a dose-dependent relationship between the number of copies of mutated *STK11* and clinical phenotypes in the present study. To the best of our knowledge, this is the first study to report a *STK11* mutation dose-dependent genotype-phenotype correlation in patients with PJS, which may have future applications in risk assessment and genetic counseling for PJS.

The *STK11* gene is ubiquitously expressed in adult and fetal human tissues (9,22). The human *STK11* protein consists of an N-terminal nuclear localization signal domain, a highly conserved serine/threonine kinase domain and a C-terminal regulatory domain (14). *STK11* is important in chromatin remodeling, cell polarization, metabolism, cell

cycle regulation and apoptosis. The majority of PJS-associated missense mutations are located in the conserved serine/threonine kinase domain, which may impair kinase activity and subsequently cell growth (23,24). Mutations in C-terminal region of *STK11* may impair cell polarization and are associated with cancer risk (25). In the present study, the single base deletion identified in *STK11* (NM_000455.4:c.842delC) is one that causes a frameshift, resulting in a premature stop signal at codon 286. The resulting truncated protein has only a partial kinase domain and complete loss of the C-terminal regulatory domain, which may be responsible for the *STK11* dose-dependent genotype-phenotype correlation observed. Further study is warranted to elucidate the potential role of *STK11* during pigmentation and polypus formation in PJS.

OR4C45 and *ZAN* were the other two candidate genes in PJS pathogenesis, which have been described in a study of Chinese patients with PJS (11). The *OR4C45* gene encodes the olfactory receptor (OR) protein, which is important in maintaining intestinal homeostasis. OR is expressed in human mucosal enterochromaffin cells and may be associated with gut function (26). The OR ligand regulates epithelial permeability and electrogenic anion secretion in the human colon (27). The *ZAN* gene encodes a protein, ZAN, with multiple transmembrane domains. ZAN is a specific mammalian protein involved in sperm-zona pellucida adhesion (28). ZAN is associated with inflammation and tumors in PJS (11). In the current study, no mutations in *OR4C45* and *ZAN* gene were found, although a novel SNP in *ZAN* (NM_003386.2:c.5768delG) was identified. One of the PJS families studied, with the typical clinical manifestations of PJS, did not carry any *STK11*, *OR4C45* or *ZAN* mutations, suggesting that genetic heterogeneity and other causative factors of PJS exist.

Patients with PJS typically present heterogeneous phenotypes with regards to oral and GI lesions, including different onset times, disease severity, distribution of GI symptoms and level of malignancy (4). In order to investigate phenotypic heterogeneity in the present study, the clinical features of participants with PJS were compared, including onset time, duration, severity and prognosis. The earliest initial manifestations of PJS, such as oral pigmentations, were found in one participant at the age of 2 years. The most severe PJS case, F_bI₂, suffered serious GI complications and succumbed to a malignant tumor at 35 years of age. The patient's two young children (F_bII₁ and F_bII₂) exhibited severe oral hyperpigmentation during childhood. This early onset (pre-puberty) of PJS may be an indicator for the development of serious GI complications, and will be followed up in the future. The present study found that oral lesions appeared prior to GI symptoms in the patients with PJS studied, and that the severity of these may reflect the severity of GI phenotypes. F_aII₁ had a high quantity and large size of oral pigmentations and a severe GI phenotype. GI symptoms are the primary complaints of patients with PJS. If mild oral lesions are ignored in the early stages of PJS, misdiagnosis may occur, delaying treatment. The results of the present study indicate that the severity of oral pigmentations may be used as a prognostic and diagnostic marker of PJS.

In conclusion, the present study employed cloning and sequencing techniques for the molecular study of inherited PJS, revealing a dose-dependent genotype-phenotype

relationship in a PJS family with a *STK11* gene mutation. In addition, it was found that an early onset time and severe oral pigmentations in patients with PJS may indicate more serious GI phenotypes. These findings may aid the diagnosis and treatment of PJS.

Acknowledgements

The present study was supported by the National Natural Science Foundation of China (grant nos. 81271116 and 81470728).

References

- Lindor NM and Greene MH: The concise handbook of family cancer syndromes. Mayo Familial Cancer Program. J Natl Cancer Inst 90: 1039-1071, 1998.
- Giardiello FM and Trimbath JD: Peutz-Jeghers syndrome and management recommendations. Clin Gastroenterol Hepatol 4: 408-415, 2006.
- Kopacova M, Tacheci I, Rejchrt S and Bures J: Peutz-Jeghers syndrome: Diagnostic and therapeutic approach. World J Gastroenterol 15: 5397-5408, 2009.
- Beggs AD, Latchford AR, Vasen HF, Moslein G, Alonso A, Aretz S, Bertario L, Blanco I, Bülow S, Burn J, et al: Peutz-Jeghers syndrome: A systematic review and recommendations for management. Gut 59: 975-986, 2010.
- Tomas C, Soyer P, Dohan A, Dray X, Boudiaf M and Hoeffel C: Update on imaging of Peutz-Jeghers syndrome. World J Gastroenterol 20: 10864-10875, 2014.
- Stojcev Z, Borun P, Hermann J, Krokowicz P, Cichy W, Kubaszewski L, Banasiewicz T and Plawski A: Hamartomatous polyposis syndromes. Hered Cancer Clin Pract 11: 4, 2013.
- Giardiello FM, Brensinger JD, Tersmette AC, Goodman SN, Petersen GM, Booker SV, Cruz-Correa M and Offerhaus JA: Very high risk of cancer in familial Peutz-Jeghers syndrome. Gastroenterology 119: 1447-1453, 2000.
- Dong K and Li B: Peutz-Jeghers syndrome: Case reports and update on diagnosis and treatment. Chin J Dig Dis 5: 160-164, 2004.
- Jenne DE, Reimann H, Nezu J, Friedel W, Loff S, Jeschke R, Müller O, Back W and Zimmer M: Peutz-Jeghers syndrome is caused by mutations in a novel serine threonine kinase. Nat Genet 18: 38-43, 1998.
- Jiang CY, Esufali S, Berk T, Gallinger S, Cohen Z, Tobi M, Redston M and Bapat B: *STK11/LKB1* germline mutations are not identified in most Peutz-Jeghers syndrome patients. Clin Genet 56: 136-141, 1999.
- Wang HH, Xie NN, Li QY, Hu YQ, Ren JL and Guleng B: Exome sequencing revealed novel germline mutations in Chinese Peutz-Jeghers syndrome patients. Dig Dis Sci 59: 64-71, 2014.
- Markie D, Huson S, Maher E, Davies A, Tomlinson I and Bodmer WF: A pericentric inversion of chromosome six in a patient with Peutz-Jeghers' syndrome and the use of FISH to localise the breakpoints on a genetic map. Hum Genet 98: 125-128, 1996.
- Mehenni H, Blouin JL, Radhakrishna U, Bhardwaj SS, Bhardwaj K, Dixit VB, Richards KF, Bermejo-Fenoll A, Leal AS, Raval RC and Antonarakis SE: Peutz-Jeghers syndrome: Confirmation of linkage to chromosome 19p13.3 and identification of a potential second locus, on 19q13.4. Am J Hum Genet 61: 1327-1334, 1997.
- Korsse SE, Peppelenbosch MP and van Veelen W: Targeting *LKB1* signaling in cancer. Biochim Biophys Acta 1835: 194-210, 2013.
- Amos CI, Keitheri-Cheteri MB, Sabripour M, Wei C, McGarrity TJ, Seldin MF, Nations L, Lynch PM, Fidler HH, Friedman E and Frazier ML: Genotype-phenotype correlations in Peutz-Jeghers syndrome. J Med Genet 41: 327-333, 2004.
- Salloch H, Reinacher-Schick A, Schulmann K, Pox C, Willert J, Tannapfel A, Heringlake S, Goecke TO, Aretz S, Stemmler S and Schmiegel W: Truncating mutations in Peutz-Jeghers syndrome are associated with more polyps, surgical interventions and cancers. Int J Colorectal Dis 25: 97-107, 2010.
- Chae HD and Jeon CH: Peutz-Jeghers syndrome with germline mutation of *STK11*. Ann Surg Treat Res 86: 325-330, 2014.

18. Wang Z, Wu B, Mosig RA, Chen Y, Ye F, Zhang Y, Gong W, Gong L, Huang F, Wang X, *et al*: STK11 domain XI mutations: Candidate genetic drivers leading to the development of dysplastic polyps in Peutz-Jeghers syndrome. *Hum Mutat* 35: 851-858, 2014.
19. Mehenni H, Resta N, Guanti G, Mota-Vieira L, Lerner A, Peyman M, Chong KA, Aissa L, Ince A, Cosme A, *et al*: Molecular and clinical characteristics in 46 families affected with Peutz-Jeghers syndrome. *Dig Dis Sci* 52: 1924-1933, 2007.
20. Schumacher V, Vogel T, Leube B, Driemel C, Goecke T, Möslein G and Royer-Pokora B: STK11 genotyping and cancer risk in Peutz-Jeghers syndrome. *J Med Genet* 42: 428-435, 2005.
21. Hearle N, Schumacher V, Menko FH, Olschwang S, Boardman LA, Gille JJ, Keller JJ, Westerman AM, Scott RJ, Lim W, *et al*: Frequency and spectrum of cancers in the Peutz-Jeghers syndrome. *Clin Cancer Res* 12: 3209-3215, 2006.
22. Hemminki A, Markie D, Tomlinson I, Avizienyte E, Roth S, Loukola A, Bignell G, Warren W, Aminoff M, Höglund P, *et al*: A serine/threonine kinase gene defective in Peutz-Jeghers syndrome. *Nature* 391: 184-187, 1998.
23. Ylikorkala A, Avizienyte E, Tomlinson IP, Tiainen M, Roth S, Loukola A, Hemminki A, Johansson M, Sistonen P, Markie D, *et al*: Mutations and impaired function of LKB1 in familial and non-familial Peutz-Jeghers syndrome and a sporadic testicular cancer. *Hum Mol Genet* 8: 45-51, 1999.
24. Mehenni H, Gehrig C, Nezu J, Oku A, Shimane M, Rossier C, Guex N, Blouin JL, Scott HS and Antonarakis SE: Loss of LKB1 kinase activity in Peutz-Jeghers syndrome, and evidence for allelic and locus heterogeneity. *Am J Hum Genet* 63: 1641-1650, 1998.
25. Forcet C, Etienne-Manneville S, Gaude H, Fournier L, Debilly S, Salmi M, Baas A, Olschwang S, Clevers H and Billaud M: Functional analysis of Peutz-Jeghers mutations reveals that the LKB1 C-terminal region exerts a crucial role in regulating both the AMPK pathway and the cell polarity. *Hum Mol Genet* 14: 1283-1292, 2005.
26. Braun T, Volland P, Kunz L, Prinz C and Gratzl M: Enterochromaffin cells of the human gut: Sensors for spices and odorants. *Gastroenterology* 132: 1890-1901, 2007.
27. Kaji I, Karaki S and Kuwahara A: Effects of luminal thymol on epithelial transport in human and rat colon. *Am J Physiol Gastrointest Liver Physiol* 300: G1132-G1143, 2011.
28. Tardif S and Cormier N: Role of zonadhesin during sperm-egg interaction: A species-specific acrosomal molecule with multiple functions. *Mol Hum Reprod* 17: 661-668, 2011.