

# Refractory hypotension induced by Sheehan syndrome with pituitary crisis: A case report

LU LIANG<sup>1\*</sup>, JIN-BO LIU<sup>1\*</sup>, FU-QIN CHEN<sup>1</sup>, JING ZHAO<sup>2</sup> and XIAO-LI ZHANG<sup>1</sup>

Departments of <sup>1</sup>Endocrinology and <sup>2</sup>Cardiology, Qilu Hospital of Shandong University, Jinan, Shandong 250000, P.R. China

Received December 5, 2015; Accepted December 19, 2016

DOI: 10.3892/etm.2017.4188

**Abstract.** The present study reported on an unusual case of refractory hypotension induced by Sheehan syndrome with pituitary crisis and explored the causes and treatment of hypotension in hypopituitarism. Refractory hypotension is a rare and severe complication of longstanding hypopituitarism induced by Sheehan syndrome with pituitary crisis. A 48-year-old Chinese woman with pituitary crisis due to Sheehan syndrome developed refractory hypotension and received longstanding vasopressor blood pressure support and hormone replacement therapy. Besides normalized blood pressure, echocardiography over 3 months revealed partial reversibility of her cardiac function with hormone replacement therapy. Consistent numerous studies reviewed, hormone replacement therapy may improve cardiac function in patients with cardiomyopathy linked to Sheehan syndrome. A retrospective study of 77 cases with hypopituitarism encountered at Qilu Hospital of Shandong University (Jinan, China) was also performed and the incidence rate of hypotension was analyzed, revealing that the present case was the first of refractory hypotension induced by Sheehan syndrome with pituitary crisis at this institution in 16 years.

## Introduction

Sheehan syndrome is characterized by hypopituitarism, which is due to ischemic necrosis of the pituitary gland secondary to postpartum hemorrhage (1). Major manifestations include failure to lactate, breast atrophy, secondary amenorrhea, genital and axillary hair loss, dry skin, hypopigmentation and other evidence of hypopituitarism. It can also present

acutely with circulatory collapse, congestive cardiac failure and hypotension. Hypotension can be quickly corrected under hormone and volume replacement therapy. The present study reported on a case of Sheehan syndrome in a 48-year-old Chinese woman who had refractory hypotension and required longstanding vasopressor blood pressure support and hormone replacement therapy, which is rarely reported in the literature. The causes of refractory hypotension have been attributed to decreased cardiac output owing to cardiomyopathy and hypovolemia arising from hypoproteinemia. After three months, her blood pressure remained at levels of ~110/70 mmHg and her cardiac function partly reversed with hydrocortisone and levothyroxine replacement therapy.

## Case report

A 48-year-old Chinese woman was admitted to the emergency department of Qilu Hospital of Shandong University (Jinan, China) with progressive chest distress and dyspnea for two weeks after a common cold. She had been suffering from long-term chronic symptoms, including fatigue, anorexia and light-headedness with a history of Sheehan syndrome without therapy. The patient had no history of cardiac disease or diabetes mellitus. In addition, the patient stopped menstruating after her second pregnancy 20 years previously.

Physical examination revealed the following: Mild hypothermia (axillary temperature, 35.8°C), low blood pressure (74/49 mmHg) and a pulse rate of 40 beats/min. Pale skin, facial edema and cool extremities with significant pitting edema of lower limbs were observed. Breast atrophy and sparse axillary and pubic hair were striking features. Lung examination revealed a moist rale in the bilateral lung bases with a respiratory rate of 20 breaths/min, muffled heart sounds and bradycardia were found in the cardiac auscultation area. Neurologically, the patient was without any focal signs.

Postpartum hypopituitarism had been identified and endocrine examination was performed (Table I). In addition to insulin-like growth factor-1 (IGF-1) deficiency, the patient's pituitary-thyroid, pituitary-gonadal and pituitary adrenal axes were dysfunctional and magnetic resonance imaging of the pituitary gland revealed an empty sella, indicating anterior hypopituitarism resulting from postpartum hemorrhage. Biochemical parameters at baseline and during follow-up are presented in Table II. A chest computed tomography (CT)

---

*Correspondence to:* Professor Xiao-Li Zhang, Department of Endocrinology, Qilu Hospital of Shandong University, 107 Wenhua West Road, Lixia, Jinan, Shandong 250000, P.R. China  
E-mail: sallyzh66@sina.com

\*Contributed equally

**Key words:** refractory hypotension, Sheehan syndrome, pituitary crisis, hypopituitarism, hormone replacement therapy

Table I. Endocrine levels at baseline and follow-up.

Parameter	During hospital		After discharge	Normal range
	Baseline	Day 21	3 months	
Free triiodothyronine (pmol/l)	<1.54	2.40	4.12	2.63-5.70
Free thyroxine (pmol/l)	<5.15	10.41	27.06	9.01-19.05
Thyroid-stimulating hormone ( $\mu$ IU/ml)	0.36	0.26	0.04	0.35-4.94
Cortisol ( $\mu$ g/dl)	1.3			8.7-22.4
Adrenocorticotrophic hormone (pg/ml)	1.6			4.7-48.8
Luteinizing hormone (mIU/ml)	0.55			7.7-58.5
Follicle-stimulating hormone (mIU/ml)	0.34			25.8-134.8
Estradiol (pg/ml)	12.17			10-39.5
Prolactin (ng/ml)	0.31			3.4-24.1
Insulin-like growth factor-1 (ng/ml)	5.2			60-350
Growth hormone (ng/ml)	0.027			0.01-5.22

Table II. Biochemical parameters at baseline and follow-up.

Factors	During hospital						After discharge	Normal range
	Day 1	Day 5	Day 8	Day 15	Day 17	Day 25	1 month	
White blood cells ( $\times 10^9/l$ )	7.75	15.61	13.99	10.87	9.40	6.60	6.92	3.5-9.5
Neutrophils (%)	74.1	93.7	93.9	91.1	89.8	78.2	75.6	40-75
Red blood cells ( $\times 10^{12}/l$ )	3.43	3.24	4.31	3.74	3.62	3.55	3.42	3.8-5.1
Hemoglobin (g/dl)	103	101	137	117	112	110	108	115-150
Platelets ( $\times 10^9/l$ )	209	118	121	175	193	172	224	125-350
Alanine transaminase (U/l)	39	308	356	53	42	18	13	7-40
Aspartate transaminase (U/l)	68	399	297	44	41	19	18	13-35
Total protein (g/l)	72.0	46.0	-	47.6	48.1	50.6	65.7	60-85
Albumin (g/l)	45.0	30.4	28.8	32.6	30.7	32.9	43.2	40-55
Blood urea nitrogen (mmol/l)	13.3	8.9	10.0	11.4	10.9	14.1	11.1	2.3-7.8
Creatinine ( $\mu$ mol/l)	119	125	129	121	114	99	99	53-97
Sodium (mmol/l)	136	144	143	144	143	139	141	137-147
Potassium (mmol/l)	2.60	3.85	3.78	3.78	2.57	4.96	3.07	3.5-5.3
Fasting blood glucose (mmol/l)	4.70	9.15	-	8.27	-	6.80	4.43	3.9-6.1
Cholesterol (mmol/l)	4.18	-	-	-	-	-	5.03	2.80-6.00
Triglyceride (mmol/l)	1.5	-	-	-	-	-	0.64	0.30-1.70
LDL-C (mmol/l)	2.45	-	-	-	-	-	2.95	1.00-3.37
HDL-C (mmol/l)	0.83	-	-	-	-	-	1.78	0.80-2.00

LDL-C, Low density lipoprotein cholesterol; HDL-C, high density lipoprotein cholesterol.

scan showed ill-defined ground glass opacity in the left lower lobe due to pulmonary consolidation. The abdominal CT scan was normal. An echocardiogram showed left ventricular (LV) global hypokinesis with decreased LV ejection fraction (LVEF), a medium amount of pericardial effusion and enlarged left atrium and right ventricle (Table III). Mask oxygen inhalation and anti-infective treatment (intravenous drip of meropenem and levofloxacin for two weeks) were

initiated to improve respiratory symptoms. Along with exacerbation of congestive heart failure and renal and hepatic injuries, the patient was treated with volume replacement, digoxin (0.125 mg/dat) and dopamine (3-5  $\mu$ g/min/kg) to raise the blood pressure, albumin infusion to increase colloid osmotic pressure, furosemide injection to relieve edema as well as further symptomatic treatments. Initially, the patient was given a stress dose of intravenous hydrocortisone

Table III. Indexes for cardiac function at baseline and follow-up.

Factor	During hospital				After discharge		Normal range
	Day 1	Day 5	Day 17	Day 25	1 month	3 months	
<b>Cardiac enzymes</b>							
Troponin-I (ng/ml)	0.01	0.23	0.11	0.05	0.02	-	0-0.06
CK-MB (ng/ml)	8.0	4.7	4.6	2.1	2.2	-	0.3-4.0
Nt-proBNP (pg/ml)	548	-	-	-	-	-	<125
<b>Electrocardiogram</b>							
Heart rate (beats/min)	40	111	63	65	65	77	60-100
PR interval	200	130	196	160	196	190	120-200
QRS duration (msec)	78	61	83	68	80	78	<120
T wave	Flat	Flat	Flat	Flat	Flat	Normal	Normal
QT/QTc (msec)	600/490	292/358	362/402	180/225	494/405	352/384	Variable/350-440
Low voltage	Limb leads	Limb leads	Limb leads	Limb leads	Limb leads	None	None
<b>Echocardiography</b>							
LA dimension (mm)	40	-	-	35	-	34	<35
RV dimension (mm)	30	-	-	26	-	23	<25
LVEF (%)	30	-	-	55	-	64	>50
LV motion	Abnormal diastolic hypokinesia	-	-	Abnormal diastolic filling	-	Abnormal diastolic filling	Normal
Tricuspid regurgitation	Severe-moderate	-	-	Moderate	-	Mild	Normal
Pericardial effusion	Medium amount	-	-	Medium amount	-	Small amount	None

CK, creatine kinase; BNP, B-type natriuretic peptide; LVEF, left ventricle ejection fraction; LA, left atrium.

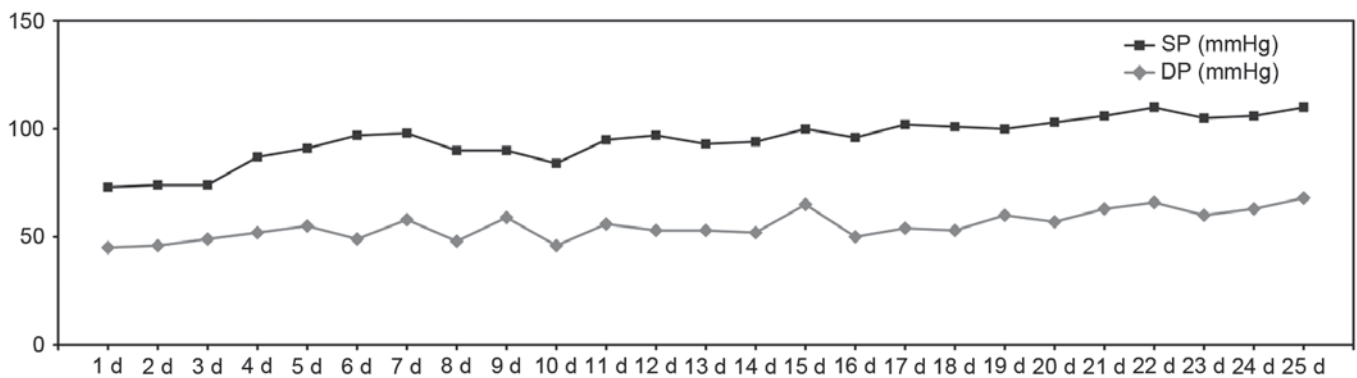


Figure 1. Blood pressure levels (mmHg) in the patient over the course of the treatment. SP, systolic blood pressure; DP, diastolic blood pressure; d, day(s).

(50 mg/6 h) with a gradual reduction to 100 mg/day, followed by a low dose of oral levothyroxine (25 µg/day), which was increased to 100 µg/day. Due to the patient's low and erratic blood pressure, she was fully weaned off vasopressor blood pressure support over 20 days, with blood pressure remaining at levels of around 90/60 mmHg (Fig. 1). Moreover, the patient's general health condition markedly improved, dyspnea eased, chest distress disappeared, edema decreased and fatigue alleviated. Abnormal biochemical indexes were almost restored to normal levels. A later echocardiography

showed dramatic changes in LVEF from 30 to 55%, with a decrease of pericardial effusion and mild tricuspid regurgitation (Table III). The patient was discharged on hydrocortisone (40 mg/day) and levothyroxine (100 µg/day) 28 days after being admitted.

At follow-up 3 months after discharge, a repeat echocardiogram showed LV filling disturbance with a continuous increase in LVEF (64%) as well as normal cardiac size, and blood pressure was increased to 110/70 mmHg with glucocorticoid and levothyroxine replacement therapy. The dose of

levothyroxine was decreased from 100 to 75  $\mu\text{g}$  as a result of a higher free thyroxine level.

## Discussion

Acute pituitary insufficiency, also called pituitary crisis, is a life-threatening condition following a period of non-specific symptoms due to chronic pituitary insufficiency, the causes of which involve electrolyte imbalance, infection, trauma or other forms of stress. Volume depletion and low cardiac output are common in acute pituitary deficiency and recovery of normal cardiovascular status is rapidly achieved under hormone and volume replacement therapy. Vesely *et al* (2) reported a case of post-herpes encephalitic anterior pituitary insufficiency (dysfunction of pituitary-thyroid and pituitary-gonadal axis) with hypothermia and hypotension in a 49-year-old man, and his blood pressure of 90/60 mmHg quickly returned to normal after thyroid hormone replacement therapy. However, the patient of the present study experienced refractory hypotension and required longstanding vasopressor blood pressure support and hormone replacement therapy, which was rarely reported in the literature. Retrospective analysis of 77 retrieved cases of Sheehan syndrome at Qilu Hospital (Jinan, China) from 1999 to 2015 revealed that patients with hypotension accounted for 29.9% (23 cases), whose normalization of blood pressure almost generally occurred on the third or fourth day of treatment, after hormone replacement and correction of hyponatremia.

In the present case, one cause of severe hypotension was closely associated with hypoproteinemia owing to chronic malnutrition and liver damage. Albumin can expand fluid and maintain a stable plasma colloid osmotic pressure, while hypoproteinemia impairs water balance, increasing the likelihood of hypovolemia. Moreover, albumin infusion combined with diuretic injection helped to ease myocardial edema and pericardial effusion, which are beneficial for cardiac function.

Initially, septic shock resulting in hypotension could not be excluded, as indicated by an increased white blood cell count and neutrophils, respiratory symptoms and chest radiological findings. After potent fluoroquinolones (levofloxacin) and cabapenems (meropenem) had been administered for two weeks, respiratory symptoms were obviously remitted. However, the white blood cell count did not decrease, which was associated with the intravenous infusion of hydrocortisone (50 mg/6 h). With the extenuation of hydrocortisone, the white blood cell count returned to normal. Infectious factors were no longer considered, as the blood pressure was not markedly elevated.

During the evaluation, symptomatic heart failure and elevated cardiac enzymes raised the suspicion of myocardial ischemia or an acute infraction resulting in hypotension. It has been reported that endocrine disorders lead to abnormal lipid and glucose metabolism and are therefore implicated in the genesis of acute coronary syndrome (ACS). However, this possibility was quickly ruled out based on the following points: i) Cardiac markers are not specific for ACS and only resemble a manifestation of myocardial damage to a certain extent; ii) serum lipid levels, a risky factor for assessing cardiovascular disease, were in the normal range; iii) nonspecific and abnormal electrocardiogram (ECG) patterns, such as sinus

bradycardia, prolonged QT intervals, low limb lead voltage and abnormal T wave, suggested a correlation with metabolic disease; iv) compared with the original ECG, there were no dynamic changes indicating ACS; v) the patient had no history of cardiac disease or diabetes mellitus; vi) an echocardiogram showed LV global hypokinesis with decreased LVEF, which was consistent with cardiomyopathy (Table III). Therefore, the patient's refractory hypotension was attributed to cardiomyopathy.

Of all endocrine hormone deficiencies linked to cardiomyopathy, glucocorticoid, thyroid hormone and growth hormone deficiencies have major roles. The mechanisms responsible for the development of cardiomyopathy are varied: i) Thyroid hormone deficiency has a significant impact on myocardial injury, resulting in weakening of myocardial contraction and relaxation, decrease in cardiac output, and rhythm disturbances, through genomic and non-genomic effects (3-5). ii) Catecholamine overproduction during stress may be toxic to the myocardium, which is unprotected by inadequate glucocorticoids, impairing cardiac function; glucocorticoid deficiency disturbs the transport function of the membrane calcium pump, affecting myocardial contractility (6,7). iii) Numerous experimental studies have demonstrated that growth hormone/IGF-1 deficiency has a deleterious influence on cardiac growth, myocardial contractility and vascular system (8,9). However, certain case studies have indicated that growth hormone deficiency has a minimal role in pathogenic mechanisms of cardiomyopathy (10,11). Laway *et al* (10) described a case of cardiomyopathy linked to Sheehan syndrome and pulmonary tuberculosis in a 25-year-old women, whose cardiac function was completely restored after replacement therapy with glucocorticoid and levothyroxine.

On the basis of the abovementioned pathogenesis, the patient was initiated with a stress dose of hydrocortisone, followed by a small dose of oral levothyroxine under the state of high stress. Glucocorticoid is replaced prior to levothyroxine to avoid aggravating pituitary crisis. In contrast to previous patients, the patient of the present study was also given positive inotropic agents, digoxin and dopamine, which improved hemodynamics and increased cardiac pump function. Her blood pressure did not return to normal until vasopressor blood pressure support and hormone replacement therapy were provided for 20 days. It is speculated that a longstanding adverse influence on cardiac function may be the primary cause of refractory hypotension. The patient was discharged whilst receiving a physiological dosage of hydrocortisone and levothyroxine. At 3-month follow-up, cardiac function was partly reversed with preserved LVEF, normal cardiac size, small pericardial effusion and abnormal LV diastolic filling.

The definite reason why the patient's hormone-induced cardiac dysfunction was not completely resolved remains elusive. One explanation that long-standing hormone deficiencies drive the irreversible change of myocardial damage appears to not be dependable (11,12). Bao and Fisher (11) reported on a 35-year-old woman with long-standing hypopituitarism for 15 years and heart failure for at least 10 years with severely compromised cardiac function. At 9 months after discharge, echocardiography showed completely normalized cardiac function without growth hormone replacement (11). Similarly, Kissell *et al* (12) reported on a 40-year-old patient

with cardiogenic shock due to non-ischemic cardiomyopathy induced by severe anterior hypopituitarism initially treated with levothyroxine and hydrocortisone replacement therapy, who had 20 years of history of undiagnosed Sheehan syndrome. Eighteen months later, echocardiography revealed that LVEF was partially reversed (12). One hypothesis is that GH deficiency is involved in pathogenic mechanisms of cardiomyopathy, although there is a possibility of complete recovery of cardiac function without growth hormone replacement (10,11). In the present case, the irreversibility of cardiac damage may have been associated with the short duration of hormone replacement therapy, while there is a possibility that cardiomyopathy may be completely reversed in the future.

The importance of a rapid diagnosis of Sheehan syndrome, particularly intercurrent hypopituitary crisis, should be emphasized, as otherwise, treatment is delayed and patients remain in a critical condition. Kaufmann *et al* (13) reported on a 52-year-old woman who developed hypopituitary crisis with severe hypotension and coma secondary to unrecognized chronic anterior hypophysitis. Unfortunately, she succumbed to refractory cardiac arrest without prompt hormone replacement treatment. In the present case, the important information that the patient had a history of Sheehan syndrome was available, which provided a hint for selecting an appropriate treatment.

In conclusion, a prompt diagnosis and specific treatment of Sheehan syndrome is vital. The present case illustrated that refractory hypotension is a rare and serious complication of longstanding hypopituitarism induced by Sheehan syndrome with pituitary crisis, of which volume depletion and low cardiac output are common pathological mechanisms. The case also exemplified that glucocorticoid, thyroid hormone and growth hormone deficiencies may contribute to cardiomyopathy by varying degrees, and cardiac function may be restored with hormone replacement therapy.

## References

1. Shivaprasad C: Sheehan syndrome's syndrome: Newer advances. *Indian J Endocrinol Metab* 15 (Suppl 3): S203-S207, 2011.
2. Vesely DL, Mastrandrea P, Samson C, Argyelan G and Charvit S: Post-herpes encephalitic anterior pituitary insufficiency with hypothermia and hypotension. *Am J Med Sci* 320: 273-277, 2000.
3. Vargas-Uricoechea H and Sierra-Torres CH: Thyroid hormones and the heart. *Horm Mol Biol Clin Invest* 18: 15-26, 2014.
4. Galli E, Pingitore A and Iervasi G: The role of thyroid hormone in the pathophysiology of heart failure: Clinical evidence. *Heart Fail Rev* 15: 155-169, 2010.
5. Schmidt-Ott UM and Ascheim DD: Thyroid hormone and heart failure. *Curr Heart Fail Rep* 3: 114-119, 2006.
6. Cleghorn RA: Cardiovascular failure in experimental adrenal insufficiency: A history revival. *Perspect Biol Med* 27: 135-155, 1983.
7. Narayanan N: Effects of adrenalectomy and in vivo administration of dexamethasone on ATP-dependent calcium accumulation by sarcoplasmic reticulum from rat heart. *J Mol Cell Cardiol* 15: 7-15, 1983.
8. Castellano G, Affuso F, Conza PD and Fazio S: The GH/IGF-1 axis and heart failure. *Curr Cardiol Rev* 5: 203-215, 2009.
9. Lombardi G, Di Somma C, Grasso LF, Savanelli MC, Colao A and Pivonello R: The cardiovascular system in growth hormone excess and growth hormone deficiency. *J Endocrinol Invest* 35: 1021-1029, 2012.
10. Laway BA, Alai MS, Gojwari T, Ganie MA and Zargar AH: Sheehan syndrome with reversible dilated cardiomyopathy. *Ann Saudi Med* 30: 321-324, 2010.
11. Bao SS and Fisher SJ: Repairing a 'broken heart' with hormone replacement therapy: Case report of cardiogenic shock due to undiagnosed pituitary insufficiency. *Endocr Pract* 18: e26-e31, 2012.
12. Kissell N, Mudd JO, Gelow JM, Chong LE and Yuen KC: Cardiogenic shock due to non-ischemic cardiomyopathy induced by severe anterior hypopituitarism. *Endocr Pract*: Nov 4, 2014 (Epub ahead of print).
13. Kaufmann P, Lax SF, Radner H, Eber B, Leuger A and Smolle KH: Severe hypotension and coma secondary to unrecognized chronic anterior hypophysitis. *Intensive Care Med* 21: 847-849, 1995.