

Endobronchial ultrasound-guided transbronchial needle aspiration for thyroid cyst therapy: A case report

PENG LI¹, WEI ZHENG¹, HONGBO LIU¹, ZHENYONG ZHANG² and LI ZHAO¹

¹Department of Respiratory Medicine, Shengjing Hospital of China Medical University, Shenyang, Liaoning 110004;

²Department of Medical Oncology, Shengjing Hospital of China Medical University, Shenyang, Liaoning 110022, P.R. China

Received December 10, 2015; Accepted December 23, 2016

DOI: 10.3892/etm.2017.4213

Abstract. Endobronchial ultrasound-guided transbronchial needle aspiration (EBUS-TBNA) is of limited usefulness for diagnosing thyroid disease, and few studies have reported its use in diagnosing and treating thyroid cysts. The present study investigated a unique case of diagnosis and treatment of a thyroid cyst by EBUS-TBNA. A 67-year-old male presented with back pain. Positron emission tomography/computed tomography scanning revealed low-density signals in the right lobe of the thyroid. Needle aspiration biopsies and drainage at this site was performed, and EBUS was used for guidance in diagnosing the thyroid cyst. A follow-up chest computed tomography scan indicated that the thyroid lesion had subsequently disappeared. The present study concludes that EBUS-TBNA provides an alternative approach for diagnosing and treating deep thyroid cysts located close to the airway. In all other cases, percutaneous needle aspiration or surgery should be the first choice.

Introduction

Endobronchial ultrasound (EBUS) has been used in clinical practice since the 1990s (1). EBUS may be used in combination with needle aspiration to obtain biopsy samples of lesions outside the airway, an application that may be termed 'EBUS-guided transbronchial needle aspiration (EBUS-TBNA)' (2). This widely used technique is recommended as an important tool for staging mediastinal lymph nodes containing malignant cells (3,4) and is predominantly used for scanning and needle aspiration biopsies of mediastinal lymph nodes outside the trachea and main bronchi (5-7). Occasionally, this approach has been used for

exploratory studies of the lesions outside the lobar bronchi and segmental bronchi (8), mediastinum (9,10), thoracic great vessels (11-13), pericardium (14), heart (15), esophagus (16), thyroid (17), and other tissues and organs (18). As the thyroid gland is located near and anterolateral to the upper trachea, the EBUS-TBNA technique may be useful in scanning thyroid lesions and obtaining needle aspiration samples for biopsy. Various case reports (17,19) and a small-sample retrospective study (20) have been published on the application of the EBUS-TBNA technique; however, few reports are available concerning the use of this technique to diagnose thyroid cysts (21). To date, no report has been published on the application of the EBUS-TBNA technique to treat thyroid cysts. Thus, the present case report investigated a case of a thyroid cyst that was diagnosed and treated via the EBUS-TBNA technique.

Case report

The present study was approved by the Institutional Review Board of Shengjing Hospital of China Medical University (no. 2015PS61J; Shenyang, China) A 67-year-old male was admitted to our hospital due to spontaneous back pain with no existing medical conditions and presented without respiratory symptoms, such as cough or shortness of breath. Physical examination revealed no positive findings. Serum carcinoembryonic antigen level was $<5 \mu\text{g/l}$ (reference range: $0-5 \mu\text{g/l}$) using a Cobas E602 immunoassay module (Roche Diagnostics, Basel, Switzerland). A positron emission tomography-computed tomography (PET/CT) scan (Siemens AG, Munich, Germany) was performed to exclude neoplastic diseases and revealed a soft tissue mass in the hilum of the left lung, a soft tissue nodule in the lower lobe of the left lung, enlarged lymph nodes superior to the left clavicle and inferior to the carina within the mediastinum, left-sided pleural effusion, bilateral pleural thickening and low-density signals in the right lobe of the thyroid (Fig. 1). To obtain a definite diagnosis, an ultrasound bronchoscope (HI-VISION Avius; Hitachi, Ltd., Tokyo, Japan) and an EB-1970UK video bronchoscope (Pentax, Tokyo, Japan) was used, following an EBUS-TBNA examination on March 18th 2015 after receiving informed consent from the patient. Ultrasound examination of the right lobe of the thyroid indicated an 11.3×14.0 -mm oval lesion with clear boundaries, and a medium-to-low signal of an incomplete

Correspondence to: Professor Li Zhao, Department of Respiratory Medicine, Shengjing Hospital of China Medical University, 36 Sanhao Street, Shenyang, Liaoning 110004, P.R. China
E-mail: lzhaoli@163.com

Key words: endobronchial ultrasound-guided transbronchial needle aspiration, thyroid cyst, drainage

membrane containing a medium-to-low signal center without blood flow (Fig. 2). Three needle aspiration biopsies, using endobronchial ultrasound needles (ECHO-HD-22-EBUS-P; EchoTip Ultra; Cook Medical, Inc., Bloomington, IN, USA), were performed at this site (Fig. 3), and 1.5 ml of a cloudy, yellow viscous fluid was obtained. The aspiration needles were changed and needle aspiration biopsies for lesions in the subcarinal area and the hilum of the left lung were performed. A small amount of bleeding occurred at the aspiration site; however, no major complications were reported following aspiration. Aspirates were collected and fixed in formalin at 20°C for 18 h and subsequently embedded in paraffin. Sections were cut (thickness, 5 μ m) and stained with hematoxylin and eosin. Cytopathological examinations were performed under a light microscope, and the results indicated a low number of inflammatory cells and thyroid epithelial cells; however, tumor cells associated with thyroid or other organs were absent (Fig. 4). The findings from the pathology examination of the subcarinal lymph nodes and from the lesion itself were negative for malignancy. Subsequently a percutaneous needle aspiration biopsy of the nodule in the lower lobe of the left lung was performed. Pathological examination of the percutaneous needle aspirates indicated lung adenocarcinoma (bronchial mucosa) based on the following immunohistochemistry results: Tumor proteins p63(+) and p40(-), NapsinA(+), thyroid transcription factor-1(+), synecocystis(-), cytokeratin(+). Reverse transcription-quantitative polymerase chain reaction was performed as previously described (22) and the results of epidermal growth factor receptor mutation testing were negative. Combined with the result of the PET/CT, the final diagnoses were lung adenocarcinoma with bone metastasis (stage IV) and thyroid cyst (21). The patient received systemic chemotherapy on 4 occasions between March and August 2015. Intravenous chemotherapy drugs included cisplatin (cycles 1 and 2; 140 mg per cycle; Qilu Pharmaceutical Co., Ltd., Shandong, China), carboplatin (cycle 2; 500 mg; Qilu Pharmaceutical Co., Ltd.), and zoledronic acid (cycle 3; Zometa; 8 mg; Novartis, Basel, Switzerland). Local radiotherapy for bone metastasis was used in conjunction with oral erlotinib tablets (Tarceva; 150 mg/day; Roche Diagnostics) for cycle 4 of the chemotherapy. A follow-up chest CT scan at 7 weeks post-aspiration showed that the low-density signal in the right lobe of the thyroid had disappeared (Fig. 5).

Discussion

Thyroid cysts are relatively common benign lesions, which are predominantly solitary elastic lesions that exhibit a smooth surface and clear boundaries (21,23). Typically, no tenderness is experienced and no adhesion between the cyst and peripheral tissues is apparent (24,25). Radioisotope scanning indicates the cyst as a 'cold' nodule, whereas an ultrasound examination reveals its cystic nature (26). Echo signals are mixed, with the anechoic area containing low- or medium-strength echo signals of deposits on the lower portion of the cyst, or attached to the cyst wall. Occasionally septa may be present inside the cyst (23,25). Thyroid cysts may be diagnosed according to the characteristics mentioned above, as demonstrated in the present case. In particular, the present study revealed that EBUS indicated medium-strength

echo signals of deposits on the lower portion of the cyst and the cyst fluid obtained by needle aspiration, which is the most direct diagnostic tool, indicated the presence of a thyroid cyst. Consequently, the EBUS examination in the present study provided the information required to diagnose a thyroid cyst in the patient.

While most patients with thyroid cysts experience no clinical symptoms, the cyst grows continuously, creating a risk of intracystic bleeding. Therefore, thyroid cysts should be treated soon after a definitive diagnosis has been made. Local aspiration and anhydrous ethanol irrigation are appropriate techniques used for treating superficial small cysts (<30 mm in diameter) (27). The procedures are minimally invasive and result in less pain for the patient and provide a satisfactory outcome; however, secondary bleeding is a recognized risk with this method. In order to treat deep thyroid cysts (>30 mm in diameter), surgical removal is a safe and reliable preferred option (27). In the present case study, the maximum diameter of the cyst was 14 mm and the cyst was located deep but close to the trachea. The EBUS technique was used to demonstrate its use as an alternative method for diagnosis and treatment, which avoids possible trauma inflicted by surgery and therefore offers an alternative for patients who cannot undergo surgery.

In the present case, the EBUS technique was used to diagnose the patient and treat the thyroid cyst, simultaneously. The patient tolerated the whole process well. Combined with the findings of case reports (19,20) and a small-sample retrospective study (17), we believe that needle aspiration biopsy and treatment using the EBUS technique are feasible procedures for deep lesions near the trachea. Additionally, EBUS guided needle aspiration to thyroid is useful to further determine that the condition of the patient is not the result of primary thyroid tumors or lung cancer metastasis to the thyroid (28).

In previous case reports, two patients presented with serious complications after EBUS-TBNA of the thyroid (29,30). One patient had a skin rash on the suprasternal notch 48 h after the biopsy procedure. Even after flucloxacillin administration, spontaneous drainage of pus occurred at the site of the rash; however, the rash disappeared after 6 days of treatment (29). Culture of the pus identified the pathogen as penicillin-sensitive *Streptococcus pneumoniae*. Another patient presented with a fever, swelling of the neck, and pain arising 8 days after biopsy. The ultrasound examination indicated an abscess in the thyroid. Ultrasound-guided percutaneous aspiration was performed twice to remove the pus, and an antibiotic was administered intravenously. Pus culture revealed penicillin-sensitive *Streptococcus mitis* and mixed gram-positive and gram-negative bacteria. However, the patient did make a full recovery (30). These cases suggest that the EBUS-TBNA technique is not aseptic and resulted in infection, which may occur easily during aspiration and manipulation of the thyroid lesions (31).

Casal *et al* (17) investigated the causes of infection following EBUS-TBNA and identified that 11 of 12 patients examined after the laryngeal mask airway who received EBUS-TBNA under general anesthesia had no complications, suggesting that manipulation under general anesthesia may reduce the risk of infection, rather than in a less-sedated

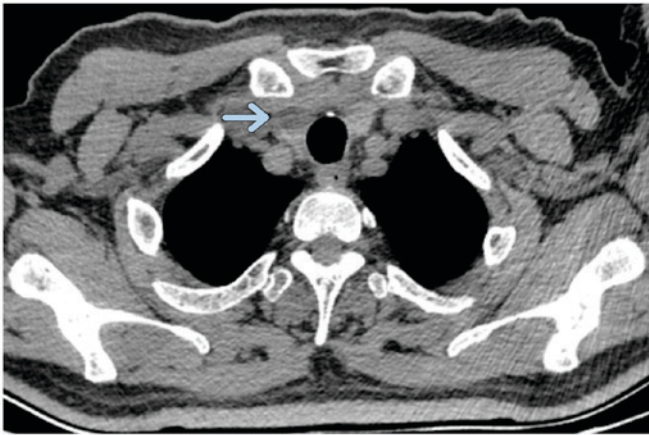


Figure 1. A computed tomography scan indicated a low-density mass in the right lobe of the thyroid posterior to the clavicle (arrow).

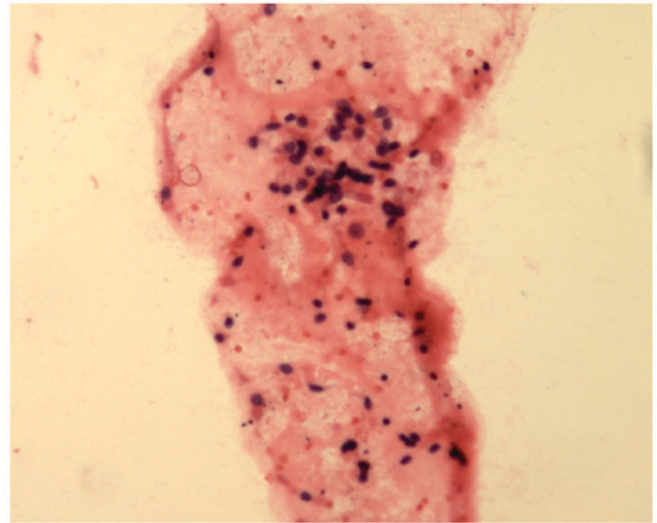


Figure 4. Pathological analysis of the lesion in the right lobe of the thyroid following endobronchial ultrasound transbronchial needle aspiration. Hematoxylin and eosin staining revealed some inflammatory cells and thyroid epithelial cells in the aspirates (magnification, x100).

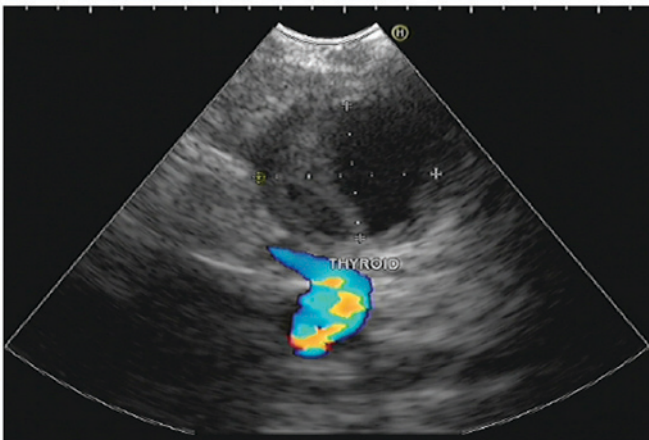


Figure 2. Endobronchial ultrasound with color doppler revealed an oval lesion in the right lobe of the thyroid.

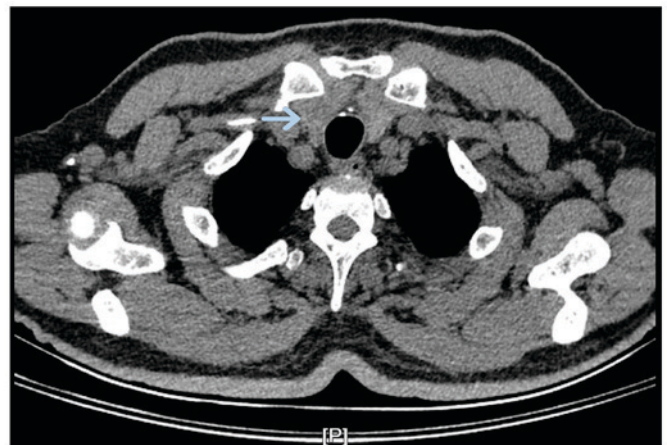

Figure 5. Low-density signal in the right lobe of the thyroid disappeared following aspiration therapy compared with before the operation. Arrow indicates where the signal originally appeared, as illustrated in Fig. 1.

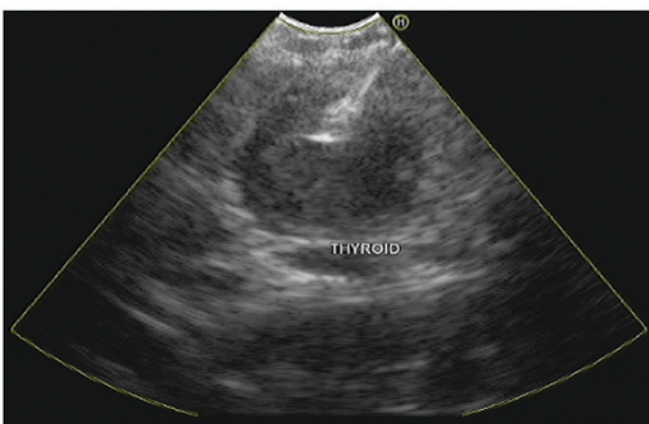


Figure 3. Endobronchial ultrasound transbronchial needle aspiration biopsy and drainage of the lesion in the right lobe of the thyroid.

state. Moreover, previous studies have demonstrated that the two patients described above were infected with penicillin-sensitive *Streptococcus* after EBUS-TBNA procedures of the thyroid (29,30). Hence, perioperative antibiotic administration is necessary for reducing the incidence of

infection. In order to reduce the incidence of infection three key steps should be considered: Using general anesthesia, administering antibiotics perioperative and decreasing the frequency of aspiration.

The present case study reported for the first time a case of thyroid cyst treated with the EBUS-TBNA technique. We believe that aspiration of the thyroid cyst using the EBUS-TBNA technique is feasible. However, strict criteria for this procedure are required to reduce the risk of possible complications. The effectiveness and safety of the EBUS-TBNA technique in the manipulation of thyroid cysts should be verified by future large-sample clinical studies. Until randomized, controlled studies yield positive results, the range of application of the EBUS-TBNA technique will not be expanded (30). To conclude, EBUS-TBNA provides an alternative for the diagnosis and treatment of deep thyroid cysts located close to the airway. In all other cases, percutaneous needle aspiration or surgery should be the first choice.

References

- Hürter T and Hanrath P: Endobronchial sonography: Feasibility and preliminary results. *Thorax* 47: 565-567, 1992.
- Wahidi MM, Herth F, Yasufuku K, Shepherd RW, Yarmus L, Chawla M, Lamb C, Casey KR, Patel S, Silvestri GA and Feller-Kopman DJ: Technical aspects of endobronchial ultrasound-guided transbronchial needle aspiration: CHEST guideline and expert panel report. *Chest* 149: 816-835, 2016.
- De Leyn P, Dooms C, Kuzdzal J, Lardinois D, Passlick B, Rami-Porta R, Turna A, Van Schil P, Venuta F, Waller D, *et al*: Preoperative mediastinal lymph node staging for non-small cell lung cancer: 2014 update of the 2007 ESTS guidelines. *Transl Lung Cancer Res* 3: 225-233, 2014.
- Colella S, Vilman P, Konge L and Clementsen PF: Endoscopic ultrasound in the diagnosis and staging of lung cancer. *Endosc Ultrasound* 3: 205-212, 2014.
- Geake J, Hammerschlag G, Nguyen P, Wallbridge P, Jenkin GA, Korman TM, Jennings B, Johnson DF, Irving LB, Farmer M and Steinfurt DP: Utility of EBUS-TBNA for diagnosis of mediastinal tuberculous lymphadenitis: A multicentre Australian experience. *J Thorac Dis* 7: 439-448, 2015.
- Harris K, Maroun R, Attwood K and Chalhoub M: Comparison of cytologic accuracy of endobronchial ultrasound transbronchial needle aspiration using needle suction versus no suction. *Endosc Ultrasound* 4: 115-119, 2015.
- Ozgul MA, Cetinkaya E, Kirkil G, Ozgul G, Abul Y, Acat M, Onaran H, Urer HN, Tutar N and Dincer HE: Lymph node characteristics of sarcoidosis with endobronchial ultrasound. *Endosc Ultrasound* 3: 232-237, 2014.
- Kurimoto N, Inoue T, Miyazawa T, Morita K, Matsuoka S and Nakamura H: The usefulness of endobronchial ultrasonography-guided transbronchial needle aspiration at the lobar, segmental, or subsegmental bronchus smaller than a convex-type bronchoscope. *J Bronchology Interv Pulmonol* 21: 6-13, 2014.
- Eckardt J: Endobronchial ultrasound-guided transbronchial needle aspiration of lesions in mediastinum. *J Thorac Dis* 2: 125-128, 2010.
- Badaoui A, Dahlqvist C, Rahier J, Weynand B, Ocak S, Deprez P, Eucher P and Duplaquet F: Combined endoscopic ultrasonography and endobronchial ultrasound-fine-needle aspiration for evaluation of mediastinal lymph nodes. *Endosc Ultrasound* 3 (Suppl 1): S9, 2014.
- Aumiller J, Herth FJ, Krasnik M and Eberhardt R: Endobronchial ultrasound for detecting central pulmonary emboli: A pilot study. *Respiration* 77: 298-302, 2009.
- Harris K, Modi K, Kumar A and Dhillon SS: Endobronchial ultrasound-guided transbronchial needle aspiration of pulmonary artery tumors: A systematic review (with video). *Endosc Ultrasound* 4: 191-197, 2015.
- Modi K, Dhillon S, Kumar A, Ylagan L and Harris K: Leiomyosarcoma of the pulmonary artery diagnosed by endobronchial ultrasound-guided transbronchial needle aspiration. *Endosc Ultrasound* 3: 249-251, 2014.
- Zarogoulidis P and He MC: Dr. Paul Zarogoulidis: The exploration on pneumothorax and new use of EBUS. *J Thorac Dis* 7: E106, 2015.
- Cetinkaya E, Yılmaz A, Özgül A, Gençoğlu A and Günlüoğlu G: Left atrial mass demonstrated during endobronchial ultrasound session. *Respiration* 81: 57-58, 2011.
- Wakamatsu T, Tsushima K, Yasuo M, Yamazaki Y, Yoshikawa S, Koide N, Fujimori M and Koizumi T: Usefulness of preoperative endobronchial ultrasound for airway invasion around the trachea: Esophageal cancer and thyroid cancer. *Respiration* 73: 651-657, 2006.
- Casal RF, Phan MN, Keshava K, Garcia JM, Grosu H, Lazarus DR, Iribarren J and Rosen DG: The use of endobronchial ultrasound-guided transbronchial needle aspiration in the diagnosis of thyroid lesions. *BMC Endocr Disord* 14: 88, 2014.
- Dincer HE, Glikberg EP and Andrade RS: Endoscopic ultrasound and/or endobronchial ultrasound-guided needle biopsy of central intraparenchymal lung lesions not adjacent to airways or esophagus. *Endosc Ultrasound* 4: 40-43, 2015.
- Kumar A, Mohan A, Dhillon SS and Harris K: Substernal thyroid biopsy using Endobronchial Ultrasound-guided Transbronchial Needle Aspiration. *J Vis Exp* e51867, 2014.
- Madan K, Mittal S, Hadda V, Jain D, Mohan A and Guleria R: Endobronchial ultrasound-guided transbronchial needle aspiration of thyroid: Report of two cases and systematic review of literature. *Lung India* 33: 682-687, 2016.
- Sánchez-Font A, Peralta S and Curull V: Thyroid cyst diagnosed by endobronchial ultrasound-guided transbronchial needle aspiration in a patient with lung cancer. *Arch Bronconeumol* 49: 38-39, 2013 (In English, Spanish).
- Han CB, Ma JT, Li F, Zhao JZ, Jing W, Zhou Y and Zou HW: EGFR and KRAS mutations and altered c-Met gene copy numbers in primary non-small cell lung cancer and associated stage N2 lymph node-metastasis. *Cancer Lett* 314: 63-72, 2012.
- Hegedüs L: Clinical practice. The thyroid nodule. *N Engl J Med* 351: 1764-1771, 2004.
- American Thyroid Association (ATA) Guidelines Taskforce on Thyroid Nodules and Differentiated Thyroid Cancer, Cooper DS, Doherty GM, Haugen BR, Kloos RT, Lee SL, Mandel SJ, Mazzaferri EL, McIver B, Pacini F, *et al*: Revised American Thyroid Association management guidelines for patients with thyroid nodules and differentiated thyroid cancer. *Thyroid* 19: 1167-1214, 2009.
- Burch HB: Evaluation and management of the solid thyroid nodule. *Endocrinol Metab Clin North Am* 24: 663-710, 1995.
- Weber AL, Randolph G and Aksoy FG: The thyroid and parathyroid glands. CT and MR imaging and correlation with pathology and clinical findings. *Radiol Clin North Am* 38: 1105-1129, 2000.
- Gharib H, Papini E, Garber JR, Duick DS, Harrell RM, Hegedüs L, Paschke R and Valcavi R; Vitti P; AACE/ACE/AME Task Force on Thyroid Nodules: American association of clinical endocrinologists, American college of endocrinology, and associazione medici endocrinologi medical guidelines for clinical practice for the diagnosis and management of thyroid nodules-2016 update. *Endocr Pract* 22: 622-639, 2016.
- Katsenos S, Archondakis S, Vaias M and Skoulikaris N: Thyroid gland metastasis from small cell lung cancer: An unusual site of metastatic spread. *J Thorac Dis* 5: E21-E24, 2013.
- Steinfurt DP, Johnson DF and Irving LB: Infective complications from endobronchial ultrasound-transbronchial needle aspiration. *Eur Respir J* 34: 524-525, 2009.
- Kennedy MP, Breen M, O'Regan K, McCarthy J, Horgan M and Henry MT: Endobronchial ultrasound-guided transbronchial needle aspiration of thyroid nodules: Pushing the boundary too far? *Chest* 142: 1690-1691, 2012.
- Haas AR: Infectious complications from full extension endobronchial ultrasound transbronchial needle aspiration. *Eur Respir J* 33: 935-938, 2009.