

# Clinical observation of umbilical cord mesenchymal stem cell treatment of severe idiopathic pulmonary fibrosis: A case report

CHUNYU ZHANG<sup>1,2</sup>, XIAOGUANG YIN<sup>2</sup>, JINGHAN ZHANG<sup>1</sup>, QIANG AO<sup>3</sup>, YONGQUAN GU<sup>4</sup> and YING LIU<sup>2,5</sup>

<sup>1</sup>Department of Respiratory Medicine, Siping Hospital of China Medical University; <sup>2</sup>Jilin Tuhua Bioengineering Co., Ltd., Siping, Jilin 136000; <sup>3</sup>Department of Tissue Engineering, China Medical University, Shenyang, Liaoning 110122; <sup>4</sup>Department of Vascular Surgery, Xuanwu Hospital, Capital Medical University, Beijing 100053; <sup>5</sup>Key Laboratory of Tissue Engineering of Jilin, Siping, Jilin 136000, P.R. China

Received March 10, 2016; Accepted February 2, 2017

DOI: 10.3892/etm.2017.4222

**Abstract.** Idiopathic pulmonary fibrosis (IPF) is a degenerative disease characterized by fibrosis. Cell therapy has been considered within the therapeutic options for IPF. In this study, we explored the potential benefits of human umbilical cord-derived mesenchymal stem cell (HUC-MSC) intravenous infusion in the management of IPF. We describe a case of a 56-year-old man with IPF who was receiving long-term oxygen therapy (LTOT). The patient underwent HUC-MSC intravenous infusion and was followed up for 12 months. Clinical and motor tests, as well as questionnaires assessing quality of life, were performed prior to and following the transplantation. At the end of 12 months, a relevant reduction of LTOT requirement was registered; improvements in terms of physical performance, quality of life, and respiratory parameters were observed in our patient. In conclusion, a program of HUC-MSC intravenous infusion appears to be beneficial to patients with IPF and may be considered as an additional therapeutic option.

## Introduction

Idiopathic pulmonary fibrosis (IPF) is a devastating, fibro-proliferative chronic lung disorder (1,2), which continues to

exercise a heavy human, financial and social toll on its victims and their family. Despite intense research efforts and large multicenter clinical trials, IPF is gradually increasing worldwide (3). Therefore, developing new treatments for IPF that are safe, effective and tolerable is now more challenging than ever. A growing number of investigations of the therapeutic potential of mesenchymal stem cells (MSCs) in experimental models of chronic lung diseases have expanded rapidly (4). MSCs are stromal cells that can be readily harvested from numerous tissues including bone marrow, human umbilical cord-derived MSCs (HUC-MSCs) (5-7) and cord blood (8,9). HUC-MSCs are widely available, with easy proliferation and multi-differentiation, low immunogenicity, and can be collected in a noninvasive manner; thus, therapy involving HUC-MSCs is attracting increasing attention. However, only a few cases of the clinical application in the treatment of IPF have been reported.

In previous studies, we investigated the safety and efficacy of HUC-MSCs in rat and human bone nonunion (10-12). In the present study, HUC-MSCs were introduced into a patient of IPF. The effect of HUC-MSCs on the pulmonary fibrosis was then assessed in the following 12 months. The aim of this case report was to provide useful clinical insights for future efficacy trials of stem cell therapy in IPF.

## Case report

We report a case of a 56-year-old Chinese man who had previously smoked cigarettes (45 pack-years) in combination with chronic obstructive pulmonary disease (COPD). Before his IPF diagnosis our patient had been affected by COPD for 5 years. His diagnosis of IPF was also confirmed by chest high-resolution computed tomography (HRCT) showing areas of intralobular interstitial and septal thickening with peripheral bilateral distribution in addition to centrilobular emphysema of both the lobes. In admission to our department, the patient exhibited chronic respiratory failure, reporting dyspnea on exertion and dry cough. Our patient received long-term oxygen therapy (LTOT) with 2.0 l/min of flow during 24 h as his peripheral capillary oxygen saturation (SpO<sub>2</sub>) steeply declined when oxygen therapy was discontinued (SpO<sub>2</sub>=70-75%). Based on the published diagnostic criteria of ATS/ERS (2011), the

---

*Correspondence to:* Professor Ying Liu, Key Laboratory of Tissue Engineering of Jilin, 89 Nanyingbin Road, Siping, Jilin 136000, P.R. China  
E-mail: ly3641829@163.com

*Abbreviations:* DLCO, diffusing capacity of the lung for carbon monoxide; FEV<sub>1</sub>, forced expiratory volume in one second; FVC, forced vital capacity; HRCT, high-resolution computed tomography; LTOT, long-term oxygen therapy; PaO<sub>2</sub>, partial arterial pressure of oxygen; PaCO<sub>2</sub>, partial pressure of carbon dioxide; PAP, pulmonary artery pressure; PiMax, maximal inspiratory pressure; PeMax, maximal expiratory pressure; 6MWT, six-minute walk test; VAS, visual analogue scale

*Key words:* cell therapy, idiopathic pulmonary fibrosis, infusion, mesenchymal stem cells, safety, efficacy

patients' disease severity was estimated with functional parameters including forced vital capacity (FVC)=68.6% and diffusing capacity of the lung for carbon monoxide (DLCO)=46.3% of the predicted normal values, the spirometry showed a relatively mild mixed concurrent pulmonary hypertension [pulmonary artery pressure (PAP), 60 mmHg] as diagnosed by color Doppler echocardiography.

**Basic principles and ethical considerations.** The protocol of the present study was approved by the Institutional Review Board and the Ethics Committee of Siping Hospital of China Medical University. The trial was conducted in compliance with current Good Clinical Practice standards and in accordance with the principles set forth under the Declaration of Helsinki (1989).

**Informed consent.** The patient signed an informed consent form agreeing to his treatment according to the Siping Hospital of China Medical University. The general characteristics of the patient are shown in Table I.

**Physical and laboratory examination.** The patient underwent a detailed physical and laboratory examination including arterial blood gases, electrocardiogram (ECG), estimation of vital signs (blood pressure, temperature, breaths and beats per minute) as well as routine laboratory tests, including white blood cell count and differential count, red blood cell count, liver and renal function and chest HRCT, screening to evaluate the functional and radiological severity of the disease and to localize the areas of the lungs.

**Isolation, propagation and confirmation of HUC-MSC phenotype.** All of the HUC-MSC doses used in this trial were derived from two donated umbilical cords obtained from healthy mothers during routine term elective caesarean section birth. Fully informed consent was obtained several weeks prior to delivery. HUC-MSC were isolated and propagated as previously described (10,11) were more than 90% double positive for CD105 and CD90, negative for HLA-DR and CD45.

**HUC-MSC intravenous infusion.** The patient was placed in the supine position, The HUC-MSCs were perfused into the right median cubital vein. HUC-MSCs (10 ml) with a cell density of  $5 \times 10^6$ - $1 \times 10^7$ /ml was intravenous infused at a rate no greater than  $12.5 \times 10^6$ /min and flushed with 20 ml saline to ensure full cell dose delivery. Once the needle was fully withdrawn, the puncture site was wrapped with sterilized dressing. The patients remained in the supine decubitus on the operation bed for another 30 min before off-bed activities. Antibiotics were given to prevent infection. The patient was monitored (temperature, blood pressure, pulse and oxygen saturation) at 15, 30, 45 and 60 min, and then hourly for a minimum of 4 h.

The patient was instructed to limit activities for 4 weeks and partial activities for the subsequent 8 weeks. Full activities were achieved 6 months post-translation.

**Clinical, functional and radiological assessment.** i) Primary safety assessments included monitoring and recording of all adverse events and serious adverse events. Arterial blood gases coupled with clinical [Medical Research Council (MRC)

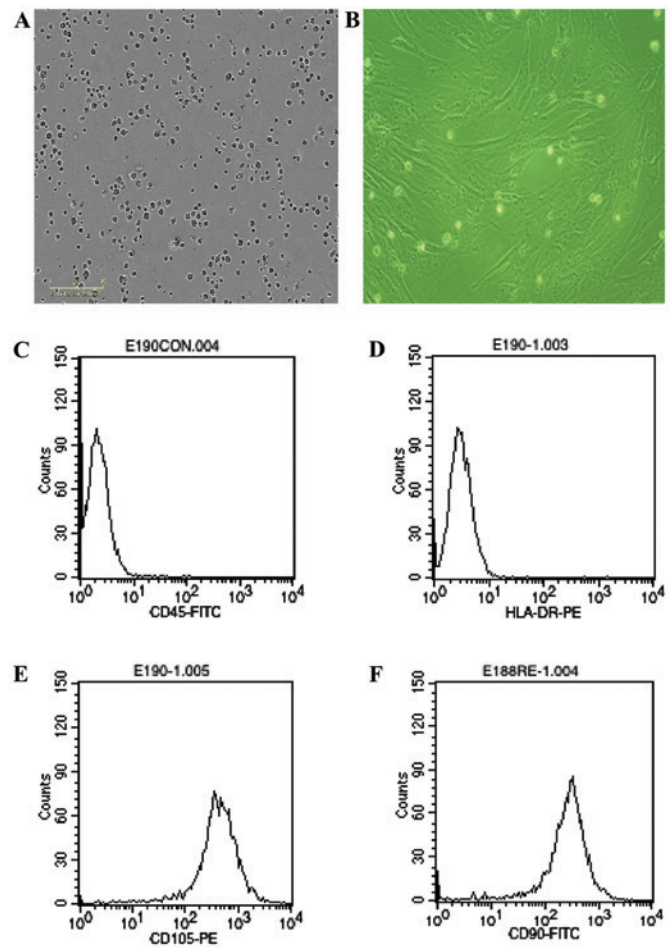


Figure 1. The characteristics of HUC-MSCs. (A) The cells derived from UC were observed at 24 h after they were seeded. (B) Fifth passage cells show typical fibroblast-shaped morphology. (C) Fifth passage cells were analysed for CD45 by flow cytometry. (D) Fifth passage cells were analysed for HLA-DR by flow cytometry. (E) Fifth passage cells were analysed for CD105 by flow cytometry. (F) Fifth passage cells were analysed for CD90 by flow cytometry. HUC-MSCs, human umbilical cord-derived mesenchymal stem cells.

dyspnea scale], ECG and monitoring of vital signs (temperature, oxygen saturation, respiratory and heart rate) were performed during the first 24 h after HUC-MSCs infusion. The patient was then discharged 24-h post-transplantation given that he was a febrile and hemodynamically stable, with no signs of infection or any type of allergic reaction.

ii) As exploratory secondary end-points we investigated whether stem cell infusion exerted any beneficial effects as assessed by clinical [modified MRC (mMRC) dyspnea scales functional (FVC, DL CO)], exercise capacity [six-minute walk test (6MWT)] and quality of life [St. George's Respiratory Questionnaire (SGRQ)] parameters, at baseline and at serial time-points (6 and 12 months post HUC-MSCs transplantation). Assessment of the disease extent and severity as reflected by chest HRCT at 6 and 12 months post-transplantation. The related parameters were supervised by an exercise physiologist.

**Pharmacological therapy protocol.** Our patient's pharmacological therapy consisted of: i) Oxygen therapy (shown above); ii) phosphodiesterase inhibitors: Doxofylline, 0.3 g, once daily, intravenous infusion; iii) antibacterial: Erythromycin, 0.9 g,

Table I. Cardiorespiratory and clinical tests before and after HUC-MSC transplantation in the IPF patient.

Test	Parameters	Before HUC-MSCs transplantation	Post-HUC-MSCs transplantation	
			6 months	12 months
Respiratory functional tests	FEV1/FVC	62.3%	70.5%	79.9%
Spirometry	FEV1	68.6% of predicted value	80.3% of predicted value	82.7% of predicted value
	FVC	63.7% of predicted value	73.3% of predicted value	75.6% of predicted value
DLCO	DLCO	46.3% of predicted value	63.1% of predicted value	78.6% of predicted value
Arterial blood gas analysis	PaO <sub>2</sub>	65.0 mmHg	76.0 mmHg	88.0 mmHg
	PaCO <sub>2</sub>	40.0	38.0	35.0
On oxygen 2.5 l/min	pH	7.3	7.4	7.4
mMRC		4.0	3.6	2.0
VAS		8.0	6.5	5.0
Borg scale		5.0	3.6	3.0
Transthoracic two-dimensional echocardiography	PAP	55 mmHg	47 mmHg	35 mmHg
Respiratory muscle strength	PiMax	40 mmHg	46 mmHg	53 mmHg
	PeMax	25 mmHg	48 mmHg	60 mmHg
6MWT		90 m <sup>a</sup>	175 m	210 m
Quality of life	Physical activities	60.7	77.6	87.6
SGRQ	Impact	70.4	57.3	32.6
	Total score	73.9	62.8	51.5
LTOT		Flow 2.0 l/min for 8 h	No need for oxygen	

<sup>a</sup>The 6MWT, before the retraining program, was stopped due to patient breathlessness. 6MWT, six-minute walk test; HUC-MSCs, human umbilical cord-derived mesenchymal stem cells; IPF, idiopathic pulmonary fibrosis; DLCO, diffusion lung capacity for carbon monoxide; FEV1, forced expiratory volume in one second; FVC, forced vital capacity; PaO<sub>2</sub>, partial arterial pressure of oxygen; PaCO<sub>2</sub>, partial pressure of carbon dioxide; mMRC, modified Medical Research Council; VAS, visual analogue scale; PAP, pulmonary artery pressure; PiMax, maximal inspiratory pressure; PeMax, maximal expiratory pressure; SGRQ, St. George's Respiratory Questionnaire; LTOT, long-term oxygen therapy.

once daily; and iv) improvement of microcirculation: Danshen, 20 ml once daily.

**Statistical analysis.** Statistical analysis was performed using SPSS 16.0 software (Chicago, IL, USA). Safety and exploratory efficacy secondary endpoints was observed for the patient against the baseline values. P<0.05 was considered to indicate a statistically significant difference.

**Results**

**Evaluation of HUC-MSCs.** The cells derived from umbilical cord were observed in 24 h after they were seeded (Fig. 1A), when part of the round mononuclear cells were adherent. Three days after inoculation, small colonies of the adherent cells with typical fibroblast-shaped morphology were obtained (Fig. 1B). The primary cells reached monolayer confluence after planting for 5-6 days, when passaged for the first time. Fifth passaged cells were analysis by flow cytometry, they were strongly positive for CD105 and CD90, but negative for CD45 and HLA-DR (Fig. 1C-F).

**Functional analysis.** The results of the evaluation by spirometry, achieved before and after the HUC-MSC transplantation.

The patient was with severe impairment of air flow at the basic line, and presented an increase in the forced expiratory volume in one second (FEV1) and FVC values, immediately after the procedure (Table I). The FEV1 values at the end of 12 months after the procedure were presented relative to maintenance. There was a marked decline in the FVC. The results of these two parameters determined an increase in the post-transplantation FEV1/FVC ratio, which increased from 62.3% in the pre-procedure period to 70.5 and 79.9% in the following 6 and 12 months, respectively. Thus, the isolated observation of these values shows a close relation to the normal predicted values of FEV1/FVC (>0.70 post-transplantation). The FVC was reduced by median 175 and 210 ml at 6 and 12 months, respectively, before returning to baseline (Table I). The diffusing capacity and 6MWD remained stable at 6 and 12 month time-points, with a transient improvement in 6MWD at 3 months (Table I).

The arterial blood gas analysis showed a pO<sub>2</sub> increase of 11% and pCO<sub>2</sub> decrease of 5.6% on oxygen with a flow of 2.0 l/min in three days. The LTOT reduced to a flow of 1.5 l/min for 24 h to compensate hypoxemia. The oxygen requirement reduction observed may have been due to the strengthening of his respiratory muscles, which allowed improvement of his exercise capacity. Oxygen was not

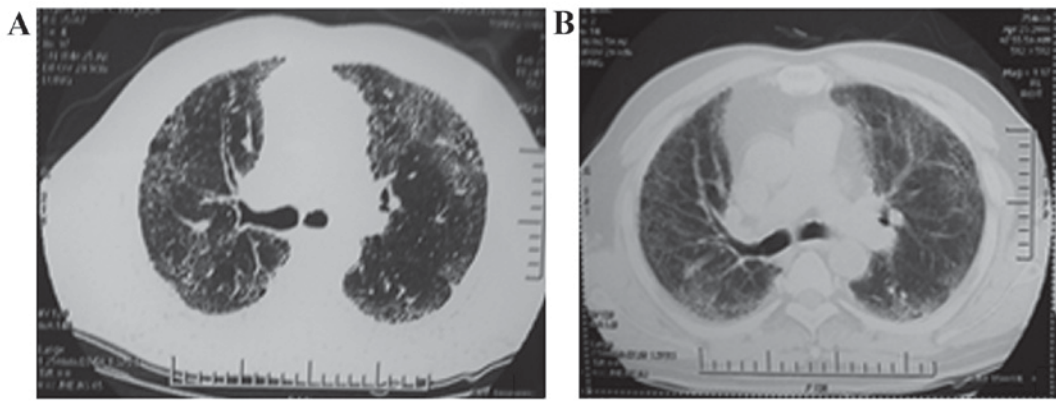


Figure 2. Radiological scan. (A) Radiological scan before HUC-MSC treatment. (B) Radiological scan post HUC-MSC treatment at the end of 12 months. HUC-MSCs, human umbilical cord-derived mesenchymal stem cells.

required at the end of 2 months. The pulmonary artery systolic pressure, estimated by transthoracic two-dimensional echocardiography, improved by 9.3% in terms of cardiac index and pulmonary vascular resistance. The 6MWT showed an increase of distance walked by 144.4% at the end of 12 months post-transplantation. There was a marginal improvement in DLCO (46.3 vs. 63.1%; 78.6% of predicted value) and fibrosis score (9.8 vs. 4.6%) at the end of 6 and 12 months. The dyspnea scores were reduced, the level of dyspnea at rest (the mMRC dyspnea scale) decreased from 3.0 to 1.5, Borg scale during exercise was reduced from 5.0 to 3.0, and his post-exercise visual analogue scale decreased from 8.0 to 5.0; there was an increase in maximal inspiratory pressure of 32.2%. In addition, the patient was in good clinical condition and increased scores in indicators of quality of life, namely SGRQ scoring values ( $70.4 \pm 3.6$  vs.  $57.3 \pm 2.9$ , and  $32.6 \pm 3.1$ ,  $P < 0.05$ , respectively), both after 6 and 12 months, were noted (Table I). Finally, our results showed a trend towards increase in systolic pulmonary arterial pressure (sPAP) at 6 and 12 months post-infusion. Demographic and baseline patient data are listed in Table I.

**Radiological analysis.** The chest HRCT scan showed (Fig. 2), there were multiple 'harder' patchy, peripheral, subpleural, and bibasilar reticular opacities observed before HUC-MSCs. These images evolved into subpleural multiple 'softer' ground-glass opacity at the end of 12 months post-HUC-MSC transplantation, while alveolitis and fibrosis were greatly reduced by HUC-MSC treatment.

**Safety outcomes.** No serious or clinically significant side effects were observed during the entire study period. As shown in Table I, there were no side effects of minor or medium severity, including allergic reactions, liver or renal abnormalities, and oxygen desaturations, cardiac abnormalities such as ECG or heart rate changes in 12 months.

## Discussion

This case reported the safety and efficacy of HUC-MSCs to treat IPF in 12 months follow-up duration. No adverse events were observed, and at 12 months post-infusion, lung function, 6MWD and CT fibrosis score were all increased from base-

line. Our data provided significant evidence for the long-term safety of the cell therapy approach in at least moderate fibrotic lung disease, and provided exciting and novel insights into lung regeneration.

IPF is a refractory and lethal form of pulmonary fibrosis characterized by fibroblast proliferation, extracellular matrix deposition, and progressive lung scarring. With respect to HUC-MSC therapy in IPF, our concerns focused on delaying or reversing the process of lung fibrosis. As shown in Fig. 2, the fibrosis area was decreased in 12 months post-transplantation. Moreover, lung function and CT scores were increased at the 12 month duration. Therefore, our data show HUC-MSCs intravenous infusion was safe and beneficial in IPF. In our previously studies (10-12), we investigated the safety and efficacy of HUC-MSCs in rat liver fibrosis (13), which reduced in 8 weeks post-translation. Taken together, our data suggest HUC-MSCs are capable of attenuating fibrotic process.

Some studies of cell therapy for IPF have shown different efficacy on IPF. Liu *et al* showed that MSCs protects against bleomycin-induced liver injury and reduced fibrosis (14); Ortiz *et al* reported intravenous MSC derived from placenta to treat IPF is feasible and has a good short-term safety profile in patients with moderately severe IPF, while the efficacy of this kind of treatment was not visibly (15). Other studies also confirmed the safety of MSC therapy for IPF, however, the efficacy of IPF was not obvious (16,17). For these experimental results, we assume the reasons were: i) Different cell source, i.e., although MSCs share some identical phenotype, and meet the criterion of the International Society for Cell Therapy (18,19), they have different characteristics from each other. ii) The patients enrolled were different. iii) Different auxiliary treatment accompanied with the MSC treatment. iv) Improvement in the micro-environment of IPF at the same time. Therefore, we suggested choosing different sources of MSCs to treat diseases according to the specific condition of different patient. Future studies will need to be designed to confirm safety and efficacy over an even longer period, particularly if different doses are employed.

In this case study, we elected to utilize HUC-MSCs due to the convenience of isolating and propagating cells in significant numbers relatively cheaply and easily from this tissue source. Clinically relevant improvements and short-term

benefits were clearly demonstrated as a result of HUC-MSC transplantation. In particular, we emphasized the improvement of microcirculation in this treatment regimens. Future large-scale trials are likely to be designed using cells from a similar source.

### Acknowledgements

The present study was supported by the National High Technology Research and Development Program (863 Program), nos. 2011AA020101 and 2012AA020905.

### References

1. Wuyts WA, Agostini C, Antoniou KM, Bouros D, Chambers RC, Cottin V, Egan JJ, Lambrecht BN, Lories R, Parfrey H, *et al*: The pathogenesis of pulmonary fibrosis: a moving target. *Eur Respir J* 41: 1207-1218, 2013.
2. Raghu G, Collard HR, Egan JJ, Martinez FJ, Behr J, Brown KK, Colby TV, Cordier JF, Flaherty KR, Lasky JA, *et al*: ATS/ERS/JRS/ALAT Committee on Idiopathic Pulmonary Fibrosis: An official ATS/ERS/JRS/ALAT statement: idiopathic pulmonary fibrosis: evidence-based guidelines for diagnosis and management. *Am J Respir Crit Care Med* 183: 788-824, 2011.
3. Raghu G, Weycker D, Edelsberg J, Bradford WZ and Oster G: Incidence and prevalence of idiopathic pulmonary fibrosis. *Am J Respir Crit Care Med* 174: 810-816, 2006.
4. Weiss DJ, Bertonecello I, Borok Z, Kim C, Panoskaltis-Mortari A, Reynolds S, Rojas M, Stripp B, Warburton D and Prockop DJ: Stem cells and cell therapies in lung biology and lung diseases. *Proc Am Thorac Soc* 8: 223-272, 2011.
5. Bailey MM, Wang L, Bode CJ, Mitchell KE and Detamore MS: A comparison of human umbilical cord matrix stem cells and temporomandibular joint condylar chondrocytes for tissue engineering temporomandibular joint condylar cartilage. *Tissue Eng* 13: 2003-2010, 2007.
6. Conconi MT, Burra P, Di Liddo R, Calore C, Turetta M, Bellini S, Bo P, Nussdorfer GG and Parnigotto PP: CD105(+) cells from Wharton's jelly show *in vitro* and *in vivo* myogenic differentiative potential. *Int J Mol Med* 18: 1089-1096, 2006.
7. Lindenmair A, Hatlapatka T, Kollwig G, Hennerbichler S, Gabriel C, Wolbank S, Redl H and Kasper C: Mesenchymal stem or stromal cells from amnion and umbilical cord tissue and their potential for clinical applications. *Cells* 1: 1061-1088, 2012.
8. Avanzini MA, Bernardo ME, Cometa AM, Perotti C, Zaffaroni N, Novara F, Visai L, Moretta A, Del Fante C, Villa R, *et al*: Generation of mesenchymal stromal cells in the presence of platelet lysate: a phenotypic and functional comparison of umbilical cord blood- and bone marrow-derived progenitors. *Haematologica* 94: 1649-1660, 2009.
9. Divya MS, Roshin GE, Divya TS, Rasheed VA, Santhoshkumar TR, Elizabeth KE, James J and Pillai RM: Umbilical cord blood-derived mesenchymal stem cells consist of a unique population of progenitors co-expressing mesenchymal stem cell and neuronal markers capable of instantaneous neuronal differentiation. *Stem Cell Res Ther* 3: 57, 2012.
10. Qu Z, Guo S, Fang G, Cui Z and Liu Y: AKT pathway affects bone regeneration in nonunion treated with umbilical cord-derived mesenchymal stem cells. *Cell Biochem Biophys* 71: 1543-1551, 2015.
11. Qu Z, Guo L, Fang G, Cui Z, Guo S and Liu Y: Biological characteristics and effect of human umbilical cord mesenchymal stem cells (hUC-MSCs) grafting with blood plasma on bone regeneration in rats. *Cell Biochem Biophys* 63: 171-181, 2012.
12. Qu Z, Fang G, Cui Z and Liu Y: Cell therapy for bone nonunion: a retrospective study. *Minerva Med* 106: 315-321, 2015.
13. Tzouveleakis A, Paspaliaris V, Koliakos G, Ntoliou P, Bouros E, Oikonomou A, Zissimopoulos A, Boussios N, Dardzinski B, Gritzalis D, *et al*: A prospective, non-randomized, no placebo-controlled, phase Ib clinical trial to study the safety of the adipose derived stromal cells-stromal vascular fraction in idiopathic pulmonary fibrosis. *J Transl Med* 11: 171, 2013.
14. Liu Y, Shi ZL and Zhao Z: Transplantation of human umbilical cord-derived mesenchymal stem cells improves hepatic fibrosis in rats with carbon tetrachloride-induced hepatic cirrhosis. *Chinese Tissue Engineering Res* 16: 1837-1840, 2012 (In Chinese). [http://d.g.wanfangdata.com.cn/Periodical\\_xdkf201210028.aspx](http://d.g.wanfangdata.com.cn/Periodical_xdkf201210028.aspx)
15. Ortiz LA, Dutreil M, Fattman C, Pandey AC, Torres G, Go K and Phinney DG: Interleukin 1 receptor antagonist mediates the anti-inflammatory and antifibrotic effect of mesenchymal stem cells during lung injury. *Proc Natl Acad Sci USA* 104: 11002-11007, 2007.
16. Chambers DC, Enever D, Ilic N, Sparks L, Whitelaw K, Ayres J, Yerkovich ST, Khalil D, Atkinson KM and Hopkins PM: A phase Ib study of placenta-derived mesenchymal stromal cells in patients with idiopathic pulmonary fibrosis. *Respirology* 19: 1013-1018, 2014.
17. Weiss DJ, Casaburi R, Flannery R, LeRoux-Williams M and Tashkin DP: A placebo-controlled, randomized trial of mesenchymal stem cells in COPD. *Chest* 143: 1590-1598, 2013.
18. Toonkel RL, Hare JM, Matthay MA and Glassberg MK: Potential for Clinical Testing: Mesenchymal stem cells and idiopathic pulmonary fibrosis. Potential for clinical testing. *Am J Respir Crit Care Med* 188: 133-140, 2013.
19. Dominici M, Le Blanc K, Mueller I, Slaper-Cortenbach I, Marini F, Krause D, Deans R, Keating A, Prockop DJ and Horwitz E: Minimal criteria for defining multipotent mesenchymal stromal cells. The International Society for Cellular Therapy position statement. *Cytotherapy* 8: 315-317, 2006.