

Application of vibration response imaging technology in patients with community-acquired pneumonia before and after the treatment

HONGYING JIANG^{1*}, JICHAO CHEN^{2,3*}, JINYING CAO^{2,3}, LAN MU^{2,3}, ZHENYU HU^{2,3} and JIAN HE^{2,3}

¹Department of Respiratory Rehabilitation Center, Beijing Rehabilitation Hospital of Capital Medical University, Beijing 100014; ²Department of Respiratory Medicine, Aerospace Center Hospital; ³Aerospace Clinical Medical College of Peking University, Peking University, Beijing 100049, P.R. China

Received July 1, 2016; Accepted February 16, 2017

DOI: 10.3892/etm.2017.4419

Abstract. The value of vibration response imaging (VRI) technology in patients with community-acquired pneumonia (CAP) was assessed. The VRI images of 62 cases of CAP patients with normal lung functions before and after treatment were observed and the changes in images before and after treatment were compared. The maximum vibration energy value of CAP patients was 1.64 ± 0.32 , patients with unsmoothed vibration energy curve accounted for 88.71%, 41 cases (66.12%) had unordered dynamic images, 56 cases (90.32%) jumping images, 54 cases (87.10%) desynchrony, 58 cases (93.55%) delay and 52 cases (83.87%) showed contrary events. The maximum vibration energy value after treatment was 1.59 ± 0.29 and the difference was not statistically significant ($P=0.93$). Patients with unsmoothed vibration energy curve accounted for 20.97%, 11 cases (17.74%) appeared as unordered dynamic images, 28 cases (45.16%) of jumping images, 21 cases (33.87%) desynchrony, 18 cases (29.03%) delay and 10 cases (16.13%) with contrary events. The differences of these symptoms before and after treatment were statistically significant. The image scores of CAP patients before treatment were 10.33 ± 1.95 , higher ($P < 0.001$) than after treatment (3.49 ± 2.29). In conclusion, the changes of VRI images of CAP patients are relatively obvious and this technology can be used for the evaluation of CAP curative effects.

Introduction

Community-acquired pneumonia (CAP) refers to infectious lung parenchyma including alveolar wall, namely pulmonary interstitium in general, suffered by non-patients, or inflammation including pneumonia, that has pathogen infection with a specific incubation period and occurs within an incubation period after admission. As one of the common infectious diseases that negatively impact human health, it ranks 6th as a cause of mortality in the US and 1st for infectious diseases (1).

Patients with signs and symptoms of respiratory tract infection and chest X-ray examination have a sheet-like, patchy invasive shadow, able to be diagnosed as CAP. In addition to the improvement of body temperature and respiratory symptoms, the determination of therapeutic effects of CAP patients after treatment also depends on radioactive X-ray examination, especially for severe pneumonia, which may need X-ray examination to evaluate the patient condition each day. However, X-ray examination has certain limitations due to problems caused by radiation such as carcinogenesis (2). Through the information of vibration changes of different tissues in the process of lung gas flow collected by a special sensor, and digital processing by computer software, the vibration response imaging (VRI) lung breathing imaging diagnostic system transforms into dynamic lung functional images that are visible and different quantitative data, without trauma and radiation, which can be detected repeatedly (3).

The present study preliminarily investigated the value of application of VRI in the evaluation of therapeutic effects of CAP patients. This was conducted by comparing and analyzing the VRI images of CAP patients before and after treatment.

Subjects and methods

Research subjects

Inclusion criteria. The study protocol was approved by the Ethics Committee of Aerospace Center Hospital (Beijing, China) and all patients included in the research signed the informed consent form. Sixty-two cases of CAP patients admitted to the Department of Pneumology of the Aerospace

Correspondence to: Dr Hongying Jiang, Department of Respiratory Rehabilitation Center, Beijing Rehabilitation Hospital of Capital Medical University, Xixiazhuang, Baduchou, Shijingshan, Beijing 100014, P.R. China
E-mail: hongying_jiang1@163.com

*Contributed equally

Key words: vibration response imaging, community-acquired pneumonia, dynamic images

Center Hospital from September 2011 to October 2012 were included in this study. Inclusion criteria were: i) Subjects that had the reading and comprehension ability and voluntarily signed an informed consent form; ii) those who complied with the Guidelines for the Diagnosis and Treatment of Community-acquired Pneumonia formulated by the Chinese Thoracic Society (4); iii) no cardiac failure; and iv) normal pulmonary ventilation function forced expiratory volume at the first second (FEV₁)/forced vital capacity (FVC) >70%, percentage of FEV₁ to predicting value (FEV₁ Pred) >80%.

Exclusion criteria were: i) Severe pneumonia; ii) factors that could affect the placement of sensor, including hirsutism, thoracic spinal deformity, injuries of back skin; iii) females in gestation period or lactation period; iv) those who had installed pacemaker or implantable defibrillator; and v) those who failed to comply with the inclusion criteria.

Research methods

Test steps. The study was conducted according to the following steps: i) Inquiring history of present illness and previous history; ii) physical examination focused on lung; iii) chest CT examination; iv) VRI examination; v) pulmonary ventilation function examination; vi) anti-infection and symptomatic treatment; and vii) VRI re-examination within 7-10 days after treatment.

Equipment. This study applied the VRI equipment and VRIxp lung breathing imaging diagnosis system manufactured by Deep Breeze Ltd. (Or-Akiva, Israel).

VRI operating procedures. In case of testing, the environment was kept quiet. The subject took the seat, relaxed, faced the VRIxp, topless, opened mouth slightly and breathed naturally. Two V-array sensors were posted on the back of the patient in the order from right to left, paralleled to spin, 1.5 cm higher than mesoscapula and 5 cm to spin for the two sides. The recording key was pressed and gestures were used to guide subjects to finish 3-5 respiratory cycles with 12 sec. After the completion of recording, the system releases vacuum automatically. VRI image acquisition of all the subjects was finished by the same technician.

Methods of image analysis. Images of inspiratory and expiratory phases within 12 sec were observed. Analysis was conducted by three trained specialized analysts. In case of any inconsistency in the process of analysis, consensus was eventually obtained through joint consultation. Observation indexes are as follows:

i) Vibration energy curve chart: Normal vibration energy curve had a smooth appearance and was continuously in a parabolic shape. It increased at the time of inspiration and was reduced after reaching the peak value. In general, it included 3-5 cycles and each cycle was similar, without obvious changes. Curve abnormalities included dissimilarity, steep inspiration, peak, platform, step, low and flat expiratory phase, single peak and saw-tooth, with one score for one abnormal sign.

ii) Max energy frame (MEF): The appearance of normal MEF was like the profile of double lungs and had smooth edge, unbalanced energy distribution and basically vertical C-line. Abnormal MEF included the appearance of puff, defect and unsmoothed edge, asymmetry of both sides, several unevenly distributed energy group and curved C-line, with one score for one abnormal sign.

iii) Dynamic images: Under normal circumstances, images moved in order, dynamic energy images appeared from up to down, from inside to outside and disappeared from down to up and from outside to inside, and the dynamic images of both lungs appeared simultaneously. The phenomenon of rapid and discontinuous movement appearing in energy center was known as bouncy feeling, scoring according to no bouncy feeling (0 score), mild (1 score), moderate (2 scores) and severe (3 scores). The abnormalities of image movement included disorder, desynchrony of occurrence and development, delay, contrary advantages, gas residual at the end of expiration and other signs, with one score for one type. Image scores included vibration energy curve chart, MEF abnormalities and abnormalities of dynamic images.

iv) Quantitative lung data (QLD) value: Read by machine.

v) Rhonchi and moist rales: Rhonchi and moist rales should not occur under normal circumstances. If any, whether it was consistent with auscultation should be investigated.

Statistical analysis. Statistical analysis was conducted by applying SPSS 16.0 statistical software (Chicago, IL, USA). Data are expressed as mean \pm SD. Paired t-test was applied for inter-group analysis and the comparison of ratio was detected with χ^2 . $P < 0.05$ was considered to indicate a statistically significant difference.

Results

General conditions. A total of 62 cases of CAP patients complied with inclusion criteria and participated in the present study. The cases included 34 cases of males and 28 cases of females, aged 43.12 ± 13.64 years. There were 29 cases of right pneumonia, 27 cases of left pneumonia and 6 cases of bilateral pneumonia.

VRI examination results. The maximum vibration energy value of CAP patients before treatment was 1.64 ± 0.32 and that after treatment was 1.59 ± 0.29 . The difference was not statistically significant. The patients with unsmoothed VRI vibration energy curve before and after treatment as well as the disorder, bounce, desynchrony, delay and contrary events occurring in dynamic images had significant changes and the differences were statistically significant (Table I and Fig. 1). The image scores of CAP patients before treatment were 10.33 ± 1.95 , which was obviously higher than that after treatment, namely 3.49 ± 2.29 , ($P < 0.001$) (Fig. 2).

Rhonchi and moist rales. Rhonchi and moist rales were found in 51 persons by applying auscultation or VRI machine before and after treatment, with the auscultation conformity of 0.94 (58/62). Among 4 persons who had inconformity between auscultation and machine monitoring, the moist rales were accessible to auscultation for 1 person which could not be monitored by machine. The 3 remaining persons could not be monitored by human ear, but were monitored by the machine.

Discussion

Imaging methods play a very important role in the diagnosis of diseases of respiratory system and the evaluation of therapeutic

Table I. Comparison of VRI results of CAP patients before and after treatment.

Groups	Cases	Maximum vibration energy value	Cases with unsmoothed vibration energy curve (%)	Cases of disorder (%)	Cases of bouncy feeling (%)	Cases of desynchrony (%)	Cases of delay (%)	Cases of contrary advantaged (%)	Image scores
Before treatment	63	1.64±0.32	55 (88.71)	41 (66.12)	56 (90.32)	54 (87.10)	58 (93.55)	52 (83.87)	10.33±1.95
After treatment	63	1.59±0.29	13 (20.97)	11 (17.74)	28 (45.16)	21 (33.87)	18 (29.03)	10 (16.13)	3.49±2.29
P-value		0.93	<0.001 ^a	<0.001 ^a	<0.001 ^a	<0.001 ^a	<0.001 ^a	<0.001 ^a	P<0.001 ^a

^aDifferences between the results of VRI examination of the two groups were statistically significant. VRI, vibration response imaging; CAP, community-acquired pneumonia.

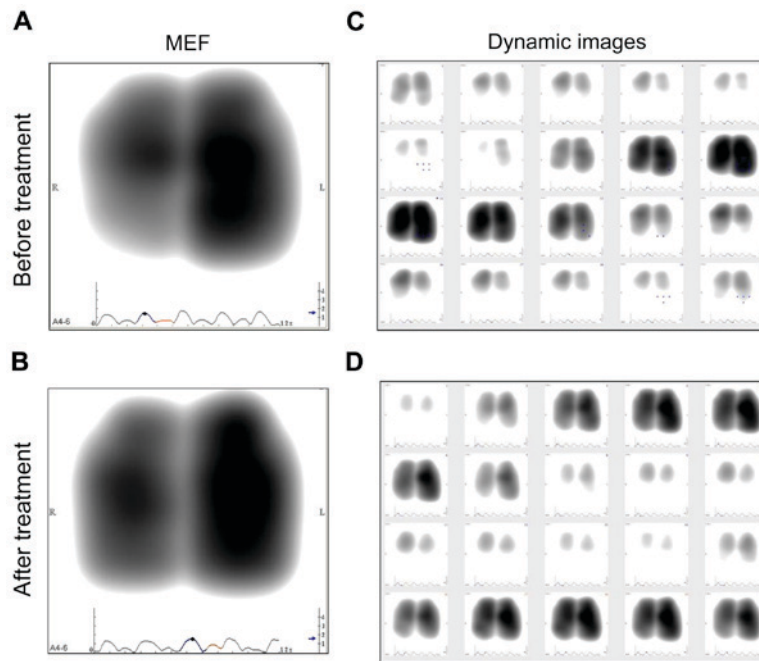


Figure 1. Changes of MEF and dynamic images of CAP patients before and after treatment. (A) MEF deficiency before treatment; (B) basically normal MEF after treatment; (C) disorder, desynchrony and contrary events (left lung dominated in inspiratory phase, right lung dominated in expiratory phase, and the alternation of double lungs increased) of dynamic images before treatment, and moist rales were collected at left lower lobe; (D) after treatment, disorder, desynchrony and contrary events of both dynamic images disappeared and the moist rales disappeared. MEF, max energy frame; CAP, community-acquired pneumonia.

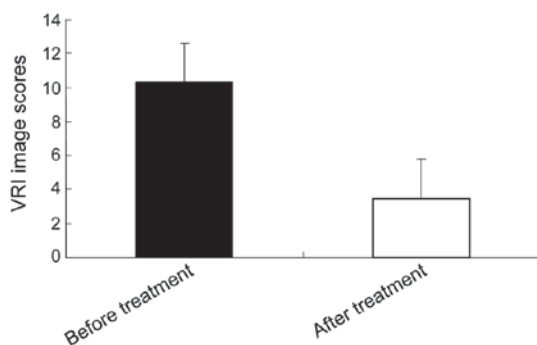


Figure 2. Scores of VRI images of CAP patients before and after treatment. VRI, vibration response imaging; CAP, community-acquired pneumonia.

effects. However, due to radiation problem, X-ray, cannot be used for special populations, including pregnant women,

and cannot conduct examination repeatedly. Moreover, CT examination cannot be operated at the bedside because of the large equipment. Although ultrasonic examination has no radiation, its application is limited because lung is tissue with gas and has weak echo. As a new means of examination, VRI technology provides information of gas flow moved in lung and the relationship between gas flow and the generated vibration energy, directly reflecting the function situations of the lungs. It is easy to operate and only needs patients to breathe naturally. It is easy to cooperate and can be conducted at the bedside, without radiation. It has wide prospect in clinical application. Previous studies were focused on the characteristics of VRI images of healthy populations and evaluation of equipment performance and pneumonectomy and mechanical ventilation were mainly involved for diseases (5-8), were mainly on airflow limited diseases (8,9). However, there were few literature reports that applied this technology in infectious diseases of the lungs.

CAP is the common disease and frequently-occurring disease of respiratory system. According to the statistics, there were ~6.5-15 million persons suffering from CAP each year, among which over 200,000 persons died of CAP. All guidelines on CAP mentioned that imaging examination was the main examination means of CAP diagnosis and evaluation of therapeutic effects (10-12). At present, there are a few reports on the studies on the application of VRI technology in CAP patients. The studies of Bartzioakas *et al* (13) included 23 cases of CAP patients and 20 cases of healthy volunteers. Six respiratory physicians conducted blind analysis for the differences of VRI images of the two groups, comparing the consistency of MEF and chest radiograph. They concluded that VRI, the new technology without radiation could be used for the diagnosis and follow-up of pneumonia, especially for patients with pulmonary consolidation or pulmonary atelectasis. However, among the 23 cases of CAP patients involved in this study, 20 cases also had chronic obstructive pulmonary diseases and 5 cases congestive heart-failure. Although they were in the stable period, they would have had certain effects on VRI images. Moreover, the chest radiograph was used as control for questions of a part of the study. For instance, it was unable to differentiate whether it was an artifact and it was not specified by lung CT. Therefore, the cases involved in our study were all patients without cardiac failure. Moreover, forced expiratory volume at the first second (FEV_1)/FVC <70%, percentage of FEV_1 to predicting value (FEV_1 Pred) <80% were added as exclusion criteria. Before treatment, CT was selected as control so as to improve the accuracy of comparison.

Vibration energy curve represents the respiratory cycles recorded by VRI, which are displayed on the lower part of dynamic image. By default, the system can select a respiratory cycle automatically (form the whole 12 sec record), namely displaying an inspiratory phase and expiratory phase. Normal VRI vibration energy curve has smooth shape and is continuous without burrs. All the respiratory cycles are similar. The findings of the present study showed that before treatment, most of the vibration energy curves of CAP patients were not smooth, with platform, depression and low and flat expiratory phase. It was considered that inflammation caused the increase of secreta in gas channel, which led to airway stenosis at inflammation site and unsmooth airflow, thus generating vibration energy with discontinuous changes and show unsmooth curve. After anti-infective treatment, inflammation was improved, secreta reduced, airway stenosis cleared, airflow passed smoothly, and vibration energy curve recovered to smoothness.

MEF represents the frame with the highest vibration intensity. Normally, it was in the shape of double lungs with smooth edge and balanced energy distribution. For CAP patients, deficiencies were found in the MEF of VRI images of pulmonary consolidation part. It was considered that the exudation of local fibrin of pulmonary consolidation increased and no gas entered or exited. After treatment and improvement, pathogenic bacteria were swallowed and dissolved by macrophages and neutrophilic granulocytes appeared by degeneration and necrosis and released a large amount of proteolytic enzyme so as to dissolve the exuded fibrin gradually and re-inflating pulmonary alveoli. Airflow began to go in and out and lung tissues returned to normal structure and

functions. Simultaneously, MEF returned to basic normal, as shown in Fig. 1A and B. This characteristic was consistent with that of previous studies (5-7).

Rale is adventitious sound beyond the normal breathing sound. VRI applied bandwidth filtering technology to objectively detect the occurrence time and position of rhonchi and moist rales. The conformity degree of moist rale detection between VRI and auscultation was 0.94, thus highly sensitive. The QLD value is quantitative data of lung and reflects vibration intensity of different lung fields and the vibration balance of the lungs. The moist rales are caused by the turbulent flow formed by gas passing through the tenuous secretion in airway, so the QLD value decreases in the position with moist rales. In the present study, moist rales were found in one case of CAP patient and CT showed left pneumonia. In case of conducting VRI examination, moist rales were found in left side and QLD value of left side decreased. Moreover, it was found that the grayscale of right side decreased, QLD value of right side increased, and no moist rales were found in the right lung. On the third day after examination, moist rales were found in the right lung and the QLD value of right side decreased through re-examination of VRI. It was found in the re-examination of chest radiograph that the right lung had exudation shadow, which indicated bilateral pneumonia. Therefore, the changes in lung structure and functions reflected by VRI were earlier than clinical manifestations, which was helpful to guide clinic and adjust therapeutic schedule early.

Moreover, our study compared the characteristics of VRI images of patients with CAP before and after treatment and obvious changes could also be found in dynamic images. Before treatment, the bouncy feeling in VRI dynamic images strengthened and the occurrence and development of images were disordered and delayed with contrary events, which meant that one side of lung dominated in case of inspiratory phase, while the other side of lung dominated in case of expiratory phase, and the alternation of double lungs increased. The reasons considered were that blood capillary of the inflammation site expanded, exudation in alveolar intracavity increased, and the different degrees of airflow going in and out formed turbulent flow. However, after treatment and improvement, the occurrence and development of images became relatively synchronous and orderly. Bouncy feeling of images were relieved obviously and the contrary events disappeared, as shown in Fig. 1C and D.

In conclusion, the above-mentioned observation indexes, including vibration energy curve chart and abnormalities of MEF and dynamic images, were image scores of quantitative observation indexes of our study. Obvious changes were found before and after treatment and the differences had statistical significance (Fig. 2).

As a new lung imaging system, VRI technology was easy to operate, without radiation, and can be conducted at the bedside. All patients in our study successfully finished the examinations before and after treatment. The changes of VRI images of patients with CAP before and after treatment were obvious and this technology can be used for the follow-up of CAP. However, most of the patients in the current study were effectively treated without disease deterioration or severe pneumonia. Therefore, we need to expand the number of cases, conduct multicenter and prospective control study

and increase reliable quantitative indexes in order to make an objective evaluation.

Acknowledgements

This study was supported by the Medical and Health Research Projects of the China Aerospace Science and Industry Group, Ltd. (JKBZ-001).

References

1. Armitage K and Woodhead M: New guidelines for the management of adult community-acquired pneumonia. *Curr Opin Infect Dis* 20: 170-176, 2007.
2. Xiao X, Zuo X, Davis AA, McMillan DR, Curry BB, Richardson JA and Benjamin IJ: HSF1 is required for extra-embryonic development, postnatal growth and protection during inflammatory responses in mice. *EMBO J* 18: 5943-5952, 1999.
3. Dellinger RP, Parrillo JE, Kushnir A, Rossi M and Kushnir I: Dynamic visualization of lung sounds with a vibration response device: a case series. *Respiration* 75: 60-72, 2008.
4. Chinese Thoracic Society: Guidelines for the diagnosis and treatment of community-acquired pneumonia (revised version in 2006). *Chinese J Tuberculosis Respiratory Diseases* 29: 651-655, 2006 (In Chinese).
5. Jimenez U, Marina N, de Santamaria EL, Pac JJ and Galdiz JB: Evaluation of the utility of vibration response imaging device and Operation Planning Software in the assessment of patients before lung resection surgery. *Eur J Cardiothorac Surg* 37: 1185-1190, 2010.
6. Comce F, Bingol Z, Kiyani E, Tanju S, Tokar A, Cagatay P and Ece T: Vibration-response imaging versus quantitative perfusion scintigraphy in the selection of patients for lung-resection surgery. *Respir Care* 56: 1936-1941, 2011.
7. Yosef M, Langer R, Lev S and Glickman YA: Effect of airflow rate on vibration response imaging in normal lungs. *Open Respir Med J* 3: 116-122, 2009.
8. Yan T, Sun L and Yun L: Relationship between vibration response imaging and lung function test in patients with chronic obstructive pulmonary disease. *Int J Respiration* 31: 339-342, 2011 (In Chinese).
9. Li J and Cai BQ: Characteristics of vibration response imaging in chronic obstructive pulmonary disease. *Zhongguo Yi Xue Ke Xue Yuan Xue Bao* 31: 335-338, 2009 (In Chinese).
10. Woodhead M: New guidelines for the management of adult lower respiratory tract infections. *Eur Respir J* 38: 1250-1251, 2011.
11. Miyashita N, Matsushima T and Oka M; Japanese Respiratory Society: The JRS guidelines for the management of community-acquired pneumonia in adults: an update and new recommendations. *Intern Med* 45: 419-428, 2006.
12. Hedlund J, Strålin K, Ortqvist A and Holmberg H; Community-Acquired Pneumonia Working Group of the Swedish Society of Infectious Diseases: Swedish guidelines for the management of community-acquired pneumonia in immunocompetent adults. *Scand J Infect Dis* 37: 791-805, 2005.
13. Bartziokas K, Daenas C, Preau S, Zygoulis P, Triantaris A, Kerenidi T, Makris D, Gourgoulis KI and Daniil Z: Vibration response imaging: evaluation of rater agreement in healthy subjects and subjects with pneumonia. *BMC Med Imaging* 10: 6, 2010.