

Dasatinib and chemotherapy in a patient with early T-cell precursor acute lymphoblastic leukemia and *NUP214-ABL1* fusion: A case report

YAN CHEN^{1*}, LI ZHANG^{2*}, JIANKUN HUANG³, XIULI HONG¹,
JIANGNING ZHAO¹, ZHAO WANG¹ and KEJIE ZHANG¹

¹Department of Hematology, Zhongshan Hospital, Xiamen University, Xiamen, Fujian 361004;

²Department of Hematology, West China Hospital, Sichuan University, Chengdu, Sichuan 610041;

³Central Laboratory, Zhongshan Hospital, Xiamen University, Xiamen, Fujian 361004, P.R. China

Received February 26, 2016; Accepted March 23, 2017

DOI: 10.3892/etm.2017.5046

Abstract. The present study aimed to evaluate the therapeutic efficacy of dasatinib in a patient with nucleoporin 214-tyrosine protein kinase ABL1 proto-oncogene 1 (*NUP214-ABL1*)-positive early T-cell precursor-acute lymphoblastic leukemia (ETP-ALL), as well as that of selinexor and dasatinib for *NUP214-ABL1*-positive ETP-ALL *in vitro*. ETP leukemia is a form of T-cell ALL (T-ALL) with poor prognosis. The *NUP214-ABL1* gene is present in ~6% of T-ALL cases, however the prevalence of *NUP214-ABL1* gene expression in ETP-ALL in particular has not yet been verified. The current study reports the rare case of a 29-year-old man with ETP-ALL harboring the *NUP214-ABL1* fusion gene, presenting with low-grade fever, stomachache and splenomegaly. The patient was successfully treated with dasatinib and vincristine, idarubicin, cyclophosphamide and prednisone (VICP) chemotherapy. The therapeutic efficacy of selinexor and dasatinib was also evaluated *in vitro*. Apoptosis was analyzed using Annexin V/propidium iodide staining and flow cytometry, and poly ADP-ribose polymerase (PARP) cleavage was detected using western blot analysis. The results demonstrated that the apoptotic cell population significantly increased following selinexor or dasatinib treatment compared with the control ($P < 0.05$). Furthermore, combined selinexor and dasatinib treatment led to a significant increase in cell apoptosis compared with either treatment alone ($P < 0.05$). The apoptosis results

were confirmed by PARP cleavage. Thus, *NUP214-ABL1* fusion gene expression should be tested in T-ALL, including ETP-ALL. Dasatinib used in combination with traditional induction chemotherapy may reverse the high induction failure of ETP-ALL with *NUP214-ABL1* fusion gene; however, further prospective studies are required to confirm this. Therefore, selinexor with or without dasatinib may serve as a potential salvage therapy in the case of relapse and may be developed as a novel treatment for ETP-ALL with the *NUP214-ABL1* fusion gene.

Introduction

Early T-cell precursor-acute lymphoblastic leukemia (ETP-ALL) has been identified as a distinct biological subtype of T-cell lineage ALL (T-ALL), which accounts for 15% of T-ALL cases (and ~2% of ALL cases). It is associated with poor clinical outcomes even following the use of current treatment regimens. Recently, the complete remission rate/complete remission with incomplete platelet recovery rate in patients with ETP-ALL was indicated to be significantly lower than that of non-ETP-ALL patients (73 vs. 91%; $P = 0.03$) in 2016 (1). Up to the last follow up, the median overall survival for patients with ETP-ALL was 20 months vs. not yet reached for the non-ETP-ALL/LBL patients ($P = 0.008$) (1). This subtype is characterized by a lack of expression of the T-cell surface markers cluster of differentiation (CD) 1a and CD8, weak or absent expression of CD5, and aberrant expression of at least one of the following myeloid or hematopoietic stem cell markers: CD13, CD33, CD34, CD117, human leukocyte antigen (HLA)-DR, CD11b and CD65 (2).

T-ALL is a genetically heterogeneous disease caused by the accumulation of multiple genetic defects in developing T-cells that affect critical cellular processes, including cell differentiation, proliferation, survival and self-renewal capacity (3). The presence of the nucleoporin 214-ABL proto-oncogene 1 (*NUP214-ABL1*) fusion gene has been identified in 6% of all T-ALL cases (4). *NUP214*, also known as CAN, is a 214-kDa FG-repeat-containing nucleoporin located at band 9q34.1 and includes 36 exons. The

Correspondence to: Dr Kejie Zhang, Department of Hematology, Zhongshan Hospital, Xiamen University, 201-209 Hubinnan Road, Xiamen, Fujian 361004, P.R. China
E-mail: zhangkejie0378@sina.com

*Contributed equally

Key words: early T-cell precursor acute lymphoblastic leukemia, *NUP214-ABL1*, dasatinib, selinexor, T-cell

encoded protein is located at the cytoplasmic side of the nuclear pore complex (NPC) (5). The *NUP214-ABL1* fusion protein is a constitutively active protein tyrosine kinase. De Keersmaecker *et al* (6) recently identified that the sparse representation-based classifier (SRC) family kinase lymphocyte-specific protein tyrosine kinase (LCK) is a protein essential for the proliferation and survival of T-ALL cells dependent on *NUP214-ABL1* activity. These findings underscore the potential of the dual *ABL1*/SRC kinase inhibitor dasatinib in the treatment of *NUP214-ABL1*-positive T-ALL. Furthermore, *NUP214* serves a role in mRNA export and chromosome region maintenance 1 (CRM1)-mediated export of the 60S pre-ribosomal subunit, and may serve a role in the transport of other proteins (7). Given that CRM1 inhibitors, such as selinexor, suppress the export of proteins associated with *NUP214* (7), there is potential for their use to treat patients with T-ALL that also harbor *NUP214-ABL1*.

The *NUP214-ABL1* gene is highly specific for T-ALL (8), however the prevalence of *NUP214-ABL1* gene expression in ETP-ALL has not been verified. Zhang *et al* (9) reported that *NUP214-ABL1* was not detected in all the 64 ETP-ALL cases studied. The present case report describes a rare case of a patient with ETP-ALL harboring the *NUP214-ABL1* fusion gene. The present study also evaluated the therapeutic efficiency of selinexor and dasatinib to treat *NUP214-ABL1*-positive ETP-ALL cells *in vitro*. ETP-ALL has higher rates of relapse and remission failure following conventional chemotherapy and shorter patient survival times (1), meaning that novel therapeutic agents to treat ETP-ALL are urgently required.

Case report

A 29-year-old Han Chinese man was admitted to the Zhongshan Hospital, Xiamen University (Xiamen, China) in September 2015 with a low-grade fever and stomachache, which he had experienced for 5 days. The patient had no family history of genetic or hematological disease. Ethical approval for the current case report was granted by the Medical Ethics Committee of Zhongshan Hospital, Xiamen University (Xiamen, China) and informed written consent was obtained from the patient.

The patient presented with splenomegaly (spleen size, 13.2x4.3 cm) determined via abdominal ultrasonography. The patient's peripheral blood was analyzed with a hematology analyzer (Beckman Coulter, Inc., Brea, CA, USA): White blood cell count was $5.86 \times 10^9/l$ (neutrophils, 10%; lymphocytes, 66%; monocytes, 20%; reference range, white blood cell count $3.5 \times 10^9/l$ - $9.5 \times 10^9/l$; neutrophils, 50-70%; lymphocytes, 20-50%; monocytes, 3-10%), hemoglobin level (Hb) was 118 g/l (reference range, 130-175 g/l) and blood platelet count (Plat) was $45 \times 10^9/l$ (reference range, $125 \times 10^9/l$ - $350 \times 10^9/l$). The proportion of immature cells detected in the peripheral blood was low (4%). The following blood coagulation characteristics were measured: Prothrombin time, 15.6 sec (reference range, 11.0-15.0 sec); activated partial thromboplastin time, 15.2 sec (reference range, 28.0-42.5 sec); fibrinogen level, 2.82 g/l (reference range, 2.00-4.00 g/l) and D-dimer quantification, 3,150 ng/ml (reference range, 0.00-500.00 ng/ml). Lactate dehydrogenase levels were elevated (605.1 U/l; reference range, 109.0-245.0 U/l), however liver and renal functions were

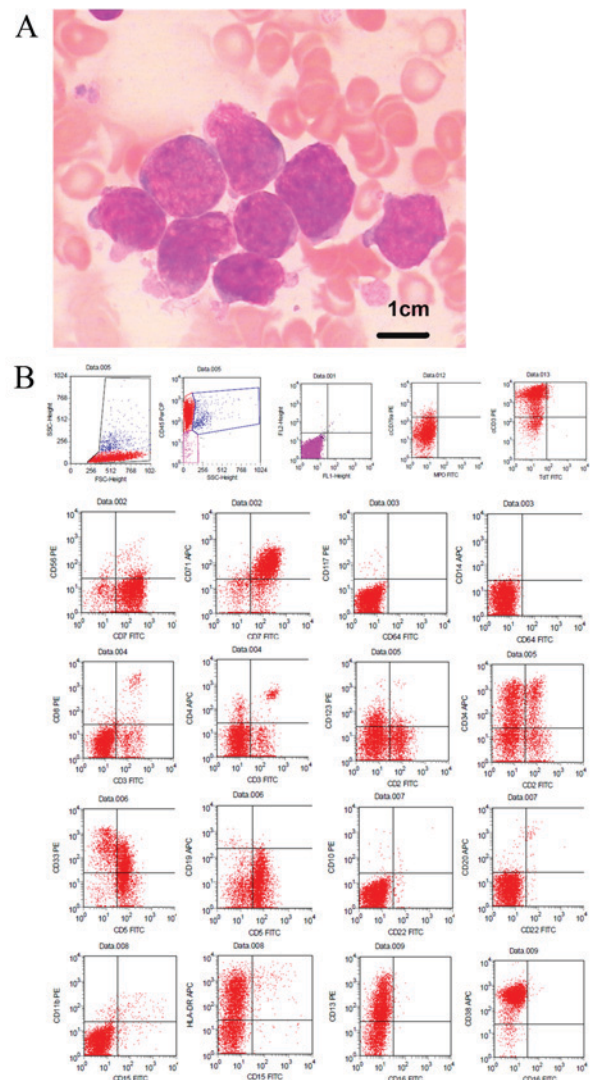


Figure 1. Histomorphological features of leukemic blasts from bone marrow aspirates and flow cytometry analysis. (A) Blasts were large and had high nuclear/cytoplasm ratios, irregular nuclei, dispersed chromatin pattern, indistinct nucleoli and basophilic cytoplasm with pseudopods (Wright-Giemsa stain, the white blood cell nucleus and cytoplasm are indicated by the characteristic blue or pink coloration; magnification, x1,000). (B) Flow cytometric immunophenotyping.

normal. The patient underwent bone marrow (BM) harvesting under general anesthesia. BM was aspirated from the posterior iliac crest in a sterile operating room, and BM smears stained with Wright-Giemsa stains (Electron Microscopy Sciences, Hatfield, PA, USA) were obtained and tested under an optical microscope. The white blood cell nucleus and cytoplasm were indicated by the characteristic blue or pink coloration. The 500-cell differential count from the BM aspirate on the first day of hospital admission revealed that 80% of all nucleated cells were blasts. The majority of blasts exhibited large sizes, high nuclear/cytoplasm ratios, irregularly shaped nuclei, dispersed chromatin, indistinct nucleoli and basophilic cytoplasm that occasionally formed pseudopods, but few exhibited moderate amounts of granular cytoplasm, fine nuclear chromatin and 2-3 prominent nucleoli (Fig. 1A). Cytochemical staining (10) was negative for myeloperoxidase (MPO) and ~3% positive for periodic acid-Schiff staining.

Table I. Genetic analysis of the early T-cell precursor-acute lymphoblastic leukemia patient.

Type of analysis	Gene	Method	Result
Gene mutation	FLT3-ITD	RT-PCR	-
Fusion gene	MLL/AF4	Multiplex nested RT-PCR	-
	MLL/AF6		-
	MLL/AF9		-
	MLL/AF10		-
	MLL/AF17		-
	MLL/AF1P		-
	MLL/AF1Q		-
	MLL/AFX		-
	MLL/ELL		-
	MLL/ENL		-
	dupMLL		-
	CBFβ/MYH11		-
	AML1/ETO		-
	AML1/MDS1		-
	SET/CAN		-
	DEK/CAN		-
	PML/RARα		-
	PLZF/RARα		-
	NPM/RARα		-
	NPM/ALK		-
	TEL/AML1		-
	E2A/PBX1		-
	BCR/ABL1		-
	NPM/MLF1		-
	TEL/ABL1		-
	E2A/HLF		-
	TLS/ERG		-
	SIL/TAL1		-
	TEL/PDGFR		-
	EVII		-
	HOX11		-
Ph-like fusion genes	RCSD1/ABL1	Multiplex RT-PCR	-
	ZMIZ1/ABL1		-
	NUP214/ABL1		+
	PAG/ABL2		-
	TNIP1/PDGFRβ		-
	RANBP2/ABL1		-
	SNX2/ABL1		-
	RCSD1/ABL2		-
	SSBP2/PDGFRβ		-
	ETV6/ABL1		-
	ZC3HAV1		-
	/ABL2		-
	ZEB2/PDGFRβ		-
	TEL/ABL1		-
	SSBP2/CSF1R		-
	EBF1/PDGFRβ		-

Table I. Continued.

Type of analysis	Gene	Method	Result
Gene mutation	FLT3-ITD	RT-PCR	-
	IDH1 ^{R132}	Next-generation sequencing	-
	NPM1(exon12)		-
	IDH2R140		-
	CEBPA		-
	IDH2R172		-
	DNMT3A		-
	C-kitD816		-
	PHF6		-
	TET2		(c.86C>G; p.P29R)
	ASXL1		(c.1954G>A; p.G652S), (c.3759T>C; p.S1253S)

RT-PCR, reverse transcription-polymerase chain reaction; +, positive; -, negative; Ph-like, Philadelphia chromosome-like.

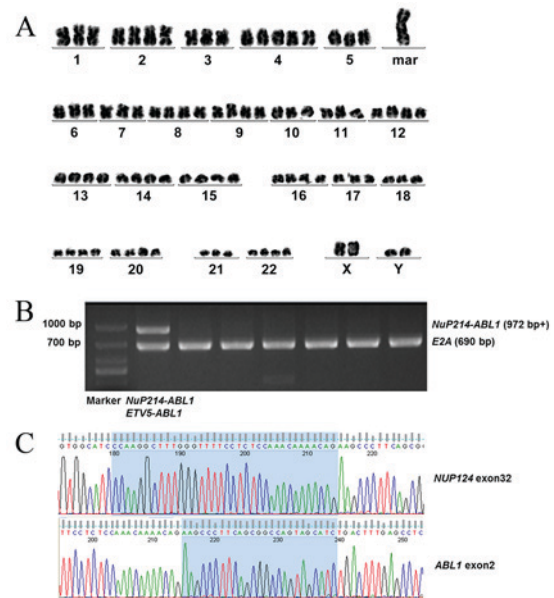


Figure 2. Karyotype of the abnormal clone and detection of the *NUP214-ABL1* fusion transcript. (A) Karyotype of the abnormal clone. The final karyotype was 80-83<4n>,XXYY,+ mar, inc [2]/46, XY[18]. (B) *NUP214-ABL1* fusion transcript detected by multiplex reverse transcription-polymerase chain reaction. (C) *NUP214-ABL1* fusion transcript detected by DNA sequencing. *NUP124* exon 32 and *ABL1* exon 2 are shaded blue. *NUP214-ABL1*, nucleoporin 214-tyrosine protein kinase *ABL1* proto-oncogene 1.

Flow cytometry of the BM aspirate was performed using a four-color Beckman Coulter Cytomics FC 500 flow cytometer (Beckman Coulter, Inc.) as described previously (11). The results indicated that ~90% of the blasts were positive for CD45, the T-cell markers cCD3, CD2 and CD7, and the myeloid/stem

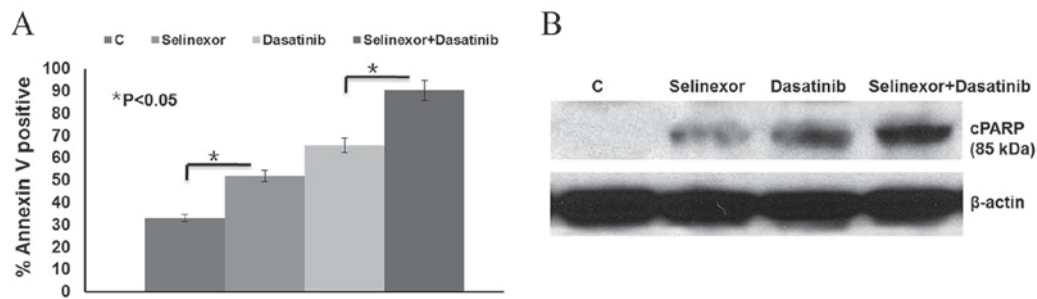


Figure 3. Effect of selinexor and dasatinib treatment in primary biopsy-derived *NUP214-ABL1*-positive lymphoblast cells. Freshly isolated lymphoblast cells were treated with 10 μ M selinexor and/or 10 μ M dasatinib for 48 h. (A) Apoptosis was measured using Annexin V/propidium iodide staining and flow cytometry. (B) Cell extracts were analyzed by western blot analysis to determine PARP cleavage. PARP, poly ADP-ribose polymerase; C, control; *NUP214-ABL1*, nucleoporin 214-tyrosine protein kinase ABL1 proto-oncogene 1.

cell markers CD34, CD38, CD13, CD33, HLA-DR and CD123. However, the blasts were weak for CD5, negative for CD1a, CD8, as well as CD19, CD10, CD79a, terminal deoxynucleotidyl transferase, CD4, CD3, CD64, CD14, CD20, CD56, CD16, CD15, CD11b and MPO (Fig. 1B), suggesting a diagnosis of ETP-ALL. Bone marrow cells were directly processed for chromosomal preparation and cytogenetic analyses were performed using the standard method and/or the G-banding method (12). The result of conventional G-banding chromosomal analysis of the BM cells was 80-83<4n>.XXYY,+mar,i nc[2]/46,XY[18] (Fig. 2A).

The results of multiplex nested reverse transcription-polymerase chain reaction (RT-PCR), which was performed as described previously (13), were negative for the fusion genes listed in Table I. Multiplex RT-PCR was subsequently used to detect Philadelphia chromosome-like fusion genes that have a gene expression profile similar to that of Ph⁺ ALL, but lack *BCR ABL1* fusion. The results demonstrated that the *NUP214-ABL1* fusion gene was positive in this case (Table I; Fig. 2B), which was further confirmed by DNA sequencing (Fig. 2C). Also, gene mutation analyses (Table I) were performed. A TET2 missense mutation (c.86C>G; p.P29R), ASXL1 missense mutation (c.1954G>A; p.G652S) and ASXL1 same-sense mutation (c.3759T>C; p.S1253S) were detected in this case, which were single nucleotide polymorphism variants (SNP) of TET2 and ASXL1 mutations. These SNP variants did not suggest any significant prognostic impact on leukemia.

The patient received pretreatment with an intravenous drip of 10 mg/day dexamethasone (Cisen Pharmaceutical Co., Ltd., Shandong, China). Following treatment for 7 days, stomachache and fever were attenuated and the patient's lymphocyte count decreased to <1.0x10⁹/l. The patient subsequently received induction chemotherapy with vincristine (Hangzhou Minsheng Pharmaceutical Group Co., Ltd., Hangzhou, China), idarubicin (Pfizer Inc., New York, NY, USA), cyclophosphamide (Baxter Oncology GmbH, Shanghai, China) and prednisone (Cisen Pharmaceutical Co., Ltd.) (VICP; 2 mg vincristine on days 1, 8, 15 and 22; 10 mg idarubicin on days 1-3 and days 15-17; 1.2 g cyclophosphamide on days 1 and 15; and 60 mg prednisone on days 1-28) and dasatinib (100 mg/day, on days 8-14). On day 15, routine blood examination results were as follows: Neutrophils, 4.76x10⁹/l; lymphocytes, 1.85x10⁹/l, Hb 65 g/l and Plat 74x10⁹/l (reference range, neutrophils, 1.8x10⁹/l-6.3x10⁹/l;

lymphocytes, 1.10x10⁹/l-3.2x10⁹/l, Hb 130-175 g/l and Plat 125x10⁹/l-350x10⁹/l). BM aspiration revealed <5% lymphoblasts, indicating that the patient had achieved a complete hematological remission with incomplete blood count recovery. On day 30, the patient had achieved complete hematological remission (CR), which was defined as <5% marrow blasts in the bone marrow aspirate and normalization of blood counts. The patient then received consolidation chemotherapy [1.2 g cyclophosphamide on day 1; 3 g cytarabine (Pfizer Inc.) every 12 h on days 1-2; and 80 mg 6-mercaptopurine (Hangzhou Minsheng Pharmaceutical Group Co., Ltd.) on days 1-7] and adequate central nervous system prophylaxis with intrathecal therapy [10 mg methotrexate (Pfizer Inc.), 50 mg cytarabine and 10 mg dexamethasone] and high-dose systemic chemotherapy with 5 g/m² methotrexate. The final date of follow-up was January 11 2016, at which point the patient was alive and healthy.

In vitro analysis of selinexor and dasatinib treatment. Upon written informed consent, *in vitro* analysis was conducted on cells from the patient. A total of 2x10⁶ primary lymphoblast cells were obtained from BM samples using Ficoll density gradient centrifugation (FicollPaque PLUS solution; GE Healthcare Life Sciences, Little Chalfont, UK). The protocol was as follows: 4 ml of Ficoll Histopaque was placed in a 15 ml centrifuge tube, then the bone marrow sample was gently layered on top. The tubes were centrifuged for 30 min at 100 x g at 4°C in a swing-out bucket. The buffy coat that formed in the interphase between histopaque and medium was aspirated and washed (centrifuged at 100 x g for 10 min) twice with 10 ml of sterile PBS. Primary lymphoblast cells were maintained in RPMI 1640 medium (Thermo Fisher Scientific, Inc.) and 15% fetal calf serum (HyClone; GE Healthcare Life Sciences, Logan, UT, USA), and incubated in an atmosphere containing 5% CO₂ at 37°C. The effect of selinexor and dasatinib on apoptosis was evaluated in primary lymphoblast cells. The primary cells were treated with 10 μ M selinexor (14) and/or 10 μ M dasatinib (15) for 48 h at 37°C. Apoptosis was subsequently analyzed using the Annexin V/propidium iodide staining (BD PharMingen, San Diego, CA, USA) and flow cytometry was performed according to the manufacturer's protocol. Poly ADP-ribose polymerase (PARP) cleavage was detected using western blot analysis (16).

The results demonstrated that the apoptotic cell population significantly increased following selinexor or dasatinib treatment compared with the control ($P < 0.05$) and combined selinexor and dasatinib treatment led to a significant increase in cell apoptosis compared with either treatment alone ($P < 0.05$; Fig. 3A). These results were further confirmed by the detection of increased PARP cleavage by western blot analysis following selinexor or dasatinib treatment, compared with the control (Fig. 3B). Combined selinexor and dasatinib treatment induced more PARP cleavage than either treatment alone.

Discussion

Approximately 8% of T-ALL cases harbor fusions involving the *ABL1* tyrosine kinase gene (17). BCR-*ABL1*, the prototypic *ABL1* fusion kinase in chronic myeloid leukemia and subsets of B-cell ALL, is rarely detected in T-ALL (18). By contrast, 6% of T-ALL cases express the constitutively active NUP214-*ABL1* fusion kinase (5). To the best of our knowledge, there have been no studies reporting *NUP214-ABL1* fusion gene expression in ETP-ALL to date. The current case report describes a rare case of ETP-ALL with *NUP214-ABL1* fusion gene expression. ETP-ALL is recognized as a form of T-ALL with high induction failure (1). However, CR was achieved in the current case following 30 days induction therapy with VICP and dasatinib. Further studies are required to confirm that dasatinib used in combination with traditional induction chemotherapy is more effective than chemotherapy alone.

The NUP214-*ABL1* fusion protein is sensitive to tyrosine kinase inhibitors including imatinib, dasatinib and nilotinib (17); therefore, these drugs may have potential in treating this subgroup of patients with T-ALL. Although NUP214-*ABL1* is sensitive to *ABL1* kinase inhibitors, the development of resistance to these compounds is a major clinical problem, underlining the requirement for additional drug targets in the sparsely studied NUP214-*ABL1* signaling network. De Keersmaecker *et al* (6) identified LCK, mitotic arrest deficient-like 1, structural maintenance of chromosomes protein 4 and nucleoporin 155 as proteins that NUP214-*ABL1*-positive T-ALL tumor cells depend on for their proliferation, indicating that these proteins are potential drug targets for NUP214-*ABL1*-positive T-ALL. Targeting LCK in NUP214-*ABL1* may be possible to treat patients with T-ALL that are NUP214-*ABL1*-positive, as dasatinib and bosutinib are able to co-target *ABL1* and LCK (6). The effect of dasatinib on the apoptosis of primary isolated lymphoblast cells from the patient in the present case study was evaluated. Following treatment for 48 h, apoptosis was induced, indicating that dasatinib induces a cytotoxic effect in NUP214-*ABL1*-positive cells.

Furthermore, De Keersmaecker *et al* (8) reported that incorporating NUP214-*ABL1* into the NPC may be critical for the activation of NUP214-*ABL1* kinase. NUP214 is one component of NPC proteins. Evolutionarily conserved NPC proteins mediate the transport of molecules between the nucleoplasm and cytoplasm, which are CRM1 dependent. Mutations in nucleoporins are often linked to specific developmental defects and disease, and the resulting phenotypes

are usually interpreted as the consequences of perturbed nuclear transport activity (8). The present study indicated that CRM1 inhibition with selinexor was effective against a case of NUP214-*ABL1*-positive T-ALL *in vitro*. Therefore, selinexor may have a potential function as a salvage therapy at the time of relapse.

In conclusion, expression of the *NUP214-ABL1* fusion gene should be tested in cases of T-ALL, including ETP-ALL. Dasatinib in combination with traditional induction chemotherapy may reverse the high induction failure of ETP-ALL with *NUP214-ABL1* fusion gene, although further prospective studies are required to confirm this. Therefore, selinexor with or without dasatinib may serve as a potential salvage therapy following relapse.

References

- Jain N, Lamb AV, O'Brien S, Ravandi F, Konopleva M, Jabbour E, Zuo Z, Jorgensen J, Lin P, Pierce S, *et al*: Early T-cell precursor acute lymphoblastic leukemia/lymphoma (ETP-ALL/LBL) in adolescents and adults: A high-risk subtype. *Blood* 127: 1863-1869, 2016.
- Coustan-Smith E, Mullighan CG, Onciu M, Behm FG, Raimondi SC, Pei D, Cheng C, Su X, Rubnitz JE, Basso G, *et al*: Early T-cell precursor leukaemia: A subtype of very high-risk acute lymphoblastic leukaemia. *Lancet Oncol* 10: 147-156, 2009.
- De Keersmaecker K, Marynen P and Cools J: Genetic insights in the pathogenesis of T cell acute lymphoblastic leukemia. *Haematologica* 90: 1116-1127, 2005.
- Graux C, Cools J, Melotte C, Quentmeier H, Ferrando A, Levine R, Vermeesch JR, Stul M, Dutta B, Boeckx N, *et al*: Fusion of NUP214 to *ABL1* on amplified episomes in T-cell acute lymphoblastic leukemia. *Nat Genet* 36: 1084-1089, 2004.
- Pante N, Bastos R, McMorrow I, Burke B and Aebi U: Interactions and three-dimensional localization of a group of nuclear pore complex proteins. *J Cell Biol* 126: 603-617, 1994.
- De Keersmaecker K, Porcu M, Cox L, Girardi T, Vandepoel R, de Beeck JO, Gielen O, Mentens N, Bennett KL and Hantschel O: NUP214-*ABL1*-mediated cell proliferation in T-cell acute lymphoblastic leukemia is dependent on the LCK kinase and various interacting proteins. *Haematologica* 99: 85-93, 2014.
- Hutten S and Kehlenbach RH: Nup214 is required for CRM1-dependent nuclear protein export *in vivo*. *Mol Cell Biol* 26: 6772-6785, 2006.
- De Keersmaecker K, Rocnik JL, Bernad R, Lee BH, Leeman D, Gielen O, Verachtert H, Folens C, Munck S, Marynen P, *et al*: Kinase activation and transformation by NUP214-*ABL1* is dependent on the context of the nuclear pore. *Mol Cell* 31: 134-142, 2008.
- Zhang J, Ding L, Holmfeldt L, Wu G, Heatley SL, Payne-Turner D, Easton J, Chen X, Wang J, Rusch M, *et al*: The genetic basis of early T-cell precursor acute lymphoblastic leukaemia. *Nature* 481: 157-163, 2012.
- Leinonen EA: Cytochemical studies of acute leukemias. *Acta Haematol* 43: 219-227, 1970.
- Tamul KR, Meyers DC, Bentley SA and Folds JD: Two color flow cytometric analysis of concomitant acute myeloid leukemia and chronic lymphocytic leukemia. *Cytometry* 18: 30-34, 1994.
- Summer AT, Evans HJ and Buckland RA: New technique for distinguishing human chromosomes. *Nature* 232: 31-32, 1971.
- Pallisgaard N, Hokland P, Riishøj DC, Pedersen B and Jørgensen P: Multiplex reverse transcription-polymerase chain reaction for simultaneous screening of 29 translocations and chromosomal aberrations in acute leukemia. *Blood* 92: 574-588, 2014.
- Etchin J, Sanda T, Mansour MR, Kentsis A, Montero J, Le BT, Christie AL, McCauley D, Rodig SJ, Kauffman M, *et al*: KPT-330 inhibitor of CRM1 (XPO1)-mediated nuclear export has selective anti-leukaemic activity in preclinical models of T-cell acute lymphoblastic leukaemia and acute myeloid leukaemia. *Br J Haematol* 161: 117-127, 2013.

15. Quintás-Cardama A, Tong W, Manshoury T, Vega F, Lennon PA, Cools J, Gilliland DG, Lee F, Cortes J, Kantarjian H, *et al*: Activity of tyrosine kinase inhibitors against human NUP214-ABL1-positive T cell malignancies. *Leukemia* 22: 1117-1124, 2008.
16. Zhang YL, Guang MH, Zhuo HQ, Min XH, Yao Q, Gu AQ, Wu SH, Zhang DB, Lu JY, Chen Y, *et al*: Carfilzomib inhibits constitutive NF- κ B activation in mantle cell lymphoma B cells and leads to the induction of apoptosis. *Acta Haematol* 137: 106-112, 2017.
17. De Keersmaecker K, Marynen P and Cools J: Genetic insights in the pathogenesis of T-cell acute lymphoblastic leukemia. *Haematologica* 90: 1116-1127, 2005.
18. Westbrook CA, Hooberman AL, Spino C, Dodge RK, Larson RA, Davey F, Wurster-Hill DH, Sobol RE, Schiffer C and Bloomfield CD: Clinical significance of the BCR-ABL fusion gene in adult acute lymphoblastic leukemia: A cancer and leukemia group B study (8762). *Blood* 80: 2983-2990, 1992.