

Ginsenoside Rg3 induces ginsenoside Rb1-comparable cardioprotective effects independent of reducing blood pressure in spontaneously hypertensive rats

YICHUAN JIANG^{1*}, MIN LI^{1*}, ZEYUAN LU¹, YUCHEN WANG¹, XIAOFENG YU¹, DAYUN SUI¹ and LI FU^{2,3}

¹Department of Pharmacology, School of Pharmaceutical Sciences, Jilin University, Changchun, Jilin 130021; ²Jilin Yatai Pharmaceutical Co., Ltd., Changchun, Jilin 130033;

³Institute of Dalian Fusheng Natural Medicine, Dalian, Liaoning 116600, P.R. China

Received March 18, 2017; Accepted August 17, 2017

DOI: 10.3892/etm.2017.5198

Abstract. Ginsenoside Rg3 (Rg3) is a rare type of ginsenoside used as an anti-tumor medicine in China. Ginsenoside Rb1 (Rb1), which exhibits protective effects on the cardiovascular system, is similar to Rg3 in chemical structure. In the present study, Rb1 and Rg3 were administered for 6 weeks to spontaneously hypertensive rats (SHR) and their cardioprotective effects were assessed. According to echocardiography and histopathological examinations, the decrease in cardiac function and ventricular remodeling that occurred in SHR rats were attenuated by Rb1 and Rg3. However, tail-cuff blood pressure measurements indicated that Rb1 and Rg3 did not reduce blood pressure in SHR rats. The cardioprotective effects of Rb1 and Rg3 occurred independently of blood pressure reduction. Furthermore, immunohistochemistry (IHC) revealed that renin angiotensin system (RAS) activity in the myocardium of SHR was significantly attenuated by Rb1 and Rg3, whereas ELISA identified no significant changes of RAS activity in the serum. The results of IHC and reverse transcription-quantitative polymerase chain reaction demonstrated that levels of transforming growth factor β 1, tumor necrosis factor- α , interleukin-6, interleukin-1 and endothelin-1 in the myocardium of SHR rats were reduced following Rb1 and Rg3 treatment. This may be due to the attenuation of RAS activity

in the myocardium and the mechanisms of the cardioprotective effects of Rb1 and Rg3.

Introduction

Ginsenosides, which are extracted from ginseng (*Panax ginseng*), American ginseng (*Panax quinquefolium*) and notoginseng (*Panax notoginseng*), exhibit a variety of pharmacological activities, including cardiovascular protective (1-7), neuroprotective (8-10) and anti-tumor effects (11-16). Ginsenoside Rb1 (Rb1) is one of the monomers contained in total ginsenosides (extracted from sun-cured ginseng) whereas ginsenoside Rg3 (Rg3), a particularly rare ginsenoside, is obtained from other ginsenosides by heat treatment during ginseng processing (17). Chemical (17) or biological (18,19) methods have also been used to transform other ginsenosides, including Rb1, into Rg3.

Previous studies have demonstrated that Rb1 exhibits beneficial effects on the cardiovascular system. It is able to attenuate myocardial ischemia, reperfusion injury (2) and ventricular remodeling (1,5). The chemical structure of Rg3 is similar to that of Rb1 (Fig. 1); however Rg3 exhibits strong anti-tumor activity (12,13,15,16), which Rb1 does not, meaning that it may be used to treat patients with tumors. The Shenyi Capsule, which is produced by Jilin Yatai Pharmaceutical Co., Ltd., is a widely used anti-tumor medication in China and its principal component is Rg3. Although the anti-tumor activity of Rg3 has been well documented, to the best of our knowledge, it remains unknown whether Rg3 induces the same beneficial effects on the cardiovascular system that Rb1 does. Our group is currently undertaking a long-term study in which the effects of various ginsenosides, including Rb1 and Rg3, are assessed in various animal models of chronic disease, such as hypertension, hyperlipemia and diabetes.

The spontaneously hypertensive rat (SHR) is a widely used animal model of hypertension. Angiotensin II (Ang II) levels in the blood and myocardial tissue are abnormally higher in SHR than in healthy Wistar-Kyoto (WKY) rats. Increased Ang II levels cause progressive hypertension, myocardial fibrosis and may even induce ventricular remodeling, resulting in heart failure (20,21). The aim of the present study was to

Correspondence to: Dr Li Fu, Institute of Dalian Fusheng Natural Medicine, 5 Tieshanzhong Road, Dalian, Liaoning 116600, P.R. China

E-mail: dlfuli@aliyun.com

Professor Dayun Sui, Department of Pharmacology, School of Pharmaceutical Sciences, Jilin University, 1266 Fujin Road, Changchun, Jilin 130021, P.R. China

E-mail: suidy@jlu.edu.cn

*Contributed equally

Key words: ginsenoside Rg3, ginsenoside Rb1, spontaneously hypertensive rats, renin angiotensin system, ventricular remodeling

assess and compare the effects of Rb1 and Rg3 and determine whether Rg3 exhibits protective effects on the cardiovascular system in SHR rats.

Materials and methods

Reagents. Rb1 (95% purity) was obtained from Dr. Yanping Chen at the Department of Natural Medicinal Chemistry, School of Chemistry, Jilin University (Jilin, China) and dissolved in double-distilled water (ddH₂O) prior to use. Rg3 (95% purity) was obtained from Jilin Yatai Pharmaceutical Co., Ltd. (Changchun, China) and suspended in 0.5% sodium carboxymethyl cellulose solution for use. All other chemicals were analytical reagents.

Animals and treatments. A total of 24 SHR and 8 WKY rats (male, 16-17-week-old, 250-300 g) were purchased from Vital River Laboratories Co., Ltd. (Beijing, China). All rats were kept in a specific pathogen-free experimental animal workshop (25°C, 10/14-h light/dark cycle), and had free access to food and water. Experiments were performed in accordance with the Guide for the Care and Use of Laboratory Animals of Jilin University and approved by the Ethics Committee of Jilin University.

The rats were randomly divided into 4 groups (each, n=8): i) A WKY group, consisting of WKY rats orally administered ddH₂O; ii) a SHR group, consisting of SHR rats orally administered ddH₂O; iii) a Rb1 group consisting of SHR rats orally administered 20 mg/kg Rb1; and iv) a Rg3 group Rg3 consisting of SHR rats orally administered 20 mg/kg Rg3. All treatments were administered once a day over 42 consecutive days.

After treatment for 6 weeks with ddH₂O or ginsenosides, all rats were anesthetized with chloral hydrate (300 mg/kg, intraperitoneally), and blood samples were obtained from the abdominal aorta before the rats were sacrificed. Hearts were obtained and weighed after the rats were sacrificed, and myocardium tissue samples were then fixed in 4% buffered paraformaldehyde solution (25°C, 24 h) for histopathological examination or frozen in liquid nitrogen and stored at -80°C prior to reverse transcription-quantitative polymerase chain reaction (RT-qPCR).

Blood pressure measurement. The systolic blood pressure (SBP), diastolic blood pressure (DBP) and pulse pressure (PP) of rats were measured using the tail-cuff method and a small animal sphygmomanometer (BP-2010A; Softron Biotechnology Ltd., Beijing, China) following a previously described protocol (22) on the first and the last days of the 6-week treatment.

Echocardiography. On the first and last days of the 6-week treatment, transthoracic echocardiography was performed as previously described (23), using a standard setting with a 10S transducer (Vivid-i; GE Healthcare, Chicago, IL, USA). Animals were anesthetized with chloral hydrate (300 mg/kg, intraperitoneally) and two-dimensional and M-mode echocardiographic measurements were conducted. A short-axis two-dimensional image of the left ventricle was obtained at the position of the papillary muscles. Subsequently, M-mode

Table I. Primer sequences of TNF- α , IL-6, IL-1 β , ET-1 and β -actin.

Primer name	Sequences
β -actin	Forward: 5'-GATCAAGATCATTGCTCCTCCTG-3' Reverse: 5'-AGGGTGTAAAACGCAGCTCA-3'
TNF- α	Forward: 5'-GTCGTAGCAAACCACCAAGC-3' Reverse: 5'-TGTGGGTGAGGAGCACGTAG-3'
IL-6	Forward: 5'-TGTATGAACAGCGATGATG-3' Reverse: 5'-AGAAGACCAGAGCAGATT-3'
IL-1 β	Forward: 5'-GCAATGGTCGGGACATAGTT-3' Reverse: 5'-AGACCTGACTTGGCAGAGG-3'
ET-1	Forward: 5'-GCTCCTCCTTGATGGACAA-3' Reverse: 5'-TTTGGTGAGCACACTGGC-3'

TNF- α , tumor necrosis factor- α ; IL, interleukin-6; IL-1 β , interleukin-1 β ; ET-1, endothelin-1.

images were acquired at a sweep speed of 100 mm/s and digitally stored. The left ventricular internal dimension at diastole (LVIDd) and left ventricular internal dimension at systole (LVIDs) were acquired from M-mode images; subsequently, left ventricular fractional shortening (FS) and left ventricular ejection fraction (EF) were calculated automatically by the equipment. The parameters were measured by an experienced echocardiographer blinded to the treatment groups.

Assay of the angiotensin converting enzyme (ACE) and Ang II levels in the serum. Blood samples were collected and left at room temperature for 2 h to allow complete clotting and then centrifuged at 1,500 x g, 4°C for 15 min. The serum was removed and stored at -80°C prior to ELISA. ACE (CSB-E04490r) and Ang II (CSB-E04494r) ELISA kits were purchased from Cusabio Biotech Co., Ltd. (Wuhan, China) and the assays were completed by this company.

Histopathological examination. Myocardial tissue samples were fixed in 4% buffered paraformaldehyde solution and then embedded in paraffin. Paraffin-embedded sections 4- μ m thick were stained with hematoxylin and eosin (H&E) and Masson trichrome stain. Sections were examined using a Nikon E100 light microscope (Nikon Corporation, Tokyo, Japan) and photomicrograph images were captured.

Immunohistochemistry (IHC). Primary antibodies against ACE (bs-0439R), Ang II (bs-0587R), Ang II receptor type 1 (AT1, bs-0438R) and transforming growth factor β 1 (TGF- β 1, bs-0103R) were purchased from Bioss Antibodies (Beijing, China). Peroxidase-conjugated goat anti-rabbit IgG (ZB-2301), DAB kit (ZLI-9018) and two step rabbit IHC kit (PV-6001) were purchased from ZSGB-BIO (Beijing, China). IHC was performed following the manufacturer's protocols of the IHC kit and DAB kit. Photomicrograph images were then captured, and Image Pro Plus 6.0 (Media Cybernetics, Inc., Rockville, MD, USA) was used for image analysis.

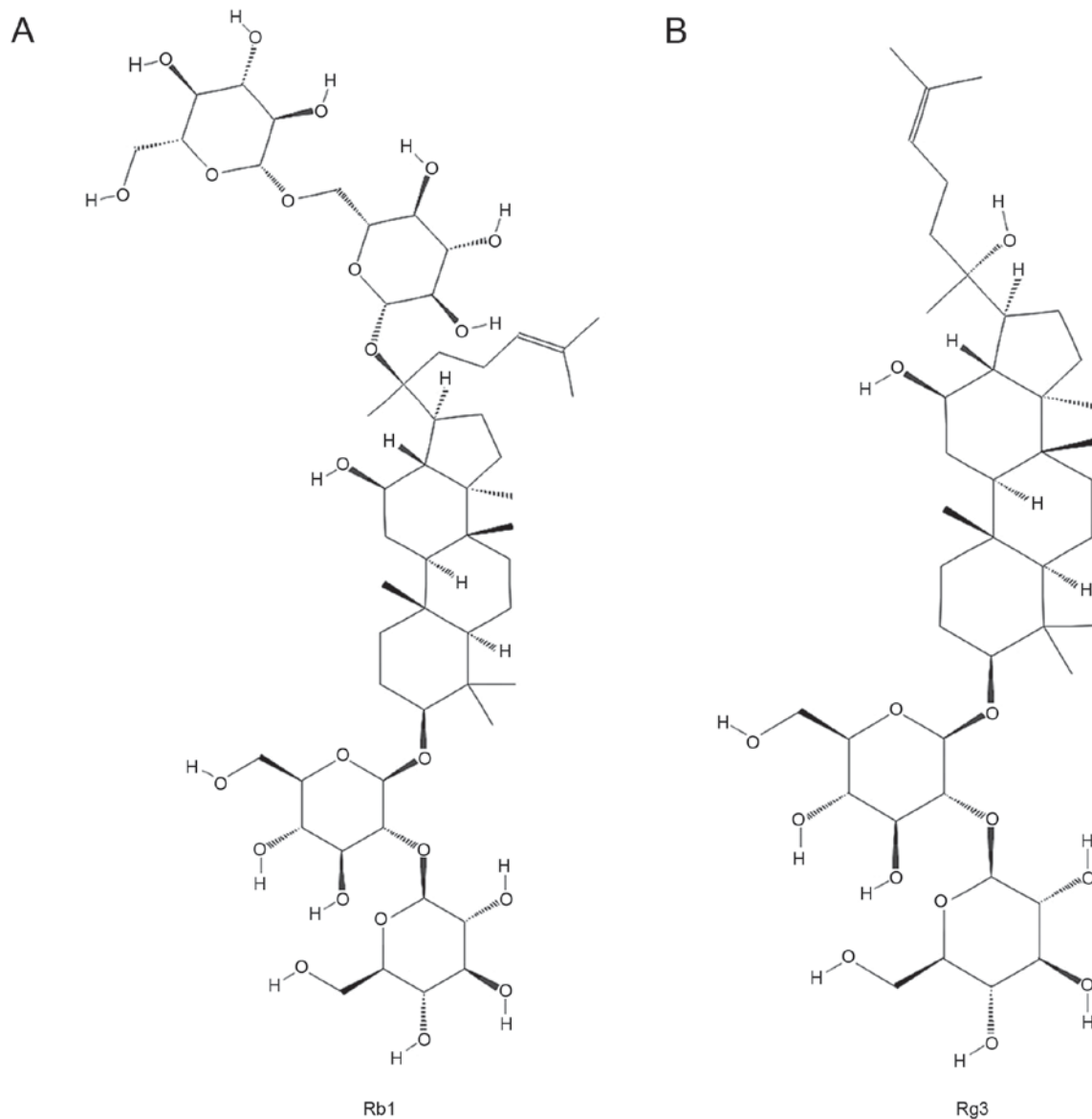


Figure 1. Chemical structures of (A) ginsenoside Rb1 and (B) ginsenoside Rg3. Images were downloaded from <https://www.ncbi.nlm.nih.gov/pccompound>. Rb1, ginsenoside Rb1; Rg3, ginsenoside Rg3.

RNA preparation and RT-qPCR. Total RNA was isolated from frozen myocardium tissue samples using TRIzol reagent (Thermo Fisher Scientific, Inc., Waltham, MA, USA) following the manufacturer's protocol. Total RNA was reverse-transcribed and qPCR was conducted using the TransScript Green Two-Step qRT-PCR SuperMix (TransGen Biotech Co., Ltd., Beijing, China) on the Stratagene Mx3000P (Agilent Technologies, Inc., Santa Clara, CA, USA) and following the manufacturer's protocol (94°C for 5 sec, 60°C for 15 sec and 72°C for 10 sec, 40 cycles). The relative fold changes in the mRNA levels of the target genes were determined using the $2^{-\Delta\Delta Cq}$ method (24) and β -actin was used as a housekeeping gene. Primer sequences are provided in Table I.

Statistical analysis. SPSS 15.0 statistical software (SPSS, Inc., Chicago, IL, USA) was used for statistical analysis. All data are expressed as the mean \pm standard deviation. One-way analysis of variance with Tukey's post hoc test was used to

analyze differences among groups and $P < 0.05$ was considered to indicate a statistically significant difference.

Results

Effects of Rb1 and Rg3 on cardiac structure and function. The effects of Rb1 and Rg3 on cardiac structure and function were evaluated using echocardiography. As depicted in Fig. 2, compared with the WKY group prior to the 6-week treatment, the three groups of SHR rats exhibited slight cardiac function injury; they had a significantly lower FS and EF compared with the WKY group ($P < 0.05$; Fig. 2D and E). However, LVIDd and LVIDs were similar among all groups, indicating that the cardiac structure of SHR rats was unaffected prior to the 6-week treatment.

Following the 6-week treatment, the FS and EF of the three SHR groups were all significantly reduced compared with the WKY group ($P < 0.05$). However, the FS and EF of the Rb1 and Rg3 groups were significantly higher than those

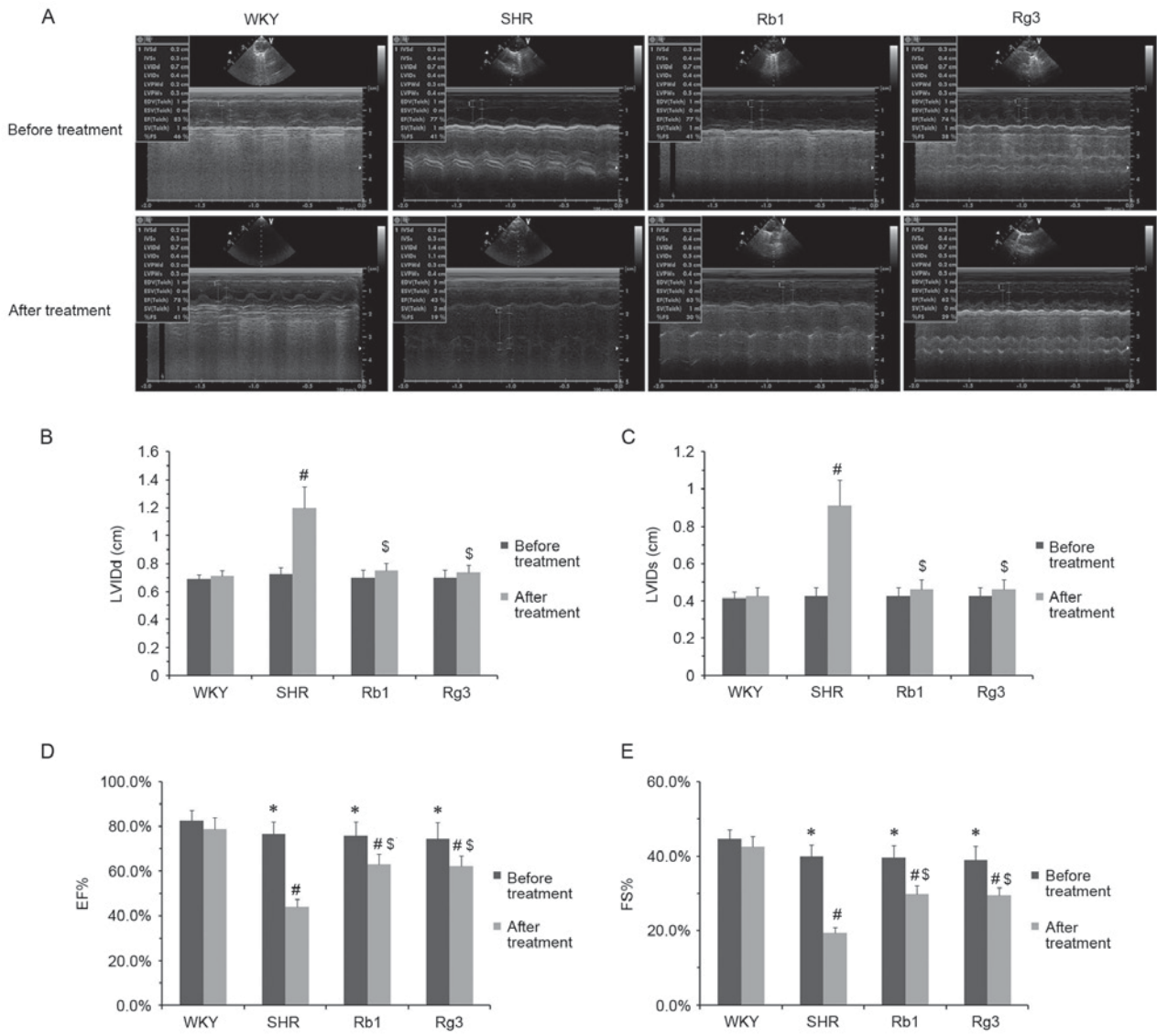


Figure 2. Effects of Rb1 and Rg3 on cardiac structure and function. (A) Representative echocardiographic M-mode records. (B) LVIDd, (C) LVIDs, (D) EF and (E) FS of rats prior to and following 6 weeks treatment. Data are presented as the mean ± standard deviation, where n=8 for each group. *P<0.05 vs. WKY group prior the treatment; #P<0.05 vs. WKY group following treatment; ^SP<0.05 vs. SHR group following treatment. Rb1, ginsenoside Rb1; Rg3, ginsenoside Rg3; LVIDd, left ventricular internal dimension at diastole; LVIDs, left ventricular internal dimension at systole; EF, left ventricular ejection fraction; FS, left ventricular fractional shortening; WKY, Wistar-Kyoto rats; SHR, spontaneously hypertensive rats.

of the SHR group (P<0.05; Fig. 2D and E). Rb1 and Rg3 also exhibited protective effects on cardiac structure. Following treatment, the LVIDd and LVIDs of the SHR group were significantly higher than those of the WKY group (P<0.05); however, those of the Rb1 and Rg3 groups were significantly lower than the SHR group and did not differ significantly between those of the WKY group (Fig. 2B and C). Notably, the cardiac protective effects of Rb1 and Rg3 were comparable.

Effects of Rb1 and Rg3 on blood pressure. Rb1 and Rg3 did not significantly affect the blood pressure of SHR rats. The SBP and DBP of the three groups of SHR rats were all significantly higher than the WKY group prior to and following 6-week treatment (P<0.05) and there was no significant difference in blood pressure between the SHR group and the Rb1 or Rg3 groups (Fig. 3A and B). Regarding PP, there were no significant

differences between any groups prior to or following treatment (Fig. 3C).

Effects of Rb1 and Rg3 on the cardiac weight index (CWI). The body weights and heart weights of all four groups are presented in Fig. 3D and E. CWI was subsequently calculated using the following formula: Heart weight/body weight. The CWI of the SHR group was significantly higher than that of the WKY group (P<0.05), while those of groups Rb1 and Rg3 were significantly lower than the SHR group (P<0.05; Fig. 3F). This result demonstrated that hypertension induces cardiac structural changes and that Rb1 and Rg3 significantly attenuate these changes.

Effects of Rb1 and Rg3 on renin angiotensin system (RAS) activity. Rb1 and Rg3 had no significant effects on RAS activity in the serum. ACE and Ang II levels of the three SHR

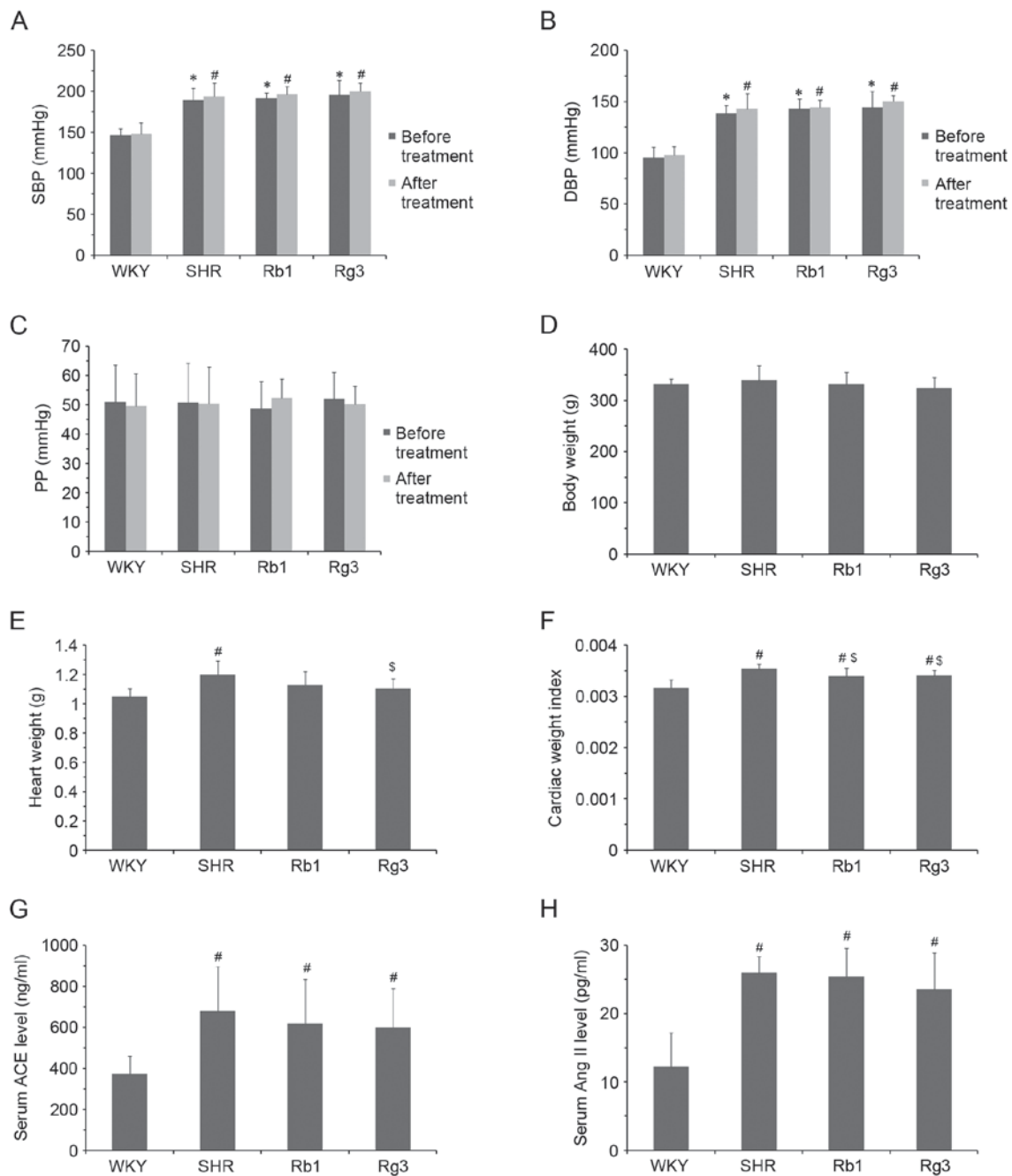


Figure 3. Effects of Rb1 and Rg3 on blood pressure, CWI and RAS activity in the serum. (A) SBP, (B) DBP and (C) PP of rats prior to and following 6 weeks treatment. (D) Body and (E) heart weights and (F) CWI. Serum (G) ACE and (H) Ang II levels. Data are presented as the mean \pm standard deviation, n=8 (A-F) or n=6 (G-H) for each group. *P<0.05 vs. WKY group prior to treatment; #P<0.05 vs. WKY group following treatment; \$P<0.05 vs. SHR group following treatment. Rb1, ginsenoside Rb1; Rg3, ginsenoside Rg3; CWI, cardiac weight index; RAS, renin angiotensin system; SBP, systolic blood pressure; DBP, diastolic blood pressure; PP, pulse pressure; ACE, angiotensin converting enzyme; Ang II, angiotensin II; WKY, Wistar-Kyoto; SHR, spontaneously hypertensive rats.

groups were all significantly higher than those of the WKY group (P<0.05) and there were no significant differences between ACE and Ang II levels between the three SHR groups (Fig. 3G and H). This may explain why Rb1 and Rg3 did not significantly reduce blood pressure in SHR rats.

Effects of Rb1 and Rg3 on myocardium histology. Representative H&E and Masson staining histology photomicrographs are presented in Fig. 4. According to the H&E photomicrographs, myocardium tissues from the SHR group exhibited increased myocardial cell size, myocardial

structural disorder and intercellular space dilatation, which are the typical pathological changes of ventricular remodeling induced by hypertension. Inflammatory cell infiltration was also observed. The Masson photomicrographs indicated increased collagen deposition (blue area) in the SHR group compared with the WKY group. However, treatment with Rb1 and Rg3 markedly improved all these histopathological changes.

Effects of Rb1 and Rg3 on RAS activity and TGF- β 1 levels in the myocardium. The expression of ACE, Ang II, AT1

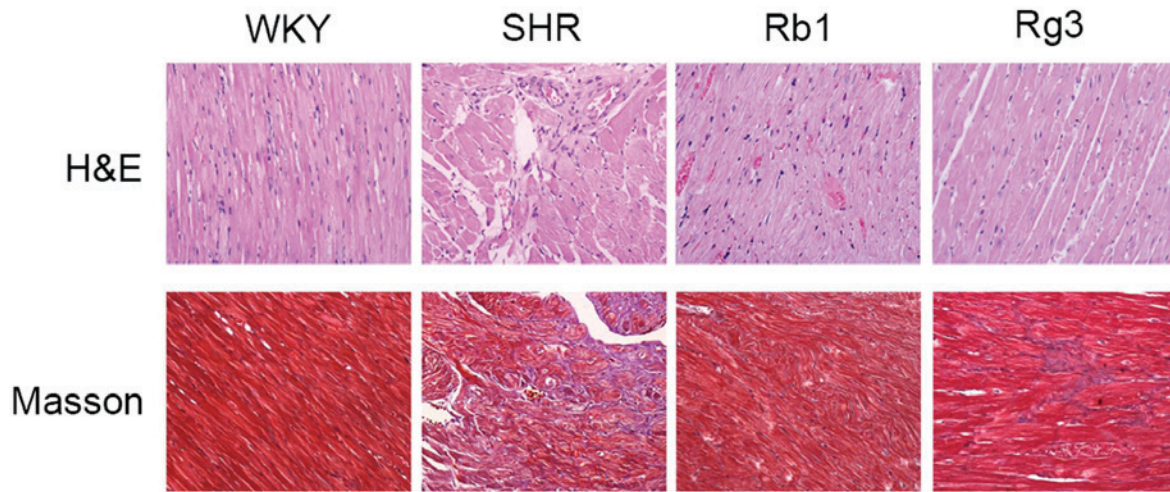


Figure 4. Effects of Rb1 and Rg3 on histology. Representative H&E and Masson staining histology photomicrographs of the myocardium tissue. Magnification, x200. Rb1, ginsenoside Rb1; Rg3, ginsenoside Rg3; H&E, hematoxylin and eosin; WKY, Wistar-Kyoto; SHR, spontaneously hypertensive rats.

and TGF- β 1 in the myocardium was evaluated using IHC. Representative photomicrographs are presented in Fig. 5A and quantitative results are presented in Fig. 5B-E. Compared with the WKY group, levels of ACE, Ang II, AT1 and TGF- β 1 were significantly increased in myocardium samples from the SHR group (all $P < 0.05$). However, these increases were significantly attenuated following treatment with Rb1 and Rg3 (all $P < 0.05$). Indeed, the expression of Ang II and TGF- β 1 in the Rb1 and Rg3 groups did not differ significantly between that of the WKY group (Fig. 5D and E). The downregulation of local RAS activity in the myocardium reduced the expression of TGF- β 1, which is also a key factor to myocardial fibrosis.

Effects of Rb1 and Rg3 on levels of inflammatory factors and ET-1 in the myocardium. Levels of tumor necrosis factor- α (TNF- α), interleukin-6 (IL-6), interleukin-1 β (IL-1 β) and ET-1 mRNA were measured (Fig. 6). In the SHR group, the expression of TNF- α , IL-6, IL-1 β and ET-1 mRNA were all significantly higher than in the WKY group (all $P < 0.05$). However, in the Rb1 and Rg3 groups, the levels of all four mRNAs were all significantly lower than the SHR group ($P < 0.05$). These results suggest that Rb1 and Rg3 may attenuate inflammation and endothelial injury in the myocardium.

Discussion

One of the main mechanisms by which hypertension arises in SHR is congenital abnormal RAS activation, which is similar to what occurs in human essential hypertension (25). Therefore, ACE inhibitors and AT1 receptor blockers are currently the most popular antihypertensive medicines. Ang II, the key factor of the RAS, increases blood pressure and induces inflammation, endothelial injury and fibrosis in various organs (26).

Ang II is an independent factor that causes myocardial fibrosis and ventricular remodeling, regardless whether it has induced hypertension or not (27). A high amount of RAS

activity causes hypertension, whereas high Ang II levels in the myocardium increase TGF- β 1 expression, which may promote fibroblast proliferation and collagen deposition (28). High levels of Ang II may also increase levels of TNF- α , IL-6, IL-1 β and ET-1, which are all closely associated with cardiovascular injury (26) and may contribute to myocardial fibrosis and ventricular remodeling.

The results of the present study indicated that Rb1 and Rg3 attenuated cardiac function and structural changes in SHR but did not reduce blood pressure (Fig. 7). RAS activity was attenuated in the myocardium of the Rb1 and Rg3 groups, whereas RAS activity in the serum remained high. The mechanism of this action remains unknown; something in the myocardium, for example, angiotensin-converting enzyme 2, an enzyme that degrades Ang II into Ang 1-7 (27), may be activated by Rb1 or Rg3 to degrade Ang II. However, further studies are required to determine the exact mechanism of action by which this occurs.

As RAS activity was attenuated in the myocardium, levels of TGF- β 1, TNF- α , IL-6, IL-1 β and ET-1 were all reduced following treatment with Rg3 and Rb1, although blood pressure remained high. Furthermore, Rb1 and Rg3 were able to protect against myocardial fibrosis and ventricular remodeling in the heart. According to the results of histopathology and echocardiography, the cardiovascular protective effect of Rg3 is similar to that of Rb1 in SHR. However, further studies are required to determine the cardioprotective effects of Rg3 in other models of cardiovascular injury, particularly in adriamycin induced heart failure (29).

Rg3 is a widely used anti-tumor medicine in China and it is important to determine whether it also exhibits protective effects on the cardiovascular system. A number of first-line chemotherapy agents, including adriamycin, are cardiotoxic (30). As Rg3 exhibits cardioprotective effects, it is worth determining whether Rg3 attenuates the cardiotoxicity of chemotherapeutic agents when they are used together. This may facilitate the development of safer and more efficient treatment protocols for chemotherapy.

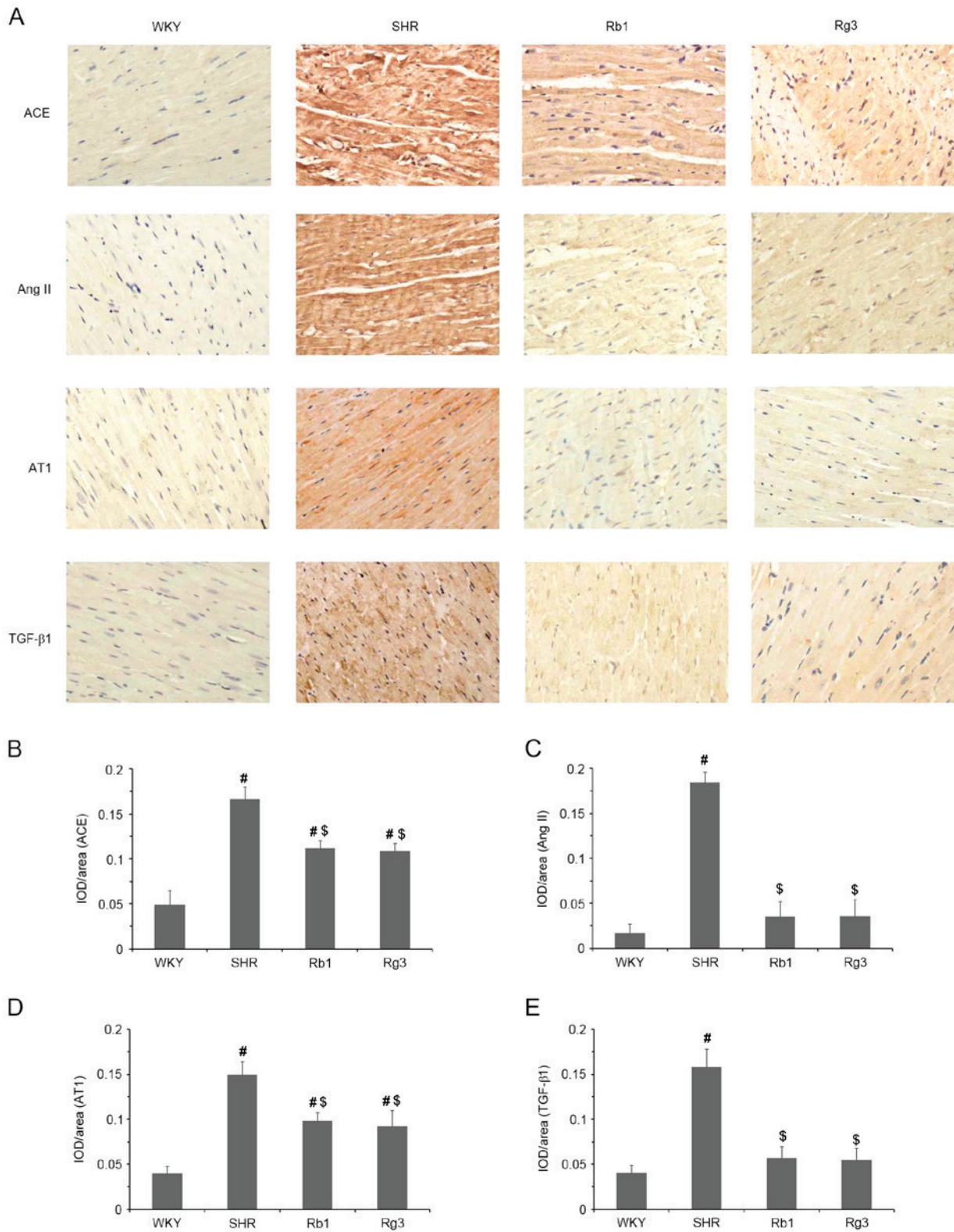


Figure 5. Effects of Rb1 and Rg3 on RAS and TGF-β1 levels in the myocardium. (A) Representative IHC staining photomicrographs of myocardium tissue. (Magnification, x400). Antibodies against ACE, Ang II, AT1 and TGF-β1 were used as the primary antibodies. (B-E) Quantitative results of IHC staining, which were presented as IOD/Area and were proportional to the levels of ACE, Ang II, AT1 and TGF-β1. Data are presented as the mean ± standard deviation, n=4. [#]P<0.05 vs. the WKY group following treatment; ^{\$}P<0.05 vs. the SHR group following treatment. Rb1, ginsenoside Rb1; Rg3, ginsenoside Rg3; RAS, renin angiotensin system; TGF-β1, transforming growth factor β1; IHC, immunohistochemistry; ACE, angiotensin converting enzyme; Ang II, angiotensin II; AT1, Ang II receptor type 1; IOD, integrated optical density; WKY, Wistar-Kyoto; SHR, spontaneously hypertensive rats.

In conclusion, the present study indicated that hypertension and high RAS activity in the myocardium induce cardiac structural and functional changes, which may be attenuated

by Rg3 as well as Rb1, independent of reducing blood pressure. Furthermore, the mechanism of these protective effects of Rg3 on the cardiovascular system may be associated with

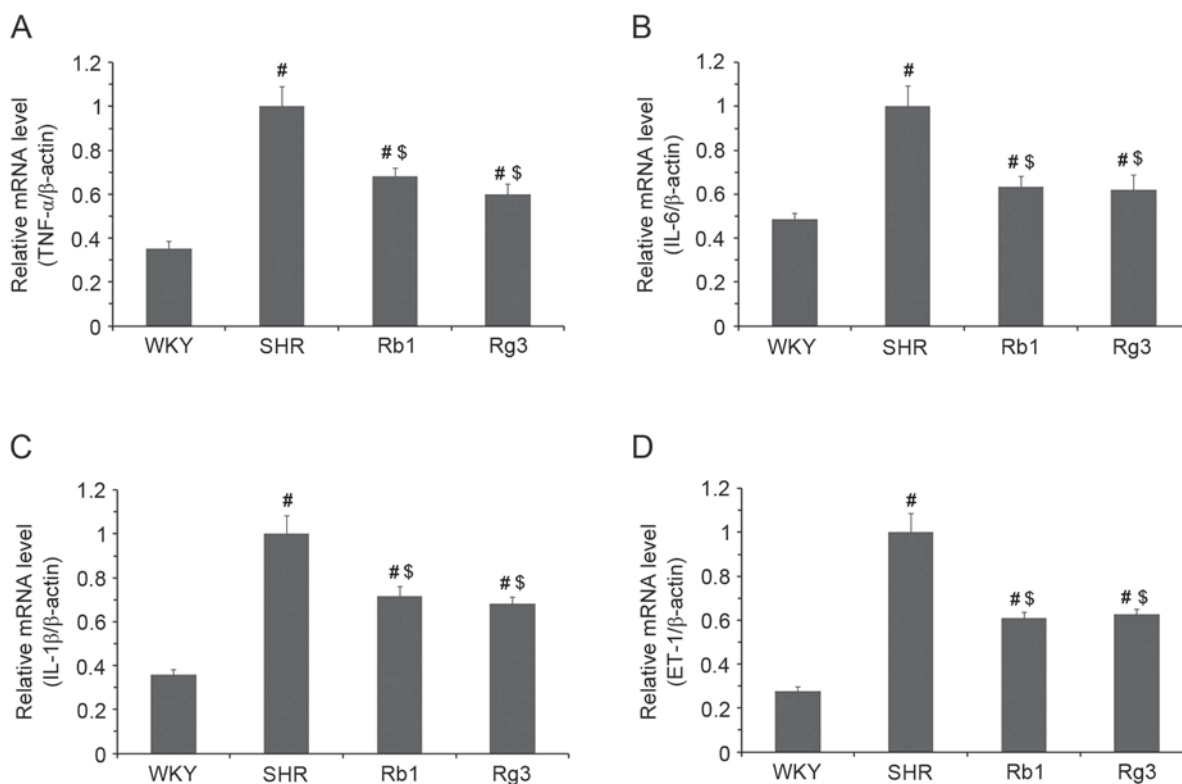


Figure 6. Effects of Rb1 and Rg3 on the mRNA levels of inflammatory factors and ET-1 in the myocardium. (A) TNF- α , (B) IL-6, (C) IL-1 β and (D) ET-1 mRNA expression. β -actin was used as a housekeeping gene. Data are presented as the mean \pm standard deviation, n=4. #P<0.05 vs. the WKY group following treatment; $^{\$}$ P<0.05 vs. the SHR group following treatment. Rb1, ginsenoside Rb1; Rg3, ginsenoside Rg3; TNF- α , tumor necrosis factor- α ; IL-6, interleukin-6; IL-1 β , interleukin-1 β ; ET-1, endothelin-1; WKY, Wistar-Kyoto; SHR, spontaneously hypertensive rats.




Figure 7. Summary of the conclusions. RAS, renin angiotensin system; Rb1, ginsenoside Rb1; Rg3, ginsenoside Rg3.

the attenuation of RAS activity in the myocardium. Therefore, Rg3 may also attenuate inflammation, endothelial injury and fibrosis. Therefore, the results of the present study demonstrated that Rg3 exhibits similar cardiovascular protective effects to Rb1 independent of reducing blood pressure in SHR rats.

Acknowledgements

The present study was supported by the National Natural Science Foundation of China (grant no. 81473378) and Outstanding Doctoral Cultivation Program of Norman Bethune Health Science Center of Jilin University (2014).

References

- Jiang QS, Huang XN, Dai ZK, Yang GZ, Zhou QX, Shi JS and Wu Q: Inhibitory effect of ginsenoside Rb1 on cardiac hypertrophy induced by monocrotaline in rat. *J Ethnopharmacol* 111: 567-572, 2007.
- Wang Z, Li M, Wu WK, Tan HM and Geng DF: Ginsenoside Rb1 preconditioning protects against myocardial infarction after regional ischemia and reperfusion by activation of phosphatidylinositol-3-kinase signal transduction. *Cardiovasc Drugs Ther* 22: 443-452, 2008.
- Wang T, Yu X, Qu S, Xu H, Han B and Sui D: Effect of ginsenoside Rb3 on myocardial injury and heart function impairment induced by isoproterenol in rats. *Eur J Pharmacol* 636: 121-125, 2010.
- Wang T, Yu XF, Qu SC, Xu HL and Sui DY: Ginsenoside Rb3 inhibits angiotensin II-induced vascular smooth muscle cells proliferation. *Basic Clin Pharmacol Toxicol* 107: 685-689, 2010.

5. Zhao H, Lv D, Zhang W, Dong W, Feng J, Xiang Z, Huang L, Qin C and Zhang L: Ginsenoside-Rb1 attenuates dilated cardiomyopathy in cTnT(R141W) transgenic mouse. *J Pharmacol Sci* 112: 214-222, 2010.
6. Shi Y, Han B, Yu X, Qu S and Sui D: Ginsenoside Rb3 ameliorates myocardial ischemia-reperfusion injury in rats. *Pharm Biol* 49: 900-906, 2011.
7. Liu X, Jiang Y, Yu X, Fu W, Zhang H and Sui D: Ginsenoside-Rb3 protects the myocardium from ischemia-reperfusion injury via the inhibition of apoptosis in rats. *Exp Ther Med* 8: 1751-1756, 2014.
8. Li F, Wu X, Li J and Niu Q: Ginsenoside Rg1 ameliorates hippocampal long-term potentiation and memory in an Alzheimer's disease model. *Mol Med Rep* 13: 4904-4910, 2016.
9. Xu H, Yu X, Qu S, Chen Y, Wang Z and Sui D: Protective effect of *Panax quinquefolium* 20(S)-protopanaxadiol saponins, isolated from *Pana quinquefolium*, on permanent focal cerebral ischemic injury in rats. *Exp Ther Med* 7: 165-170, 2014.
10. Radad K, Gille G, Moldzio R, Saito H and Rausch WD: Ginsenosides Rb1 and Rg1 effects on mesencephalic dopaminergic cells stressed with glutamate. *Brain Res* 1021: 41-53, 2004.
11. Qu X, Qu S, Yu X, Xu H, Chen Y, Ma X and Sui D: Pseudo-G-Rh2 induces mitochondrial-mediated apoptosis in SGC-7901 human gastric cancer cells. *Oncol Rep* 26: 1441-1446, 2011.
12. Choi YJ, Lee HJ, Kang DW, Han IH, Choi BK and Cho WH: Ginsenoside Rg3 induces apoptosis in the U87MG human glioblastoma cell line through the MEK signaling pathway and reactive oxygen species. *Oncol Rep* 30: 1362-1370, 2013.
13. Kim BM, Kim DH, Park JH, Na HK and Surh YJ: Ginsenoside Rg3 induces apoptosis of human breast cancer (MDA-MB-231) cells. *J Cancer Prev* 18: 177-185, 2013.
14. Lin G, Yu X, Wang J, Qu S and Sui D: Beneficial effects of 20(S)-protopanaxadiol on antitumor activity and toxicity of cyclophosphamide in tumor-bearing mice. *Exp Ther Med* 5: 443-447, 2013.
15. Zhang YH, Li HD, Li B, Jiang SD and Jiang LS: Ginsenoside Rg3 induces DNA damage in human osteosarcoma cells and reduces MNNG-induced DNA damage and apoptosis in normal human cells. *Oncol Rep* 31: 919-925, 2014.
16. Luo Y, Zhang P, Zeng HQ, Lou SF and Wang DX: Ginsenoside Rg3 induces apoptosis in human multiple myeloma cells via the activation of Bcl-2-associated X protein. *Mol Med Rep* 12: 3557-3562, 2015.
17. Vo HT, Cho JY, Choi YE, Choi YS and Jeong YH: Kinetic study for the optimization of ginsenoside Rg3 production by heat treatment of ginsenoside Rb1. *J Ginseng Res* 39: 304-313, 2015.
18. Cheng LQ, Na JR, Bang MH, Kim MK and Yang DC: Conversion of major ginsenoside Rb1 to 20(S)-ginsenoside Rg3 by *Microbacterium* sp. GS514. *Phytochemistry* 69: 218-224, 2008.
19. Quan LH, Min JW, Yang DU, Kim YJ and Yang DC: Enzymatic biotransformation of ginsenoside Rb1 to 20(S)-Rg3 by recombinant β -glucosidase from *Microbacterium esteraromaticum*. *Appl Microbiol Biotechnol* 94: 377-384, 2012.
20. Pfeffer JM and Pfeffer MA: Angiotensin converting enzyme inhibition and ventricular remodeling in heart failure. *Am J Med* 84: 37-44, 1988.
21. Pfeffer JM, Pfeffer MA, Mirsky I and Braunwald E: Regression of left ventricular hypertrophy and prevention of left ventricular dysfunction by captopril in the spontaneously hypertensive rat. *Proc Natl Acad Sci USA* 79: 3310-3314, 1982.
22. Dias Da Silva VJ, Cavalcante Viana PC, de Melo Alves R, Salgado HC, Montano N and Fazan R Jr: Antihypertensive action of amiodarone in spontaneously hypertensive rats. *Hypertension* 38: 597-601, 2001.
23. Zhang LP, Jiang YC, Yu XF, Xu HL, Li M, Zhao XZ and Sui DY: Ginsenoside Rg3 improves cardiac function after myocardial ischemia/reperfusion via attenuating apoptosis and inflammation. *Evid Based Complement Alternat Med* 2016: 6967853, 2016.
24. Livak KJ and Schmittgen TD: Analysis of relative gene expression data using real-time quantitative PCR and the 2(-Delta Delta C(T)) method. *Methods* 25: 402-408, 2001.
25. Williams GH, Braley LM and Menachery A: Decreased adrenal responsiveness to angiotensin II: A defect present in spontaneously hypertensive rats. A possible model of human essential hypertension. *J Clin Invest* 69: 31-37, 1982.
26. Duprez DA: Role of the renin-angiotensin-aldosterone system in vascular remodeling and inflammation: A clinical review. *J Hypertens* 24: 983-991, 2006.
27. Zhong J, Basu R, Guo D, Chow FL, Byrns S, Schuster M, Loibner H, Wang XH, Penninger JM, Kassiri Z and Oudit GY: Angiotensin-converting enzyme 2 suppresses pathological hypertrophy, myocardial fibrosis, and cardiac dysfunction. *Circulation* 122: 717-728, 2010.
28. Li M, Jiang Y, Jing W, Sun B, Miao C and Ren L: Quercetin provides greater cardioprotective effect than its glycoside derivative rutin on isoproterenol-induced cardiac fibrosis in the rat. *Can J Physiol Pharmacol* 91: 951-959, 2013.
29. Zong WN, Yang XH, Chen XM, Huang HJ, Zheng HJ, Qin XY, Yong YH, Cao K, Huang J and Lu XZ: Regulation of angiotensin-(1-7) and angiotensin II type 1 receptor by telmisartan and losartan in adriamycin-induced rat heart failure. *Acta Pharmacol Sin* 32: 1345-1350, 2011.
30. Singal PK, Li T, Kumar D, Danelisen I and Iliskovic N: Adriamycin-induced heart failure: Mechanism and modulation. *Mol Cell Biochem* 207: 77-86, 2000.