

Observation of corneal transplantation in peripheral corneal disease postoperatively

YIBING ZHANG¹, YUAN HU², XIAODONG LI³, XIAORU SHI¹, FEIHONG XU² and HUI JIA¹

¹Department of Ophthalmology, First Hospital of Jilin University, Changchun, Jilin 130021, P.R. China;

²Department of Medicine, Immunology Institute, Icahn School of Medicine at Mount Sinai, New York, NY 10029, USA;

³Department of Ophthalmology, Baicheng Central Hospital, Baicheng, Jilin 137000, P.R. China

Received October 11, 2017; Accepted March 19, 2018

DOI: 10.3892/etm.2018.6100

Abstract. The aim of the present study was to investigate the role of the limbal stem cells in corneal epithelial homeostasis in patients with peripheral corneal disease who received corneal transplantation surgery. This retrospective study enrolled 85 patients (85 eyes) with peripheral corneal lesion who underwent corneal transplantation at Department of Ophthalmology in First Hospital of Jilin University, Jilin, China. All patients during each follow-up period were examined for best corrected visual acuity, corneal reconstruction (assessed by slit-lamp biomicroscopy), anterior segment optical coherence tomography, and confocal microscopy. Patients were followed up for 3.5 ± 2.4 years. All patients had improved postoperative best corrected visual acuity. Neither vascularization nor conjunctivalization of the graft occurred. Scanning of the graft was covered by normal corneal epithelium as confirmed on the laser scanning *in vivo* confocal microscopy. No evidence of normal limbal was detected in any of the operation eyes. The limbal stem cells may not play a critical role during normal corneal epithelial turnover in patients with peripheral corneal disease following corneal transplantation surgery.

Introduction

In 1986, Schermer *et al* (1), proposed that corneal epithelium was maintained by undifferentiated or poorly differentiated limbal stem cells (LSCs). LSCs generally function as the reserve for cell proliferation, and are keep in balance between cell production and loss (2). LSCs have long been regarded as the sole repository of corneal epithelial stem cells (3,4). The limbus is also called the palisades of Vogt due to its radial structure, which prevents invasion of the conjunctival

epithelium onto the cornea like a 'barrier'. If the 'barrier' is damaged, then the corneal epithelium will be replaced by a conjunctival-like epithelium. Accumulated evidence has demonstrated that the limbal niche is efficient in restoring the corneal surface. For example, in the *in vivo* model of partial limbal stem cell deficiency, removal of the central corneal epithelium resulted in conjunctivalization of the cornea (5). Another example is the impressive clinical results obtained with the transplantation of limbal holoclones (6).

However, the role of LSCs has recently been challenged. Specifically, Majo *et al* (7) stated that LSCs do not necessarily maintain normal corneal homeostasis, although LSCs are an important source for treating corneal epithelial diseases involving stem cell deficiency. Histopathologically, peripheral corneal thinning diseases such as Terrien's marginal degeneration, Mooren's ulcer, and immune peripheral ulcerative keratitis leave only the unhealthy epithelium, extremely thinned and degenerated stroma, and Descemet's membrane.

Corneal transplantation is now a well-established treatment for these peripheral corneal diseases, and in peripheral corneal pathologies the procedure usually has low rates of graft rejection. However, part of the graft and limbus are covered with conjunctival-shaped epithelium and vascularization during the follow-up period. Moreover, previous data attribute the presence of conjunctivalization to limbal stem cell deficiency (LSCD) (8,9). The longstanding concept proposes that corneal epithelial stem cells reside mainly in the limbus. The limbus is essential for maintenance of corneal epithelium and damage to it results in abnormal corneal epithelium (10,11).

In this study, we enrolled patients with peripheral corneal disease who underwent corneal transplantation surgery, and preserved intact corneal epithelium of graft and limbus to perform a long-term observation. The purpose of this study was to investigate whether LSCs could serve as a barrier to prevent migration of the conjunctival epithelium over the long term.

Patients and methods

Patients. This prospective study enrolled patients with peripheral corneal lesions who visited Department of Ophthalmology in First Hospital of Jilin University and received corneal transplantation surgery between January 2008 and January 2016.

Correspondence to: Professor Hui Jia, Department of Ophthalmology, First Hospital of Jilin University, 71 Xinmin Avenue, Changchun, Jilin 130021, P.R. China
E-mail: jiahuiD0120@126.com

Key words: deep anterior lamellar keratoplasty, penetrating keratoplasty, limbal stem cell, conjunctivalization

Patients with infectious keratitis, trauma, or other ocular diseases (i.e., cataract, glaucoma, or macular degeneration) were excluded. Surgery informed written consent forms were obtained from all enrolled patients. And the patients provided informed consent for participation in the present study. The surgical procedures performed in our study included deep anterior lamellar keratoplasty (DALK) and penetrating keratoplasty (PKP). The research was approved by the First Hospital of Jilin University Review Board, and was performed in accordance with the tenets of the Declaration of Helsinki.

Donor corneas. Donor corneas in this study came from two eye banks of Jilin Red Cross Society, Jilin, Changchun, China. The preserved donor corneas for DALK were stored at -80°C in pure sterile glycerin. All glycerol-preserved tissues were rehydrated at room temperature for 60 min before the operations were performed. Fresh corneas of PKP were preserved in medium-term solution (Eusol-C; Al.Chi.Mi.A. Srl, Padova, Italy) at 4°C .

Surgical procedures. All DALKs and PKPs were performed by the same surgeon (HJ). The selection of surgical procedures was based on the size and shape of the corneal lesion.

Crescent or ring-shaped DALK was performed if the inner edge of lesion was in the peripheral cornea without involving the pupil area and progressed circumferentially. D-shaped or total DALK was selected if the inner edge was close to or involving the pupil, and the lesion progressed both circumferentially and centrally. The outer edge was 1-1.5 mm larger than the thinned corneal limbus meaning that the scope of resection included the clear arc of the limbus, in a way to avoid the recurrence of the corneal lesion.

In cases of corneal limbal dermoid, the diameter of recipient trephine was chosen according to the size of the tumor. Generally, the diameter of the trephine was 0.25 mm larger than the excised dermoid bed. In cases of the limbal squamous neoplasia, incision was made 2 mm from the edge of mass. The outer edge was 3-4 mm larger than the limbus of corneal tumor. Epithelium could desquamate for edema with rehydration.

After epithelium and endothelium were wiped away, the full-thickness graft was sutured in place using an interrupted 10-0 nylon suture. If the range of perforation was less than 2 mm, then DALK could be ended by anterior chamber injection of sterile air. Otherwise, the procedure was converted into PKP intraoperatively. The epithelium of graft was removed clearly as well.

Postoperative medication and follow-up. 0.1% tacrolimus (Santen Pharmaceutical Co., Ltd., Osaka, Japan), 0.5% levofloxacin (Santen Pharmaceutical Co., Ltd.), and 0.1% dexamethasone eyedrops (Alcon-Couvreur, S.A., Puurs, Belgium) were routinely administered to the patients.

All patients were followed up on a weekly basis for 1 month and monthly for 6 months, and thereafter at different intervals. Ocular examinations during each follow-up included best corrected visual acuity (BCVA), corneal reconstruction accessed by slit-lamp biomicroscopy, and anterior segment optical coherence tomography (AS-OCT, Visante; Carl Zeiss Meditec AG, Dublin, CA, USA), as well as laser scanning

Table I. Shapes of corneal grafts.

Shapes of grafts	Eyes, n (%)
Crescent	25 (29.4)
Ring-shaped	4 (4.7)
D-shaped	18 (21.2)
Circular	30 (35.3)
Total DALK	8 (9.4)
Total	85

in vivo confocal microscopy (IVCM, Heidelberg Retina Tomograph II with Rostock Cornea Module; Heidelberg Engineering GmbH, Dossenheim, Germany).

Statistical analysis. All statistical analyses were performed with Statistical Package for the Social Sciences v19 software (SPSS Inc., Chicago, IL, USA). All tests were 2-tailed, and $P < 0.05$ was considered to indicate a statistically significant difference.

Results

The 85 patients enrolled in this study included 26 Terrien's marginal degeneration patients (26 eyes), 16 Mooren's ulcer patients (16 eyes), 6 immune peripheral ulcerative keratitis patients (6 eyes), 24 limbal dermoids patients (24 eyes), and 13 limbal squamous neoplasia patients (13 eyes); These 13 limbal squamous neoplasia patients included 8 squamous papilloma patients (8 eyes), 2 intraepithelial neoplasia patients (2 eyes), and 3 corneal squamous cell carcinoma patients (3 eyes). The mean age of patients at presentation was 42.80 ± 24.06 years (range, 1-83 years) and 45 of the 85 patients were males. The mean postoperative follow-up time was 3.5 ± 2.4 years (range, 1-8 years).

Crescent, ring-shaped, D-shaped, and circular grafts were respectively used in 25, 4, 18, and 30 eyes with limbal tumor, and total DALK was performed in 8 eyes (Table I) (Figs. 1-4). Seventy-six patients finally received DALK and 9 patients received PKP. The intraoperative complications such as iris prolapse, limbal perforation, and scleral perforation did not occur in our research. The BCVA fluctuated in the early period, and was stable after 3-6 months postoperatively. The mean BCVA was increased from 20/400 to 20/40 preoperatively to 20/200 to 20/20 postoperatively ($P < 0.01$) (Table II).

The day after surgery, a slit-lamp microscopy examination showed that all patients had no corneal interface fluid. The graft was comparatively edematous in the early postoperative period and then gradually clarified. Donor grafts achieved complete corneal epithelialization in 7 days. The corneal fluorescein staining showed that the corneal epithelial cell sheet was smooth. All operation eyes received successful reconstruction of corneal structure. During each follow-up, slit-lamp microscopy and AS-OCT examinations showed that all grafts had intact epithelia and were well attached to the recipient beds, as well as all cases preserved anatomic integrity. Neither vascularization nor conjunctivalization of the graft occurred. Rejection occurred in one patient with Mooren's ulcer.

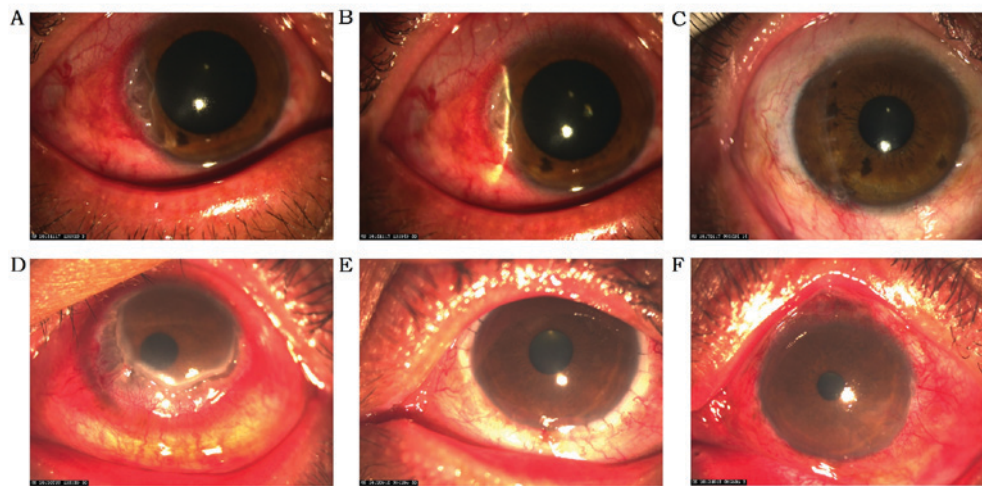


Figure 1. A 47-year-old male with Mooren's ulcer underwent crescent-DALK (A and B). The corneal epithelium retained intact without conjunctivalization for 24 months (C). A 46-year-old male was diagnosed with Mooren's ulcer (D). Total DALK was performed, and the corneal graft was 12.0 mm diameter with marginal sclera (E). The corneal epithelium remained intact during the next 15 months and the patient's postoperative BCVA was 20/32 (F).

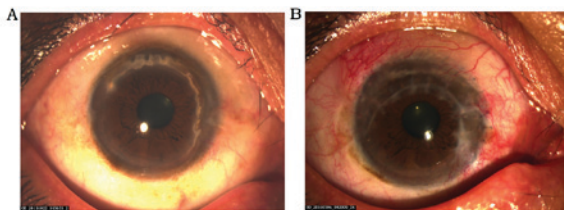


Figure 2. A 48-year-old man diagnosed with Terrien's marginal degeneration (A) underwent PKP. Slit-lamp examination showed ring-shaped grafts in approximately 240 degrees. (B) During a follow-up of 16 months, the epithelium of graft and central cornea stayed smooth and transparent.

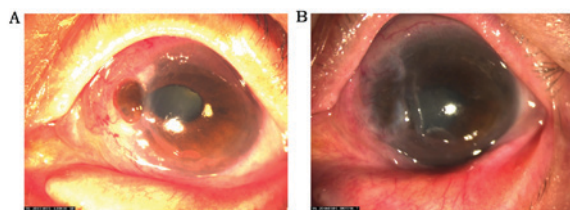


Figure 3. (A) An 81-year-old female was diagnosed with immune peripheral ulcerative keratitis with a 2 mm2-sized perforation at 9 o'clock. (B) After PKP, the D-shaped graft remained translucent during the next 30 months.

All operation eyes presented clear corneal characteristics by observing central and paracentral epithelial morphology using IVCN. Polygonal and flat cells with hyper-reflective nuclei in the superficial layer progressively decreased in size in the intermediate layers and small cells without detectable nuclei were in the basal layer with reflective borders (Fig. 5A-C). Corneal frames of the grafts demonstrated some cellular architecture similar to normal appearing epithelium. No conjunctival epithelial cells or goblet cells were detected in the epithelium of the grafts. The superficial layer showed groups of polygonal cells with bright cytoplasm and bright nuclei. The wing cells seemed smaller than the superficial cells, with clear bright borders. The basal layer

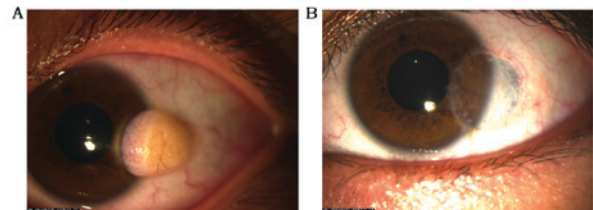


Figure 4. A 19-year-old female diagnosed with limbal dermoids (A) underwent DALK. (B) The graft epithelium retained intact and smooth for 12 months.

was represented by a honeycomb pattern of cells with smaller diameters. No nuclei were observed in the wing cells and the basal cells (Fig. 5D-G). IVCN showed irregular limbal architecture with the absence of the palisades of Vogt in the limbal area of the grafts.

Discussion

In the present study, we performed a long-term observation of limbus in the grafts in 85 peripheral corneal lesion patients who underwent corneal transplantation. All patients received successful corneal reconstructions. Neither vascularization nor conjunctivalization of the graft occurred. The grafts were covered by normal corneal epithelium without evidence of limbus in any operation eyes. Our findings indicate that LSCs may not play a critical role during normal corneal epithelial turnover in patients with peripheral corneal disease following corneal transplantation surgery.

Majo *et al* (7), proposed a hypothesis whereby the stem cells residing throughout the basal layer of the corneal epithelium maintain the homeostasis of the corneal epithelium. The authors believed that the central epithelial explants could successfully regenerate the entire denuded corneal epithelial surface, and oligopotent epithelial stem cells in the central cornea contributed to the repair of epithelium. Nevertheless, the findings from Majo *et al* (7), are based on a mouse model and interspecies differences need to be taken into account

Table II. Comparison of the BCVA of pre and post surgery.

BCVA	n (%)	
	Preoperative	Postoperative
≥20/400		
<20/200	17 (20)	11 (12.9)
≥20/200		
<20/40	28 (32.9)	20 (23.5)
≥20/40		
<20/25	26 (30.6)	28 (33)
≥20/25		
<20/20	14 (16.5)	26 (30.6)
Total	85	85

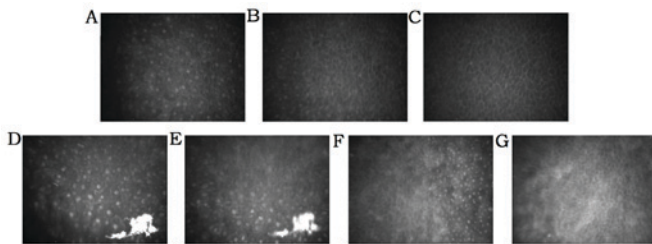


Figure 5. The stratified corneal epithelium in the operated eye presented specific morphological characteristics by observing central and paracentral cornea using IVCN (A-C). (D-G) The graft presented clear corneal epithelium under IVCN.

when extrapolating results from animal models to humans. Nevertheless, the findings reported by Majo *et al* (7), have provoked controversy and have prompted re-evaluation of the conventional LSCs hypothesis.

Some authors have supported this new hypothesis. For instance, Chang *et al* (12), separated human corneal epithelial cells from the central cornea and the limbus for sphere-forming assay and found that both human limbal and central epithelial cells were capable of forming spheres in cultures with properties of stem cells properties. This finding indicates that human central corneal epithelium contains some cells with progenitor potential.

In another study by Chang *et al* (13), the corneal healing was assessed by a human corneal organotypic culture model. In this *in vitro* model, the regenerative capability of central epithelial cells with or without limbus was evaluated by a paracentral corneal epithelial ring or 'donut' ablation. The authors' results demonstrated that the central corneal epithelium could self-regenerate and self-repair but LSCs had no immediate response to an acute wound. However, we think that their observation of only 12 h was too short to properly evaluate the real capability of corneal epithelial regeneration.

Dua *et al* (14), in a clinical observation with a mean follow-up of 60 months, reported that some patients with total LSCD (with conjunctivalization) retain central islands of normal corneal epithelium during the entire follow-up period. It is possible that there are some cells that have characteristics closer to the stem cell than to the transient

amplifying cell. The authors termed these cells 'transient cells'. Thus it seems that the role of LSCs in maintaining normal homeostasis of the corneal epithelium is limited due to existence of 'transient cells'.

Our findings challenge the traditional hypostasis and are also consistent with the observation by Majo *et al* (7). The stroma of lesion was excised to the extent that only Descemet's membrane remained, which indicated that the corneal epithelium and matrix tissue had been removed completely. Meanwhile, the scope of resection was sufficiently large enough to avoid the recurrence of the corneal lesion, with the limbus structure unreserved. Therefore, the limbus of recipient may have a potential role in the physiologic homeostasis of corneal epithelium postoperatively impossible.

Our study also showed that long-term glycerin-cryopreserved lamellar grafts were just a stromal collagen matrix for keratoplasty containing no living cells and only dead keratocyte cells. In the 8 cases of PKP, the corneal epithelial layer was completely wiped off. What is maintaining the intact corneal epithelium sheet in these cases? The more likely scenario is that: (1) the amount of LSCs surrounding the limbus of corneal lesion is not clinically detectable but they are enough to maintain the homeostasis of grafts; (2) transient amplifying cells (TACs) in the basal cell layer of the central epithelium may have an unexpected capacity of maintaining the normal epithelial turnover for a long time, even longer than the previously thought proliferative potential; and (3) the self-renewing capacity of precursor cells in the central cornea suggests that the limbus may not have a critical role in physiologic corneal epithelial homeostasis. All this evidence indicates that the regeneration of corneal epithelium is not different from other squamous epithelia and limbus is not the only niche for corneal stem cells.

In conclusion, the existence of long-term healthy corneal epithelium in patients with peripheral corneal disease following corneal transplantation surgery indicates that LSCs may not play a critical role during normal corneal epithelial turnover. Further research efforts are required to clarify these possibilities and to explore the conundrum.

Acknowledgements

Not applicable.

Funding

No funding was received.

Availability of data and materials

All data generated or analyzed during this study are included in this published article.

Author's contributions

HJ designed the study and reviewed the draft. YZ conducted the analyses and wrote the original draft. YH completed the methodology of the study, XL performed the data curation, XS collected the data and FX performed the statistics.

Ethics approval and consent to participate

Surgery informed written consent forms were obtained from all enrolled patients. Patients provided informed consent for participation in the present study.

The research was approved by the First Hospital of Jilin University Review Board, and was performed in accordance with the tenets of the Declaration of Helsinki.

Consent for publication

All identifying information is removed in the manuscript. The patients have provided informed consent for participation in this study and gave their consent for publication.

Competing interests

The authors declare that they have no competing interests.

References

- Schermer A, Galvin S and Sun TT: Differentiation-related expression of a major 64k corneal keratin in vivo and in culture suggests limbal location of corneal epithelial stem cells. *J Cell Biol* 103: 49-62, 1986.
- Cotsarelis G, Cheng SZ, Dong G, Sun TT and Lavker RM: Existence of slow-cycling limbal epithelial basal cells that can be preferentially stimulated to proliferate: Implications on epithelial stem cells. *Cell* 57: 201-209, 1989.
- Li W, Hayashida Y, Chen YT and Tseng SCG: Niche regulation of corneal epithelial stem cells at the limbus. *Cell Res* 17: 26-36, 2007.
- Castro-Muñozledo F: Review: Corneal epithelial stem cells, their niche and wound healing. *Mol Vis* 19: 1600-1613, 2013.
- Kawakita T, Higa K, Shimmura S, Tomita M, Tsubota K and Shimazaki J: Fate of corneal epithelial cells separated from limbus in vivo. *Invest Ophthalmol Vis Sci* 52: 8132-8137, 2011.
- Pathak M, Olstad OK, Drolsum L, Moe MC, Smorodinova N, Kalasova S, Jirsova K, Nicolaissen B and Noer A: The effect of culture medium and carrier on explant culture of human limbal epithelium: A comparison of ultrastructure, keratin profile and gene expression. *Exp Eye Res* 153: 122-132, 2016.
- Majo F, Rochat A, Nicolas M, Jaoudé GA and Barrandon Y: Oligopotent stem cells are distributed throughout the mammalian ocular surface. *Nature* 456: 250-254, 2008.
- Baradaran-Rafii A, Ebrahimi M, Kanavi MR, Taghi-Abadi E, Aghdami N, Eslani M, Bakhtiari P, Einollahi B, Baharvand H and Javadi MA: Midterm outcomes of autologous cultivated limbal stem cell transplantation with or without penetrating keratoplasty. *Cornea* 29: 502-509, 2010.
- Tseng SC, He H, Zhang S and Chen SY: Niche regulation of limbal epithelial stem cells: Relationship between inflammation and regeneration. *Ocul Surf* 14: 100-112, 2016.
- Shen C, Chan CC and Holland EJ: Limbal stem cell transplantation for soft contact lens wear-related limbal stem cell deficiency. *Am J Ophthalmol* 160: 1142-1149.e1, 2015.
- Chan EH, Chen L, Yu F and Deng SX: Epithelial thinning in limbal stem cell deficiency. *Am J Ophthalmol* 160: 669-77.e4, 2015.
- Chang CY, Green CR, McGhee CN and Sherwin T: Acute wound healing in the human central corneal epithelium appears to be independent of limbal stem cell influence. *Invest Ophthalmol Vis Sci* 49: 5279-5286, 2008.
- Chang CY, McGhee JJ, Green CR and Sherwin T: Comparison of stem cell properties in cell populations isolated from human central and limbal corneal epithelium. *Cornea* 30: 1155-1162, 2011.
- Dua HS, Miri A, Alomar T, Yeung AM and Said DG: The role of limbal stem cells in corneal epithelial maintenance: Testing the dogma. *Ophthalmology* 116: 856-863, 2009.