

Dynamic protein expression of NF- κ B following rat intracerebral hemorrhage and its association with apoptosis

ZONG-CHAO LIU¹, LING-QIU MENG², JING-HUI SONG¹ and JING GAO¹

¹Department of Neurology, Affiliated Hospital of Qingdao University, Qingdao, Shandong 266000;

²Department of Neurology, Tianjin People's Hospital, Tianjin 300121, P.R. China

Received February 26, 2018; Accepted August 14, 2018

DOI: 10.3892/etm.2018.6715

Abstract. The aim of the present study was to evaluate the dynamic protein expression of nuclear factor (NF)- κ B and apoptosis in the cerebral tissue surrounding hematoma following intracerebral hemorrhage (ICH) in rats. A total of 80 healthy male Wistar rats were divided into a sham-surgery group and an ICH group. The ICH model was established by injecting autogenous non-heparin anticoagulant arterial blood into the caudate putamen. NF- κ B levels were assessed by immunohistochemistry at different time points subsequent to surgery, and apoptosis condition was investigated by terminal deoxynucleotidyl-transferase-mediated dUTP nick end labeling. Different levels of NF- κ B were expressed in the cerebral tissue around the ICH at each time point in the ICH group. NF- κ B protein expression was detected at 3 h following hemorrhage, mainly in the cytoplasm. Following 6 h, NF- κ B was identified in the nucleus. Its expression peaked at 72 h following hemorrhage, and persisted for 5 days. Apoptosis was observed 6 h following hemorrhage, and had increased significantly by 12 h. The rate of apoptosis continued to rise from 72-120 h following hemorrhage. Correlation analysis revealed a significant positive correlation between NF- κ B expression and apoptosis ($r=0.753$; $P<0.01$). The enhancement of NF- κ B expression and apoptosis around ICH, and the significant positive correlation between NF- κ B expression and apoptosis, indicates that NF- κ B activation may enhance cerebral apoptosis in rats following ICH.

Introduction

Intracerebral hemorrhage (ICH) has a high rate of morbidity, disability and mortality, but lacks a specific or efficient therapeutic method (1,2). Pathological injuries of ICH include:

Correspondence to: Dr Zong-Chao Liu, Department of Neurology, Affiliated Hospital of Qingdao University, 59 Haier Road, Qingdao, Shandong 266000, P.R. China
E-mail: qdliuzongchao@sohu.com

Key words: intracerebral hemorrhage, cerebral injury, nuclear factor κ B, apoptosis

i) Injury to cerebral tissue caused by a large amount of bleeding; ii) mass effect causing hypothalamus, epithalamus or brain-stem injury, and iii) secondary nerve injury in the peripheral tissue of the foci (3-5). Thus, nerve injury following ICH not only results from the mass effect and the direct damage to the surrounding cerebral tissue caused by hematoma, but also secondary nerve injury (6). Therefore, investigating the mechanism of secondary cerebral tissue injury following ICH is an important research theme.

Nuclear factor (NF)- κ B is a key nuclear transcription factor, associated with the regulation of gene transcription and activated by environmental stimuli applied to the whole body (7). NF- κ B is widely expressed in nerve cells, astrocytes and microglia (8,9). The role of NF- κ B in central nervous system diseases; particularly in ischemic cerebrovascular disease, has become an increasingly popular research topic (10). Following cerebral ischemia, NF- κ B is stimulated and brain injury is exacerbated through mechanisms including the promotion of the inflammatory reaction, cell apoptosis induction and free radical injury mediation (11,12). As the pathogenesis of brain injury subsequent to cerebral hemorrhage is similar to that of cerebral infarction, an ICH model was established by injecting autogenous non-heparin anticoagulant arterial blood into the caudate putamen of rats in the present study, to preliminarily investigate the pathogenesis of brain injury following ICH.

Materials and methods

Animals and experimental protocol. A total of 80 healthy male Wistar rats, aged 3-4 months and weighing 250-300 g, were provided by the Laboratory Animal Center of Qingdao University (Qingdao, China). Rats were housed at a temperature of 20-25°C and a humidity of 30-50%, with a 12 h light/dark circulation and free access to food and water. The study protocol was approved by the Ethics Committee for Animal Experiments of the Affiliated Hospital of Qingdao University (Qingdao, China). Rats were randomly divided into a sham-surgery control group ($n=40$) and an ICH group ($n=40$). Following the establishment of the ICH model, 5 rats from each group were sacrificed at each of the following time points: 0, 3, 6 and 12 h and 1, 2, 3 and 5 days following surgery, and their brain tissues were isolated. Rats were sacrificed via the following method: The rats were intraperitoneally

anesthetized with 10% chloral hydrate (350 mg/kg; China National Pharmaceutical Group Corporation, Beijing, China; batch no. 20080325), then the chest was opened and the right atrium was cut, inducing mortality via exsanguination. Successful sacrifice was confirmed when heartbeat and breathing stopped, and the volume of blood extracted by exsanguination was 10-13 ml. In the present study, no rats exhibited signs of peritonitis following the administration of 10% chloral hydrate. The weight of the animals at the time of sacrifice was 250-300 g.

Analysis of NF- κ B expression. For immunohistochemistry, rat brains were obtained and immediately fixed in 40 g/l formaldehyde (pH 7.0) for 24 h at room temperature, and later embedded in paraffin wax. Samples were sliced into 5 μ m-thick sections using a paraffin slicing machine (RM2235; Leica Microsystems GmbH, Wetzlar, Germany). Following deparaffinization and rehydration, paraffin-embedded tissue sections were treated with heat-induced antigen retrieval buffer (pH 6.0 citrate buffer) and blocked using 3% hydrogen peroxide at room temperature. Samples were then incubated with mouse anti-rat NF- κ B p65 monoclonal antibodies (1:50; cat. no. sc-8008; Santa Cruz Biotechnology, Inc., Dallas, TX, USA) overnight at 4°C. Tissue was then incubated with secondary mouse HRP (cat. no. sc-516102; Santa Cruz Biotechnology, Inc.) for 30 min at room temperature and developed using a DAB kit (cat. no. ZL1-9017; OriGene Technologies, Inc., Rockville, MD, USA) at room temperature for 1 min. Samples and then counterstained with hematoxylin for 30 sec at room temperature.

Terminal deoxynucleotidyl transferase-mediated dUTP nick end labeling (TUNEL) assay. Following deparaffinization and rehydration, paraffin-embedded tissue sections were treated with PBS at room temperature. To observe DNA strand breaks in nuclei, sections were treated with Proteinase K (cat. no. CW 2584M; CWBio, Beijing, China) for 15 min and 3% H₂O₂ for 5 min. The TUNEL assay was performed using the TUNEL Apoptosis Detection kit (cat. no. 40307; Yeasen Biotechnology Co., Ltd., Shanghai, China) according to the manufacturer's protocol. DAPI (cat. no. C0060; Beijing Solarbio Science & Technology Co., Ltd., Beijing, China) was used for the coloration of apoptotic cells at room temperature for 15 min. Cell apoptosis was analyzed using a FACS caliber flow cytometer (Beckman Coulter, Inc., Brea, CA, USA). Images were obtained at a magnification of x400. Five non-overlapping visual fields were selected and the number of positive cells was counted. An average value of each field was then calculated.

ICH model establishment. The ICH model was established as described by Deinsberger *et al* (13). The rats were intraperitoneally anesthetized using 10% chloral hydrate (350 mg/kg), and placed onto a stereotaxic instrument in the prone position. A 10-mm incision was made along the center of the scalp, and the anterior fontanelle was exposed when a 0.5-mm hole was made 0.2 mm in front of the anterior fontanelle, 3 mm to the right of the midline. An injection of 50 μ l blood from the tail tip was administered slowly within 8-10 min. The injection was administered 5.5 mm deep, into the caudate putamen.

The injection needle remained in place for 10 min following injection, then slowly withdrawn. The hole was sealed with sterilized medical bone wax, and the skin was sutured. All steps were performed under sterilized conditions. The rat was returned to normal housing post-surgery, with free food and water access. The rats in the control group underwent equivalent procedures, but no blood injection was administered.

Data processing and statistical analysis. Cell counting was performed for each single specimen under microscopy at x400 magnification. Positively stained cells were counted under an automatic morphology measuring instrument (HPIAS21000) in 5 perihematomal fields of view. All data are presented as the mean \pm standard deviation. Comparisons between more than two groups were made using analysis of variance, and comparisons between 2 groups were made using Student's t-test. The association between two parameters was analyzed via simple linear regression. $P < 0.05$ was considered to indicate a statistically significant difference. SPSS software (version 13.0; SPSS, Inc., Chicago, IL, USA) was used for all statistical analysis.

Results

Dynamic expression of NF- κ B in the cerebral tissue around ICH. A small number of NF- κ B-positive cells were observed in the tissue around the needle path in rats in the control group. NF- κ B was mainly located in the cytoplasm, and there was no statistically significant difference between any time points ($P > 0.05$). NF- κ B-positive cells were observed in the perihematomal edema at all time points in rats of the ICH group. There was significantly more NF- κ B staining in the ICH group compared with the control group ($P < 0.01$). NF- κ B was mainly located in nerve cells and gliocytes in the ICH group. NF- κ B expression was increased at 3 h following hemorrhage, mainly in the cytoplasm. Following 6 h, NF- κ B was also observed in the nucleus. The expression peaked at 72 h following hemorrhage, and then decreased gradually. However, NF- κ B expression could still be detected following 5 days in the ICH group. (Figs. 1-3; Table I).

Apoptosis in the cerebral tissue around ICH. The mean number of apoptotic cells in the sham-surgery control group at each subsequent time point following surgery was 2.85 ± 0.26 , 2.96 ± 0.36 , 2.76 ± 0.39 , 2.87 ± 0.29 , 3.21 ± 0.41 , 3.24 ± 0.36 , 3.05 ± 0.37 and 3.11 ± 0.32 , whereas that of the ICH group was 2.80 ± 0.32 , 3.79 ± 0.46 , 7.83 ± 1.01 , 22.01 ± 3.94 , 42.28 ± 5.55 , 43.26 ± 4.74 , 52.88 ± 5.97 and 69.03 ± 5.93 (Fig. 4; Table II). In the ICH group, a small number of apoptotic nerve cells were identified in the cerebral tissue around the hematoma at 3 h following ICH. Following 6 h, the apoptotic cell number increased, and it had increased significantly by 6 h. The number of apoptotic cells continued to increase at 72 and 120 h following ICH. The difference in apoptotic cell number at each time point 6 h post surgery was statistically significant compared with those in the control group ($P < 0.01$). Changes observed in an apoptotic cell include nucleus condensation, cell shrinkage, nuclear envelope shrinkage, chromatin condensation to nuclear envelope, irregular condensation and light brown granules within the nucleus, which became dark brown

Table I. Nuclear factor-κB-positive cells in the cerebral tissue in both groups.

Time post surgery (h)	Rats (n)	Control group, cells (n)	ICH group, cells (n)
0	5	4.89±0.46	4.35±0.52
3	5	5.01±0.54	17.86±2.74 ^{a,b}
6	5	5.24±0.61	28.42±3.24 ^{a,b}
12	5	6.36±0.64	34.04±4.69 ^{a,b}
24	5	6.51±0.52	65.53±7.50 ^{a,b}
48	5	9.06±0.74	88.14±9.34 ^{a,b}
72	5	9.05±0.82	100.13±12.88 ^{a,b}
120	5	7.89±0.96	62.30±6.48 ^{a,b}

^aP<0.01 vs. control group; ^bP<0.01 vs. 0 h. ICH, intracerebral hemorrhage.

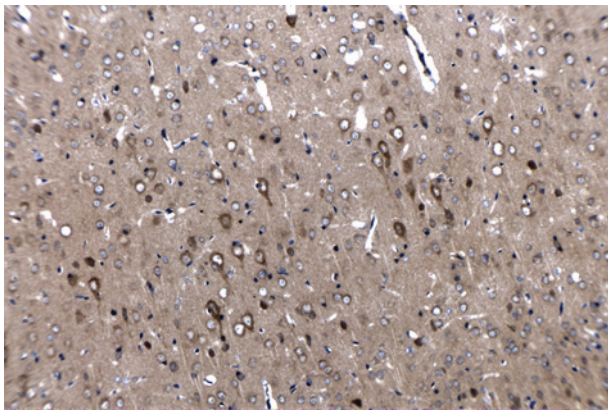


Figure 1. Nuclear factor-κB immunohistochemical staining of cytoplasmic phase in the intracerebral hemorrhage group, with positive expression in the cytoplasm (original magnification, x200).

upon staining. Brain tissue around the hematoma exhibiting distinct color alteration following the TUNEL assay indicated dense areas of apoptotic cells. Only small amounts of apoptotic nerve cells were observed in normal tissue following staining, as was observed in the sham-surgery control group. (Figs. 5 and 6).

Correlation between NF-κB expression and apoptosis in the cerebral tissue around ICH. The number of apoptotic cells was significantly and positively correlated with the number of NF-κB-positive cells ($r=0.753$; $P<0.01$). The correlation between the number of NF-κB-positive cells and the number of apoptotic cells in the ICH group is presented in Fig. 7.

Discussion

NF-κB is an important multidirectional transcription factor. Without stimulation, NF-κB exists in cytoplasm bound to its inhibitory factor, IκB (14). Certain environmental stimuli, including cytokines, free radicals, ultraviolet irradiation, ischemia, anoxia and bacterial or viral antigens, stimulate NF-κB, leading to the promotion of target gene transcription (15-17).

Table II. Apoptotic cells in the cerebral tissue in both groups.

Time post surgery (h)	Rats (n)	Control group, cells (n)	ICH group, cells (n)
0	5	2.85±0.26	2.80±0.32
3	5	2.95±0.34	3.79±0.46
6	5	2.76±0.39	7.83±1.01 ^{a,b}
12	5	2.87±0.29	22.01±3.94 ^{a,b}
24	5	3.21±0.41	42.28±5.55 ^{a,b}
48	5	3.24±0.36	43.26±4.74 ^{a,b}
72	5	3.05±0.37	52.88±5.97 ^{a,b}
120	5	3.11±0.32	69.03±5.93 ^{a,b}

^aP<0.01 vs. control group; ^bP<0.01 vs. 0 h. ICH, intracerebral hemorrhage.

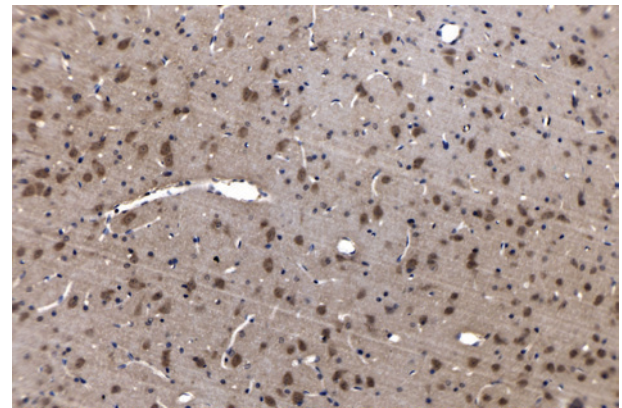


Figure 2. Nuclear factor-κB immunohistochemical staining of nucleus phase in the intracerebral hemorrhage group, positive expression in the nucleus (original magnification, x200).

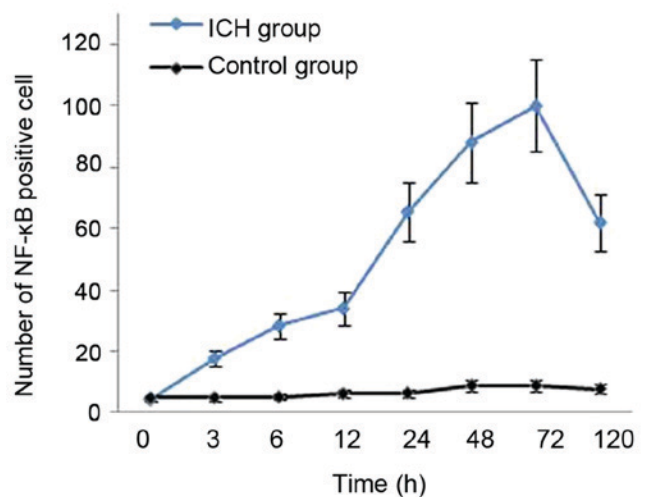


Figure 3. Time course of changes in positive cell number of NF-κB expression in both groups. NF, nuclear factor; ICH, intracerebral hemorrhage.

The target is then recruited for physiological or pathological processes, including the inflammatory reaction, immunoreaction, cell apoptosis and free radical injury (18-21).

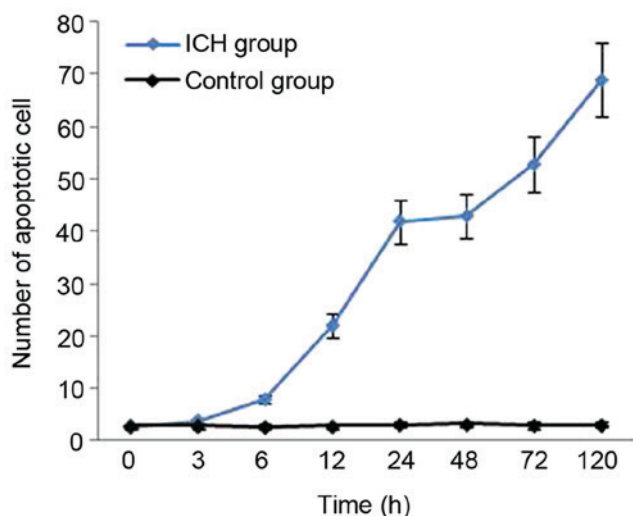


Figure 4. Time course of changes in number of apoptotic cells in both groups. ICH, intracerebral hemorrhage.

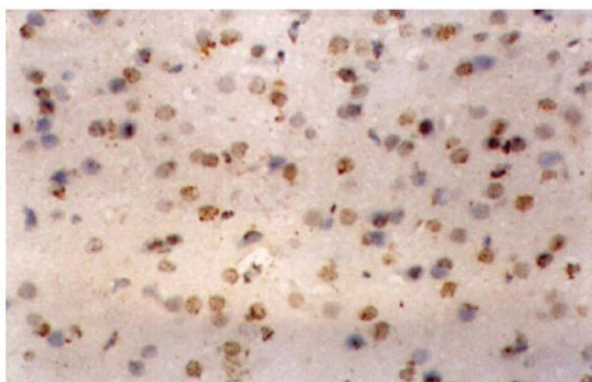


Figure 5. A small number of apoptotic cells were detected in the intracerebral hemorrhage group at 6 h following hemorrhage, and the nuclei were brown (terminal deoxynucleotidyl-transferase-mediated dUTP nick end labeling; original magnification, x400).

The majority of current studies of the role of NF- κ B in cerebrovascular disease focus on brain ischemia. Animal experiments and clinical autopsies have demonstrated that, following ischemic cerebral injury, existing NF- κ B was activated from the rest state, and its mRNA and protein expression levels were enhanced (22,23). Due to varying experimental conditions, the results of previous studies are inconsistent. Among the extensive research of the role of NF- κ B in ischemic cerebral injury (24-26), one study indicated that administration of the NF- κ B inhibitor, N-acetylcysteine, resulted in a significant decrease in cerebral infarct volume in middle cerebral artery occlusion (MACO) ischemia/reperfusion rats (27). It has been demonstrated in numerous animal experiments and clinical trials that mild hypothermia can reduce infarct volume and accelerate the recovery of nerve function (28,29). Han *et al* (30) used MACO ischemia/reperfusion rats to observe the effect of mild hypothermia on the expression of NF- κ B, and it was demonstrated that rats with mild hypothermia exhibited significantly reduced activity of NF- κ B. Thus, it is speculated that the inhibition of NF- κ B activity may be a mechanism of brain protection.

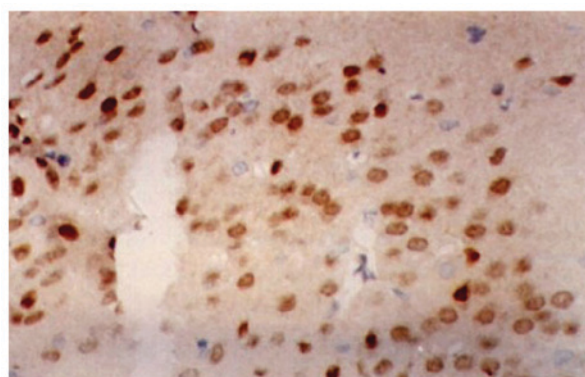


Figure 6. A large number of apoptotic cells were detected in the intracerebral hemorrhage group at 120 h following hemorrhage, and the nuclei were brown (terminal deoxynucleotidyl-transferase-mediated dUTP nick end labeling; original magnification, x400).

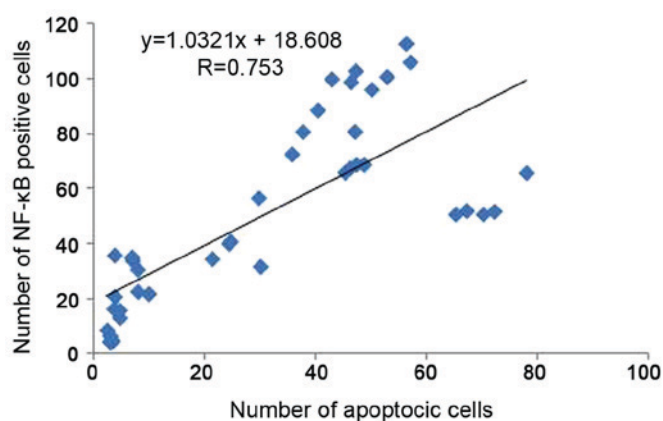


Figure 7. The correlation between NF- κ B expression and apoptosis in the cerebral tissue around intracerebral hemorrhage. NF, nuclear factor.

The pathogenesis of brain injury following ICH is similar to that of cerebral infarction, suggesting that NF- κ B may also be associated with brain cell injury following ICH (31). Therefore the present study evaluated the dynamic expression of NF- κ B and its association with apoptosis in the cerebral tissue surrounding hematoma in rats following ICH. It was demonstrated that, in the sham-surgery group, minimal NF- κ B-positive cells were observed around the needle path with no significance regarding time or nuclear translocation. In the ICH group, NF- κ B was activated 3 h following ICH, and a large number of positive cells were observed in the cerebral tissue around the hematoma. The NF- κ B-positive cells were mainly located in the cytoplasm, indicating that NF- κ B had not exerted biological activity in nucleus. At 6 h following ICH, an NF- κ B nuclear shift was observed, and NF- κ B-positive staining was evident in the cytoplasm and nucleus, or in the nucleus alone. NF- κ B activation also occurred in the surrounding tissues, including the cortex, hippocampus and hypothalamus. NF- κ B-activation peaked at 72 h following ICH, then decayed gradually. The number of positive cells at 5 days was twice that at 3 h. This demonstrated that NF- κ B remained activated following ICH, and suggests that it may be associated with pathogenesis of cerebral injury following ICH. Previous studies have demonstrated that

penumbra also exists in the cerebral tissue around hematoma following ICH, with a similar pathological mechanism to that of cerebral infarction (32). Therefore, it was speculated that the continuous activation of NF- κ B following ICH may aggravate cerebral injury.

Previous studies have demonstrated apoptosis was associated with secondary cerebral injury following ICH (30,33-34). In the present study, TUNEL assays indicated that an increased number of apoptotic nerve cells were observed in the cerebral tissue surrounding hematomas in the ICH surgery group. In these rats, chromatin was condensed into sharply delineated masses with irregular shapes, including crescent, annulus, rectangular, or fragments, which were margined against the nuclear membranes. In contrast, in the sham-surgery rats, very few apoptotic cells were observed in the brain tissue. The increase in apoptosis up to 120 h following ICH, was a contrasting finding to that of Matsushita *et al* (35), which may be due to differences in the size of the hematoma or model-establishment methodology. The present study demonstrated that apoptotic cells were mostly observed in the cerebral tissue surrounding the hematoma, whereas necrotic cells were located near the edge of the hematoma. No apoptotic cells were observed in tissue far from the hematoma, indicating that the apoptotic mechanism is associated with nerve cell injury following ICH. Furthermore, apoptotic cells were also observed in tissue without pathological change, suggesting that the range of nerve cell injury around the hematoma is more extensive than the pathological changes observed under a light microscope. A total of 6 h following ICH, the level of NF- κ B activation increased significantly and the protein translocated into the nucleus, followed by the emergence of a large number of apoptotic cells at 12 h. This illustrates the association between apoptosis and NF- κ B activation following ICH. Furthermore, correlation analysis revealed a significant positive correlation between NF- κ B protein expression and apoptosis, indicating that NF- κ B activation may enhance cerebral apoptosis in perihematomal edema of rats following ICH. However, the mechanism of how NF- κ B regulates apoptosis remains unclear. Future studies will include investigation of the regulatory effect of NF- κ B on the expression of apoptosis-associated genes.

In conclusion, NF- κ B protein expression and apoptotic-cell number were demonstrated to be increased in the cerebral tissue following ICH, and there was a significant positive correlation between NF- κ B expression and apoptosis. Therefore, the present study indicates that NF- κ B activation may promote cerebral apoptosis in perihematomal edema of rats following ICH. However, further research is required to elucidate how NF- κ B promotes apoptosis.

Acknowledgements

The authors would like to thank the Central Laboratory of Affiliated Hospital of Qingdao University (Qingdao, China) for technical support, and to the Department of Neurology of Tianjin People's Hospital (Tianjin, China) for their valuable cooperation.

Funding

No funding was received.

Availability of data and materials

The datasets used and/or analyzed during the present study are available from the corresponding author on reasonable request.

Authors' contributions

ZL designed the current study and analyzed/interpreted the data. LM acquired the data, performed the experiments and analyzed/interpreted the data. JS acquired the data, performed data analysis/interpretation and supervised the current study. JG performed the experiments and statistical analysis.

Ethics approval and consent to participate

The study protocol was approved by the Ethics Committee for Animal Experiments of the Affiliated Hospital of Qingdao University (Qingdao, China).

Patient consent for publication

Not applicable.

Competing interests

The authors declare that they have no competing interests.

Reference

- Satopää J, Meretoja A, Koivunen RJ, Mustanoja S, Putaala J, Kaste M, Strbian D, Tatlisumak T and Niemelä MR: Treatment of intracerebellar haemorrhage: Poor outcome and high long-term mortality. *Surg Neurol Int* 8: 272, 2017.
- Chang JJ, Khorchid Y, Dillard K, Kerro A, Burgess LG, Cherkassky G, Goyal N, Chapple K, Alexandrov AW, Buechner D, *et al*: Elevated pulse pressure levels are associated with increased in-hospital mortality in acute spontaneous intracerebral hemorrhage. *Am J Hypertens* 30: 719-727, 2017.
- Zhai W, Chen D, Shen H, Chen Z, Li H, Yu Z and Chen G: A1 adenosine receptor attenuates intracerebral hemorrhage-induced secondary brain injury in rats by activating the P38-MAPKAP2-Hsp27 pathway. *Mol Brain* 9: 66, 2016.
- Cai P, Luo H, Xu H, Zhu X, Xu W, Dai Y, Xiao J, Cao Y, Zhao Y, Zhao BQ and Fan W: Recombinant ADAMTS 13 attenuates brain injury after Intracerebral hemorrhage. *Stroke* 46: 2647-2653, 2015.
- P Skevas C, Knospe V, Vettorazzi E, Richard G, Wagenfeld L, Westphal M and Regelsberger J: Terson syndrome in subarachnoid hemorrhage, intracerebral hemorrhage, and traumatic brain injury. *Neurosurg Rev* 38: 129-136, 2015.
- Wasserman JK and Schlichter LC: White matter injury in young and aged rats after intracerebral hemorrhage. *Exp Neurol* 214: 266-275, 2008.
- Tak PP and Firestein GS: NF-kappaB: A key role in inflammatory diseases. *J Clin Invest* 107: 7-11, 2001.
- Mehmood T, Maryam A, Tian X, Khan M and Ma T: Santamarine inhibits NF- κ B and STAT3 activation and induces apoptosis in HepG2 liver cancer cells via oxidative stress. *J Cancer* 8: 3707-3717, 2017.
- O'Neill LA and Kaltschmidt C: NF-kappa B: A crucial transcription factor for glial and neuronal cellfunction. *Trends Neurosci* 20: 252-258, 1997.
- Zhu S, Tang S and Su F: Dioscin inhibits ischemic stroke-induced inflammation through inhibition of the TLR4/MyD88/NF- κ B signaling pathway in a rat model. *Mol Med Rep* 17: 660-666, 2018.
- Jeong J, Kim S, Lim DS, Kim SH, Doh H, Kim SD and Song YS: TLR5 Activation through NF- κ B is a neuroprotective mechanism of postconditioning after cerebral ischemia in mice. *Exp Neurobiol* 26: 213-226, 2017.

12. Simmons LJ, Surles-Zeigler MC, Li Y, Ford GD, Newman GD and Ford BD: Regulation of inflammatory responses by neuregulin-1 in brain ischemia and microglial cells in vitro involves the NF-kappa B pathway. *J Neuroinflammation* 13: 237, 2016.
13. Deinsberger W, Vogel J, Kuschinsky W, Auer LM and Böker DK: Experimental intracerebral hemorrhage: Description of double injection model in rats. *Neurol Res* 18: 475-477, 1996.
14. Niu J, Wang K, Graham S, Azfer A and Kolattukudy PE: MCP-1-induced protein attenuates endotoxin-induced myocardial dysfunction by suppressing cardiac NF- κ B activation via inhibition of I κ B kinase activation. *J Mol Cell Cardiol* 51: 177-186, 2011.
15. Kunsch C and Rosen C: NF-kappaB subunit-specific regulation of the interleukin-8 promoter. *Mol Cell Biol* 13: 6137-6146, 1993.
16. Zambrano S, de Toma I, Piffer A, Bianchi ME and Agresti A: NF- κ B oscillations translate into functionally related patterns of gene expression. *Elife* 5: 1-38, 2016.
17. Lee REC, Walker SR, Savery K, Frank DA and Gaudet S: Fold change of nuclear NF- κ B determines TNF-induced transcription in single cells. *Mol Cell* 53: 867-879, 2014.
18. Al-Rasheed NM, Al-Rasheed NM, Bassiouni YA, Hasan IH, Al-Amin MA, Al-Ajmi HN and Mohamad RA: Vitamin D attenuates pro-inflammatory TNF- α cytokine expression by inhibiting NF- κ B/p65 signaling in hypertrophied rat hearts. *J Physiol Biochem* 71: 289-299, 2015.
19. Lian S, Xia Y, Khoi PN, Ung TT, Yoon HJ, Kim NH, Kim KK and Jung YD: Cadmium induces matrix metalloproteinase-9 expression via ROS-dependent EGFR, NF- κ B, and AP-1 pathways in human endothelial cells. *Toxicology* 338: 104-116, 2015.
20. Khaksar S and Bigdeli MR: Intra-cerebral cannabidiol infusion-induced neuroprotection is partly associated with the TNF- α /TNFR1/NF- κ B pathway in transient focal cerebral ischaemia. *Brain Inj* 31: 1932-1943, 2017.
21. Candel S, Tyrkalska SD, García-Moreno D, Meseguer J and Mulero V: Identification of Evolutionarily Conserved Mdl Splice Variants That Regulate Innate Immunity through Differential Induction of NF- κ B. *J Immunol* 197: 1379-1388, 2016.
22. Zhang M, Cui Z, Cui H, Wang Y and Zhong C: Astaxanthin protects astrocytes against trauma-induced apoptosis through inhibition of NKCC1 expression via the NF- κ B signaling pathway. *BMC Neurosci* 18: 42, 2017.
23. Qi W, Zhou F, Li S, Zong Y, Zhang M, Lin Y, Zhang X, Yang H, Zou Y, Qi C, Wang T and Hu X: Remote ischemic postconditioning protects ischemic brain from injury in rats with focal cerebral ischemia/reperfusion associated with suppression of TLR4 and NF- κ B expression. *Neuroreport* 27: 469-475, 2016.
24. Shen W, Zhang C and Zhang G: Nuclear factor kappaB activation is mediated by NMDA and non-NMDA receptor and L-type voltage-gated Ca(2+) channel following severe global ischemia in rat hippocampus. *Brain Res* 933: 23-30, 2002.
25. Nurmi A, Lindsberg PJ, Koistinaho M, Zhang W, Juettler E, Karjalainen-Lindsberg ML, Weih F, Frank N, Schwaninger M and Koistinaho J: Nuclear factor-kappaB contributes to infarction after permanent focal ischemia. *Stroke* 35: 987-991, 2004.
26. Clemens JA, Stephenson DT, Smalstig EP, Smalstig EB, Mincy RE, Rash KS and Little SP: Global ischemia activates nuclear factor-kappa B in forebrain neurons of rats. *Stroke* 28: 1073-1080, 1997.
27. Carroll JE, Howard EF, Hess DC, Wakade CG, Chen Q and Cheng C: Nuclear factor-kappa B activation during cerebral reperfusion: Effect of attenuation with N-acetylcysteine treatment. *Brain Res Mol Brain Res* 56: 186-191, 1998.
28. Ma LL, Song L, Yu XD, Yu TX, Liang H and Qiu JX: The clinical study on the treatment for acute cerebral infarction by intra-arterial thrombolysis combined with mild hypothermia. *Eur Rev Med Pharmacol Sci* 21: 1999-2006, 2017.
29. Geurts M, Scheijmans FE, van Seeters T, Biessels GJ, Kappelle LJ, Velthuis BK and van der Worp HB; DUST investigators: Temporal profile of body temperature in acute ischemic stroke: Relation to infarct size and outcome. *BMC Neurol* 1: 233, 2016.
30. Han HS, Karabiyikoglu M, Kelly S, Sobel RA and Yenari MA: Mild hypothermia inhibits nuclear factor-kappaB translocation in experimental stroke. *J Cereb Blood Flow Metab* 23: 589-598, 2003.
31. Bihl JC, Zhang C, Zhao Y, Xiao X, Ma X, Chen Y, Chen S, Zhao B and Chen Y: Angiotensin-(1-7) counteracts the effects of Ang II on vascular smooth muscle cells, vascular remodeling and hemorrhagic stroke: Role of the NF κ B inflammatory pathway. *Vascul Pharmacol* 73: 115-123, 2015.
32. Menon BK, Hill MD, Eesa M, Modi J, Bhatia R, Wong J, Hudon ME, Morrish W, Demchuk AM and Goyal M: Initial experience with the Penumbra Stroke System for recanalization of large vessel occlusions in acute ischemic stroke. *Neuroradiology* 53: 261-266, 2011.
33. Xue M and Del Bigio MR: Intracerebral injection of autologous whole blood in rats: Time course of inflammation and cell death. *Neurosci Lett* 283: 230-232, 2000.
34. Wei N, Wei Y, Li B and Pang L: Baicalein Promotes Neuronal and Behavioral Recovery after intracerebral hemorrhage via suppressing apoptosis, oxidative stress and neuroinflammation. *Neurochem Res* 42: 1345-1353, 2017.
35. Matsushita K, Meng W, Wang X, Asahi M, Asahi K, Moskowitz MA and Lo EH: Evidence for apoptosis after intercerebral hemorrhage in rat striatum. *J Cereb Blood Flow Metab* 20: 396-404, 2000.



This work is licensed under a Creative Commons Attribution-NonCommercial-NoDerivatives 4.0 International (CC BY-NC-ND 4.0) License.