SPANDIDOS PUBLICATIONS

EXPERIMENTAL AND THERAPEUTIC MEDICINE 19: 451-458, 2020

Comparison of four different internal fixation methods in the treatment of distal clavicle fractures

LIANG LI*, HONGXIAO WU*, PEICHAO JIANG, XIAOCHUAN HAN, SHIYUAN CHEN and XUEZHONG YU

Department of Orthopaedics, Dongying People's Hospital, Dongying, Shandong 257091, P.R. China

Received March 15, 2019; Accepted August 8, 2019

DOI: 10.3892/etm.2019.8233

Abstract. This study compared the clinical efficacy of four internal fixation methods in the treatment of distal clavicle fractures, in an effort to guide appropriate selection and application in the clinic. Eighty-four patients with distal clavicle-comminuted fractures were treated with a distal clavicle anatomic plate (group A), clavicular hook plate (group B), double-plate vertical fixation (group C), or T-shaped steel plate internal fixation (group D). The Constant-Murley scoring system was used to evaluate the shoulder joint function. The fracture healing time, VAS, and postoperative complications were compared and analyzed among the four groups. According to the Constant-Murley evaluation standard, the excellent and good rates of the four groups were 94.4, 73.1, 95 and 80% in groups A-D, respectively. The excellent and good rates of Constant-Murley evaluation standard in groups A and C were significantly better than those in groups B and D ($P<0.05$). VAS in the distal clavicle anatomic plate group (group A), double-plate vertical fixation group (group C), and T-shaped steel plate internal fixation group (group D) were significantly better than the clavicular hook plate group (group B) ($P<0.05$). The incidence of postoperative complications in the clavicular hook plate group (group B) was 15.4% and in the T-shaped steel plate internal fixation group (group D) was 15%, which were significantly higher than those of the distal clavicle anatomic plate group (group A) and double-plate vertical internal fixation group (group C) ($P<0.05$). The treatment of distal clavicle fractures using either one of the four internal fixation techniques can obtain better clinical results. The distal clavicle anatomic plate and double-plate vertical internal fixation techniques are associated with a decreased incidence of shoulder pain, an increase in the range of motion of the shoulder, and a reduction in complications, and thus, are preferable for the early functional recovery of limbs.

Correspondence to: Dr Xiaochuan Han or Dr Shiyuan Chen, Department of Orthopaedics, Dongying People's Hospital, 317 Nanyi Road, Dongying, Shandong 257091, P.R. China
E-mail: zlg198122@163.com
E-mail: ly198355@163.com

*Contributed equally

Key words: clavicle, fracture fixation, bone plates, dual plate

Introduction

Due to its subcutaneous location, clavicle is one of the bones that are most frequently fractured in the upper body due to car accidents and sports trauma. The incidence of distal clavicle fractures accounts for 12-21% of all clavicular fractures (1). Distal clavicle fractures are typically attributed to a direct blow to the point of the shoulder or a fall on an outstretched hand. In Craig class II type II and class II type V fractures of the distal one-third which are unstable fractures, the force of the sternocleidomastoid muscle moves the proximal fragment upward and the weight of the arm moves the distal fragment downward; these forces cause displacement and difficulty in maintaining reduction with conservative treatment. Although non-surgical strategies can be effective for the treatment of Craig class II type II and class II type V fractures of the distal one-third, they lead to higher rates of non-union. Non-union is painful and symptomatic, which has made many to suggest a series of early surgical treatments of Craig class II type II and class II type V fractures of the distal one-third of the clavicle (2). Early surgical treatments have been developed in order to reduce the complication rate of bone resorption, prominent deformity, and improve the functional outcome. The unstable fractures seem to represent a challenge because of the loss of the attachment of the coracoclavicular ligaments to the clavicle.

In recent years, a variety of methods of surgical fixation to treat these unstable fractures have been reported, including the distal clavicle anatomic plate, clavicular hook plate, double-plate vertical fixation, and T-shaped steel plate internal fixation, which provide rigid fixation and good bony union rates. With the extensive use of the surgical fixation, the fracture healing rate and functional recovery have improved; however, there is no current consensus regarding which method is the most suitable. None of the internal fixation techniques described has been characterized as the 'gold standard'. Choosing among these four internal fixators is still controversial. Each of these treatment modalities has its advantages and disadvantages. All these four surgical methods could provide good functional results for patients according to

our clinical experience. However, there is no previous report on their comparison in the literature reviews.

From January 2015 to May 2017, a total of 84 patients with distal clavicle Craig class II type II and class II type V fractures were treated with a distal clavicle anatomic plate, clavicular hook plate, double-plate vertical fixation, or T-shaped steel plate internal fixation. The aim of this study was to retrospectively evaluate the clinical results and compare the efficacy of these four surgical methods for the treatment of acute unstable distal clavicle fractures. A retrospective analysis of the patient data was carried out.

Patients and methods

General information. Complete data of 84 patients with Craig class II type II and class II type V fractures of the distal one-third of the clavicle, treated with four types of internal fixation methods, from January 2015 to May 2017, were analyzed retrospectively. Of the 84 patients, 54 were males and 30 were females, 52.6±28.4 years of age. The causes of injury were as follows: Traffic injury, 47 cases; and fall injury, 37 cases. The fracture classification according to Craig was as follows: Class II type II, 70 cases; and class II type V, 14 cases. The appropriate internal fixation method was selected based on the length of the distal clavicle fracture fragment on X-ray pre-operatively. Four patients with comminuted fractures and distal fractures <0.5 cm in length underwent double-plate vertical fixation. The remaining cases were sequentially divided into four groups based on the internal fixation method used, as follows: Distal clavicle anatomic plate fixation group (group A), 18 cases; clavicular hook plate internal fixation group (group B), 26 cases; double-plate vertical fixation group (group C), 20 cases; and T-shaped steel plate internal fixation group (group D), 20 cases. There were no significant differences in sex, age, Craig classification of fracture, cause of injury, and time from injury to operation among the four groups (P>0.05, Table I).

The study was approved by the Ethics Committee of Dongying People's Hospital (Dongying, China). Patients who participated in this research had complete clinical data. Signed informed consents were obtained from the patients or their guardians.

Operative method. All of the operations were performed by the same group of physicians.

Distal clavicle anatomic plate fixation group (group A): A transverse incision over the distal clavicle was made to expose the distal clavicle without completely exposing the acromioclavicular joint and removing soft tissue. After reduction of the fracture, the anatomic plate of the distal clavicle was imbedded. According to the length of the distal end of the fracture, 3-6 locking screws (2.7 mm) were selected and the proximal end was fixed with three-to-four 3.5-mm locking screws. The locking screw did not enter the acromioclavicular joint space. For comminuted fractures of the distal clavicle, the fracture was fixed with coarse silk thread with upper and lower annular banding (Fig. 1).

Clavicular hook plate internal fixation group (group B): An incision was made along the distal surface of the clavicle to the acromion, the distal clavicle was exposed, a clavicle hook plate of appropriate length was selected and pre-bent. The clavicle hook was inserted into the lower rear part of the acromion, and the plate was placed close to the clavicle. Holes were then drilled along the proximal and distal ends of the clavicle. The distal clavicle comminuted fracture was fixed with screws after reduction and absorbable line was used to bundle up when fixation was not possible (Fig. 2).

Double-plate vertical internal fixation group (group C): The fracture end was exposed in layers by a transverse incision above the clavicle. After reduction of the fracture, two microplate systems (2.0 mm or 2.5 mm T or L type) were implanted in the superior and anterior clavicle according to the length from the fracture line to the articular surface. Screws were selected to fix the distal and proximal ends of the fracture. For comminuted fractures of the distal clavicle, it was not necessary to fully expose the acromioclavicular joint, which could be strapped with absorbable non-invasive sutures or temporarily fixed with Kirschner needles. The plate could be bent and shaped according to the condition of the fracture to enhance attachment to the clavicle profile, and the distal end of the fracture was fixed with at least 3 screws (Fig. 3).

T-shaped steel plate internal fixation group (group D): A direct incision from the distal clavicle to the acromion was made, ~5-6 cm in length, layer-by-layer. The fracture end of the clavicle and the acromioclavicular joint were exposed, the acromioclavicular ligament was protected, one Kirschner needle was inserted into the acromioclavicular joint, and screw penetration was avoided into the acromioclavicular joint. The size of the distal fracture bone was inspected and determined whether or not the fracture was comminuted. The distal bone mass was confirmed to be fixed with at least 3 screws to reset the fracture end. According to the fracture line, the straight T or oblique T-shaped steel plate was selected intraoperatively, and the plate was placed above the clavicle. The suitable length screw was twisted after drilling the hole. At least 3 screws were screwed in the distal end of the clavicle and 3-4 cortical screws were screwed into the proximal end of the clavicle (Fig. 4).

Postoperative management. Patients in each group were treated with wrist bands to acockbill shoulder joints. Functional activities, such as forearm rotation and elbow flexion and extension, were performed 6 h postoperatively. Functional exercises, such as anteflexion, back extension, and shrugging of the upper limbs, were performed 1 week postoperatively. Proper lifting exercises were performed 3 weeks postoperatively. The full range of non-load-bearing activities were gradually restored 6 weeks postoperatively, 1 and 3 months postoperatively, and every 3 months thereafter. A radiograph was obtained to observe the fracture healing and gradually complete weight bearing.

Postoperative evaluation. The operative time, amount of intraoperative bleeding, cost of hospitalization, time of fracture healing, and the occurrence of postoperative complications were recorded. The fracture healing standard was an X-ray showing a fuzzy fracture line with continuous callus formation. VAS was used to evaluate pain intensity. At the last follow up, the Constant-Murley evaluation criteria were used to comprehensively evaluate the general curative effect on the postoperative shoulder joint according to the clinical curative

Table I. Comparison of preoperative general data among the four groups of patients.

Group	No.	Sex		Age (years)	Craig fracture classification		Cause of injury		Time from injury to operation (days)
		Male	Female		Class II type II	Class II type V	Traffic injury	Fall injury	
Group A	18	11	7	55.2±16.3	15	3	8	10	3.4±2.9
Group B	26	16	10	51.7±17.1	22	4	13	13	3.2±3.1
Group C	20	14	6	51.9±20.3	16	4	14	6	3.4±2.7
Group D	20	13	7	47.8±15.1	17	3	12	8	3.4±3.2
χ^2/F value	-	0.328		0.129	3.216		2.168		4.286
P-value	-	0.628		0.746	0.168		0.348		0.251

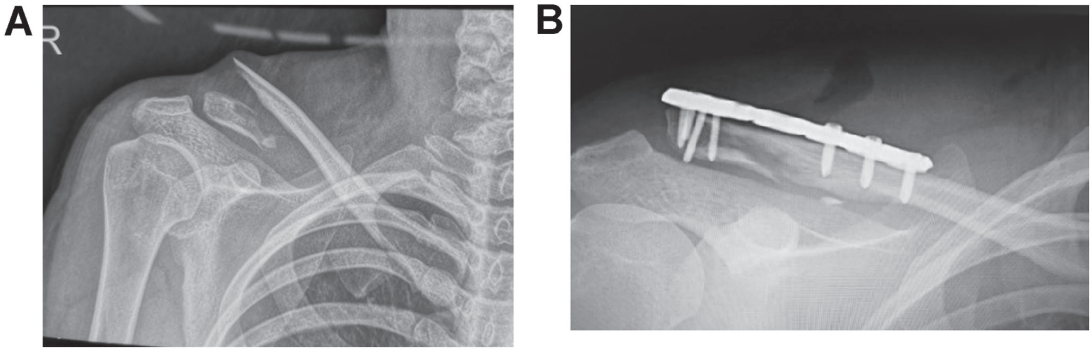

Figure 1. Male, 44 years of age, with closed fracture of right distal clavicle caused by falling injury. (A) Preoperative clavicular radiography shows Craig class II type II fracture of left distal clavicle. (B) The clavicular radiography at 3 days after operation shows that the fracture was fixed with an anatomic plate of distal clavicle.

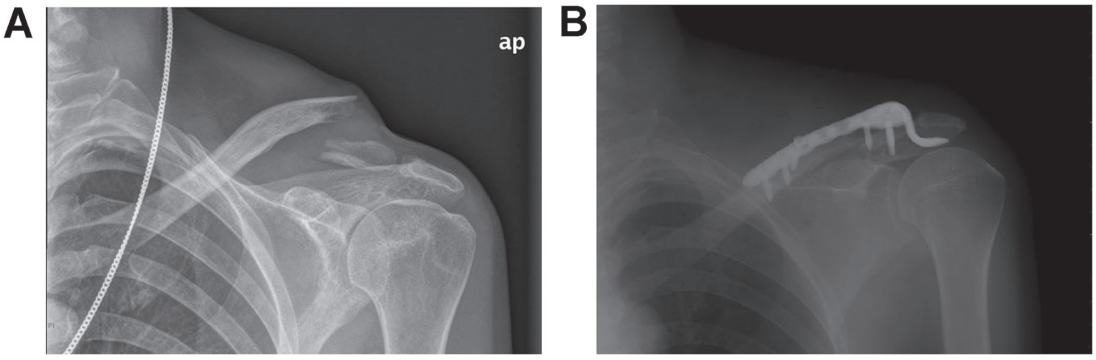

Figure 2. Female, 39 years of age, with closed fracture of left distal clavicle caused by a traffic accident. (A) Preoperative clavicular X-rays shows Craig class II type II fracture of left distal clavicle. (B) The clavicular radiography at 3 days after operation shows that the fracture was fixed with clavicular hook plate.

effect and imaging results, which were classified as excellent, good, moderate, or poor. The postoperative complications in each group were recorded and compared.

Statistical analysis. SPSS 13.0 statistical software (SPSS, Inc.) was used to statistically analyze the data expressed as the mean ± SD. Normally distributed data were analyzed using analysis of variance. If the difference was statistically significant, then the SNK-q post hoc test was used to carry out a pairwise comparison. Enumeration data of the four groups were compared by χ^2 test or Fisher's exact probability method. P<0.05 was considered to indicate a statistically significant difference.

Results

Comparison of preoperative general data. Because of comminuted fractures and poor distal screw holding, 2 patients scheduled to undergo double-plate fixation were treated with clavicular hook plates. Eighteen patients underwent distal clavicular anatomical plate internal fixation, 26 patients had clavicular hook plate internal fixation, 20 patients had

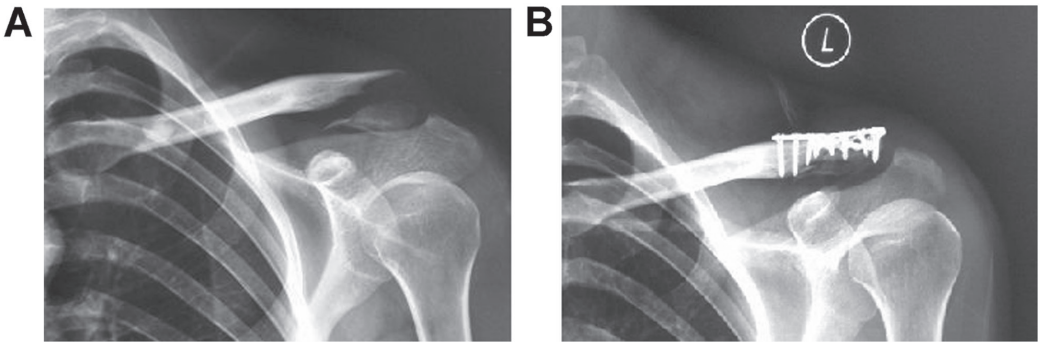

Figure 3. Female, 32 years of age, with closed fracture of left distal clavicle caused by a traffic accident. (A) Preoperative clavicular radiography shows Craig class II type II fracture of left distal clavicle. (B) The clavicular radiography at 2 months after operation shows that the fracture was fixed with double mini plate.

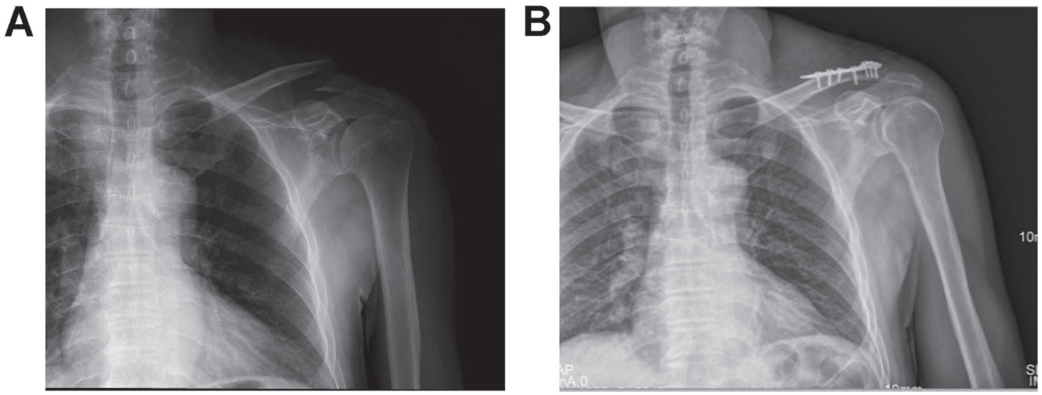

Figure 4. Male, 32 years of age, with closed fracture of left distal clavicle caused by falling injury. (A) Preoperative clavicular radiography shows Craig class II type II fracture of left distal clavicle. (B) The clavicular radiography at 3 days after operation shows that the fracture was fixed with T-shaped steel plate.

double-plate vertical internal fixation, and 20 patients underwent T-shaped steel plate internal fixation. The 84 patients were followed up for 13-19 months (average, 17.2 months). There was no significant difference in age, sex, fracture type, and time from injury to operation in the four groups (P>0.05; Table I).

Comparison of intraoperative indexes and postoperative fracture healing time. There was no significant difference in the operative time, intraoperative blood loss, hospitalization cost, and fracture healing time among the four groups (P>0.05; Table II).

Comparison of VAS in the four groups of patients. VAS for the distal clavicle anatomic plate group (group A), double-plate vertical fixation group (group C), and T-shaped steel plate internal fixation group (group D) was significantly better than the clavicular hook plate group (group B) (P<0.05; Table III).

Comparison of Constant-Murley score and incidence of postoperative complications in the four groups of patients. Evaluation of shoulder function according to the Constant-Murley criteria was as follows: The distal clavicle anatomic plate group (group A) was classified as excellent (12 cases), good (5 cases), moderate (1 case), and poor (0 cases), with an excellent and good rate of 94.4%; the clavicular hook plate group (group B) was classified as excellent (8 cases), good (11 cases), moderate (5 cases), and poor (2 cases), with an excellent and good rate of 73.1%; the double-plate vertical internal fixation group (group C) was classified as excellent (13 cases), good (6 cases), moderate (1 case), and poor (0 cases), with an excellent and good rate of 95%; and the T-shaped steel plate internal fixation group (group D) was classified as excellent (12 cases), good (4 cases), moderate (3 cases), and poor (1 case), with an excellent and good rate of 80%. The excellent and good rates for the double-plate vertical internal fixation (group C) and distal clavicle anatomic plate fixation group (group A) were significantly better than those of the the clavicular hook plate group (group B) and T-shaped steel plate internal fixation group (group D). There were significant differences in the Constant-Murley scores between various follow-up periods postoperatively (P<0.05; Table IV).

None of the patients in the four groups had complications, such as wound infections, fractures around the plate, and fractures of the plate. In the clavicular hook plate group (group B), 3 patients had osteoarthritis and 1 patient had shoulder pain. One patient in the double-plate vertical internal fixation group (group C) and 3 patients in the T-shaped steel plate internal fixation group (group D) had early removal of nails. The incidence of postoperative complications in the clavicular hook plate group (group B) was 15.4% (4/26) and in the T-shaped steel plate internal fixation group (group D) was 15% (3/20), significantly higher than those in the distal clavicle anatomic plate group (group A) and double-plate vertical internal fixation group (group C).

Table II. Comparison of intraoperative indexes and postoperative fracture healing time in the four groups of patients.

Group	No.	Operative time (min)	Intraoperative bleeding (ml)	Hospitalization expenses (x10,000 CNY)	Fracture healing time (weeks)
Group A	18	42.3±20.5	25.4±10.9	1.1±0.8	22.7±3.2
Group B	26	41.8±12.4	21.8±12.6	1.1±0.1	22.2±5.1
Group C	20	47.7±26.3	28.1±12.2	0.9±0.2	22.4±2.8
Group D	20	41.2±15.7	24.3±11.5	1.1±0.2	23.1±3.5
F value	-	2.364	4.218	2.549	4.878
P-value	-	0.246	0.194	0.159	0.243

Table III. Comparison of VAS at 2 and 6 months after operation, 1 week before the removal of internal fixation, and at the last follow up in the four groups of patients.

	VAS			
Group	2 months after operation	6 months after operation	1 week before removal of internal fixation	Last follow up
Group A	5.92±0.32[a]	2.32±0.22[a]	1.43±0.24[a]	1.21±0.11[a]
Group B	6.74±0.26	2.89±0.28	1.73±0.21	1.54±0.11
Group C	5.82±0.46[a]	2.41±0.26[a]	1.44±0.46[a]	1.30±0.24[a]
Group D	5.95±0.46[a]	2.58±0.58[a]	1.55±0.42[a]	1.33±0.28[a]
F value	2.186	5.274	1.628	1.862
P-value	0.038	0.026	0.028	0.022

[a]P<0.05, compared with clavicular hook plate group (group B).

Table IV. Comparison of Constant-Murley score at 2 and 6 months after operation, 1 week before the removal of internal fixation, and at the last follow up, and incidence of postoperative complications in the four groups of patients.

	Constant-Murley score				
Group	2 months after operation	6 months after operation	1 week before removal of internal fixation	Last follow up	Total occurrence of complications [n (%)]
Group A	75.2±5.3[a,b]	77.4±5.2[a,b]	82.2±4.1[a,b]	89.9±2.8[a,b]	0[a,b]
Group B	62.9±4.1	72.1±3.4	77.1±5.3	83.1±5.6	4 (15.4)
Group C	76.1±6.4[a,b]	78.1±4.6[a,b]	83.3±3.6[a,b]	90.2±4.4[a,b]	1 (5)[a,b]
Group D	72.5±4.4[a]	75.1±5.3[a]	80.7±3.7[a]	88.3±2.47[a]	3 (15)
F value	4.216	6.002	5.024	3.906	
P-value	0.00086	0.00074	0.00062	0.00048	

[a]P<0.05, compared with clavicular hook plate group (group B); [b]P<0.05, compared with T-shaped steel plate internal fixation group (group D).

Discussion

Among the fractures involving the distal one-third of the clavicle, Craig class II type II and class II type V fractures most often involve the ligamenta coracoclaviculare and acromioclavicular joint. Fracture non-union, acromioclavicular joint dysfunction, and other complications of conservative treatment are relatively high (3). The purpose of surgical treatment is to stabilize the distal clavicle, to avoid non-union of the fracture, to allow early functional exercise, and to reduce complications (4).

Advantages and disadvantages of the four internal fixation methods and selection of indications. The clavicular hook plate is a dynamic internal fixation, the main principle of which is that the lateral tip hook is inserted under the acromion along the posterior edge of the acromioclavicular joint, while the

medial plate is fixed on the clavicle. The clavicular hook plate forms a sustained and stable lever that lifts up the acromion and presses down the clavicle to reset and fix the displaced distal clavicle fracture, minimizes the movement of the distal end of the fracture, and does not interfere with the rotation of the clavicle. This fixation is widely used in the treatment of distal clavicle fractures (5). The mechanical distribution of the clavicular hook plate is uneven, and the stress near the acromioclavicular joint is greater. Therefore, after reduction and fixation the distal clavicle tends to sink and undergo excessive reduction, which affects the therapeutic effect (6). For elderly patients with osteoporosis, the brittleness of bone is increased and the clavicle in contact with the medial end of the hook plate is prone to stress fractures. Loose bone will also reduce the holding power of screws and it is easy to lose screws, resulting in failure of internal fixation. Therefore, use of the clavicle hook plate should be performed with caution in elderly patients (7). Application of the clavicle hook plate to juvenile patients with immature bone may interfere with the normal development of the acromion and cause permanent damage to the acromion. Therefore, the age of the patients should be considered first when selecting the clavicle hook plate for internal fixation. The appropriate depth of the clavicle hook plate and appropriate bending of the hook plate can be chosen intraoperatively to avoid excessive lifting up of the acromion, and to reduce lifting stress of the hook tip acting on the acromion, subacromial bone erosion, and the occurrence of subacromial impingement.

The distal clavicle anatomic plate design of the distal end of the plate is a 2.7-mm small locking screw with a double row of six different directions with 2.7- and 3.5-mm screw systems in the distal anterolateral clavicle. There is no significant difference in bone holding force (8). Therefore, as long as the distal clavicle has a bone block 2 cm in length, even if the fracture block is comminuted, >3 locking screws can be used with the screws in different directions to stabilize the fracture. There is a gap between the plate and periosteum after the distal anterolateral clavicle plate is placed, and there is no compression of bone and periosteum, which reduces the compression of the periosteum and the destruction of local blood circulation, and provides a good environment for the fracture to the maximum extent (9). The distal clavicle anatomic plate in the distal anterolateral clavicle does not involve the acromioclavicular joint, there is no interference and stress on the acromion and the rotator cuff, and no complications, such as subacromial bone resorption, impingement, and rotator cuff injury, will arise (10). The passive motion of the joint is not limited postoperatively, and early functional exercise creates a good condition for recovery of shoulder joint function. To our opinion, for patients with a distal clavicle fracture >2 cm the anterolateral clavicle fixation with a distal clavicle anatomic plate can be considered.

Miniature steel plates can provide a reliable control effect for comminuted bone with different direction screws and reliable fixation for comminuted bone. The vertical placement of double steel plates on two mutually 90˚ planes to form a beam structure also increases the fastness of the flattened frame structure at the distal end of the clavicle. The miniature steel plate is thinner and smaller, which ensures that there is enough space to implant two plates above and in front of the distal clavicle fracture and vertical fixation to achieve anatomic reduction. There are at least 3 screws fixed in the vertical plane in the distal clavicle (11). After the double miniature steel plate has been shaped and bent, the plate can be fitted well to the clavicle to achieve firm fixation, and the anatomic position of the fracture end can be maintained effectively; the occurrence of bone disunion, loosening, and fracture of the plate can be reduced (12). The distal end does not involve the acromioclavicular joint and has no interference and stress on the acromion. It will not lead to compressive bone absorption and impact of the subacromial bone nor cut the rotator cuff to cause injury. The cost of vertical internal fixation with a double plate is the lowest of the four methods, and double plate improves the stability of fixation, effectively reduces internal fixation failure and reduction, provides biological conditions for stable bone healing, and creates conditions for early postoperative rehabilitation and exercise (13). For patients with a small length of distal clavicle fracture, a double miniature steel plate fixation should be considered.

Because the T-shaped steel plate at the distal end of the radius is thin and easy to shape, the distal clavicle is slightly intamescentia, flat, and the clavicle is not loaded, thus the treatment of distal clavicular fractures with this plate cannot only fix the end of the fracture, but also it does not interfere with the acromioclavicular joint and the perioperative soft tissue injury is also small. A multi-directional locking nail could provide a stable fixation for the distal end of the fracture (14). Moreover, because the T-shaped steel plate is thinner, occupies less space, and the clavicle tissue is looser. If the patient does not request removal due to discomfort, the plate can remain *in situ* after fracture healing, which can reduce the pain of a second operation and alleviate the economic burden. Because of the design problem of the T-shaped plate in the distal radius, it is impossible to fix all the locking holes in different directions at the outboard end of the distal radius with locking screws at the same time. Therefore, it is easy to lose the screws when the locking holes are fixed with ordinary screws.

Comparison of postoperative complications. The incidence of postoperative complications in the clavicular hook plate group (group B) was 15.4%, and in the T-shaped steel plate internal fixation group (group D) was 15%, significantly higher than the distal clavicle anatomic plate group (group A) and double-plate vertical internal fixation group (group C) ($P<0.05$). In the clavicular hook plate group (group B), 3 patients had osteoarthritis after the plate was removed, and 1 patient had shoulder pain and other clinical symptoms. The appearance of osteoarthritis after the removal of the clavicular hook plate is closely related to the principle of leverage of the clavicular hook plate. The clavicle hook plate contacts the acromion through the hook tip, so the bone surface of the acromion is the concentration point of the lever stress. The pressure caused by lifting up the hook tip and the friction formed by the movement of the tip on the acromial surface will result in absorption and abrasion of the subacromial bone. There will be imaging signs of osteoarthritis at the hook tip of the removed hook plate (15). In addition to choosing a clavicle hook plate of suitable depth during surgery, an appropriate shape of the hook plate can be made so that the hook tip can fit completely under the shoulder peak, thus avoiding excessive lifting of the acromion (16). In the clavicular hook plate group (group B), shoulder

pain occurred in 1 patient postoperatively. The subacromian space was narrower in this patient. It was considered that stimulating the bursae synovialis of the acromium during the insertion of the hook plate might have caused synovitis. Compression of the supraspinatus muscle may have resulted in subacromial impingement. In the T-shaped steel plate group (group D), early de-nailing occurred in 3 patients postoperatively. Considering that the original intention of designing the T-shaped steel plate was not according to the anatomic structure of the clavicle, it was easy for the patients with small distal clavicle fractures to be unable to use locking screws completely. In the patients who choose to use the T-shaped steel plate the distal radius can be molded according to the shape of the distal clavicle fracture block during the operation.

Comparison of postoperative functional recovery. The long-term functional recovery of the distal clavicle anatomic plate group (group A), the double-plate vertical internal fixation (group C), and the distal radius T-shaped steel plate internal fixation group (group D) was significantly better than the clavicular hook plate group (group B) ($P<0.05$). The distal anatomic clavicle plate, double-plate vertical internal fixation, and T-shaped steel plate of the distal radius do not involve the acromioclavicular joint, and do not produce interference and stress of the acromion, avoiding the occurrence of osteoarthritis and impingement in subacromial iconography, and no damage to the acromion sac and supraspinatus muscle occurs. The early stability of the T-shaped steel plate of the distal radius was significantly worse than the distal clavicular anatomic plate and double-plate vertical fixation. Therefore, the early functional exercise of the shoulder joint in the T-shaped steel plate of the distal radius (group D) was worse than in the distal clavicular anatomic plate (group A) and double-plate vertical internal fixation group (group C).

Shortcomings of this study. i) It was considered that two patients with fractures were unable to use at least 3 screws to fix the distal clavicle fracture block and to be switched to the clavicular hook plate. ii) This study was a retrospective analysis, however, the patients underwent a non-randomized selection of pre- and intra-operative procedures. There were numerous patients with fractures who received clavicular hook plates, and there was a selection bias in the internal fixation options, which may be one of the reasons for the poor efficacy of the clavicular hook plate group. iii) In recent years, the use of a double-button steel plate for the treatment of Neer II type fractures has been gradually applied to clinical practice. The operation is relatively simple, does not involve the acromioclavicular joint, does not interfere with the subacromial space, and does not damage the rotator cuff. Moreover, the procedure reduces postoperative shoulder pain and the button steel plate is small in size. Compared with the hook and locking plates, the built-in object is not obvious and more cosmetic. There is no need for secondary surgery to remove the double-button steel plate, however, complications including intraoperative coracoid process fracture, non-union and delayed union have been observed (17). Rieser *et al* (4) conducted biomechanical experiments and confirmed that the mechanical strength of the button steel plate or locking plate fixation was significantly lower than the button steel plate combined with locking plate fixation. The fixed stability of this procedure is to be further studied in later biomechanical experiments. iv) In this study, the sample size was small, and therefore a randomized controlled study of a larger sample is needed to confirm the conclusions of this report.

In conclusion, all four methods were effective in the treatment of distal clavicle fractures. The distal clavicular anatomic plate and double-plate vertical internal fixation led to a decreased incidence of shoulder pain, increased the range of motion of the shoulder, and reduced complications. Hence, the distal clavicular anatomic plate and double plate vertical internal fixation are preferable for the early functional recovery of the limbs.

Acknowledgements

Not applicable.

Funding

No funding was received.

Availability of data and materials

The datasets used and/or analyzed during the present study are available from the corresponding author on reasonable request.

Authors' contributions

LL and HW were involved in the writing of the manuscript. LL made substantial contributions to the conception and design of the current study and gave final approval of the version to be published. PJ contributed to the design of the study. SC approved the version to be published, analyzed and interpreted the patient data regarding the distal clavicle fracture. XH and HW were involved in the conception of the study. XY contributed to the interpretation of the data. XH and SC were accountable for all aspects of the work in ensuring that questions related to the accuracy or integrity of any part of the work were appropriately investigated and resolved. All authors read and approved the final manuscript.

Ethics approval and consent to participate

The study was approved by the Ethics Committee of Dongying People's Hospital (Dongying, China). Patients who participated in this research had complete clinical data. Signed informed consents were obtained from the patients or their guardians.

Patient consent for publication

Not applicable.

Competing interests

The authors declare that they have no competing interests.

References

1. Gstettner C, Tauber M, Hitzl W and Resch H: Rockwood type III acromioclavicular dislocation: Surgical versus conservative treatment. J Shoulder Elbow Surg 17: 220-225, 2008.

2. Martetschläger F, Kraus TM, Schiele CS, Sandmann G, Siebenlist S, Braun KF, Stöckle U, Freude T and Neumaier M: Treatment for unstable distal clavicle fractures (Neer 2) with locking T-plate and additional PDS cerclage. Knee Surg Sports Traumatol Arthrosc 21: 1189-1194, 2013.
3. Oe K, Gaul L, Hierholzer C, Woltmann A, Miwa M, Kurosaka M and Buehren V: Operative management of periarticular medial clavicle fractures-report of 10 cases. J Trauma Acute Care Surg 72: E1-E7, 2012.
4. Rieser GR, Edwards K, Gould GC, Markert RJ, Goswami T and Rubino LJ: Distal-third clavicle fracture fixation: A biomechanical evaluation of fixation. J Shoulder Elbow Surg 22: 848-855, 2013.
5. Deng Z, Cai L, Ping A, Ai Q and Wang Y: Anatomical research on the subacromial interval following implantation of clavicle hook plates. Int J Sports Med 35: 857-862, 2014.
6. Gu X, Cheng B, Sun J and Tao K: Arthroscopic evaluation for omalgia patients undergoing the clavicular hook plate fixation of distal clavicle fractures. J Orthop Surg Res 9: 46, 2014.
7. Jou IM, Chiang EP, Lin CJ, Lin CL, Wang PH and Su WR: Treatment of unstable distal clavicle fractures with Knowles pin. J Shoulder Elbow Surg 20: 414-419, 2011.
8. Yoo JH, Chang JD, Seo YJ and Shin JH: Stable fixation of distal clavicle fracture with comminuted superior cortex using oblique T-plate and cerclage wiring. Injury 40: 455-457, 2009.
9. Johnston PS, Sears BW, Lazarus MR and Frieman BG: Fixation of unstable type II clavicle fractures with distal clavicle plate and suture button. J Orthop Trauma 28: e269-e272, 2014.
10. Andersen JR, Willis MP, Nelson R and Mighell MA: Precontoured superior locked plating of distal clavicle fractures: A new strategy. Clin Orthop Relat Res 469: 3344-3350, 2011.
11. Madsen W, Yaseen Z, LaFrance R, Chen T, Awad H, Maloney M and Voloshin I: Addition of a suture anchor for coracoclavicular fixation to a superior locking plate improves stability of type IIB distal clavicle fractures. Arthroscopy 29: 998-1004, 2013.
12. Sohn HS, Shin SJ and Kim BY: Minimally invasive plate osteosynthesis using anterior-inferior plating of clavicular midshaft fractures. Arch Orthop Trauma Surg 132: 239-244, 2012.
13. Bisbinas I, Mikalef P, Gigis I, Beslikas T, Panou N and Christoforidis I: Management of distal clavicle fractures. Acta Orthop Belg 76: 145-149, 2010.
14. Schliemann B, Roßlenbroich SB, Schneider KN, Petersen W, Raschke MJ and Weimann A: Surgical treatment of vertically unstable lateral clavicle fractures (Neer 2b) with locked plate fixation and coracoclavicular ligament reconstruction. Arch Orthop Trauma Surg 133: 935-939, 2013.
15. Lin HY, Wong PK, Ho WP, Chuang TY, Liao YS and Wong CC: Clavicular hook plate may induce subacromial shoulder impingement and rotator cuff lesion-dynamic sonographic evaluation. J Orthop Surg Res 38: 1461-1468, 2014.
16. Dou Q and Ren X: Clinical therapeutic effects of AO/ASIF clavicle hook plate on distal clavicle fractures and acromioclavicular joint dislocations. Pak J Med Sci 30: 868-871, 2014.
17. Cho CH, Jung JH and Kim BS: Coracoclavicular stabilization using a suture button device for Neer type IIB lateral clavicle fractures. J Shoulder Elbow Surg 26: 804-808, 2017.

This work is licensed under a Creative Commons Attribution-NonCommercial-NoDerivatives 4.0 International (CC BY-NC-ND 4.0) License.