

Post-arthroscopic osteonecrosis of the knee: A case report and literature review

ZE ZHUANG^{1*}, KISHOR CHHANTYAL^{2*}, YI SHI¹, QI ZHUANG³,
FEI ZHANG¹, DEHAI SHI¹, BO HE¹ and KUN WANG¹

Departments of ¹Joint Surgery and Orthopedic Trauma, ²Spine Surgery and ³Laboratory Medicine,
The Third Affiliated Hospital of Sun Yat-sen University, Guangzhou, Guangdong 510630, P.R. China

Received September 2, 2019; Accepted May 15, 2020

DOI: 10.3892/etm.2020.9056

Abstract. Post-arthroscopic osteonecrosis is a rare complication of arthroscopic surgery. The present study reported on a case of knee osteonecrosis after arthroscopic surgery. The patient, an 81-year-old male, presented with left knee pain and limited range of motion without any history of trauma. MRI revealed medial meniscus tear. Medial partial meniscectomy was performed using arthroscopy. The pain was found to be relieved due to the operation. However, there was an aggravation of pain after two months post-operatively. X-ray revealed that the subchondral bone in the medial femoral condyle (MFC) had collapsed. MRI revealed a large area of bone marrow edema in the MFC with cartilage delamination and subchondral flattening. Considering the age of the patient and the large area of bone necrosis, total knee arthroplasty was performed. At the 1-year follow-up, the Knee Society Knee Score improved from 44 points pre-operatively to 90 points and the Knee Society Functional Score was elevated from 35 to 90 points. Patient-reported outcome measures were assessed in the form of the Oxford Knee Score, which was 16. Furthermore, previous case reports of post-arthroscopic osteonecrosis were reviewed and the clinical and radiographic features, as well as the treatment, were summarized. If the patient complains of persistent and worsening pain after arthroscopy, particularly in elderly osteoporotic patients with meniscal tears or chondral lesions, the possibility of post-arthroscopic knee osteonecrosis should be considered. Diagnosis and treatment at the early stages are likely to be beneficial for the outcome.

Introduction

Post-arthroscopic osteonecrosis is a rare disease that may progress to end-stage osteoarthritis, which was first reported by Brahme *et al* (1) in 1991. In addition, it has been reported as 'post-meniscectomy', 'post-arthroscopy' or 'osteonecrosis in the post-operative knee' in later years (2-5). Santori *et al* (6) reported only two cases of osteonecrosis among >2,000 patients who underwent knee arthroscopy (0.2%). Pruès-Latour *et al* (7) reported 9 cases in 585 patients who underwent arthroscopic meniscectomies and were >50 years old (1.5%). Post-arthroscopic osteonecrosis is more likely to occur in elderly patients, without any sex bias. Nowadays, it is a rare condition and its morbidity remains elusive. However, compared with the large number of arthroscopic surgery performed worldwide every year, the number of reported cases of post-arthroscopic osteonecrosis is low.

The etiology of post-arthroscopic osteonecrosis remains elusive. Certain studies have suggested that it may be due to the effect of the heat generated by radiofrequency on the subchondral bone (8). Other studies have hypothesized that the mechanical shavers used may cause damage to the cartilage (9). Furthermore, certain studies have reported the lesion as a subchondral fracture (10). Another theory is that the increased biomechanical load in the medial compartment following medial meniscus resection may be the major reason (7).

The present study describes a case of post-arthroscopic knee osteonecrosis and delineation identified during surgery. In addition, a literature review was performed and the latest progress in the diagnosis and treatment of post-arthroscopic osteonecrosis was summarized. Finally, the present study aimed to provide additional details regarding the prevention and treatment of this disease.

Case report

An 81-year-old man suffered from left knee pain without any history of trauma for 3 months. The pain was aggravated by walking and the range of motion was indicated to be limited. The patient had a history of Parkinson's disease for 6 years and a history of hypertension and diabetes for >10 years. There was no history of sports injury, alcohol abuse or intra-articular steroid injections. The patient went to see the doctor at his

Correspondence to: Dr Bo He or Dr Kun Wang, Department of Joint Surgery and Orthopedic Trauma, The Third Affiliated Hospital of Sun Yat-sen University, 600 Tianhe Road, Guangzhou, Guangdong 510630, P.R. China
E-mail: 56273609@qq.com
E-mail: wangkunsums@163.com

*Contributed equally

Key words: post-arthroscopic osteonecrosis, knee, case report, review

local hospital in February 2018. His body mass index was $\sim 27 \text{ kg/m}^2$. Physical examination revealed no ligamentous instability. The tenderness was on the medial joint line on palpation and McMurray's test was positive. Conservative treatment, including non-steroidal anti-inflammatory drugs (NSAIDs) and a topical patch, was initiated for 1 month; however, this was ineffective. MRI was performed at the local hospital and revealed evidence of a medial meniscus tear with unremarkable articular chondral damage (Fig. 1). Arthroscopic surgery was performed under spinal anesthesia in March 2018. A tear in the posterior horn of the medial meniscus was identified. Subsequently, arthroscopic partial medial meniscectomy was performed using basket forceps and a shaver (Smith & Nephew) without any cartilage intervention. No radiofrequency or laser was used. The surgery lasted for ~ 40 min. NSAIDs were prescribed for 7 days postoperatively. He felt that the pain was relieved, therefore NSAIDs was not taken after 7 days. Although some of the pain that could not be relieved even after NSAIDs administration pre-operatively, the patient felt that the operation improved this condition initially. However, the pain in the left knee aggravated 1 month after arthroscopic surgery, with worsening of the symptoms as the activity level and weight-bearing increased. There was also swelling in the whole knee, which was different from the knee prior to the first surgery. Prior to the operation, the knee did not exhibit any swelling. The patient stated that he did not receive any steroid treatment and there was no injury after the primary surgery. Conservative treatment, including non-steroidal anti-inflammatory drugs (NSAIDs) and physiotherapy, as well as ice compressions, were administered for 2 months; however, this was ineffective.

Subsequently, the patient came to our hospital for further treatment in June 2018. The pre-operative MRI and X-ray were re-evaluated. The X-ray revealed collapse in the femoral medial condyle and narrowing of the joint space (Fig. 2). The pre-operative MRI revealed a large area of bone marrow edema (BME) in the medial femoral condyle with cartilage delamination and subchondral flattening. Recurrence of meniscal tear was not observed (Fig. 3).

Considering the patient was elderly (81 years) and the necrotic bone lesion area on MRI was large, treatments such as high tibial osteotomy (HTO) and arthroscopic core decompression and osteochondral autograft were not ideal for this patient. Therefore, it was decided to perform total knee arthroplasty (TKA). In addition, a metal prosthesis was prepared in case the bone defect would have been identified as too large during the surgery.

Surgical procedure. The patient received combined spinal and epidural anesthesia. Subsequently, the patient took a supine position and a tourniquet was fixed on the left thigh. The medial parapatellar approach was taken. During the surgery, it was identified that the cartilage of the left femur, tibia and patella was severely defaced and worn. The cartilage of the medial femur condyle was separated from the subchondral bone and had become soft and delaminated. The subchondral bone of the medial femoral condyle was found to be collapsed and necrotized. The size of the area of the lesion was $\sim 4 \times 2 \text{ cm}$ (Fig. 4). This was consistent with the pre-operative MRI findings. In addition, the anterior cruciate ligament was degenerated.

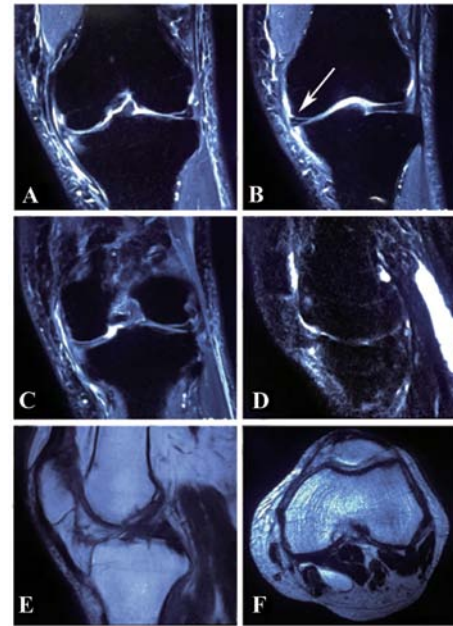


Figure 1. MRI prior to the first arthroscopic surgery. (A) Bone marrow edema in the lateral tibial plateau margin. (B) Horizontal high signal in the medial meniscus extending into the articular capsule of the meniscus, as indicated by the arrow, in the T2-weighted MRI coronal section implied the medial meniscus tear. (C) No evidence of osteonecrosis in the proximal tibia and distal femur. The patellofemoral facet had been degenerated (D) in the T2-weighted MRI and (E) T1-weighted MRI (figure E). (F) Cross-section of the distal femur. None of the coronal, sagittal and cross-sectional views of the pre-operative T1- and T2-weighted MRI exhibited any evidence of osteonecrosis of the medial femoral epicondyle prior to the arthroscopy surgery.

Subsequently, a tourniquet with a pressure of 250 mmHg was applied. All the lesions were debrided. Subsequently, the distal femoral and proximal tibia were correctly osteotomized and the irrigation pump was used. Then, the osteotomized cancellous bone was cut into a small bone mass and filled into the bone defect area of the femoral medial condyle without using the metal prosthesis pad. Finally, a posterior-stabilized knee prosthesis was implanted. The tourniquet time was 50 min. The entire surgery lasted ~ 85 min.

After the surgery, an X-ray revealed that the position of the prosthesis was good (Fig. 5). Histopathological analysis revealed osteonecrosis of the cartilage (Fig. 6). The patient received routine analgesia and anti-coagulant therapy post-operatively and was discharged from hospital 6 days post-operatively. At that time, the patient was able to walk without crutches. The Knee Society Knee Score improved from 44 points pre-operatively to 90 points at the 1-year follow-up post-operatively and the Knee Society Functional Score (11) increased from 35 to 90 points. Similarly, the Oxford Knee Score (OKS; patient-reported outcome measures) (12,13) was 16 at the 1-year follow-up. The OKS is a 12-item questionnaire, which evaluates the pain and function of the knee. The patient is currently pain-free in his left knee and satisfied with the knee function.

Systematic review

A review of relevant articles published between January 1995 and January 2019 was performed to compare the present results with those of previously published case reports in the PubMed,

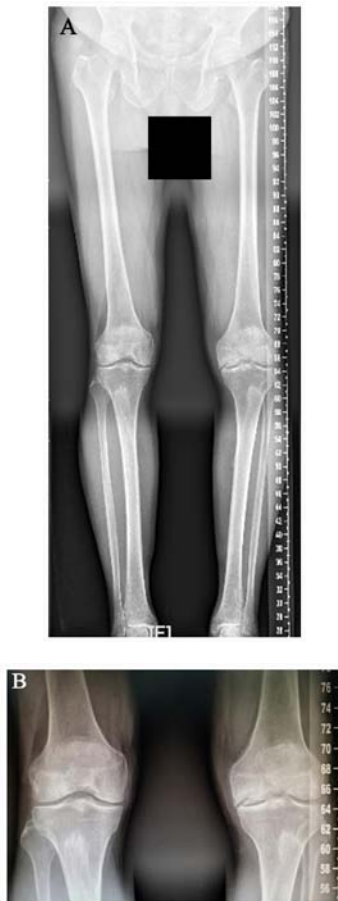

Figure 2. Long standing anteroposterior X-ray prior to the second surgery. (A) Compared with the right knee, the left knee became valgus because of the collapse of the medial femoral condyle. (B) The joint space of the left knee became narrow.

Web of Science and Cochrane Library databases. The keywords included 'arthroscopy', 'osteonecrosis', 'knee', 'meniscal tear', 'meniscal tears', 'meniscectomy', 'ACL reconstruction', 'radio-frequency' and 'chondroplasty' and nine reports matching the criteria were found (2,3,6,8,10,14-17). These reports included most of the existing studies between January 1995 and January 2019. Two authors (ZZ and KC) reviewed each paper separately to reach a consensus regarding data abstraction and article inclusion. Subsequently, the variables in the literature were compared with those of the present case. Table I lists the basic characteristics of the included studies.

Discussion

Arthroscopy is a useful method to treat various types of knee disorder (18). Countless arthroscopic surgeries are performed worldwide every year. Post-arthroscopic osteonecrosis is a rare complication of arthroscopy. It has been reported in patients who received arthroscopic knee surgery, particularly in patients undergoing meniscectomy. However, it may also occur in association with other types of arthroscopic surgery. Furthermore, a previous study has suggested that it may be a rare complication of the anterior cruciate ligament reconstruction (14). The most common location of necrosis is the medial femoral condyle, followed by the lateral femoral condyle,

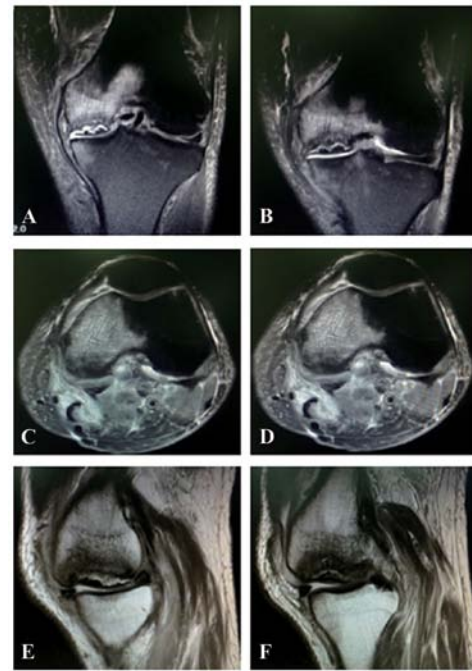


Figure 3. T2-weighted MRI images prior to the total knee arthroplasty surgery. (A) Coronal MRI through the intercondylar fossa: On imaging, the lesion was surrounded by a large hypointense area with diffuse bone marrow edema and collapse of the subchondral bone. (B) Coronal MRI through the post femoral condyle: On imaging the whole medial post femoral condyle was presented with diffuse bone marrow edema. (C) Sagittal MRI: On T2-weighted imaging, a large hypointense edematous area of the medial femoral condyle was observed, which was not present in the first MRI examination. (D) Another sagittal MRI on T2-weighted imaging showed the edematous area of the medial femoral condyle was larger and went through several sections. (E) The sagittal T2-weighted image revealed a crescent-shape area of low signal intensity indicating subchondral bone destruction within the medial femoral condyle. (F) The sagittal T2-weighted image showed the area of the subchondral bone destruction in the lateral femoral condyle became smaller than the medial femoral condyle.

whereas the lateral tibia, the medial tibial plateau and the patella are rarely affected.

The mechanism of post-arthroscopic osteonecrosis remains elusive. It has been hypothesized that alteration in the load distribution in the knee joint may be a cause of osteonecrosis. Meniscalplasty under arthroscopy has been demonstrated to be an effective method to relieve knee pain and improve the daily life of affected patients (19); however, the change in the knee biomechanics after meniscectomy may lead to higher tibiofemoral contact pressure. In addition, tears of the medial meniscal root are considered to increase the peak pressure of the femoral condyle more than that in the horizontal tears of the posterior horn. Under these conditions, it may lead to incomplete fracture of the cartilage and subchondral bone (10,15), followed by leakage of synovial fluid and subchondral collapse. These pathological changes may result in osteonecrosis of the knee. In certain circumstances, if there is pre-existing cartilage damage prior to arthroscopic surgery, the arthroscopic fluid may infiltrate into the pathologic area, which may aggravate the subchondral edema (7). Furthermore, manipulation during the arthroscopic surgery, including the use of laser or radiofrequency, that generates thermal energy, has been reported to potentially increase the risks of osteonecrosis (20,21). However, this remains to be further validated.

Table I. Ficat classification.

Stage	Description
0	This stage is preclinical and pre-radiographic
I	No radiographic evidence of knee osteonecrosis. The bone presents with no sclerosis and maintained curvature.
II	Signs of mottled sclerosis but the normal curvature of the bone remains intact.
III	The presence of a crescent sign is indicative of subchondral fracture, which defines this stage.
IV	Collapse of the subchondral bone.

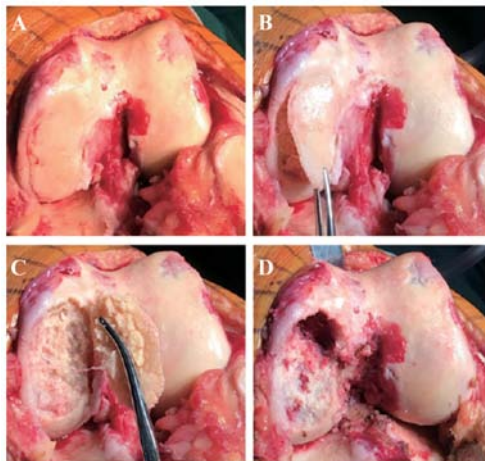


Figure 4. Intraoperative images. (A) The cartilage surface of the femur and the anterior cruciate ligament was severely degraded, worn and degenerated. (B and C) The medial condylar cartilage was separated from the subchondral bone, revealing that the subchondral osteonecrosis was collapsed and necrotized. The area of the lesion was ~4 cm x 3 cm in size. (D) There was a large inclusive bone defect in the medial femoral epicondyle after debridement of the necrotic bone.

In the present case, laser or radiofrequency treatment were not used. There are several possible reasons for the osteonecrosis observed in the present case. First, elderly individuals have a narrow medial joint space. Excessive intra-operative manipulation to expose the posterior horn of the medial meniscus may cause damage to the chondral lesions of the femoral condyle. Furthermore, excessive meniscal resection, particularly of the posterior horn of the meniscus, changes the mechanical distribution in the knee. In addition, osteoporosis, early post-operative weight-bearing and functional rehabilitation exercises increase the tibiofemoral pressure, which may accelerate the development of post-arthroscopic osteonecrosis. MRI is the most important tool for the diagnosis of post-arthroscopic osteonecrosis (22). In early necrotic stages, MRI T2-weighted imaging reveals a heterogeneous, non-specific, large area of BME in the meniscectomy compartment. Similarly, close to the BME, a line of low signal may be observed around the necrotic area. In the later stages of post-arthroscopic osteonecrosis, the bone sequestration exhibits a high signal rim accompanied by flattening of the femoral condyle.

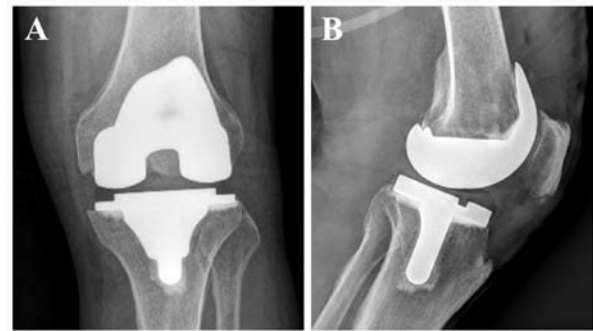


Figure 5. (A) Anteroposterior view and (B) lateral view of the X-ray after the total knee arthroplasty.

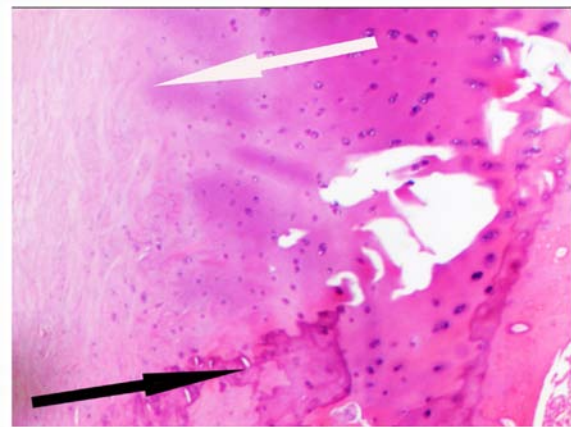


Figure 6. Histopathological analysis of the sample. H&E staining: The white arrowhead indicates osteonecrosis of the cartilage and the black arrow head points at the calcium deposition in the cartilage (magnification, x200).

Even though BME may be present in the post-operative MRI, it is absent in a pre-operative MRI in the early stages. The time interval ('window period') between the onset of osteonecrosis symptoms and a positive MRI finding should be addressed. The exact time interval remains to be determined. The 'window period' was defined based on an animal study previously performed by Nakamura *et al* (23), in which a canine model of femoral head osteonecrosis was established to demonstrate that ≥ 4 weeks was required to obtain positive MRI findings post-operatively. Johnson *et al* (2) and Türker *et al* (24) also regarded ≥ 6 weeks after symptom onset as the 'window period' to exclude the early stage of spontaneous osteonecrosis of the knee (SPONK). Therefore, ≥ 6 weeks was also chosen for the present study. This may be the differential diagnosis point between the early stage of the spontaneous osteonecrosis and post-arthroscopic osteonecrosis.

If a patient complains of persistently worsening knee pain following arthroscopy, a diagnosis of post-arthroscopic osteonecrosis should be considered. Post-arthroscopy osteonecrosis should be distinguished from secondary osteonecrosis, SPONK and recurrent meniscal tear (25,26). Secondary osteonecrosis has a multifactorial etiology, including trauma, chemotherapy, alcohol abuse and corticosteroid treatment. The patients are typically <45 years old and occurrence is more common in females than in males (26). Most cases of secondary osteonecrosis are bilateral and secondary osteonecrosis may also

Table II. Continued.

Author (year)	Cases (n)	Patient age (years), sex	Primary operation	ON location involved	Treatment	(Refs.)
Son (2013)	1	50, M	PMM	MFC	UKA	(17)
Faletti (2002)	1	66, M	Meniscal recontouring	MFC	Shock-wave therapy	(3)
Bonutti (2006)	19	Average 69 years; F (n=5) M (n=14)	5 Arthroscopy with associated laser treatment; 1 underwent a laser-assisted arthroscopy, 10 arthroscopy with associated radiofrequency treatment, 3 treated with a shaver and adjunctive microfracture surgery.	13 knees (68%) presented with distal femoral involvement, 2 knees (11%) had involvement of the proximal aspect of the tibia and 4 knees (21%) presented with both femoral and tibial involvement. The medial femoral condyle was involved in 14 knees; the lateral femoral condyle in 3 knees; the medial tibial plateau in 5 knees; and the lateral tibial plateau in 1 knee	UKA and TKA	(20)

CM, chondromalacia; CP, chondroplasty; F, female; G, grade; LFC, lateral femoral condyle; LMT, lateral tibial plateau; M, male; MFC, medial femoral condyle; MMT, medial meniscus tear; MTP, medial tibial plateau; OA, osteoarthritis; ON, osteonecrosis; PLM, partial lateral meniscectomy; PMM, partial medial meniscectomy; UKA, unicompartmental knee arthroplasty; TKA, tricompartmental knee arthroplasty.

involve other joints (26). Spontaneous osteonecrosis is idiopathic and it may be caused by chronic mechanical stress or a weight-bearing articular surface subjected to altered stresses as the result of subchondral fracture, or the progression of osteoarthritis. The patients are usually >50 years old and the female-to-male ratio is ~3:1. Spontaneous osteonecrosis is mainly unilateral and without the involvement of other joints (25). Post-arthroscopic osteonecrosis is associated with subchondral collapse with altered knee mechanics. Patients of any age may be affected and it occurs without sex bias (26,27). For secondary and spontaneous osteonecrosis, bone edema may be observed soon after the onset of symptoms. On the other hand, for recurrent meniscus tear, bone edema and epicondyle necrosis are not identified (26).

The treatment strategy should be based on the disease stage at which osteonecrosis is diagnosed. The Ficat classification was first applied to classify osteonecrosis of the femoral head. This classification system describes the different degrees of osteonecrosis (28). It has also been widely used to describe osteonecrosis of the knee (27,29,30). According to this system, osteonecrosis is divided into five stages. A description of the different stages is provided in Table II. The outcomes of post-arthroscopic osteonecrosis have a limited association with the size of the lesion, since even small bone marrow changes observed on MRI may lead to osteonecrosis.

Conservative treatment is used for patients whose lesions are still at the pre-collapse early stages (29). This treatment includes avoiding full weight-bearing, NSAIDs, bisphosphonates and hyperbaric oxygen treatment. Partial weight-bearing with crutches and taking NSAIDs for 4-8 weeks are usually recommended. Early surgical intervention is not recommended, since it may accelerate the damage to the joint. However, the success rate of conservative treatment is not satisfactory. Pape *et al* (27) reported 47 cases of post-arthroscopic osteonecrosis treated by conservative methods; however, only 3 cases exhibited improvement. Surgical treatment is reserved for patients with failed conservative treatment and late-stage lesions at the time of diagnosis (29).

For patients with Ficat stage I-II, there is pre-existing chondral bone collapse. The surgical methods include arthroscopic debridement, microfracture, bone grafting, core decompression, antegrade drilling, retrograde drilling and high tibial osteotomy (29). Arthroscopic debridement does not change the course of the disease. It is used only in patients who have mechanical symptoms due to unsteady chondral fragments or loose bodies. Microfractures or retrograde drilling are performed to stimulate revascularization within the lesion. However, this may damage the intact articular surface and it is not easy to locate the lesion accurately. Antegrade drilling or core decompression is another treatment method. It is regarded to be a better option than microfractures or retrograde drilling. Jacobs *et al* (31) was the first to report core decompression in stage-I and -II SPONK. They reported that seven cases of stage I and II with mild femorotibial alignment had good results. Bone grafting is beneficial in patients who have subchondral collapse and require restoration of the cartilage surface (32,33). After decompression is finished, bone grafting may be performed. Autogenic, allogenic cancellous bone or demineralized bone matrix are optional. HTO is considered for young, active individuals with early-stage osteonecrosis.

Since this is a joint-preserving technique, the weight-bearing axis may be transferred laterally so that the medial condyle is less affected. For patients with Ficat stage III-IV, since irreversible destruction occurred in the subchondral bone and articular cartilage and the lesion area is large, unicompartment knee arthroplasty (UKA) and TKA may be considered (26).

In the present case, the medial parapatellar approach was utilized. It would have been convenient to select UKA or TKA based on the range and depth of bone necrosis and the situation of anterior cruciate ligament during the surgery. The anterior cruciate ligament and the lateral femoral condyle were degenerated. In addition, the necrotic area of the medial femoral condyle was almost 8 cm² and the bone involvement was extended. If UKA had been chosen, the prosthesis coverage at the lesion would have been insufficient, which may have led to bone collapse around the prosthesis and prosthesis loosening, so TKA was the most viable option. In the present study, the visual osteonecrosis images and the findings during surgery were presented to learn more about the disease intuitively and the treatment procedure was illustrated. All of these are rarely presented in other case reports.

It is well-known that TKA is a common surgery option for patients with end-stage osteoarthritis; however, certain clinicians are concerned about its application in post-arthroscopic osteonecrosis due to poor bone quality.

To date, only few studies have reported on the long-term follow-up of arthroplasty for patients with post-arthroscopy osteonecrosis. Only one case report was identified in the literature search that described the follow-up outcome. In this study, Bonutti *et al* (20) reported 19 cases of post-arthroscopic necrosis treated by UKA (4 cases) or TKA (15 cases), and the midterm results with a mean follow-up of 62 months (range, 24-133 months). In their study, 95% of the patients had a Knee Society objective score of >80 points and the mean Knee Society objective score was 92 points. The follow-up period in the present case was just 1 year and the final outcome was good, which was consistent with the study by Bonutti *et al* (20). However, a longer follow-up period is required.

In summary, the treatment strategies should be dependent on the individual patient, including the necrosis stage and function of the other areas of the joint. Table I lists the features of previous studies on post-arthroscopic necrosis.

In conclusion, post-arthroscopic osteonecrosis is a rare event following arthroscopic surgery. For elderly patients, arthroscopy manipulation should be gentler and the amount of meniscectomy should be reduced. If the patient complains of persistent and worsening pain after arthroscopy, post-arthroscopic osteonecrosis should be suspected, particularly in elderly osteoporotic patients with meniscal tears or chondral lesions. Early diagnosis and treatment are important in the management of this condition. The prognosis of post-arthroscopic osteonecrosis is mostly associated with the timing of the diagnosis but not the size of the lesions.

Acknowledgements

Not applicable.

Funding

Not applicable.

Availability of data and materials

The datasets used during the present study are available from the corresponding author on reasonable request.

Authors' contributions

ZZ and KC contributed equally to the study. ZZ and KW conceived the study. ZZ and KC performed the literature search and wrote the manuscript. BH contributed to the interpretation of data and literature review. YS contributed to assembling the figures and the follow-up of the patient. QZ, FZ and DS collected and assembled the data. ZZ and DS contributed to the interpretation of data and the revision of the manuscript. All authors have read and approved the final manuscript.

Ethics approval and consent to participate

Not required due to the retrospective nature of the study.

Patient consent for publication

The patient provided consent for publication.

Competing interests

The authors declare that they have no competing interests.

References

- Brahme SK, Fox JM, Ferkel RD, Friedman MJ, Flannigan BD and Resnick DL: Osteonecrosis of the knee after arthroscopic surgery: Diagnosis with MR imaging. *Radiology* 178: 851-853, 1991.
- Johnson TC, Evans JA, Gilley JA and DeLee JC: Osteonecrosis of the knee after arthroscopic surgery for meniscal tears and chondral lesions. *Arthroscopy* 16: 254-261, 2000.
- Faletti C, Robba T and de Petro P: Postmeniscectomy osteonecrosis. *Arthroscopy* 18: 91-94, 2002.
- Kobayashi Y, Kimura M, Higuchi H, Terauchi M, Shirakura K and Takagishi K: Juxta-articular bone marrow signal changes on magnetic resonance imaging following arthroscopic meniscectomy. *Arthroscopy* 18: 238-245, 2002.
- Patel DV, Breazeale NM, Behr CT, Warren RF, Wickiewicz TL and O'Brien SJ: Osteonecrosis of the knee: Current clinical concepts. *Knee Surg Sports Traumatol Arthrosc* 6: 2-11, 1998.
- Santori N, Condello V, Adriani E and Mariani P: Osteonecrosis after arthroscopic medial meniscectomy. *Arthroscopy* 11: 220-224, 1995.
- Pruès-Latour V, Bonvin JC and Fritschy D: Nine cases of osteonecrosis in elderly patients following arthroscopic meniscectomy. *Knee Surg Sports Traumatol Arthrosc* 6: 142-147, 1998.
- Garino JP, Lotke PA, Sapega AA, Reilly PJ and Esterhai JL Jr: Osteonecrosis of the knee following laser-assisted arthroscopic surgery: A report of six cases. *Arthroscopy* 11: 467-474, 1995.
- Strauss EJ, Kang R, Bush-Joseph C and Bach BR Jr: The diagnosis and management of spontaneous and post-arthroscopy osteonecrosis of the knee. *Bull NYU Hosp Jt Dis* 69: 320-330, 2011.
- MacDessi SJ, Brophy RH, Bullough PG, Windsor RE and Sculco TP: Subchondral fracture following arthroscopic knee surgery: A series of eight cases. *J Bone Joint Surg Am* 90: 1007-1012, 2008.
- Insall JN, Dorr LD, Scott RD and Scott WN: Rationale of the Knee Society clinical rating system. *Clin Orthop Relat Res* 248: 13-14, 1989.
- Petersen CL, Kjærsgaard JB, Kjærsgaard N, Jensen MU and Laursen MB: Thresholds for Oxford Knee Score after total knee replacement surgery: A novel approach to post-operative evaluation. *J Orthop Surg Res* 12: 89, 2017.
- Ramkumar PN, Harris JD and Noble PC: Patient-reported outcome measures after total knee arthroplasty: A systematic review. *Bone Joint Res* 4: 120-127, 2015.
- Lansdown DA, Shaw J, Allen CR and Ma CB: Osteonecrosis of the knee after anterior cruciate ligament reconstruction a report of 5 cases. *Orthop J Sports Med* 24 3: 2325967115576120, 2015.
- Hall FM: Osteonecrosis in the postoperative knee. *Radiology* 236: 370-371, author reply 371, 2005.
- DeFalco RA, Ricci AR and Balduino FC: Osteonecrosis of the knee after arthroscopic meniscectomy and chondroplasty: A case report and literature review. *Am J Sports Med* 31: 1013-1016, 2003.
- Son JJ, Kim MK, Kim JY and Kim JG: Osteonecrosis of the knee after arthroscopic partial meniscectomy. *Knee Surg Relat Res* 25: 150-154, 2013.
- Li L, Wang H, He Y, Si Y, Zhou H and Wang X: Treatment of recurrent patellar dislocation via knee arthroscopy combined with C-arm fluoroscopy and reconstruction of the medial patellofemoral ligament. *Exp Ther Med* 15: 5051-5057, 2018.
- Shi Y, Tian Z, Zhu L, Zeng J, Liu R and Zhou J: Clinical efficacy of meniscus plasty under arthroscopy in middle-aged and elderly patients with meniscus injury. *Exp Ther Med* 16: 3089-3093, 2018.
- Bonutti PM, Seyler TM, Delanois RE, McMahon M, McCarthy JC and Mont MA: Osteonecrosis of the knee after laser or radiofrequency-assisted arthroscopy: Treatment with minimally invasive knee arthroplasty. *J Bone Joint Surg Am* 88 (Suppl 3): S69-S75, 2006.
- Cetik O, Cift H, Comert B and Cirpar M: Risk of osteonecrosis of the femoral condyle after arthroscopic chondroplasty using radiofrequency: A prospective clinical series. *Knee Surg Sports Traumatol Arthrosc* 17: 24-29, 2009.
- Lotke PA, Ecker ML, Barth P and Lonner JH: Subchondral magnetic resonance imaging changes in early osteoarthritis associated with tibial osteonecrosis. *Arthroscopy* 16: 76-81, 2000.
- Nakamura T, Matsumoto T, Nishino M, Tomita K and Kadoya M: Early magnetic resonance imaging and histologic findings in a model of femoral head necrosis. *Clin Orthop Relat Res*: 68-72, 1997.
- Türker M, Çetik Ö, Çırpar M, Durusoy S and Cömert B: Postarthroscopy osteonecrosis of the knee. *Knee Surg Sports Traumatol Arthrosc* 23: 246-250, 2015.
- Karim AR, Cherian JJ, Jauregui JJ, Pierce T and Mont MA: Osteonecrosis of the knee: Review. *Ann Transl Med* 3: 6, 2015.
- Di Caprio F, Meringolo R, Navarra MA, Mosca M and Ponziani L: Postarthroscopy Osteonecrosis of the Knee: Current Concepts. *Joints* 5: 229-236, 2017.
- Pape D, Seil R, Anagnostakos K and Kohn D: Postarthroscopic osteonecrosis of the knee. *Arthroscopy* 23: 428-438, 2007.
- Ficat RP: Idiopathic bone necrosis of the femoral head. Early diagnosis and treatment. *J Bone Joint Surg Br* 67: 3-9, 1985.
- Mont MA, Marker DR, Zywił MG and Carrino JA: Osteonecrosis of the knee and related conditions. *J Am Acad Orthop Surg* 19: 482-494, 2011.
- Kraenzlin ME, Graf C, Meier C, Kraenzlin C and Friedrich NF: Possible beneficial effect of bisphosphonates in osteonecrosis of the knee. *Knee Surg Sports Traumatol Arthrosc* 18: 1638-1644, 2010.
- Jacobs MA, Loeb PE and Hungerford DS: Core decompression of the distal femur for avascular necrosis of the knee. *J Bone Joint Surg Br* 71: 583-587, 1989.
- Duany NG, Zywił MG, McGrath MS, Siddiqui JA, Jones LC, Bonutti PM and Mont MA: Joint-preserving surgical treatment of spontaneous osteonecrosis of the knee. *Arch Orthop Trauma Surg* 130: 11-16, 2010.
- Tanaka Y, Mima H, Yonetani Y, Shiozaki Y, Nakamura N and Horibe S: Histological evaluation of spontaneous osteonecrosis of the medial femoral condyle and short-term clinical results of osteochondral autografting: A case series. *Knee* 16: 130-113, 2009.



This work is licensed under a Creative Commons Attribution-NonCommercial-NoDerivatives 4.0 International (CC BY-NC-ND 4.0) License.