

Short vs. long intramedullary nail systems in trochanteric fractures: A randomized prospective single center study

ȘERBAN DRAGOSLOVEANU^{1,2}, CHRISTIANA D.M. DRAGOSLOVEANU³,
DRAGOȘ C. COTOR² and CRISTIAN I. STOICA^{1,2}

¹Department of Orthopedics, 'Carol Davila' University of Medicine and Pharmacy, 050474 Bucharest;

²Department of Orthopedic Surgery, 'Foișor' Orthopedics-Traumatology and Osteoarticular TB Hospital, 030167 Bucharest;

³Department of Ophthalmology, 'Carol Davila' University of Medicine and Pharmacy, 050474 Bucharest, Romania

Received September 3, 2021; Accepted October 5, 2021

DOI: 10.3892/etm.2021.11029

Abstract. In unstable pertrochanteric fractures, there are still debates regarding the complications and long-term benefits after internal fixation using short or long cephalomedullary nails. Therefore, a study was developed regarding this idea. From May 2017 to April 2020, 61 patients with unstable (AO 31-A2) and intertrochanteric fractures (AO 31-A3) were surgically operated on. During follow-up, 8 patients were excluded (lost or deceased). A total of 26 patients received internal short nail system fixation and 27 received a long nail system. All cases followed the standard 6-week rehabilitation protocol. Follow-up was at 3, 6 weeks, 3, 6 and 12 months, and clinical and functional assessment were determined by a different surgeon using the Visual Analogue Scale (VAS), Harris Hip Score (HHS) and Functional Ambulation Categories (FAC). A total of 42 (79.2%) had a 31.A2 fracture (21 in the long nail group and 21 in the short nail group) and 11 (20.8%) had a 31.A3 fracture (6 in long nail group and 5 in the short nail group). Surgical time was significantly longer ($P<0.05$) in the long nail group (an average of 81.38 ± 12.01 min), compared with the short nail group (53.11 ± 8.36 min). Blood loss was significantly higher ($P<0.05$) in the long nail group (210 ± 12.1 ml) compared to the short nail group (75.4 ± 14.8 ml). No statistical differences were noted regarding tip-apex distance (TAD) and VAS score. At 6 months, HHS was better for the short nail group (84.76 ± 3.68) ($P<0.05$). Regarding the FAC scale, no significant statistical differences were identified. Cut-out occurred in 2 cases in the short nail group and 1 case from the long nail group. Only 1 peri-implant fracture occurred in a patient with a long cephalomedullary nail.

In conclusion, the long cephalomedullary nail requires a longer surgical time and is associated with an increase in intraoperative blood loss without improving the functional outcome after 12 months postoperatively. A larger sample of cases is required to thoroughly analyze the postoperative complications.

Introduction

Intertrochanteric fractures are common to elderly patients and show an increased morbidity and a higher risk of mortality, especially within the first year (1,2). According to the literature, over one-third of all hip fractures are intertrochanteric (3,4). The main goal of surgical treatment is to restore patient mobility. The ideal treatment allows immediate weight-bearing on the affected limb, but this requires an acceptable reduction and a secured fixation of the fracture. An early mobilization significantly decreases the risk of postoperative complications such as pneumonia, deep vein thrombosis, pulmonary embolism or death (5-7). In the last decade, cephalomedullary nailing has become the most popular surgical treatment for pertrochanteric fractures (8,9). The main benefit of the intramedullary nail is considered the early mobilization and the possibility of an aggressive rehabilitation.

There are still controversies around the long-term benefits and risk of complications after fixation using short or long cephalomedullary nails after unstable intertrochanteric fractures. Some studies report that the short nail does not provide an adequate diaphyseal fixation; thus, the risk of femoral fracture at the tip of the implant may be higher. On the other hand, with the newer nail designs available, this risk has significantly decreased (10-14).

Considering that in Romania there are not many articles regarding this subject, we aimed to conduct a study to compare the ambulatory function of patients with intertrochanteric fractures surgically fixed with either short or long cephalomedullary nails (Gamma 3 Nail, Stryker MedEd).

Correspondence to: Dr Christiana D.M. Dragosloveanu, Department of Ophthalmology, 'Carol Davila' University of Medicine and Pharmacy, 8 Eroii Sanitari Boulevard, 050474 Bucharest, Romania
E-mail: christianacelea@gmail.com

Key words: short intramedullary nail systems, long intramedullary nail systems, trochanteric fractures, hip, implant choice

Patients and methods

This randomized prospective single center study was conducted between May 2017 and April 2020 and 61 patients with unstable (AO 31-A2) and intertrochanteric fractures

(AO 31-A3) were included (Fig. 1). From the patients initially reviewed, 5 were lost during the follow-up and 3 were deceased before the first year of assessment; thus, they were excluded from our study. Patients with stable trochanteric fractures (AO 31-A1), bone tumors, subtrochanteric fractures and polytrauma were also excluded from this research. Among the studied cases, 26 patients underwent internal fixation using a short nail system and 27 using the long nail system.

The study was approved by the Ethics Committee of 'Foişor' Orthopaedics-Traumatology and Osteoarticular TB Hospital in Bucharest, Romania. All patients provided a signed informed consent. The choice of implant was based on the randomization of the cases using sealed envelopes prepared by an independent individual, which contained the instructions regarding the type of fixation. The nails used in this paper and available in our center were the standard 180-mm Stryker Gamma3 Trochanteric Nail (Stryker MedEd) (Stryker for the short nail group and Stryker Gamma3 Long Nail for the long nail group, both with a 135 degree proximal nail angle. The distal screw was locked for the short nail and dynamic for the long nail. The diameters were 11 mm for both types of nail.

All patients received a spinal or general anesthesia with preoperative antibiotics (1 g cefuroxime and postoperative antibiotics for 24 h). Patients were positioned supine on the fracture table, and the fracture was reduced under fluoroscopic guidance while applying traction and internal rotation of the lower limb. After the surgical preparation and draping, the patients were treated according to the Stryker Gamma 3 nail surgical technique recommended by the manufacturer. For the long nail group, a previous reaming 2 mm larger than the distal nail diameter was used. In all cases, the position of the lag screw was assessed and measured using the tip-apex distance (TAD) (15). The surgical time, surgical blood loss and length of stay were recorded for each case.

All cases followed the standard rehabilitation protocol if the patient's clinical status and the nail stability allowed it. It consisted of assisted walking with weight bearing as tolerated using a walking frame for 6 weeks. All patients were followed up at 3 weeks, 6 weeks, 3 months, 6 months and 12 months, and clinical and functional assessments were undertaken by a different surgeon blinded to the type of treatment received. X-rays were taken each time, in order to evaluate the fracture union and complications. The Visual Analogue Scale (VAS), Harris Hip Score (HHS) (16) and Functional Ambulation Category scale (FAC) were also used for the assessment.

The VAS is a subjective index, used in our study to determine the amount of pain, which consists of a score between 0 (minimum) and 10 (maximum). This scale is considered a reliable and simple tool for describing the pain intensity felt by the patient (17).

The HHS was originally developed in 1969 and was intended to evaluate hip disabilities and various types of treatment (16). It is a questionnaire that covers mainly four domains which are pain, range of motion, function and the absence of deformities (16). The maximum score is 100. The higher the score, the better the patient outcome. A score below 70 is equivalent to a poor functional result.

The FAC scale, first described by Holden *et al* in 1984, ranges from 0 (nonfunctional ambulatory) and 5 (independent ambulatory) and evaluates the amount of human support the

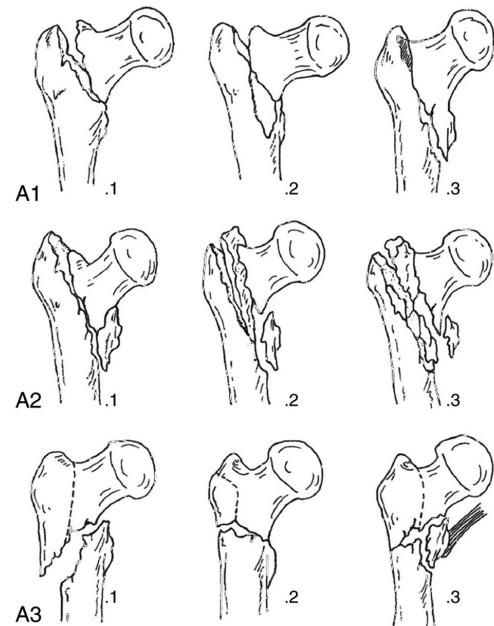


Figure 1. AO-OTA classification of trochanteric fractures.

patients require while walking (18). It is a quick, simply to use and easy to interpret test that requires only stairs and an indoor floor with a length of at least 15 m (19) (Table I).

Statistical analysis was performed using SPSS version 27.0. Continuous variables were compared between the groups using the independent sample t-test and Mann-Whitney U test. The categorical variables were compared using the Chi Square test. A P-value <0.5 was considered as indicative of a statistically significant difference.

Results

The baseline characteristics of the patients are presented in Table II. Out of the 53 patients included, 42 (79.2%) had a 31.A2 fracture (21 in the long nail group and 21 in the short nail group) and 11 patients (20.8%) had a 31.A3 fracture (6 in the long nail group and 5 in the short nail group). Both groups presented comparable results regarding the age of the patients included ($P=0.67$), sex ($P=0.67$), and length of hospital stay ($P=0.07$). The surgical time was significantly longer ($P<0.05$) in the long nail group, the average time recorded being 81.38 (± 12.01) min, while the result for the short nail group was 53.11 (± 8.36) min. In addition, the blood loss was significantly higher ($P<0.05$) in the patients treated with long nails (210 ± 12.1 ml) compared to the short nail group (75.4 ± 14.8). Even though the surgical time was significantly longer for the long nail group, the length of hospital stay showed no significant difference ($P=0.07$). The average TAD was 17.8 \pm 1.69 mm for the long nail group and 18.1 \pm 1.53 mm for the short nail group; thus, the differences were not statistically significant ($P=0.98$). The fracture union time was 11.9 \pm 2.51 for the long nail group and 12.2 \pm 2.36 for the short nail group ($P=0.28$).

The results at each follow-up are presented in Table III. No statistical differences were noted regarding the VAS score at 1 day after surgery ($P=0.74$), 6 weeks ($P=0.56$), 6 months ($P=0.86$) and 12 months ($P=0.40$). At 6 months, the HHS

Table I. Functional ambulatory category (FAC) scale.

Score	Category	Interpretation
0	Nonfunctional ambulatory	Patient cannot ambulate, requires more than one person to ambulate safely
1	Ambulatory, dependent for physical assistance Level II	Patient requires continuous manual contact to support body weight and to maintain balance or assist coordination
2	Ambulatory, dependent for physical assistance Level I	Patient requires intermittent or continuous light touch to assist balance or coordination
3	Ambulatory, dependent for supervision	Patient can ambulate on level surfaces without manual contact of another person but requires supervision for guarding or verbal cueing
4	Ambulatory, independent only on leveled surfaces	Patient can ambulate independently on level surfaces but requires supervision or physical assistance on stairs, inclines or other non-level surfaces
5	Ambulatory, independent	Patient can ambulate independently on non-level and level surfaces, stairs and inclines

Table II. Baseline characteristics and intraoperative data.

	Long nail (n=27)	Short nail (n=26)	P-value
Unstable (AO31-A2)	21 (77.7%)	21 (80.7%)	n/a
Transtrochanteric (AO31-A3)	6 (22.2%)	5 (19.3%)	n/a
Age, mean (years)	78.07±5.03	78.65±4.84	0.67
Sex (M/F)	13/14	14/12	0.678
Surgical time (min)	81.38±12.01	53.11±8.36	<0.05
Length of hospital stay (days)	9.07±1.32	8.5±0.88	0.07
Estimative blood loss (ml)	210±12.1	75.4±14.8	<0.05
TAD (mm)	17.8±1.69	18.1±1.53	0.98

M, male; F, female; TAD, tip-apex distance.

Table III. VAS, HHS and FAC scale average results during each follow-up.

	Follow-up time	Long nail (n=27)	Short nail (n=26)	P-value
VAS	1 day	5.92±1.38	5.8±1.26	0.74
	6 weeks	3.44±1.05	3.11±1.07	0.56
	6 months	1.81±1.17	1.8±1.09	0.86
	12 months	0.51±0.7	0.3±0.47	0.406
HHS	6 months	82.37±3.79	84.76±3.68	<0.05
	12 months	87.29±3.43	88.53±3.32	0.15
FAC	Preoperative	4.14±0.86	4.34±0.74	0.465
	12 months	3.7±0.84	4.03±0.72	0.28

VAS, Visual Analogue Scale; HHS, Harris Hip Score; FAC, Functional Ambulation Categories.

demonstrated a statistical difference ($P<0.05$) with a better result for the short nail group (84.76 ± 3.68). At 12 months, we recorded no significant differences between the groups ($P=0.15$). Regarding the FAC scale, no significant differences were noted either before the fracture ($P=0.465$) or after 12 months ($P=0.28$).

Proximal screw cut-out occurred in 2 cases in the short nail group and 1 case from the long nail group, which resulted

in reoperations that consisted of total hip replacement for all cases. The screw position was optimal, except for the case with the long implant, where the screw position was eccentric on the lateral view. Only 1 peri-implant fracture occurred distal to the implant, in a case with a long cephalomedullary nail; it was treated with open reduction and internal fixation with plates and screws. No other complications were recorded in our

study, except a single case with local postoperative hematoma that did not require reintervention.

Discussion

The goal of treatment in the management of pertrochanteric fractures is to allow weight-bearing as soon as possible and to avoid the complications following prolonged immobilization, as well as to provide a rapid recovery (20,21). We used the Functional Ambulation Categories (FAC) scale and Harris hip score (HHS) to evaluate the hip disability, independence and the burden of care. We did not find any statistically significant differences after 12 months regarding the FAC scale. Conversely, we noticed a statistically better HHS after 6 months for the short nail group ($P < 0.05$).

After 12 months, the short nail group still showed better results, but not statistically significant; thus, the length of the nail may not influence the long-term functional result ($P = 0.28$). In the literature, we found studies that demonstrated acceptable and comparable results regarding HHS (22-25). Sellan *et al* observed a better HHS for the short nail group, but did not find any significance from the clinical point of view. One hypothesis is that usually, cases with such fractures are geriatric patients with low motor functions required to return to the baseline (26).

The short nail group experienced a 28-min shorter operative time than the long nail group. This result is a consequence of the aiming guide usage for the short nail, unlike the other group of patients where the distal screw is fixed by free hand and under assistance of intraoperative fluoroscopic imaging. Despite the significant differences, we were not able to correlate these results with the functional outcome. Zhang *et al* also demonstrated that the operative time does not influence the average length of hospital stay (25). We also found that the intraoperative blood loss was significantly higher in the long nail group. This may be linked to the longer operative time and the longer distal reaming distance necessary for the insertion of the long nail (27-29).

Regarding the postoperative complications, we noted 2 screw cut-outs in the short nail group and 1 screw cut-out in the long nail group, but without statistically significant differences. Except in the case with a long implant, the screw position was acceptable (lower half of the femoral neck on the AP view and central on the lateral view). The screw cut-out is the most frequent reason for reoperation and is usually caused by a screw malposition or an increased TAD (27-30). According to Baumgartner and Solberg, the TAD should be less than 25 mm to prevent the screw cutout. In our study, the TAD showed no statistically significant differences between the groups, and the mean distance was not longer than 19 mm. Therefore, the screw cut-out could be due to the higher leverage, a decreased length of the short nail and a higher instability of the construct (15). Regarding the case with a long nail, an eccentric screw position was noted on the lateral view. This kind of screw malposition may have caused a rotational force of the femoral neck around the proximal screw. The central position of the screw on the lateral plane is considered optimal in order to decrease the torsional forces (31,32).

We also recorded a peri-implant distal femur fracture in a case with a long nail implant. The fracture was caused by a fall from ground-level after 8 weeks. The patient was surgically

treated with open reduction and internal fixation with a locking plate. We did not report peri-implant fractures in the short nail group. Even though short proximal femoral nails demonstrated an increased risk of fractures at the distal tip of the implant in the early 1990's, later designs have demonstrated that this is not an issue anymore (13,14,33).

Some retrospective studies have demonstrated that the peri-implant fracture rate after short and long proximal femoral nail fixation showed no significant differences. The fracture rates reported in the literature are between 0 and 3.3% for the short femoral nail and 0 and 2.3% for the long femoral nail (27-29,34,35).

The inclusion of two groups of patients with unstable trochanteric fractures to determine the outcome of long compared with short proximal femoral nails in a prospective randomized study is the main strength of our study. We considered that the sample size was not adequate to analyze the complications, this being one of the main limitations. We consider that a larger sample is required to properly evaluate and to find correlations between complications and surgical errors. The blood loss being estimated and the inability to blind patient and the surgeon data represent other limitations of our study.

In conclusion, the present study showed no significant differences between short and long proximal femoral nails regarding the functional outcome after 12 months, which reinforces other findings available in the literature. The long cephalomedullary nail requires a longer surgical time and is associated with an increase in intraoperative blood loss without improving the patient function. We recorded only one peri-implant fracture in a patient with a long nail construct, which required surgical treatment. A larger sample of cases is required to thoroughly analyze the postoperative complications.

Acknowledgements

Professional editing, linguistic and technical assistance performed by Irina Radu, Individual Service Provider (credentials: E0048/2014, Medicine-Pharmacy).

Funding

No funding was received.

Availability of data and materials

All data generated or analyzed during this study are included in this published article.

Authors' contributions

SD planned the clinical study, contributed to the conception and design of the study, and the acquisition, analysis and interpretation of the data. CDMD planned the clinical study and contributed to the conception and design of the study. DCC contributed to the conception and design of the study, translation and critical revision for important intellectual content. CIS contributed to the analysis and interpretation of the data and the critical revision for important intellectual content. All authors read and approved the final version of the manuscript and agreed to be accountable for all aspects of the study.

Ethics approval and consent to participate

All procedures performed in studies involving human participants were in accordance with the national ethical standards and with the 1964 Helsinki declaration and its later amendments or comparable ethical standards. The study was approved by the Ethics Committee of 'Foişor' Orthopaedics-Traumatology and Osteoarticular TB Hospital in Bucharest, Romania (no. 1309/2020). Informed consent was obtained from all individual participants included in the study.

Patient consent for publication

Not applicable.

Competing interests

The authors declare that they have no competing interests.

References

- Zuckerman JD: Hip fracture. *N Engl J Med* 334: 1519-1525, 1996.
- Miyamoto RG, Kaplan KM, Levine BR, Egol KA and Zuckerman JD: Surgical management of hip fractures: An evidence-based review of the literature. I: Femoral neck fractures. *J Am Acad Orthop Surg* 16: 596-607, 2008.
- Kannus P, Parkkari J, Sievänen H, Heinonen A, Vuori I and Järvinen M: Epidemiology of hip fractures. *Bone* 18 (Suppl 1): S57-S63, 1996.
- National hip fracture database (NHFD) annual report 2017: <https://www.nhfd.co.uk/files/2017ReportFiles/NHFD-AnnualReport2017.pdf>. Accessed: November, 2020.
- Fisher AA, Davis MW, Rubencher SE, Sivakumaran S, Smith PN and Budge MM: Outcomes for older patients with hip fractures: The impact of orthopedic and geriatric medicine cocare. *J Orthop Trauma* 20: 172-178, 2006.
- Erez O and Dougherty PJ: Early complications associated with cephalomedullary nail for intertrochanteric hip fractures. *J Trauma* 72: E101-E105, 2012.
- Rogers FB, Shackford SR and Keller MS: Early fixation reduces mobility and mortality in elderly patients with hip fractures from low-impact falls. *J Trauma* 39: 261-265, 1995.
- Anglen JO and Weinstein JN, American Board of Orthopaedic Surgery Research Committee: Nail or plate fixation of intertrochanteric hip fractures: Changing pattern of practice. A review of the American board of orthopaedic surgery database. *J Bone Joint Surg Am* 90: 700-707, 2008.
- Werner BC, Fashandi AH, Gwathmey FW and Yarboro SR: Trends in the management of intertrochanteric femur fractures in the United States 2005-2011. *Hip Int* 25: 270-276, 2015.
- Valverde JA, Alonso MG, Porro JG, Rueda D, Larrauri PM and Soler JJ: Use of the gamma nail in the treatment of fractures of the proximal femur. 1998. *J Orthop Trauma* 17 (Suppl 8): S51-S56, 2003.
- Lorich DG, Geller DS and Nielson JH: Osteoporotic pertrochanteric hip fractures: Management and current controversies. *Instr Course Lect* 53: 441-454, 2004.
- Hesse B and Gächter A: Complications following the treatment of trochanteric fractures with the gamma nail. *Arch Orthop Trauma Surg* 124: 692-698, 2004.
- Radford PJ, Needoff M and Webb JK: A prospective randomised comparison of the dynamic hip screw and the gamma locking nail. *J Bone Joint Surg Br* 75: 789-793, 1993.
- Bridle SH, Patel AD, Bircher M and Calvert PT: Fixation of intertrochanteric fractures of the femur. A randomised prospective comparison of the gamma nail and the dynamic hip screw. *J Bone Joint Surg Br* 73: 330-334, 1991.
- Baumgaertner MR and Solberg BD: Awareness of tip-apex distance reduces failure of fixation of trochanteric fractures of the hip. *J Bone Joint Surg Br* 79: 969-971, 1997.
- Harris WH: Traumatic arthritis of the hip after dislocation and acetabular fractures: Treatment by mold arthroplasty. An end-result study using a new method of result evaluation. *J Bone Joint Surg Am* 51: 737-755, 1969.
- Katz J and Melzack R: Measurement of pain. *Surg Clin North Am* 79: 231-252, 1999.
- Holden MK, Gill KM, Magliozzi MR, Nathan J and Piehl-Baker L: Clinical gait assessment in the neurologically impaired. Reliability and meaningfulness. *Phys Ther* 64: 35-40, 1984.
- Wade DT: Measurement in neurological rehabilitation. *Curr Opin Neurol Neurosurg* 5: 682-686, 1992.
- Oldmeadow LB, Edwards ER, Kimmel LA, Kipen E, Robertson VJ and Bailey MJ: No rest for the wounded: Early ambulation after hip surgery accelerates recovery. *ANZ J Surg* 76: 607-611, 2006.
- Dragosloveanu Ş, Dragosloveanu CDM, Stanca HT, Cotor DC, Dragosloveanu CI and Stoica CI: A new perspective towards failure of gamma nail systems. *Exp Ther Med* 20: 216, 2020.
- Okcu G, Ozkayin N, Okta C, Topcu I and Aktuglu K: Which implant is better for treating reverse obliquity fractures of the proximal femur: A standard or long nail? *Clin Orthop Relat Res* 471: 2768-2775, 2013.
- Schipper IB, Steyerberg EW, Castelein RM, van der Heijden FH, den Hoed PT, Kerver AJ and van Vugt AB: Treatment of unstable trochanteric fractures. Randomized comparison of the gamma nail and the proximal femoral nail. *J Bone Joint Surg Br* 86: 86-94, 2004.
- Elis J, Chechik O, Maman E and Steinberg EL: Expandable proximal femoral nails versus 95 dynamic condylar screw-plates for the treatment of reverse oblique intertrochanteric fractures. *Injury* 43: 1313-1317, 2012.
- Zhang Y, Zhang S, Wang S, Zhang H, Zhang W, Liu P, Ma J, Pervaz N and Wang J: Long and short intramedullary nails for fixation of intertrochanteric femur fractures (OTA 31-A1, A2 and A3): A systematic review and meta-analysis. *Orthop Traumatol Surg Res* 103: 685-690, 2017.
- Sellam M, Bryant D, Tieszer C, Papp S, Lawendy A, Liew A, Viskontas D, MacLeod M, Coles C, Carey T, *et al*: Short versus long interTAN fixation for geriatric intertrochanteric hip fractures: A multicentre head-to-head comparison. *J Orthop Trauma* 33: 169-174, 2019.
- Hou Z, Bowen TR, Irgit KS, Matzko ME, Andreychik CM, Horwitz DS and Smith WR: Treatment of pertrochanteric fractures (OTA 31-A1 and A2): Long versus short cephalomedullary nailing. *J Orthop Trauma* 27: 318-324, 2013.
- Boone C, Carlberg KN, Koueiter DM, Baker KC, Sadowski J, Wiater PJ, Nowinski GP and Grant KD: Short versus long intramedullary nails for treatment of intertrochanteric femur fractures (OTA 31-A1 and A2). *J Orthop Trauma* 28: e96-e100, 2014.
- Kleweno C, Morgan J, Redshaw J, Harris M, Rodriguez E, Zurakowski D, Vrahas M and Appleton P: Short versus long cephalomedullary nails for the treatment of intertrochanteric hip fractures in patients older than 65 years. *J Orthop Trauma* 28: 391-397, 2014.
- Vicario C, Marco F, Ortega L, Alcobendas M, Dominguez I and López-Durán L: Necrosis of the femoral head after fixation of trochanteric fractures with gamma locking nail. A cause of late mechanical failure. *Injury* 34: 129-134, 2003.
- Den Hartog BD, Bartal E and Cooke F: Treatment of the unstable intertrochanteric fracture. Effect of the placement of the screw, its angle of insertion, and osteotomy. *J Bone Joint Surg Am* 73: 726-733, 1991.
- Lenich A, Bachmeier S, Prantl L, Nerlich M, Hammer J, Mayr E, Al-Munajjed AA and Fichtmeier B: Is the rotation of the femoral head a potential initiation for cutting out? A theoretical and experimental approach. *BMC Musculoskelet Disord* 12: 79, 2011.
- Parker MJ and Handoll HH: Gamma and other cephalocondylic intramedullary nails versus extramedullary implants for extracapsular hip fractures in adults. *Cochrane Database Syst Rev*: CD000093, 2010.
- Vaughn J, Cohen E, Vopat BG, Kane P, Abbood E and Born C: Complications of short versus long cephalomedullary nail for intertrochanteric femur fractures, minimum 1 year follow-up. *Eur J Orthop Surg Traumatol* 25: 665-670, 2015.
- Lindvall E, Ghaffar S, Martirosian A and Husak L: Short versus long intramedullary nails in the treatment of pertrochanteric hip fractures: Incidence of ipsilateral fractures and costs associated with each implant. *J Orthop Trauma* 30: 119-124, 2016.