

Femtosecond-LASIK outcomes using the VisuMax[®]-MEL[®] 80 platform for hyperopia and hyperopic astigmatism refractive surgery

BOGDANA TĂBĂCARU¹, HORIA TUDOR STANCA¹, RUXANDRA ANGELA PÎRVULESCU¹, SIMONA STANCA², CIPRIAN DANIELESCU³, MIHNEA MUNTEANU⁴, COSMIN ROȘCA⁵ and ADRIAN COSMIN TEODORU⁶

Departments of ¹Ophthalmology, ²Pediatrics, 'Carol Davila' University of Medicine and Pharmacy, 050474 Bucharest;

³Department of Ophthalmology, 'Grigore T. Popa' University of Medicine and Pharmacy, 700115 Iasi;

⁴Department of Ophthalmology, 'Victor Babeș' University of Medicine and Pharmacy, 300041 Timisoara;

⁵Department of Ophthalmology, Oculens Clinic, 400501 Cluj-Napoca; ⁶Department of Ophthalmology,

Faculty of Medicine, 'Lucian Blaga' University, 550159 Sibiu, Romania

Received November 11, 2020; Accepted December 11, 2020

DOI: 10.3892/etm.2021.9719

Abstract. The present study evaluated the efficacy, the safety and the predictability of the Femtosecond laser-assisted *in situ* keratomileusis (Femto-LASIK) procedure for hyperopia and hyperopic astigmatism. We retrospectively analyzed the postoperative 12-month evolution of 593 eyes with hyperopia and hyperopic astigmatism that underwent Femto-LASIK treatment. The procedure was predictable and effective. No eye lost 2 lines of corrected distance visual acuity (CDVA), demonstrating a safety profile of the procedure. Nine percent of the eyes gained at least one line of CDVA. The accuracy of the spherical equivalent after 12 months was 74% within ± 1.0 diopter (D) of emmetropia. The refractive outcomes were stable during the follow-up period. There were no significant complications during the procedure. Femto-LASIK using the VisuMax[®]-MEL[®] 80 platform was demonstrated to be a suitable option to correct selected cases of hyperopia and hyperopic astigmatism. A longer follow-up period is required to better assess the refractive results and to detect any further regression.

Introduction

Currently, laser-assisted *in situ* keratomileusis (LASIK) is the default choice for refractive surgical procedures, as it can address a wide spectrum of high and complex ametropias (1-5). There are numerous previous reports of hyperopic LASIK showing various safety, efficiency and predictability percentages (6-32). The new femtosecond laser technology to perform LASIK flaps avoids many complications of the mechanical microkeratome (free caps, incomplete, irregular or displaced flaps), being presently preferred by many surgeons (1,2,33). In this study, we evaluated the safety, efficacy, predictability and accuracy of the refractive results of Femtosecond-LASIK (Femto-LASIK) procedure using the VisuMax[®]-MEL[®] 80 platform for hyperopia with or without astigmatism.

Patients and methods

Data collection. We performed a retrospective, noncomparative consecutive case series study on eyes with hyperopia and hyperopic astigmatism that underwent Femto-LASIK surgery. Patients were operated on by the same refractive surgeon (HTS) at the Europe Eye-Metropolitan Hospital in Bucharest, Romania between June 2011 and June 2017. All surgeries were performed using the same femtosecond laser-excimer laser platform VisuMax[®]-MEL[®] 80 (Carl Zeiss Meditec).

Inclusion and exclusion criteria. The inclusion criteria for the surgery were: Patients of age ≥ 22 years, no refractive change for at least 2 years before surgery, stable peripheral retina (normal or already treated by laser photocoagulation if at-risk peripheral lesions were present), central endothelial density $\geq 2,000$ cells/mm² and good compliance (1,3,33,34).

The refractive inclusion criteria were: Manifest hyperopia up to 6.00 diopter (D) with or without astigmatism up to 5.00 D and spherical equivalent +6.00 D at most. Patients outside these limits were referred for intraocular surgery, either phakic

Correspondence to: Dr Horia Tudor Stanca, Department of Ophthalmology, 'Carol Davila' University of Medicine and Pharmacy, 8 Eroilor Sanitari Street, 050474 Bucharest, Romania
E-mail: hstanca@yahoo.com

Dr Simona Stanca, Department of Pediatrics, 'Carol Davila' University of Medicine and Pharmacy, 8 Eroilor Sanitari Street, 050474 Bucharest, Romania
E-mail: simonastanca@yahoo.com

Key words: femtosecond-LASIK, Femto-LASIK, hyperopia, hyperopic astigmatism, refractive surgery

intraocular lenses or refractive lens exchange, according to patient age and ocular biometric considerations (35-37).

We considered the following exclusion criteria for surgery: Eyes with corneal inadequate parameters (evidence or suspect of ectasia, thinnest point on pachymetry $\leq 500 \mu\text{m}$, estimated postoperative steep keratometry $>50 \text{ D}$, insufficient corneal thickness for laser ablation-estimated residual thickness of the stromal bed after treatment $\leq 300 \mu\text{m}$) (1,3,33), eyes with anterior segment pathology (eg. severe dry eye syndrome, ocular inflammation or infection) (1,3,33), patients with eye-related conditions which might interfere with visual acuity (eg. cataract, congenital or acquired macular pathology, optic nerve pathology or retinal vascular pathology) (1,38-44), patients with previous ocular trauma or any previous ocular procedures (eg. scleral, vitreo-retinal surgery, glaucoma laser procedures or glaucoma surgery) (1,45-47) and patients taking medication with potential ocular side effects (eg. isotretinoin, amiodarone) (1,3,33).

Patients with very deep-set eyes were also excluded, as well as patients with narrow palpebral fissures or periocular tumors (1,48-50), as normal orbital anatomy is important in order to permit the proper suction cup positioning.

We also excluded patients with systemic diseases with risk of postoperative low visual acuity due to possible vascular complications including ischemic optic neuropathy or vascular occlusion (eg. cardiovascular diseases, severe systemic hypertension, severe dyslipidemia) (1,51-54) and patients with systemic diseases that could interfere with the wound-healing process (eg. autoimmune disorders, diabetes mellitus) (1,33,55).

Pregnancy or lactation were exclusion criteria for the surgery (1,3,33).

Patients unable to understand the perioperative management, patients with unreasonable expectations or patients unable to sign the informed consent were excluded as well (1,33).

Preoperative assessment. Preoperative ocular examination included: Corrected and uncorrected distance visual acuity, manifest, fogging and cycloplegic refractions, keratometry, ultrasound corneal pachymetry, corneal topography and tomography (Scheimpflug), non-contact tonometry, pupillometry, white-to-white corneal diameter, quantification of corneal endothelial cell density, slit-lamp examination of the anterior segment and retina assessment with pharmacological mydriasis.

Patients were asked not to wear soft contact lenses 2 weeks prior to preoperative investigations and then 2 weeks prior to surgery.

All patients signed an informed written consent form in accordance with the Declaration of Helsinki after being fully informed about the benefits and risks of the procedure. The study was approved by the Ethics Committee of 'Carol Davila' University of Medicine and Pharmacy of Bucharest, Romania (no. 16-02-06-2011).

Surgical technique. All surgeries were performed by the same refractive surgeon (HTS), with the same femtosecond laser-excimer laser platform (VisuMax®-MEL® 80; Carl Zeiss Meditec), using the same protocol and technique.

Surgical steps included the following: Topical anesthesia, sterilization of the eyelids with 10% povidone-iodine solution,

draping of the eyelids, positioning of the eye to be treated under the femtosecond laser surgical microscope, docking of the eye and proper suction, femtosecond laser assisted cutting of the corneal flap, repositioning of the eye under the excimer laser surgical microscope, lifting the flap, drying the corneal bed, excimer laser ablation, lavage of the debris with saline solution, repositioning of the flap, bandage contact lens application and instillation of topical antibiotic and artificial tears.

The flap position, the flap regularity and the interface clarity were examined before patient discharge.

Postoperative care. Postoperative treatment consisted of topical eye drops: Antibiotic, steroid and non-steroid anti-inflammatory and artificial tears. The bandage contact lens was removed on the first day of postoperative visit.

The follow-up visits were carried out at 1, 3, 6 and 12 months. For each examination, a slit-lamp examination of the anterior segment and several investigations were performed which included: Manifest refraction, uncorrected distance visual acuity, corneal topography and tomography (Scheimpflug) and non-contact tonometry. Corrected distance visual acuity and cycloplegic refraction were performed for the eyes in which a residual refraction was determined or the visual acuity was uncorrelated with the manifest refraction.

Data analysis and statistics. Patient data were centralized into an Excel® (ver.14.0, Microsoft Corp.) database after being collected on case forms. Statistical analysis was performed using Statistical Package for the Social Sciences (SPSS) software (ver. 20, IBM® SPSS® Statistics; IBM Corp.). Normality of continuous variables distribution was checked by the Shapiro-Wilk test, the statistical significance being set at a P-value <0.05 . Preoperative and postoperative refractive data are presented as mean \pm standard deviation and range.

Refractive outcome analysis was performed according to the Standard Graphs for Reporting Refractive Surgery (56,57). Thus, we compared the preoperative data with the 1-, 3-, 6- and 12-month postoperative results and we analyzed the safety, the efficacy, the predictability, the accuracy and the stability of the Femto-LASIK procedure.

Results

Patient demographics and operative data. A total of 593 eyes (290 right eyes and 303 left eyes) from 373 patients (294 males and 79 females) were available for evaluation 12 months after laser surgery and were reviewed for statistical analysis in our retrospective interventional consecutive case series study. The mean patient age at the time of surgery was 33.20 ± 8.098 years (range, 22-49 years). A total of 224 patients (448 eyes) had bilateral Femto-LASIK, while 153 patients were anisometropic cases, being operated in one single eye. A total of 163 eyes (27.49%) were amblyopic, having a visual acuity between 20/60 and 20/30. The preoperative manifest and cycloplegic refraction data are presented in Table I.

Visual and refractive results. The efficacy was defined as the ratio of the uncorrected distance visual acuity (UDVA) at the end of the follow-up period (12 months) and the preoperative corrected visual acuity (CDVA). Fig. 1 shows that

Table I. Preoperative manifest and cycloplegic refraction data.

Parameter	Diopters (mean ± SD, range)
Manifest sphere	+3.9532±1.5282, +1.25 to +6.00
Manifest cylinder	+2.6316±1.2208, +0.50 to +5.00
Manifest SEQ	+4.0780±1.5723, +1.50 to +6.00
Cycloplegic sphere	+5.7198±1.4351, +3.25 to +6.75
Cycloplegic cylinder	+3.1320±1.4829, +0.50 to +5.00

SD, standard deviation; SEQ, spherical equivalent refraction.

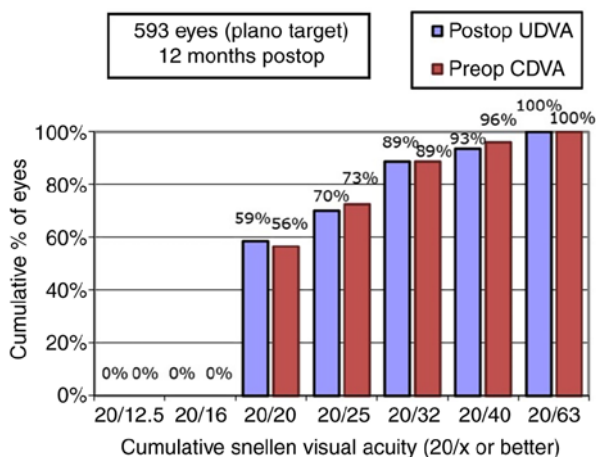


Figure 1. Summary of the 12-month postoperative uncorrected distance visual acuity (UDVA) and preoperative corrected distance visual acuity (CDVA). Refractive target was emmetropia (plano target). Postop, postoperative; Preop, preoperative.

all eyes reached a UDVA of 20/63 or better 12 months after Femto-LASIK surgery. As shown in Fig. 2, for 84.1% of the eyes, the postoperative 12-month UDVA was the same or better than the preoperative CDVA.

Safety, defined as no loss of two or more Snellen lines of CDVA, was excellent. Twelve months after Femto-LASIK surgery, no eye lost 2 lines and 6 eyes (1.012%) lost one Snellen line of CDVA (Fig. 3). Contrariwise, we found several amblyopic eyes that gained at least one line of visual acuity, reflecting potential benefit of the refractive surgery, possibly explained by reduction or elimination of optical aberrations of the hyperopic magnifying correction lenses.

The scatterplot of the attempted spherical equivalent refraction (SEQ) against the achieved refractive change is shown in Fig. 4. At the postoperative 12 months follow-up visit, the mean sphere was +0.887±0.8746 D, the mean cylinder was +0.766±0.5797 and the mean SEQ was +0.5042±0.8336. The accuracy of SEQ at 12 months was 49% within ±0.50 D and respectively 74% within ±1.00 D of emmetropia (Fig. 5). Lower predictability and accuracy of SEQ was found for the eyes with high preoperative refractive errors.

Regarding the mean refractive manifest astigmatism at the last postoperative visit, 54 and 79% were <0.50 D and ≤1.00 D, respectively. Fig. 6 also shows the comparison between the preoperative and the 12-month postoperative refractive astigmatism.

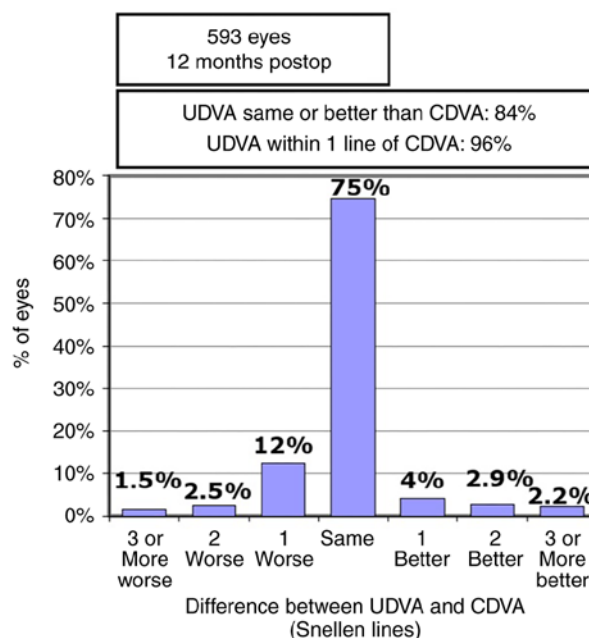


Figure 2. Efficacy, shown as gained and lost Snellen lines of postoperative uncorrected distance visual acuity (UDVA) compared to preoperative corrected distance visual acuity (CDVA), 12-months postoperative. Postop, postoperative.

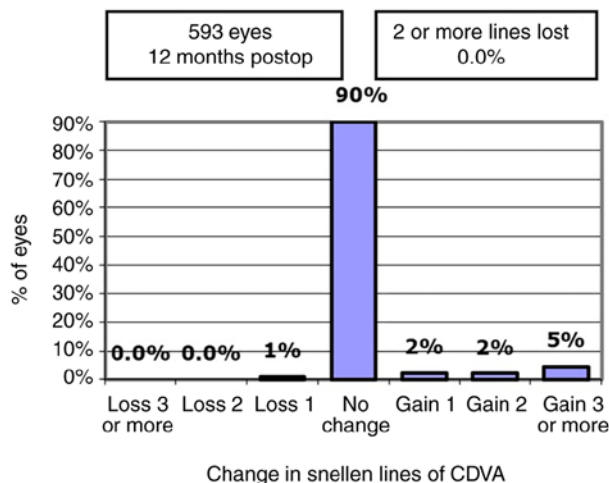


Figure 3. Safety, shown as gained and lost Snellen lines of postoperative corrected distance visual acuity (CDVA) compared to preoperative CDVA, 12-months postoperative. Postop, postoperative.

Fig. 7 shows the excellent evolution of SEQ after the surgery and its stability in time over the 12-month follow-up period. The postoperative refraction data at 1, 3, 6 and 12 months postoperative are presented in Table II. There were no intraoperative or postoperative complications during the follow-up period.

Discussion

Laser-assisted *in situ* keratomileusis (LASIK) is currently the most frequently practiced laser refractive procedure worldwide as it can correct large diopter limits of all types of refractive errors (1-4,6-33). However, laser refractive surgery is

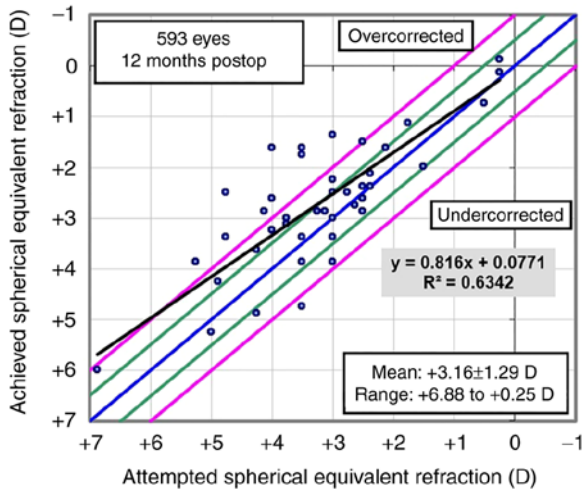


Figure 4. Scattergram of attempted vs. achieved spherical equivalent refraction (SEQ), 12-months postoperative. Postop, postoperative; D, diopter.

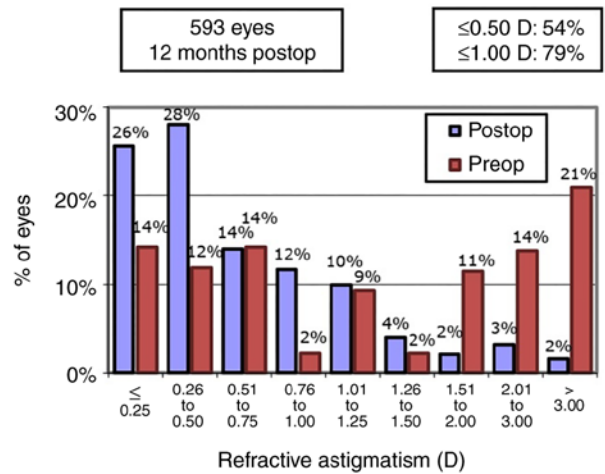


Figure 6. Summary of preoperative and 12-months postoperative refractive astigmatism. Postop, postoperative; Preop, preoperative; D, diopter.

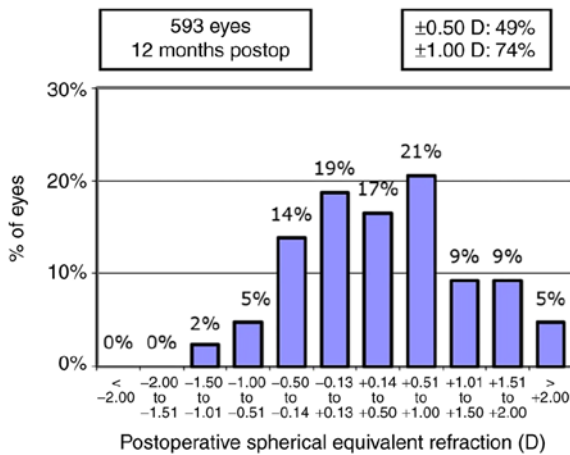


Figure 5. Accuracy of spherical equivalent refraction (SEQ) to intended target, 12-months postoperative. Postop, postoperative; D, diopter.

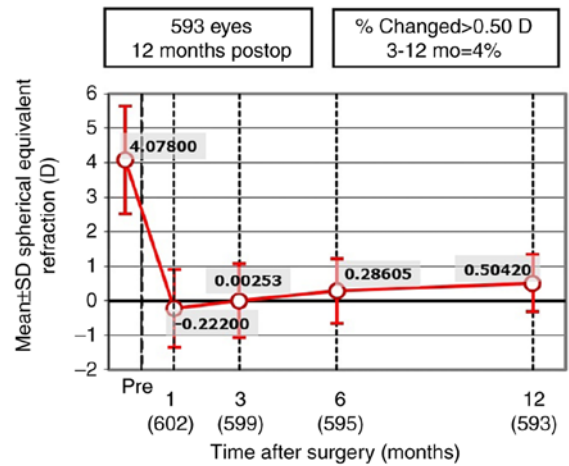


Figure 7. Stability of spherical equivalent refraction (SEQ) during the follow-up period of 12 months. Postop, postoperative.

challenging for eyes with hyperopia or hyperopic astigmatism, especially when refractive error is high (1,6-32,58).

Hyperopic correction has several difficulties. Hyperopic patients are frequently under-corrected in regards to glass prescriptions prior to preoperative evaluation and have accommodation reserve of different degrees or accommodation spasm (1,6). Therefore, the integration of manifest and cycloplegic refractions is difficult and latent hyperopia may lead to increasing values of manifest refraction with age (1,6). Accurate centration of the ablation is another difficult point as hyperopic patients have a wide angle Kappa (6). Hyperopic correction induces central corneal flattening, which may be limited by preoperative keratometry (6). Another issue concerning hyperopic and astigmatic patients is the higher risk of de-centration of ablation due to the difficulty in fixation of the near target point during laser correction (6). Considering all the above listed features, the predictability and the accuracy of the refractive results in hyperopia, with or without astigmatism, are lower when compared to myopic refractive corrections (58).

Although some excimer lasers have been approved for corrections up to +6.0 D (1,7) and current technology using models with

wide ablation and high correction speed has greatly improved prognosis (1,8) [large diameter optical areas being more resistant to epithelial hyperplasia that is responsible for real regression (1,7)], latent hyperopia is often the reason why refractive surgeons avoid approaching cases of hyperopia and hyperopic astigmatism or limit the surgeries to refractive errors below +3.0 D (1,8). Laser refractive treatment is difficult to choose because ablation of manifest refraction in hyperopia or hyperopic astigmatism may lead postoperatively to recurrence of a degree of hyperopia, falsely interpreted as regression of the laser procedure (1,6,7), while ablation of cycloplegic refraction may lead to myopic refraction in the immediate postoperative period, causing an unsatisfactory UDVA (1). In order to compensate in part for the latent hyperopia, Kanellopoulos proposed a nomogram that involves full treatment in the case of the cylinder and the ablation of the manifest refraction sphere with an addition of +0.25 D for the dominant eye and up to +0.75 D for the non-dominant eye (1,9).

There have been several reports of hyperopic-LASIK and hyperopic astigmatism-LASIK in the past, using different excimer laser platforms and using for the flap creation either the microkeratome or the femtosecond laser (1,6-32). Table III

Table II. Postoperative refraction data.

Parameter	Postoperative visit			
	1 month	3 months	6 months	12 months
	Diopters (mean \pm SD, range)			
Manifest sphere	+0.233 \pm 1.1409, -1.50 to +3.25	+0.4393 \pm 1.1563, -1.25 to +3.75	+0.667 \pm 0.9742, -1.00 to +2.50	+0.887 \pm 0.8746, -1.00 to +2.75
Manifest cylinder	+0.91 \pm 0.739, +0.00 to +3.00	+0.8735 \pm 0.6021, +0.25 to +2.75	+0.7618 \pm 0.54706, +0.00 to +2.75	+0.766 \pm 0.5797, +0.25 to +3.25
Manifest SEQ	-0.222 \pm 1.1320, -2.50 to +3.00	+0.00253 \pm 1.079, -1.50 to +3.375	+0.28605 \pm 0.9382, -1.25 to +2.50	+0.5042 \pm 0.8336, -1.00 to +3.00

SD, standard deviation; SEQ, spherical equivalent refraction.

Table III. Predictability of the SEQ between ± 0.5 D and ± 1.0 D of the intended target, in several published reports of LASIK interventions for hyperopia or hyperopic astigmatism (1).

Authors (Ref.)	Refractive error of the treated eyes	Follow-up period (months)	± 0.5 D of the intended target	± 1.0 D of the intended target
Zadok <i>et al</i> (20)	Hyperopia (SEQ <+3)	6		88.9%
Salz and Stevens (32)	Hyperopia	6	65.0%	87.4%
Pineda-Fernández <i>et al</i> (30)	Low hyperopia	6	54.5%	
Zadok <i>et al</i> (20)	Hyperopia (SEQ <+5)	6		51.8%
Pineda-Fernández <i>et al</i> (30)	Medium hyperopia	6	40.0%	
Kanellopoulos <i>et al</i> (25)	Hyperopia (SEQ <+3)	12	92.0%	
Salz and Stevens (32)	Hyperopia	12	74.1%	91.4%
Roesler and Kohnen (31)	Hyperopia	12		88.0%
Kanellopoulos <i>et al</i> (25)	Hyperopia (SEQ <+5)	12	79.0%	
Ditzen <i>et al</i> (27)	Hyperopia	12	78.0%	
Kanellopoulos (9)	Hyperopia and Hyperopic astigmatism	6	77.9%	88.9%
El-Naggar and Hovaghimian (6)	Hyperopia and Hyperopic astigmatism	12	95%	100.0%
Kanellopoulos <i>et al</i> (25)	Hyperopia (SEQ >+5) and Hyperopic astigmatism	12	71.0%	
Lian <i>et al</i> (28)	Hyperopia and Hyperopic astigmatism	12	61.1%	83.3%
Kanellopoulos (9)	Hyperopia and Hyperopic astigmatism	24	75.5%	94.4%
Pineda-Fernández <i>et al</i> (30)	Hyperopic astigmatism (SEQ <+3)	6	50.0%	
Pineda-Fernández <i>et al</i> (30)	Hyperopic astigmatism (SEQ <+6)	6	38.8%	
Salz and Stevens (32)	Hyperopic astigmatism	6	60.5%	88.7%
Salz and Stevens (32)	Hyperopic astigmatism	12	73.0%	89.2%
Ditzen <i>et al</i> (27)	Hyperopic astigmatism	12	42.0%	

SEQ, spherical equivalent refraction.

shows the follow-up periods and the refractive reports of all of these studies either with high (1,6-23,25-29) and lower predictability and efficacy rates for high refractive errors (1,6,24,30). The safety of the procedure in these reports was reported as good; the number of eyes that lost two lines of CDVA postoperatively being either zero (1,6,8,25,29) or ranging between 1.09 and 4.34% (1,20,27,28,30,32). The reports in the literature

mention that the improvement of the ametropic error allowed the gain in CDVA of one line in 44.6% of cases (1,9) and of two lines in 3.7 to 22.8% of cases in various studies (1,8,28).

In the present study, we assessed the refractive outcomes of femtosecond assisted LASIK performed for the correction of hyperopia up to 6 D without or with astigmatism up to 5 D, with a spherical equivalent not exceeding +6 D. The refractive target

was emmetropia in all cases. The treatment plan was chosen corroborating the manifest, fogging and cycloplegic refraction, considering both the accommodative reserve and patient age.

Femtosecond-LASIK using the VisuMax®-MEL® 80 platform was demonstrated to be a suitable option to correct selected cases of hyperopia and hyperopic astigmatism. The postoperative results after one year demonstrated the Femto-LASIK procedure to be safe and effective. The predictability at 12 months was 74% within ± 1 D of emmetropia. As both the sphere and the cylinder plus values were reduced and the need for hyperopic correction lenses was minimal, the optical aberrations and distortion of the retinal image were smaller, allowing us to achieve a better postoperative CDVA with at least one line in 9% of the eyes.

The retrospective pattern of this report and the short period of follow-up of one year are limiting factors in our study. A future prospective study and a longer follow-up period are necessary for a better understanding of the procedure stability and for elaboration of nomogram ablation profiles.

Acknowledgements

Professional editing, linguistic and technical assistance was performed by Irina Radu, Individual Service Provider.

Funding

No funding was received.

Availability of data and materials

The data that support the findings of this study are available from the corresponding author (HTS), upon reasonable request.

Authors' contributions

BT contributed to the conception and design of the study, the acquisition, analysis and interpretation of the data of the study. She also contributed to the drafting of the work and its critical revision for important intellectual content. HTS contributed to the conception and design of the study, the acquisition, analysis and interpretation of the data of the study, contributed to the drafting of the work and its critical revision for important intellectual content. RAP contributed to the acquisition, analysis and interpretation of data of the study, contributed to the drafting of the work and its critical revision for important intellectual content. SS contributed to the conception and design of the study, contributed to the drafting of the work and its critical revision for important intellectual content. CD contributed to the conception and design of the study, contributed to the drafting of the work and its critical revision for important intellectual content. MM contributed to the acquisition, the analysis and interpretation of data of the study, to the drafting of the work and its critical revision for important intellectual content. CR contributed to the analysis and interpretation of data of the study, to the drafting of the work and its critical revision for important intellectual content. ACT contributed to the analysis and interpretation of data of the study, to the drafting of the work and its critical revision for important intellectual content. All authors read and approved the final version of the manuscript and agreed to be

accountable for all aspects of the study in ensuring that questions related to the accuracy or integrity of any part of the work are appropriately investigated and resolved.

Ethics approval and consent to participate

All participants signed an informed consent in accordance with the Declaration of Helsinki. The study was approved by the Ethics Committee of 'Carol Davila' University of Medicine and Pharmacy of Bucharest, Romania.

Patient consent for publication

This manuscript does not contain case details, personal information or images that may enable an individual to be identified.

Competing interests

The authors have no financial or proprietary interest to declare in any device presented in this article.

References

1. Tăbăcaru B: Femtosecond Laser-Excimer Laser Platform for Ametropias Surgery, PhD thesis (no. TD 4697). 'Carol Davila' University of Medicine and Pharmacy, Bucharest, Romania, 2019.
2. Shah R: History and results; indications and contraindications of SMILE compared with LASIK. *Asia Pac J Ophthalmol (Phila)* 8: 371-376, 2019.
3. Stanca HT, Munteanu M, Jianu DC, Motoc AG, Jecan CR, Tăbăcaru B, Stanca S and Preda MA: Femtosecond-LASIK outcomes using the VisuMax®-MEL® 80 platform for mixed astigmatism refractive surgery. *Rom J Morphol Embryol* 59: 277-283, 2018.
4. Tabacaru B and Stanca HT: One year refractive outcomes of femtosecond-LASIK in mild, moderate and high myopia. *Rom J Ophthalmol* 61: 23-31, 2017.
5. Tabacaru B and Stanca HT: Scheimpflug topographical changes after femtosecond LASIK for mixed astigmatism-theoretical aspects and case study. *Rom J Ophthalmol* 61: 69-75, 2017.
6. El-Naggar MT and Hovaghimian DG: Assessment of refractive outcome of femtosecond-assisted LASIK for hyperopia correction. *Electron Physician* 9: 3958-3965, 2017.
7. Motwani M and Pei R: Treatment of moderate-to-high hyperopia with the WaveLight Allegretto 400 and EX500 excimer laser systems. *Clin Ophthalmol* 11: 999-1007, 2017.
8. Motwani M: Topographic-guided treatment of hyperopic corrections with a combination of higher order aberration removal with WaveLight® Contoura and wavefront-optimized hyperopic treatment. *Clin Ophthalmol* 12: 1021-1029, 2018.
9. Kanellopoulos AJ: Topography-guided hyperopic and hyperopic astigmatism femtosecond laser-assisted LASIK: Long-term experience with the 400 Hz eye-Q excimer platform. *Clin Ophthalmol* 6: 895-901, 2012.
10. Suarez E, Torres F and Duplessie M: LASIK for correction of hyperopia and hyperopia with astigmatism. *Int Ophthalmol Clin* 36: 65-72, 1996.
11. Esquenazi S: Five-year follow-up of laser in situ keratomileusis for hyperopia using the Technolas Keracor 117C excimer laser. *J Refract Surg* 20: 356-363, 2004.
12. Zadok D, Raifkup F, Landau D and Frucht-Pery J: Long-term evaluation of hyperopic laser in situ keratomileusis. *J Cataract Refract Surg* 29: 2181-2188, 2003.
13. Jaycock PD, O'Brart DP, Rajan MS and Marshall J: 5-year follow-up of LASIK for hyperopia. *Ophthalmology* 112: 191-199, 2005.
14. Varley GA, Huang D, Rapuano CJ, Schallhorn S, Boxer Wachler BS and Sugar A; Ophthalmic Technology Assessment Committee Refractive Surgery Panel, American Academy of Ophthalmology: LASIK for hyperopia, hyperopic astigmatism, and mixed astigmatism: A report by the American academy of ophthalmology. *Ophthalmology* 111: 1604-1617, 2004.

15. Spades L, Sabetti L, D'Alessandri L and Balestrazzi E: Photorefractive keratectomy and LASIK for the correction of hyperopia: 2-year follow-up. *J Refract Surg* 22: 131-136, 2006.
16. Alió J, Galal A, Ayala MJ and Artola A: Hyperopic LASIK with esiris/schwind technology. *J Refract Surg* 22: 772-781, 2006.
17. Antonios R, Arba Mosquera S and Awwad ST: Hyperopic laser in situ keratomileusis: Comparison of femtosecond laser and mechanical microkeratome flap creation. *J Cataract Refract Surg* 41: 1602-1609, 2015.
18. Desai RU, Jain A and Manche EE: Long-term follow-up of hyperopic laser in situ keratomileusis correction using the Star S2 excimer laser. *J Cataract Refract Surg* 34: 232-237, 2008.
19. el-Agha MS, Johnston EW, Bowman RW, Cavanagh HD and McCulley JP: Excimer laser treatment of spherical hyperopia: PRK or LASIK? *Trans Am Ophthalmol Soc* 98: 59-66, 2000.
20. Zadok D, Maskaleris G, Montes M, Shah S, Garcia V and Chayet A: Hyperopic laser in situ keratomileusis with the Nidek EC-5000 excimer laser. *Ophthalmology* 107: 1132-1137, 2000.
21. Davidorf JM, Eghbali F, Onclinx T and Maloney RK: Effect of varying the optical zone diameter on the results of hyperopic laser in situ keratomileusis. *Ophthalmology* 108: 1261-1265, 2001.
22. Rashad KM: Laser in situ keratomileusis for the correction of hyperopia from +1.25 to +5.00 diopters with the Technolas Keracor 117C laser. *J Refract Surg* 17: 113-122, 2001.
23. Llovet F, Galal A, Benitez-del-Castillo JM, Ortega J, Martin C and Baviera J: One-year results of excimer laser in situ keratomileusis for hyperopia. *J Cataract Refract Surg* 35: 1156-1165, 2009.
24. Alió JL, El Aswad A, Vega-Estrada A and Javaloy J: Laser in situ keratomileusis for high hyperopia (>5.0 diopters) using optimized aspheric profiles: Efficacy and safety. *J Cataract Refract Surg* 39: 519-527, 2013.
25. Kanellopoulos AJ, Conway J and Pe LH: LASIK for hyperopia with the WaveLight excimer laser. *J Refract Surg* 22: 43-47, 2006.
26. Gil-Cazorla R, Teus MA, de Benito-Llopis L and Mikropoulos DG: Femtosecond laser vs. mechanical microkeratome for hyperopic laser in situ keratomileusis. *Am J Ophthalmol* 152: 16-21.e2, 2011.
27. Ditzen K, Fiedler J and Pieger S: Laser in situ keratomileusis for hyperopia and hyperopic astigmatism using the Meditec MEL 70 spot scanner. *J Refract Surg* 18: 430-434, 2002.
28. Lian J, Ye W, Zhou D and Wang K: Laser in situ keratomileusis for correction of hyperopia and hyperopic astigmatism with the Technolas 117C. *J Refract Surg* 18: 435-438, 2002.
29. El-Agha MS, Bowman RW, Cavanagh D and McCulley JP: Comparison of photorefractive keratectomy and laser in situ keratomileusis for the treatment of compound hyperopic astigmatism. *J Cataract Refract Surg* 29: 900-907, 2003.
30. Pineda-Fernández A, Rueda L, Huang D, Nur J and Jaramillo J: Laser in situ keratomileusis for hyperopia and hyperopic astigmatism with the Nidek EC-5000 excimer laser. *J Refract Surg* 17: 670-675, 2001.
31. Roesler C and Kohnen T: Changes of functional optical zone after LASIK for hyperopia and hyperopic astigmatism. *J Refract Surg* 34: 476-481, 2018.
32. Salz JJ and Stevens CA: LADARVision LASIK Hyperopia Study Group: LASIK correction of spherical hyperopia, hyperopic astigmatism, and mixed astigmatism with the LADARVision excimer laser system. *Ophthalmology* 109: 1647-1658, 2002.
33. Tăbăcaru B, Stanca S, Mocanu V, Zemba M, Stanca HT and Munteanu M: Intraoperative flap-related complications in FemtoLASIK surgeries performed with Visumax® femtosecond laser: A ten-year Romanian experience. *Exp Ther Med* 20: 2529-2535, 2020.
34. Stanca TH, Tabacaru B and Celea C: Correlations between confocal microscopy and histological aspects of normal cornea. *Rom J Ophthalmol* 59: 19-23, 2015.
35. Schallhorn SC, Schallhorn JM, Pelouskova M, Venter JA, Hettlinger KA, Hannan SJ and Teenan D: Refractive lens exchange in younger and older presbyopes: Comparison of complication rates, 3 months clinical and patient-reported outcomes. *Clin Ophthalmol* 11: 1569-1581, 2017.
36. Mălăescu M, Stanca HT, Tăbăcaru B, Stănilă A, Stanca S and Danielescu C: Accuracy of five intraocular lens formulas in eyes with trifocal lens implant. *Exp Ther Med* 20: 2536-2543, 2020.
37. Alió JL, Grzybowski A and Romaniuk D: Refractive lens exchange in modern practice: When and when not to do it? *Eye Vis (Lond)* 1: 10, 2014.
38. Stanca HT, Stanca S, Tabacaru B, Boruga M and Balta F: Bevacizumab in Wet AMD treatment: A tribute to the thirteen years of experience from the beginning of the anti-VEGF era in Romania. *Exp Ther Med* 18: 4993-5000, 2019.
39. Goldberg I, Jay Katz L, Mansouri K, Pakravan M and Yazdani S: A refractive surgery candidate with optic nerve head cupping. *J Ophthalmic Vis Res* 7: 248-256, 2012.
40. Stanca HT, Suvac E, Munteanu M, Jianu DC, Motoc AGM, Roșca GC and Boruga O: Giant cell arteritis with arteritic anterior ischemic optic neuropathy. *Rom J Morphol Embryol* 58: 281-285, 2017.
41. Moshirfar M, D Wagner W, H Linn S, W Brown T, L Goldberg J, T Gomez A, C Ronquillo Y and C Hoopes P: Corneal refractive surgery in patients with history of optic neuritis. *J Ophthalmic Vis Res* 14: 436-441, 2019.
42. Munteanu M, Rosca C and Stanca H: Sub-inner limiting membrane hemorrhage in a patient with Terson syndrome. *Int Ophthalmol* 39: 461-464, 2019.
43. Arevalo JF: Managing retinal detachment after refractive surgery: With current knowledge, we cannot determine whether prophylactic treatment is indicated in candidates for refractive surgery. *Retina Today* 2017: 36-40, 2017.
44. Vatsa S and Sood S: Macular dystrophy in a post LASIK patient. *DJO* 30: 60-62, 2020.
45. Stanca HT, Munteanu M, Jianu DC, Motoc AGM, Tăbăcaru B, Stanca S, Ungureanu E, Boruga VM and Preda MA: New perspectives in the use of laser diode transscleral cyclophotocoagulation. A prospective single center observational cohort study. *Rom J Morphol Embryol* 59: 869-872, 2018.
46. Donnenfeld ED: Correcting astigmatism after glaucoma surgery. *Glaucoma Today* 2011: 29-32, 2011.
47. Preda MA, Karancsi OL, Munteanu M and Stanca HT: Clinical outcomes of micropulse transscleral cyclophotocoagulation in refractory glaucoma-18 months follow-up. *Lasers Med Sci* 35: 1487-1491, 2020.
48. Chang JSM, Law AKP, Ng JCM and Cheng MSY: Femtosecond laser in situ keratomileusis flap creation in narrow palpebral fissure eyes without suction. *Case Rep Ophthalmol* 8: 341-348, 2017.
49. Boruga O, Bălășoiu AT, Giuri S, Munteanu M, Stanca HT, Iovănescu G and Preda MA: Caruncular late-onset junctional nevus: Apropos of an anatomo-clinical observation. *Rom J Morphol Embryol* 58: 1461-1464, 2017.
50. Moshirfar M, Shah TJ, Skanchy DF, Linn SH, Kang P and Durrie DS: Comparison and analysis of FDA reported visual outcomes of the three latest platforms for LASIK: Wavefront guided Visx iDesign, topography guided WaveLight allegro contoura and topography guided Nidek EC-5000 CATz. *Clin Ophthalmol* 11: 135-147, 2017.
51. J Shah T, Moshirfar M and C Hoopes P: Safety of the excimer laser in LASIK and PRK for patients with implantable cardiac devices: Our clinical experience in the past two decades. *J Ophthalmic Vis Res* 14: 530-531, 2019.
52. Stanca HT, Petrović Z and Munteanu M: Transluminal Nd:YAG laser retinolysis-a reasonable method to reperfuse occluded branch retinal arteries. *Vojnosanit Pregl* 71: 1072-1077, 2014.
53. Cobo-Soriano R, Beltrán J and Baviera J: LASIK outcomes in patients with underlying systemic contraindications: A preliminary study. *Ophthalmology* 113: 1118.e1-e8, 2006.
54. Savoivu Balint G, Iovanescu G, Stanca H, Popoiu CM, Boia E, Popovici RA and Bolintineanu SL: The protective effect of HDL-cholesterol in patients with essential hypertension. *Rev Chim* 68: 949-952, 2017.
55. Spadea L and Paroli MP: Laser refractive surgery in diabetic patients: A review of the literature. *Clin Ophthalmol* 6: 1775-1783, 2012.
56. Reinstein DZ, Archer TJ and Randleman JB: JRS standard for reporting astigmatism outcomes of refractive surgery. *J Refract Surg* 30: 654-659, 2014.
57. Waring GO III: Standard graphs for reporting refractive surgery. *J Refract Surg* 16: 459-466, 2000.
58. Spierer O, Mimouni M, Nemet A, Rabina G and Kaiserman I: Hyperopic laser keratorefractive surgery: Do steep corneas have worse outcomes? *Int Ophthalmol* 40: 1885-1895, 2020.

