

Central precocious puberty occurring in Bardet-Biedl syndrome-10 as a method for self-protection of human reproductive function: A case report

HANMING LI¹, JIANYU HE¹, IATLUN LEONG², RUNXIAO HUANG¹ and XIAOJIE SHI¹

¹Department of Children's Health Care, Fifth People's Hospital of Foshan City, Foshan, Guangdong 528211;

²Department of General Surgery, University Hospital of Macau Special Administrative Region, Macau Special Administrative Region 999078, P.R. China

Received March 29, 2022; Accepted June 21, 2022

DOI: 10.3892/etm.2022.11511

Abstract. Hypogonadism and obesity are primary features of Bardet-Biedl syndrome (BBS). Obesity is also an associated factor of central precocious puberty (CPP). The present report describes the case of a girl (age, 7 years and 6 months), with clinical manifestations of precocious puberty, progressive obesity, postaxial polydactyly, retinal degeneration and intellectual disability. The patient visited the clinic for the first time due to early breast development and progressive obesity. After 8 months of follow-up, the bone age had advanced almost 3 years, and the gonadotropin-releasing hormone (GnRH) stimulation test showed results that had changed from indicating pseudo precocious puberty to CPP. Whole-exome gene sequencing showed that there were two heterozygous mutations in the BBS type 10 (*BBS10*) gene, chr12:76739816(c.1949del) and chr12:76740374(c.1391C>G). The final diagnosis was of BBS10 and CPP. In order to protect the reproductive capacity of the patient, GnRH analogs were used for CPP treatment. After 15 months of treatment and follow-up, a physical examination revealed Tanner breast stage 1. Ultrasonography showed that the uterus and ovaries had reduced to their prepubertal size. In conclusion, the present report describes a case of CPP that occurred in a young girl with BBS10. We hypothesize that this was a prelude to gonad dysplasia, acting as a method for the self-protection of human reproductive function. However,

more clinical data and molecular biological evidence are required to confirm the etiology and mechanism of this case.

Introduction

Bardet-Biedl syndrome (BBS) a rare autosomal recessive genetic disease with clinical manifestations that can affect multiple systems throughout the body, was first reported by Georges Bardet (1). The incidence of BBS is nearly 1 in 125,000-160,000 in North America and Europe (2). Beales *et al* (3) analyzed the clinical symptoms of 109 families with BBS and summarized and revised the diagnostic criteria of the disease. The proposed diagnostic criteria for BBS are the presence of either four primary features or three primary and two secondary features, which differentiate this syndrome from other phenotype overlapped syndromes.

The incidence rate of retinal degeneration/dystrophy in patients with BBS is >90% (4), and it mostly occurs as night blindness at the beginning of the disease (3). Obesity is the second primary feature of BBS, with an incidence rate of 72-92% (3-5); it often starts in childhood and gradually worsens with age, and can further develop into type 2 diabetes (4). The average body mass index (BMI) of adult men and adult women with BBS is 36.6 and 31.5 kg/m² (normal ranges: 18-24 kg/m²), respectively (5). Postaxial polydactyly is the only symptom that can be observed at birth, with both upper and lower extremities being simultaneously involved in 21% of patients, lower limb involvement occurring in 21% of the patients and upper limb involvement occurring in 9% of the patients (4,6). The incidence rate of hypogonadism in BBS populations is 59-98% (6). The indicators of hypogonadism range from late sexual maturity to hypogonadism in males (7). Most individuals with this condition have a micropenis and/or low testicular volume at birth, and 9% have cryptorchidism (3). Females with hypogonadism exhibit features such as hypoplastic fallopian tubes, uterus and ovaries, partial and complete vaginal atresia, a septate vagina, a duplex uterus, hydrocolpos, hydrometrocolpos and a persistent urogenital sinus (8). Renal abnormality is a major cause of morbidity and mortality in patients with BBS, and has an incidence rate ranging between 20 and 53% (3), including cystic tubular disease and anatomical deformities. Intellectual

Correspondence to: Dr Hanming Li, Department of Children's Health Care, Fifth People's Hospital of Foshan City, 63 Jiangpu Dong Road, Xiqiao, Nanhai, Foshan, Guangdong 528211, P.R. China
E-mail: 524242655@qq.com

Abbreviations: BBS, Bardet-Biedl syndrome; BMI, body mass index; SDS, standard deviation score; CPP, central precocious puberty; LH, luteinizing hormone; FSH, follicle-stimulating hormone; BBS10, BBS type 10; GnRH, gonadotropin-releasing hormone analog

Key words: CPP, obesity, BBS

disability occurs in 50–61% of patients with BBS (7), and a previous study has shown that the volume of the hippocampus is decreased in patients with BBS (9).

Secondary BBS phenotypes include hepatic fibrosis, diabetes mellitus, neurological impairment, speech deficits, behavioral abnormalities, craniofacial dysmorphism, dental irregularities, developmental delay, hypertension, cardiovascular abnormalities, hearing loss and olfactory impairments (7).

In total, >500 cases of BBS have been reported globally, of which only 80 cases have been accurately diagnosed in China (10). To date, 21 BBS genes have been identified and mapped on various chromosomes (11), and ~80% of the clinically examined cases can be explained by the known identified BBS genes (6). BBS has both a high degree of genetic heterogeneity and extensive clinical heterogeneity, and the association between genotype and phenotype is not significant (12). Novel interventions are developing at a rapid pace including genetic therapeutics such as gene therapy, exon skipping therapy, nonsense suppression therapy, and gene editing. Other non-genetic therapies such as gene repurposing, targeted therapies, and non-pharmacological interventions are also ongoing. A major challenge in developing genetic therapies for BBS is the generation of a long lasting therapy. A successful example of this is the retinal gene therapy (Luxturna), which has been developed for RPE65-associated Leber congenital amaurosis (13).

The present report describes the case of a girl (age, 7 years and 6 months) who was initially diagnosed with BBS due to early breast development and obesity, and gradually developed central precocious puberty (CPP) during follow-up. Whole-exome gene sequencing revealed new heterozygous mutations in the BBS type 10 (*BBS10*) gene, which, to the best of our knowledge, have not yet been reported.

Case report

Patient. The patient was a girl (age, 7 years and 6 months), with a height of 127.8 cm [+0.4 standard deviation score (SDS) girls, i.e. 0.4 SDs above average for girls this age] (14), weight of 38.0 kg (+3.0 SDS girls (14)) and a BMI of 23.3 kg/m². The patient visited the Department of Children's Health Care, Fifth People's Hospital of Foshan City (Foshan, China) for the first time in July 2020 due to a rapid increase in body weight from the age of 6 years and breast development for a month prior to the visit. The patient was the only daughter in the family and was born at full-term after spontaneous labor (measuring 49 cm in length and 3.0 kg in weight, with a 43.5-cm head circumference at birth).

At 1 year and 3 months of age, the parents of the patient noticed rapid weight increase, with a height of 76.0 cm [-1 SDS girls (14)], a weight of 13.0 kg [+3.1 SDS girls (14)] and a BMI of 22.5 kg/m² being reached. The patient experienced retinal degeneration in both eyes. Sixth finger/toe deformities in both hands and the left foot were treated with surgical operations when she was 2 years old. At the first visit, motor functions and speech development were delayed, and the patient had attention problems and a poor academic performance (age, 7 years and 6 months). The father and mother were aged 44 and 42 years, respectively, and both were healthy; the

family history revealed a non-consanguineous marriage and no notable genetic findings.

Clinical findings. At the first visit to the Department of Children's Health Care, Fifth People's Hospital of Foshan City in July 2020, the patient was 7 years and 6 months of age. A physical examination indicated the following: Blood pressure, 92/60 mmHg; height, 127.8 cm [+0.4 SDS girls (14)]; weight, 38.0 kg [+3.0 SDS girls (14)]; and BMI, 23.3 kg/m². The abdominal circumference was 73.5 cm. Facial features revealed a low hairline, crowding of the teeth, malocclusion and no abnormal facial features or limb malformation appearance. The patient had small hands and feet, with surgical scars of 1.0–1.5 cm in length on the outside of the little fingers of both hands and the little toe of the left foot. The breasts were at Tanner stage 2 (15) of development and female genitalia were present. The vaginal opening was normal and located below the urethral opening. The patient's father and mother were 167 cm [-0.9 SDS (14)] and 163 cm [+0.4 SDS (14)] in height, respectively. Both parents had normal sexual characteristics and both were Tanner stage 5. After this visit, the patient was referred to other hospitals. Therefore, no other examination and treatment was provided.

The patient returned for another visit in January 2021, at 8 years and 2 months of age. The patient had experienced breast development and intermittent pain for 3 months. The following measurements were recorded: Height, 130.8 cm [+0.3 SDS girls (14)]; weight, 40.5 kg [+2.8 SDS girls (14)]; and BMI, 23.6 kg/m². The abdominal circumference was 75.8 cm and the patient was at Tanner breast stage 2.

Diagnostic assessment. In July 2020, at the time of the first visit, the patient's intelligence test score (Chinese-Wechsler Intelligence Scale for Children) was 75 (normal range: 85–115) (16). Routine blood and urine tests were within the normal ranges. Her hormones and biochemical data were normal, and they were in the state of Tanner Stages 2 female. And her ovarian function was also normal (Table I).

Ultrasonography indicated that the patient's uterus and ovaries were in the prepubertal stage, and there was no adrenal and celiac ectopic hyperplastic disease. Additionally, the bone age was 10 years (17), which was 2 years and 6 months advanced of that expected. Magnetic resonance imaging of the pituitary gland was normal.

The gonadotropin-releasing hormone (GnRH) stimulation test showed that the peaks of FSH and LH, which were 5.66 IU/l and 1.23 IU/l (Reference range: peak of LH > 5.0 IU/l and LH/FSH > 0.6), respectively, appeared at 60 min post-administration. The ratio of LH to FSH was 0.22. Peripheral blood lymphocyte karyotype showed a result of 46, XX (Fig. 1).

According to all the aforementioned results, the patient was initially diagnosed with BBS and pseudo-precocious puberty. However, whole-exome gene sequencing was not performed, as it was too expensive for the parents. After 3 months of follow-up, the patient's breasts returned to Tanner stage B1.

In January 2021, at 8 years and 2 months old, the patient returned for another visit. This time, her hormones and biochemical data were still normal, and they were in the state of Tanner Stages 2 female. And her ovarian and adrenal function were also normal (Table II).

Table I. Hormones and biochemical data in July 2020.

Parameter	Result	Reference range
Triglyceride, mmol/l	1.70	0.56-1.70
Total cholesterol, mmol/l	3.40	3.10-5.70
Fasting blood glucose, mmol/l	5.40	3.90-6.10
Fasting insulin, mU/l	15.40	3.00-25.00
Blood 17-hydroxyprogesterone, ng/ml	0.76	0.33-2.97
α -fetoprotein, IU/ml	1.10	0-20.00
β -human chorionic gonadotropin, mIU/ml	2.00	0-10.00
Inhibin B, pg/ml	11.20	0-43.91
Anti-Müllerian hormone, ng/ml	2.20	0.05-10.40
Testosterone, nmol/l	0.08	<0.24-0.97
Estradiol, pmol/l	99.80	37.00-88.00
FSH, IU/l	3.51	1.00-10.80
LH, IU/l	0.16	0.02-4.70
Free triiodothyronine, pmol/l	5.80	3.50-6.60
Free thyroxine, pmol/l	17.30	11.50-22.70
Thyroid-stimulating hormone, mIU/l	3.87	0.64-6.27

FSH, follicle-stimulating hormone; LH, luteinizing hormone.

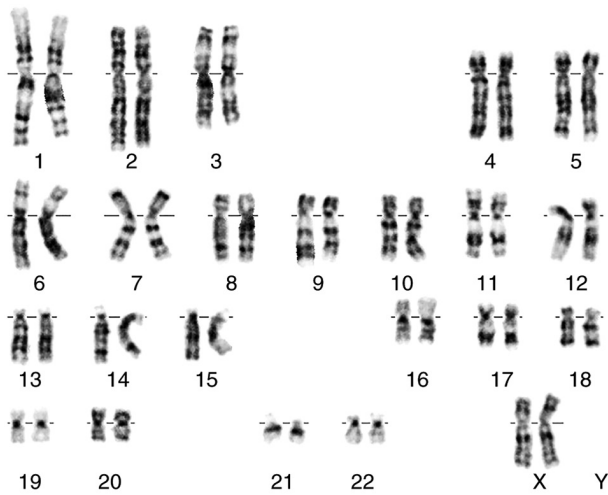


Figure 1. Analysis of the peripheral blood lymphocyte karyotype showed a result of 46, XX.

Furthermore, the bone age was 11 years (17), which was almost 3 years advanced of that expected. Ultrasonography revealed the following results: Uterine volume, 26x10x17 mm; endometrial thickness, 4 mm; left ovary volume, 21x13x15 mm or ~2.1 ml; and right ovary volume, 17x11x12 mm or ~1.2 ml. No early antral follicles were observed. The GnRH stimulation test showed that the peaks of FSH and LH, which were 9.29 and 6.31 IU/l, respectively, appeared 60 min after administration. The ratio of LH to FSH was 0.68.

Whole-exome gene sequencing was performed by the Guangzhou Daan Clinical Laboratory Center in Guangzhou, China). Genomic DNA from peripheral blood leukocytes, derived from the proband was extracted using a QIAamp DNA Blood Mini kit (cat. no. 51185; Qiagen, GmbH).

Concentration was measured by Qubit 3.0. A total of 1 μ g each genomic DNA sample was fragmented by sonication and purified to yield fragments of 200-300 bp. Paired-end adaptor oligonucleotides from Illumina, Inc. were ligated to the shared genomic DNA. A total of 500 nanograms of these tailed fragments were then hybridized to the probe library of the Sure Select Human All Exon V6 (Agilent; catalogue number: 51908864). The enrichment libraries were sequenced on the Illumina Novaseq 6000 sequencer (Illumina, San Diego, California) as 150-bp paired-end reads. Reads were aligned to the human reference genome (GRCh37/hg19) with the burrows-wheeler aligner (BWA) (18) and potential duplicate paired-end reads were removed with Genome Analysis Toolkit (GATK) v.4.2.0.0 (<https://github.com/broadinstitute/gatk/releases/tag/4.2.2.0>). GATK v.4.2.0.0 was used for base quality-score recalibration and indel realignment as well as for single-nucleotide-variant and indel discovery and genotyping with standard hard-filtering parameters (19). Variants with low quality were flagged and excluded from subsequent analyses. Bamdst v.1.0.9 (github.com/shiquan/bamdst) was used to assess coverage of the clean data of each sample with default parameters. All variants identified in the affected individuals were annotated with databases, including refGene (<http://varianttools.sourceforge.net/Annotation/RefGene>), Avsnp150 (<https://www.ncbi.nlm.nih.gov/snp/>), gnomAD211 (<http://gnomad-sg.org/>), Clinvar (<https://www.ncbi.nlm.nih.gov/clinvar/>), dbnsfp41a (<https://sites.google.com/site/jpopgen/dbNSFP>), Intervar (<http://wintervar.wglab.org/>) by snpeff5.0d (sourceforge.net/projects/snpeff/) and annovar2020Jun (annovar.openbioinformatics.org/en/latest/). Candidate mutational events were then inspected with the integrative genomics viewer (20). The resulting variants were excluded when the frequency was >1/1,00 in genome aggregation database (gnomAD). Variants

Table II. Hormones and biochemical data, January 2021.

Parameter	Result	Reference range
Blood 17-hydroxyprogesterone, ng/ml	0.28	0.33-2.97
DHEA-S, μ mol/l	1.06	0.88-3.35
α -fetoprotein, IU/ml	0.70	0-20.00
β -human chorionic gonadotropin, mIU	3.10	0-10.00
Inhibin B, pg/ml	7.20	0-43.91
Anti-Müllerian hormone, ng/ml	4.40	0.05-10.40
Testosterone, nmol/l	0.21	<0.24-0.97
Estradiol, pmol/l	81.30	37.00-88.00
FSH, IU/l	1.47	1.00-10.80
LH, IU/l	0.26	0.02-4.70
Free triiodothyronine, pmol/l	5.30	3.50-6.60
Free thyroxine, pmol/l	14.00	11.50-22.70
Thyroid-stimulating hormone, mIU/l	5.23	0.64-6.27

DHEA-S, dehydroepiandrosterone-sulfate; FSH, follicle-stimulating hormone; LH, luteinizing hormone.

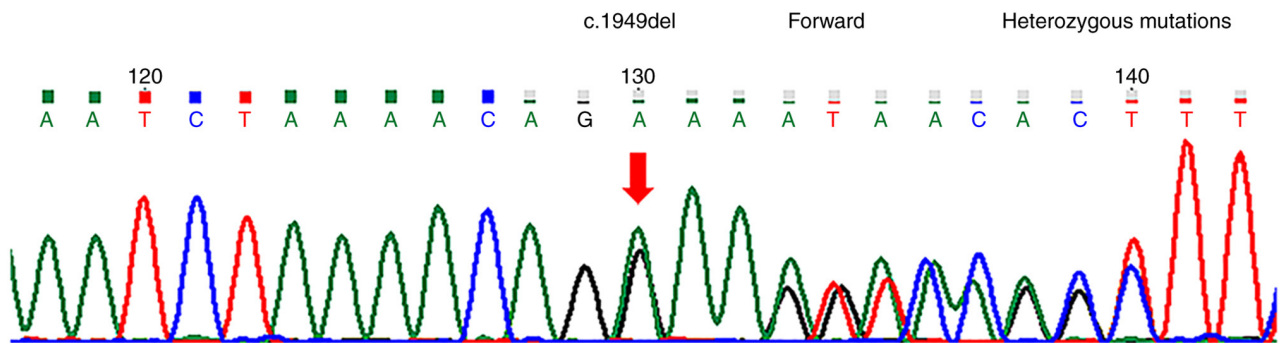


Figure 2. *BBS10* c.1949del heterozygous mutations. *BBS10*, Bardet-Biedl syndrome type 10.

were correlated with patient phenotypes and the results of clinical investigations. All variants were classified in the American College of Medical Genetics and Genomics (ACMG) standards and guidelines (21). chr12:76739816 (c.1949del) (Fig. 2) and chr12:76740374 (c.1391C>G) (Fig. 3) heterozygous mutations associated with the patient's clinical phenotype were located in the *BBS10* gene. However, no possible pathogenic variants in the 59 genes recommended by the ACMG (21) were detected. The final diagnosis was BBS10 and CPP.

Therapeutic intervention. To avoid premature depletion of gonadal function, the patient's parents agreed to use GnRH analog (GnRHa) for CPP treatment. The initial dose was 3.75 mg subcutaneous injection, and the maintenance dose was subcutaneous injection 50-100 mg/kg every 4 weeks. The patient's height and sexual development will be fully assessed every 3 months. This treatment plan will last until the age of 11 or until the precocious puberty is well controlled.

Follow-up and outcomes. The patient showed good intervention compliance and tolerance. So far, no unfavorable and unanticipated events have been observed. After 3 months

of treatment with GnRHa, height and weight had increased to 132.0 cm [+0.2 SDS girls (14)] and 42.0 kg [+2.8 SDS girls (14)], respectively. The Tanner breast stage was now 1. The GnRH stimulation test showed that the peaks of FSH and LH, which were 7.15 and 3.42 IU/l, respectively, appeared 60 min after administration. The ratio of LH to FSH was 0.48. Ultrasonography showed that the uterus and ovaries had reduced to their prepubertal size.

In May 2022, the patient was 9 years and 6 months old, and after receiving 15 months of treatment with GnRHa, height and weight measurements had increased to 138.6 cm [+0.26 SDS girls (14)] and 46.8 kg [+2.4 SDS girls (14)], respectively. The BMI was 24.4 kg/m² and the abdominal circumference was 76.8 cm. The patient was at Tanner breast stage 1. The GnRH stimulation test showed that the peaks of FSH and LH, which were 9.66 and 3.15 IU/l, respectively, appeared 90 min after administration. The ratio of LH to FSH was 0.33. The level of anti-Müllerian hormone was 3.9 ng/ml (reference range for a 0 to 10-year-old girl, 0.05-10.40 ng/ml). Ultrasonography showed that the uterus and ovaries were still their prepubertal size. The patient's bone age was 11 years and 6 months (17), which was 2 years advanced of that expected.

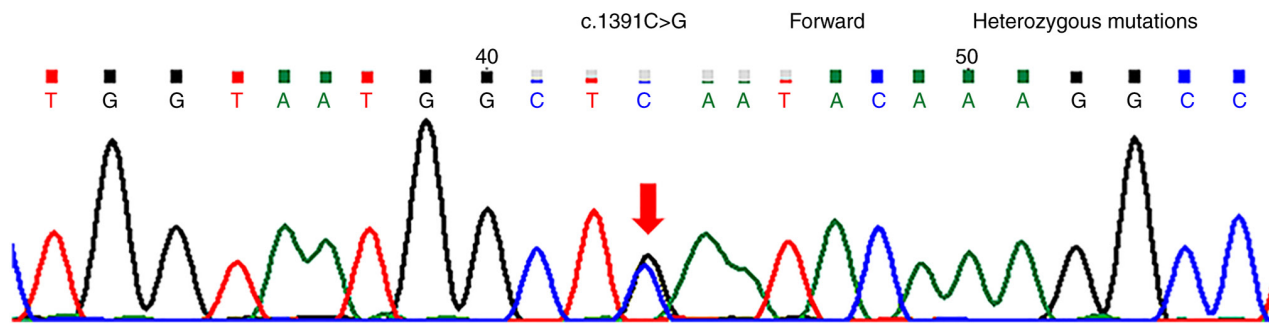


Figure 3. *BBS10* c.1391C>G heterozygous mutations. *BBS10*, Bardet-Biedl syndrome type 10.

Discussion

The final diagnosis in the present case was BBS10 and CPP. This is the first ever encounter of a patient with BBS10 and CPP in the Fifth People's Hospital of Foshan City.

The first visit of the patient was due to a rapid increase in body weight, but in fact, weight and BMI measurements did not change significantly from the beginning of pseudo-precocious puberty to CPP. A recent study showed that early-onset obesity enhanced paraventricular nucleus expression of serine palmitoyltransferase long chain base subunit 1 and advanced the maturation of the ovarian noradrenergic system (22). Although the age of thelarche has decreased from 1977 to 2013 (23), it is questionable whether this type of obesity is sufficient to cause precocious puberty in BBS, which is characterized by hypogonadism.

Patients with precocious puberty often have secondary sex characteristic of mismatched gonadal development. However, the Tanner stage of the breast, and the uterus and ovaries of the present patient markedly lagged behind the development of bone age. We hypothesized that this may have been associated with the clinical features of BBS. Clinical manifestations included retinal degeneration, obesity, postaxial polydactyly and intellectual disability, which were in line with the characteristics of BBS10, except for renal abnormality. No adrenal gland diseases and germ cell tumors were found, and there was no chronic steroid use. The final whole-exome gene sequencing revealed that the c.1949del and c.1391C>G heterozygous mutations associated with the patient's clinical phenotype were located in the *BBS10* gene, and were not included in the recommendations of the ACMG guidelines of 59 genes. A literature search revealed no clinical studies reporting these two mutations. Therefore, none of these mutations of the previous case reports can explain the occurrence of CPP.

To explain the cause of the CPP with BBS10, the literature was searched using the key words 'precocious puberty', 'gonad dysplasia', 'Turner syndrome', 'Klinefelter syndrome', 'Kallmann syndrome' and 'Prader-Willi syndrome' in Medline (<https://www.medline.com/>), Pubmed (<https://pubmed.ncbi.nlm.nih.gov/>), Embase (<https://www.embase.com/landing?status=grey>) and CNKI databases (<https://www.cnki.net/>) up to May 2021, and a notable phenomenon was found: Regardless of hypergonadotropic hypogonadism and hypogonadotropic hypogonadism, cases of precocious puberty have been reported, which is somewhat unusual.

U-shaped gonadotrophin levels are present from birth to puberty in normal males, while the same pattern, but at markedly higher levels, is present in anorchid boys, indicating that the gonads serve a role in the negative feedback of gonadotrophins in childhood (24). In addition, patients with Turner syndrome and triple X syndrome show premature activation of the GnRH pulse generator, even without signs of puberty (25). Both of these chromosomal aneuploidies have increased gonadotrophin levels as compensation for the restricted ovarian function, to the extent that they manifest as CPP, but eventually progress to premature ovarian failure. Gonadal dysplasia may reduce the negative feedback of gonadotrophins, resulting in the earlier activation of the hypothalamic-pituitary-gonadal axis (25). These theories seem to reasonably explain the occurrence of precocious puberty cases in hypergonadotropic hypogonadism.

Another question is with regard to the manner in which precocious puberty then occurs in hypogonadotropic hypogonadism. No pathogenic allelic variants of genes known to cause monogenic CPP (KISS1 receptor, KiSS-1 metastasis suppressor, makorin ring finger protein 3 and δ like non-canonical Notch ligand 1) (26-28) were found in the present case. Perhaps hints can be taken from other biological studies; for example, adult *Drosophila* accelerate their mating behavior to defend against the threat of certain parasitic wasps (29). It is unclear whether CPP occurring in BBS-10 would be a prelude of gonad dysplasia (30) or a self-protection mechanism of human reproductive function.

Central precocious puberty occurred in case of hypogonadotropic hypogonadism. Therefore, further clinical data and molecular biological evidence is required to confirm the etiology and mechanism of the present case.

Acknowledgements

The authors would like to thank Ms Liyu Yuan (Institute of Fashion Technology of Guangdong Polytechnic, Foshan China) for editing the figures associated with the manuscript.

Funding

No funding was received.

Availability of data and materials

All data generated or analyzed during this study are included in this published article.

Authors' contributions

HL, JH and IL were responsible for the study investigation. HL, JH, IL, RH and XS conceived and designed the study. HL wrote the original manuscript. HL, RH and XS reviewed and edited the manuscript. All authors read and approved the final manuscript. HL, JH and RH confirm the authenticity of all the raw data.

Ethics approval and consent to participate

The experimental protocol was established according to the ethical guidelines of the Helsinki Declaration and was approved by the Human Ethics Committee of the Fifth People's Hospital of Foshan City (Foshan, China; approval no. 2021060704).

Patient consent for publication

Written informed consent for publication of the case report was obtained from parents.

Competing interests

The authors declare that they have no competing interests.

References

- Bardet G: On congenital obesity syndrome with polydactyly and retinitis pigmentosa (a contribution to the study of clinical forms of hypophyseal obesity). *Obes Res.* 3: 387-99, 1920.
- Ajmal M, Khan MI, Neveling K, Tayyab A, Jaffar S, Sadeque A, Ayub H, Abbasi NM, Riaz M, Micheal S, *et al.*: Exome sequencing identifies a novel and a recurrent BBS1 mutation in Pakistani families with Bardet-Biedl syndrome. *Mol Vis* 19: 644-653, 2013.
- Beales PL, Elcioglu N, Woolf AS, Parker D and Flinter FA: New criteria for improved diagnosis of Bardet-Biedl syndrome: Results of a population survey. *J Med Genet* 36: 437-446, 1999.
- Forsythe E and Beales PL: Bardet-Biedl syndrome. *Eur J Hum Genet* 21: 8-13, 2013.
- Moore SJ, Green JS, Fan Y, Bhogal AK, Dicks E, Fernandez BA, Stefanelli M, Murphy C, Cramer BC, Dean JC, *et al.*: Clinical and genetic epidemiology of Bardet-Biedl syndrome in Newfoundland: A 22-year prospective, population-based, cohort study. *Am J Med Genet A* 132A: 352-360, 2005.
- M'hamdi O, Ouertani I and Chaabouni-Bouhamed H: Update on the genetics of bardet-biedl syndrome. *Mol Syndromol* 5: 51-56, 2014.
- Khan SA, Muhammad N, Khan MA, Kamal A, Rehman ZU and Khan S: Genetics of human Bardet-Biedl syndrome, an updates. *Clin Genet* 90: 3-15, 2016.
- Uğuralp S, Demircan M, Cetin S and Siğirci A: Bardet-Biedl syndrome associated with vaginal atresia: A case report. *Turk J Pediatr* 45: 273-275, 2003.
- Baker K, Northam GB, Chong WK, Banks T, Beales P and Baldeweg T: Neocortical and hippocampal volume loss in a human ciliopathy: A quantitative MRI study in Bardet-Biedl syndrome. *Am J Med Genet A* 155A: 1-8, 2011.
- Shen T, Yan XM and Xiao CJ: Current status and implication of research on Bardet-Biedl syndrome. *Zhonghua Yi Xue Yi Chuan Xue Za Zhi* 30: 570-573, 2013 (In Chinese).
- Heon E, Kim G, Qin S, Garrison JE, Tavares E, Vincent A, Nuangchamnon N, Scott CA, Slusarski DC and Sheffield VC: Mutations in C8ORF37 cause Bardet Biedl syndrome (BBS21). *Hum Mol Genet* 25: 2283-2294, 2016.
- Daniels AB, Sandberg MA, Chen J, Weigel-DiFranco C, Fielding Hejtmancic J and Berson EL: Genotype-phenotype correlations in Bardet-Biedl syndrome. *Arch Ophthalmol* 130: 901-907, 2012.
- Forsythe E, Kenny J, Bacchelli C and Beales PL: Managing Bardet-Biedl syndrome-now and in the future. *Front Pediatr* 6: 23, 2018.
- Li H, Ji CY, Zong XN and Zhang YQ: Body mass index growth curves for Chinese children and adolescents aged 0 to 18 years. *Zhonghua Er Ke Za Zhi* 47: 493-498, 2009 (In Chinese).
- Emmanuel M and Bokor BR: Tanner Stages. In: StatPearls [Internet]. Treasure Island (FL): StatPearls Publishing; 2022 Jan.
- Dai X, Gong Y, Tang Q, Cai T, Zhou S, Cheng Z, Yao S, Guo B and Xie Y: Chinese intelligence scale for young children: Item analysis, reliability, and National norms. *Chin J Clin Psychol* 6: 1-7, 1998.
- William Walter Greulich, S.Idell Pyle (eds): Radiographic atlas of skeletal development of hand and wrist. Vol 1. 2nd edition. Stanford University Press, Stanford, California, pp 161-165, 2017.
- Li H and Durbin R: Fast and accurate short read alignment with Burrows-Wheeler transform. *Bioinformatics* 25: 1754-1760, 2009.
- Danecek P, Auton A, Abecasis G, Albers CA, Banks E, DePristo MA, Handsaker RE, Lunter G, Marth GT, Sherry ST, *et al.*: The variant call format and VCFtools. *Bioinformatics* 27: 2156-2158, 2011.
- Robinson JT, Thorvaldsdóttir H, Winckler W, Guttman M, Lander ES, Getz G and Mesirov JP: Integrative genomics viewer. *Nat Biotechnol* 29: 24-26, 2011.
- Richards S, Aziz N, Bale S, Bick D, Das S, Gastier-Foster J, Grody WW, Hegde M, Lyon E, Spector E, *et al.*: Standards and guidelines for the interpretation of sequence variants: A joint consensus recommendation of the American college of medical genetics and genomics and the Association for molecular pathology. *Genet Med* 17: 405-424, 2015.
- Heras V, Castellano JM, Fernandois D, Velasco I, Rodríguez-Vazquez E, Roa J, Vazquez MJ, Ruiz-Pino F, Rubio M, Pineda R, *et al.*: Central ceramide signaling mediates obesity-induced precocious puberty. *Cell Metab* 32: 951-966.e8, 2020.
- Eckert-Lind C, Busch AS, Petersen JH, Biro FM, Butler G, Bräuner EV and Juul A: Worldwide secular trends in age at pubertal onset assessed by breast development among girls: A systematic review and meta-analysis. *JAMA Pediatr* 174: e195881, 2020.
- Grinson RP, Ropelato MG, Bedecarrás P, Loreti N, Ballerini MG, Gottlieb S, Campo SM and Rey RA: Gonadotrophin secretion pattern in anorchid boys from birth to pubertal age pathophysiological aspects and diagnostic usefulness. *Clin Endocrinol (Oxf)* 76: 698-705, 2012.
- Stagi S, di Tommaso M, Scalini P, Lapi E, Losi S, Bencini E, Masoni F, Dosa L, Becciani S and de Martino M: Triple X syndrome and puberty: Focus on the hypothalamus-hypophysis-gonad axis. *Fertil Steril* 105: 1547-1553, 2016.
- Abreu AP, Dauber A, Macedo DB, Noel SD, Brito VN, Gill JC, Cukier P, Thompson IR, Navarro VM, Gagliardi PC, *et al.*: Central precocious puberty caused by mutations in the imprinted gene MKRN3. *N Engl J Med* 368: 2467-2475, 2013.
- Leka-Emiri S, Chrousos GP and Kanaka-Gantenbein C: The mystery of puberty initiation: Genetics and epigenetics of idiopathic central precocious puberty (ICPP). *J Endocrinol Invest* 40: 789-802, 2017.
- Roberts SA and Kaiser UB: GENETICS IN ENDOCRINOLOGY: Genetic etiologies of central precocious puberty and the role of imprinted genes. *Eur J Endocrinol* 183: R107-R117, 2020.
- Ebrahim SAM, Talross GJS and Carlson JR: Slight of parasitoid wasps accelerates sexual behavior and upregulates a micropeptide gene in *Drosophila*. *Nat Commun* 12: 2453, 2021.
- Li L and Gong C: Central precocious puberty as a prelude of gonad dysplasia. *Pediatr Investig* 3: 50-54, 2019.



This work is licensed under a Creative Commons Attribution-NonCommercial-NoDerivatives 4.0 International (CC BY-NC-ND 4.0) License.