

New diagnostic and therapeutic procedures applied in pediatric esophageal achalasia in a pediatric tertiary center: A case series

DANIELA POP^{1,2}, RADU SAMUEL POP¹, TEODORA SURDEA BLAGA^{3,4}, LILIANA DAVID^{4,5},
CARMEN ASAVOAIE⁶, MARCEL TANTAU^{7,8}, DAN LUCIAN DUMITRASCU^{3,4} and DORIN FARCAU^{2,5}

¹Third Pediatric Discipline, Mother and Child Department, 'Iuliu Hațieganu' University of Medicine and Pharmacy;

²Third Pediatric Department, Clinical Emergency Hospital for Children, 400394 Cluj-Napoca; ³Second Medical Department, 'Iuliu Hațieganu' University of Medicine and Pharmacy, 400000 Cluj-Napoca; ⁴Gastroenterology Department, Second Medical Clinic, Emergency Clinical County Hospital, 400000 Cluj-Napoca; ⁵Nursing Discipline, Mother and Child Department, 'Iuliu Hațieganu' University of Medicine and Pharmacy, 400083 Cluj-Napoca;

⁶Department of Radiology, Clinical Emergency Hospital for Children, 400394 Cluj-Napoca; ⁷Third Medical Department, 'Iuliu Hațieganu' University of Medicine and Pharmacy; ⁸Department of Gastroenterology, Regional Institute of Gastroenterology and Hepatology, 400162 Cluj-Napoca, Romania

Received August 18, 2022; Accepted December 16, 2022

DOI: 10.3892/etm.2023.11800

Abstract. Achalasia is an esophageal motor disorder that is rare in children. While the condition is uncommon, it is especially difficult to diagnose in pediatric patients; however, the ability to form a diagnosis has progressed markedly with the advent of esophageal high-resolution manometry (HRM). The aim of the present study was to highlight particularities of the diagnosis, based on esophageal HRM, as well as the treatment of achalasia in children. The current study analyzed cases of achalasia from a single pediatric tertiary center, Clinical Emergency Hospital for Children (Cluj-Napoca, Romania). The clinical data and the results of the investigations of seven children with achalasia, the first children to be evaluated using esophageal HRM in the center, were reported. The patients were aged between 11 and 18 years. All the patients were newly diagnosed with achalasia, except for one. The duration of symptoms was between 4 months and 2 years in the newly diagnosed patients. All the patients were assessed with conventional esophageal manometry and/or esophageal HRM. A multidisciplinary team contributed to the diagnosis and the management of achalasia. A total of 4 children diagnosed with

type II achalasia were treated with peroral endoscopic myotomy (POEM) and 3 of the patients were treated with pneumatic dilations. Overall, achalasia is a rare but challenging condition in children. A diagnosis starts with a clinical suspicion based on swallowing disorders and upper digestive endoscopy, and is confirmed by esophageal HRM. Therapy should be adapted to the type of achalasia, the age of the children and the severity. In the present study, a relatively recent treatment option, POEM, was applied in pediatric patients with minor immediate adverse events. The report of these cases adds to the limited experience of using HRM and POEM in children with achalasia.

Introduction

Achalasia is a neurodegenerative disease affecting the inhibitory neurons in the myenteric plexus, which synthesize nitric oxide and vasoactive intestinal peptide. The inhibitory neurons in the muscular layer of the esophagus are affected by chronic inflammation and/or an autoimmune process, which leads to aganglionosis (1). The consequence of this defect is the incomplete relaxation and high pressure of the lower esophageal sphincter (LES) and the impaired peristalsis of the esophagus (2).

Over time, technical advances have allowed a shift from conventional esophageal manometry to high-resolution manometry (HRM) devices, increasing the diagnostic accuracy in esophageal motor disorders (3). By increasing the number of recording sites and reducing the space between them, either by water-perfused catheters or incorporated pressure sensors, esophageal HRM offers a functional mapping of the esophagus (3). HRM has been successfully used in adults, and it has led to the Chicago Classification (CC) of esophageal motor disorders (3). Soon after the studies in adults, pediatric studies followed (2). However, the small number of cases in the pediatric population makes it more difficult to standardize

Correspondence to: Dr Daniela Pop, Third Pediatric Department, Clinical Emergency Hospital for Children, 2-4 Campeni Street, 400394 Cluj-Napoca, Romania
E-mail: pop.daniela@umfcluj.ro

Abbreviations: UES, upper esophageal sphincter; LES, lower esophageal sphincter; HRM, high-resolution manometry; POEM, peroral endoscopic myotomy; IRP, integrated relaxation pressure; CC, Chicago Classification

Key words: achalasia, dysphagia, children, manometry, POEM

this procedure (2). HRM is a valuable tool in this age group, being easily and quickly performed, with good accuracy in identifying abnormal esophageal motor patterns (2).

The management of achalasia in children depends on the clinical experience and available diagnostic investigations in different centers (4). Access to esophageal HRM is still lacking in numerous parts of the world. In the past year, the Clinical Emergency Hospital for Children (Cluj-Napoca, Romania) had the opportunity to collaborate with colleagues from an adult gastroenterology department in order to diagnose achalasia in suspected pediatric cases using esophageal HRM.

The most effective therapeutic options in children with achalasia are pneumatic dilation and Heller myotomy (laparoscopic or classic) (2). Peroral endoscopic myotomy (POEM) is a relatively new procedure that is being used more frequently in children (2); however, there are only a few centers in the world where this treatment procedure is available (4).

The present study aimed to analyze the data from the first children diagnosed with achalasia using esophageal HRM, thanks to a collaboration between the Third Pediatric Department, Clinical Emergency Hospital for Children and the Gastroenterology Department, Second Medical Clinic, Emergency Clinical County Hospital, in Cluj-Napoca, Romania. A series of 7 cases is reported, which were evaluated between March 2021 and May 2022. The clinical data and results of the investigations are reviewed. All patients were assessed using conventional manometry and/or esophageal HRM. Both types of investigation were performed without sedation of the patients, after a fasting period of 8 to 12 h. We also present the treatment procedures applied in these patients and the immediate complications after the treatment.

Case series

Patients. The patients included in this study were sent to the Third Pediatric Department, Clinical Emergency Hospital for Children, Cluj-Napoca from all across Romania with the suspicion of achalasia. The present study included pediatric patients diagnosed with achalasia with HRM and to which a treatment procedure was already applied after being diagnosed with HRM. Patients who were not assessed with HRM and were only diagnosed based on conventional manometry were excluded. In addition, patients who were not yet treated after being diagnosed with HRM were excluded from the study.

Clinical data. Table I describes the clinical and demographic data of the patients. All the patients were newly diagnosed with achalasia, except for case 4 who had been previously diagnosed and was admitted to the Third Pediatric Department, Clinical Emergency Hospital for Children, 2 months after treatment with bougie dilation.

In all patients, the Eckardt score was calculated (5). This score assesses the presence and frequency (occasionally, daily or after each meal) of dysphagia, regurgitation and chest pain, and the weight loss (<5, 5-10, and >10 kg) (5). For each parameter and its severity, the patients received a score between 0 and 3. The maximum value of the Eckardt score is 12 (5).

The male patient described as case 1 first presented with dysphagia for solids and then for fluids. No weight loss was recorded and development had been normal. The patient had

been diagnosed with bronchial asthma at 2 years of age and had no family medical history of digestive or autoimmune diseases.

The female patient described as case 2 had experienced weight loss of 6 kg in the 7 months since symptom onset. No data regarding any significant family health history was found, and there was no previous personal medical history.

Regarding the male patient described as case 3, the patient's mother had autoimmune thyroiditis with hyperthyroidism and vitiligo. The antithyroid peroxidase antibodies of the patient were slightly increased, yet normal thyroid function was recorded.

Case 4 was a male patient previously diagnosed with autoimmune thyroiditis. A diagnosis of achalasia had been made 2 years before presenting to the department. The patient was treated using bougie dilation, but dysphagia, regurgitations and thoracic pain reappeared 2 months after this procedure. No weight loss was exhibited and none of the family members had been diagnosed with chronic diseases.

In the patients described as cases 2 and 4, total antinuclear antibodies were assessed, and the results were negative.

Cases 5, 6 and 7 had no family medical background or personal medical history of autoimmune disorders. The male patient described as case 5 had experienced weight loss of 3 kg in 3 weeks. The female patient described as case 6 had experienced weight loss of 15 kg in 6 months, and had the highest Eckardt score (5) of all of the patients. The male patient described as case 7 also presented with weight loss of 4.5 kg in 6 months.

Investigations. The neutrophil to lymphocyte ratio was calculated in all patients, by dividing the neutrophil count by the lymphocyte count. Normal ranges were considered between 0.99 and 1.76 (6). The ratio was assessed based on the results of the complete blood count obtained in the evaluation preceding treatment. Venous blood samples were collected from the patients in tubes with dipotassium ethylenediamine tetraacetic acid (concentration, 1.2-2.0 mg/ml blood). The complete blood count parameters were analyzed by an automatic hematological analyzer, the LabXpert 6800 (Shenzhen Mindray Bio-medical Electronics Co. Ltd.). The results are included in Table I. The mean \pm SD value of all patients was 1.99 ± 1.66 and the median was 1.47.

All patients were evaluated with a barium swallow, and they all presented with a 'bird's beak' appearance of the esophagus. The dilation of the esophagus was also measured in most of the patients, and the maximum value of these measurements is included in Table I. All patients underwent an upper digestive endoscopy and, in most of them, biopsy fragments were taken from the esophagus. The results are summarized in Table I.

Conventional esophageal manometry. A total of 4 patients were also investigated using conventional esophageal manometry. The device used for conventional manometry had a water perfusion system and was a Model PIP 48220S5 (Mui Scientific). The measured parameters were as follows: Resting pressure of the LES and upper esophageal sphincter (UES); amplitude, duration and length of the peristaltic waves in the esophageal body; and relaxation of the LES after wet swallows. The resting pressure of the LES in the 4 patients

Table I. Demographic, clinical and laboratory data of the patients.

Charateristics	Case 1	Case 2	Case 3	Case 4	Case 5	Case 6	Case 7
Demographic data							
Age, years	13	17	11	17	14	13	17
Sex	Male	Female	Male	Male	Male	Female	Male
Clinical variables							
BMI (percentile, Z score), kg/m ²	20.1 (69th, 0.50)	17.5 (6th, -1.54)	22.7 (93rd, 1.47)	20.2 (29th, -0.54)	13.5 (0, -3.98)	17.0 (22nd, -0.79)	19.9 (30th, -0.51)
Disease evolution, months	4	7	12	24	12	24	6
Chest pain	Yes	No	Yes	Yes	No	Yes	Yes
Dysphagia for solids	Yes	Yes	Yes	No	Yes	Yes	Yes
Dysphagia for liquids	Yes	Yes	Yes	Yes	Yes	No	Yes
Regurgitations	Yes	Yes	Yes	Yes	Yes	Yes	Yes
Heartburn	Yes	No	No	Yes	No	Yes	No
Cough	No	Yes	No	No	No	Yes	No
Weight loss	No	Yes	No	No	Yes	Yes	Yes
Eckardt score	6	6	5	5	7	11	6
Laboratory data and preoperative diagnostic studies							
Neutrophil to lymphocyte ratio	1.15	5.39	2.82	1.47	0.58	0.88	1.66
Barium swallow-dilation of the esophagus, mm	40.0	30.0	50.0	37.0	- ^a	- ^a	34.8
Histopathology exam of the biopsy fragments from the esophagus	No changes	3rd grade esophagitis	Esophageal candidosis	1st grade esophagitis	Not performed	1st grade esophagitis	3rd grade esophagitis

^aIn two of the patients the dilation of the esophagus was not measured. BMI, body mass index.

who were initially investigated with conventional esophageal manometry ranged between 44 and 50 mmHg, and that of the UES ranged between 55 and 80 mmHg. Relaxations of the LES were incomplete in all the patients. Patients had absent peristalsis in the esophageal body. Low amplitude waves were recorded in the esophageal body (20-30 mmHg). Most of these waves were measured with no propagation along the esophagus.

Esophageal HRM. Esophageal HRM recordings were performed in the Gastroenterology Department, Second Medical Clinic, Emergency Clinical County Hospital (Cluj-Napoca, Romania) for all of the aforementioned patients. The system used was the ISOLAB HR manometry system (Standard Instruments GmbH) attached to a solid-state catheter (Unisensor AG) with 36 sensors. The catheter was inserted transnasally and positioned with ≥ 3 sensors in the stomach. After a baseline recording of 2 min, 10 wet 5-ml swallows, spaced 30 sec apart, were performed. The manometry was performed in the supine position with the thorax angulated at 30°. The upper normal limit for integrated relaxation pressure (IRP), measured using the Unisensor AG probe, was set at 28 mmHg, according to the CC of esophageal motility disorders v3.0 criteria used at the time of diagnosis (5). The main parameters measured during esophageal HRM (Table II) were

IRP and the number of swallows followed by pan-esophageal pressurization.

Cases 1-3 and cases 5 and 6 had increased resting LES pressure, increased IRP and pan-esophageal pressurization, and were classified as having type II achalasia based on the CC v3.0 classification of esophageal motility disorders. A representative wet swallow recorded for case 1 is presented in Fig. 1, and several swallows of case 2 are presented in Figs. 2 and 3. In the fourth case (Fig. 4), esophageal HRM was performed after endoscopic dilation. In this case, the resting LES pressure was normal, the IRP was at the upper normal limit (28 mmHg) and there was no pan-esophageal pressurization. These measurements would be compatible with type I achalasia, according to the CC v3.0 classification, but this classification is intended to be used for patients who were not previously treated.

The treatment options and immediate complications after the treatment are also depicted in Table II.

Patients were/are followed up at 1, 6 and 12 months (for patients who were treated more recently, these data are incomplete). Clinical data were/are assessed at all visits. At 6 and 12 months, the patients were/are evaluated using upper digestive endoscopy and esophageal pH/impedance monitoring. In total, 2 patients (cases 2 and 4) were transferred to

Table II. Results of the high-resolution esophageal manometry, achalasia subtype, treatment and immediate complications after the treatment.

Case	Case 1	Case 2	Case 3	Case 4	Case 5	Case 6	Case 7
Resting pressure of the LES, mmHg	95.10±23.92	102.26±12.05	60.55±22.85	35.89±4.80	66.93±12.49	57.16±5.77	44.96±7.92
Median IRP, mmHg	61	82	50	28	60	47	40
Peristalsis	6/8 swallows with panesophageal pressurization	3/10 swallows with panesophageal pressurization	6/10 swallows with panesophageal pressurization	No pressurization	6/9 swallows with panesophageal pressurization	2/9 swallows with panesophageal pressurization	No pressurization
Resting pressure of the UES, mmHg	218.65±57.40	147.42±54.47	393.10±144.27	202.43±98.28	222.18±64.13	167.84±49.70	243.49±27.88
Achalasia subtype	II	II	II	I	II	II	I
Previous treatment	No	No	No	Dilation with bougies	No	No	No
Treatment	POEM	POEM	POEM	Pneumatic dilation	Pneumatic dilation	POEM	Pneumatic dilation
Immediate complications after the treatment	Minimal pneumoperitoneum	Mild pneumomediastinum	Minimal pneumoperitoneum	None	None	None	None
Medical treatment after the procedure	PPI	PPI	PPI	None	None	PPI	PPI

LES, lower esophageal sphincter; UES, upper esophageal sphincter; IRP, integrated relaxation pressure; POEM, peroral endoscopic myotomy; PPI, proton pump inhibitor.

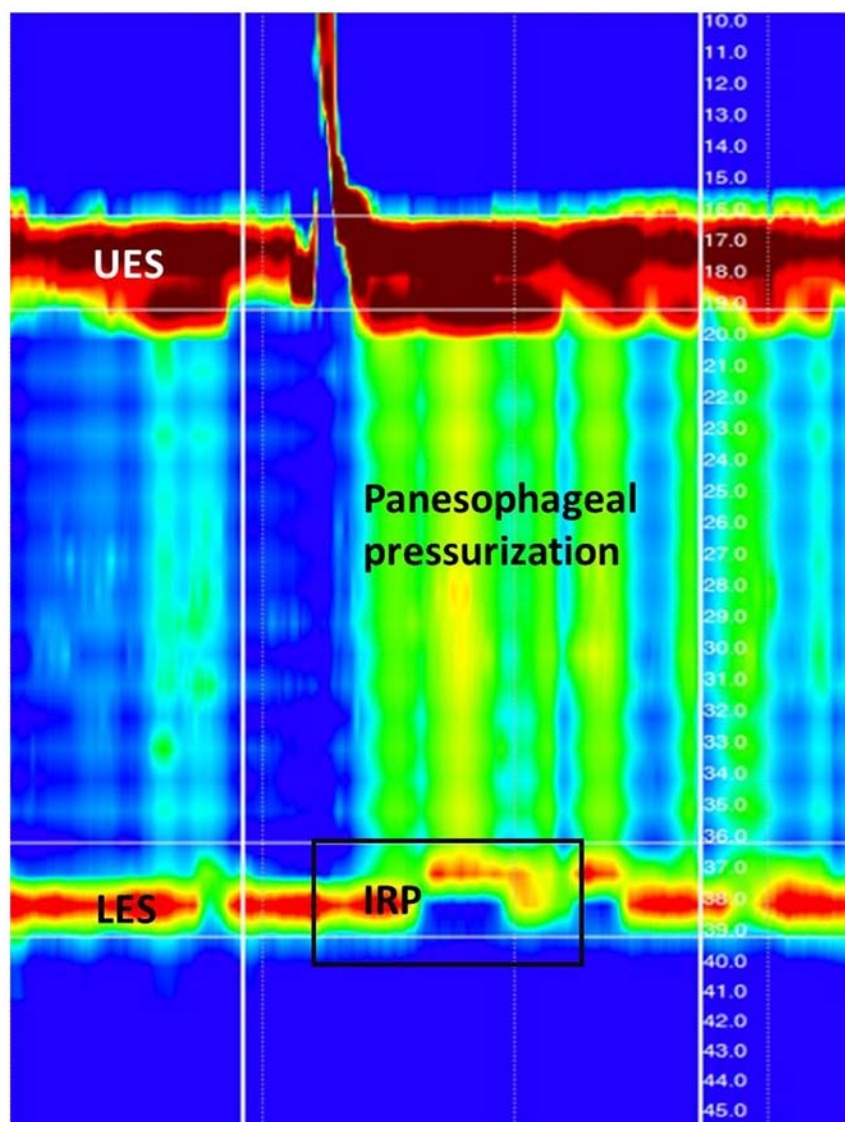


Figure 1. Esophageal high resolution manometry image showing a wet swallow (from case 1), with no LES relaxation during the swallow. There was also panesophageal pressurization (indicated by the green-yellow column extending from the UES to the LES). Pressure data are displayed as isobaric contour plots resembling topographic plots of geographical elevations (low pressures are represented in blue and high pressures in red). The distance from the nostril is depicted on the numbered scale: UES is localized at 16-19 cm, and the LES is at 36-39 cm. UES, upper esophageal sphincter; LES, lower esophageal sphincter; IRP, integrated relaxation pressure.

an adult gastroenterologist within 5 and 4 months, respectively, after the procedure due to Romanian legislation only allowing a pediatrician to follow patients until 18 years of age. Since the results of the follow-up assessments are yet to be available for all of the patients, they were not reported in the present study.

The present study was approved by the Ethics Committee of 'Iuliu Hațieganu' University of Medicine and Pharmacy (Cluj-Napoca, Romania) and written informed consent was obtained from both the parents of the patients and the patients themselves.

Discussion

Achalasia is an uncommon esophageal motor disorder that is rare in children (2). Although, its diagnosis has progressed markedly with the advent of esophageal HRM, there are few centers globally in which there is experience with new investigation methods and treatment options in children with

achalasia (4). Therefore, the aim of the present study was to highlight the particularities of the diagnosis of pediatric achalasia based on esophageal HRM, as well as its treatment, by contributing data from a series of cases recruited from across Romania.

The CC of esophageal motility disorders is based on the changes of the parameters assessed by HRM (3). However, the CC was conceived for adults, and there is still debate as to whether it can be applied in children (3).

Evaluating patients using esophageal HRM is essential, as the therapeutic approach and prognosis are different in the various subtypes of achalasia (3). Certain parameters determined in HRM are dependent on the age and length of the esophagus (7). A total of 7 patients, aged <18 years, were diagnosed with achalasia in our University Center and their cases reported in the present study. Evaluation of children with HRM was performed in the Gastroenterology Department, Second Medical Clinic, Emergency Clinical County Hospital

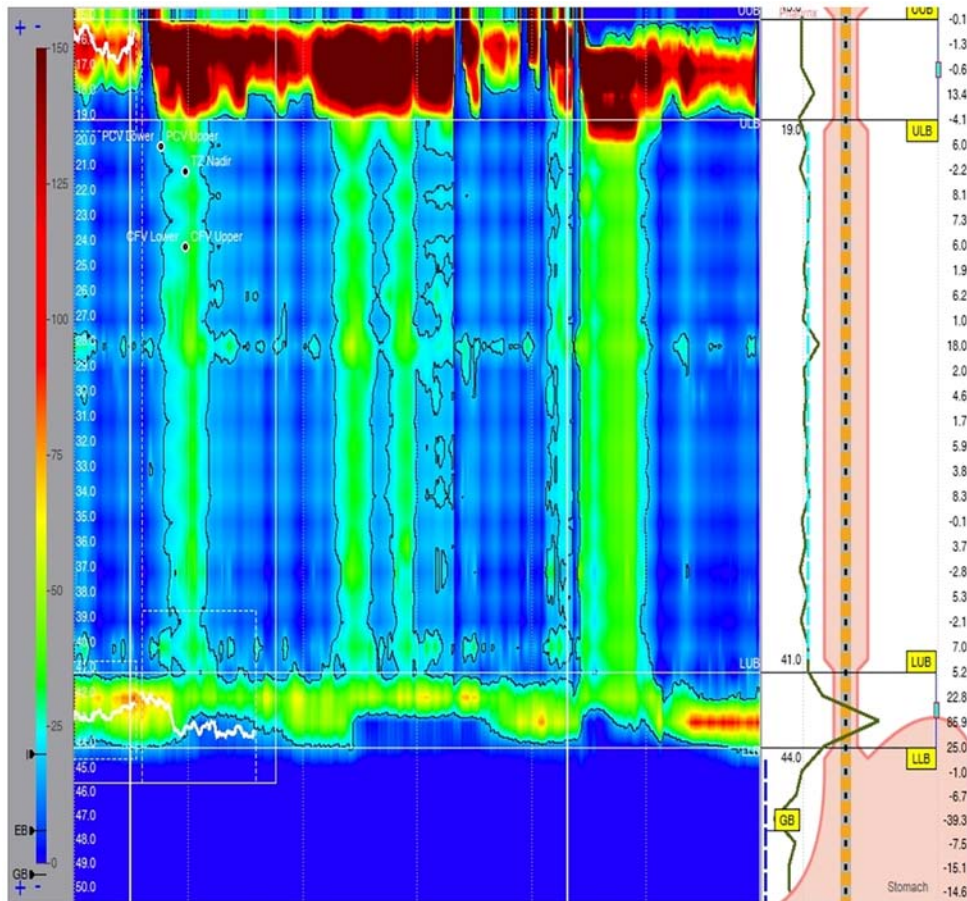


Figure 2. Esophageal high resolution manometry image showing two test swallows from case 2 followed by panesophageal pressurization, and no relaxation of the lower esophageal sphincter (therefore the integrated relaxation pressure was increased). The color legend is shown on the left in mmHg above gastric baseline pressure. The numbered scale on the left shows the distance from the nostril. The numbered scale on the right shows the pressures measured at different points in mmHg.

(Cluj-Napoca, Romania). A total of 6 patients were newly diagnosed and had no previous treatment, while one patient had already received dilation with bougies (with esophageal HRM having been performed after this procedure), but had persisting symptoms.

The symptom duration was between 4 months and 2 years in the newly diagnosed patients, and 2 years in the patient who had already received bougie endoscopic dilation (case 4). Dysphagia for solids and liquids was the most frequently reported symptom in the patients. Patel *et al* (8) found that weight loss in adult patients was correlated with phenotype, as patients with type II disease were more likely to have weight loss than type I. It was also noted that patients with a longer duration of symptoms did not have any weight loss. It was hypothesized that this was due to a lack of adaptation in patients with a shorter disease course. In the present study, 3 of the patients (cases 2, 6 and 7) had weight loss of between 4.5 and 15 kg in a period of 6-7 months.

In studies on a large number of patients, Nurko (9,10) found that 80% of children present with vomiting (most probably regurgitation, but interpreted as vomiting by parents), 76% with dysphagia, 61% with weight loss, 44% with respiratory symptoms (more frequent in younger ages), 38% with thoracic pain, 31% with growth failure and 21% with nocturnal regurgitations. All of the patients in the present study presented

with dysphagia, a cough was present in 2 patients and 1 patient reported bothersome nocturnal regurgitations.

The Eckardt score (5) is used in adult patients to evaluate the severity of achalasia. It has been argued that it has been developed for adults and that it does not take into consideration the impact of the disease on growth or insufficient weight gain (2,4). The etiology and physiopathology of achalasia are not fully understood. Studies showing autoantibodies against the myenteric plexus and infiltration of Auerbach's plexus predominantly with CD8⁺ T lymphocytes suggest an autoimmune mechanism in patients with achalasia (1). A study conducted by Romero-Hernández *et al* (11) identified an autoimmune disease in 16.7% of the adult patients with achalasia, and 68.4% of these patients had a familial history of autoimmunity. A positive family background for autoimmune diseases was identified in 1 patient in the present study (case 3), as the mother had been diagnosed with autoimmune thyroiditis with hyperthyroidism and vitiligo. This patient had a slightly increased number of antithyroid peroxidase antibodies. Another patient (case 4) has been diagnosed with autoimmune thyroiditis. The neutrophil to lymphocyte ratio has been reported as increased in adult patients with achalasia compared with that in healthy controls (12). In the current study, 2 of the patients (cases 2 and 3) had higher values (5.39 and 2.82, respectively) of this parameter than the mean value

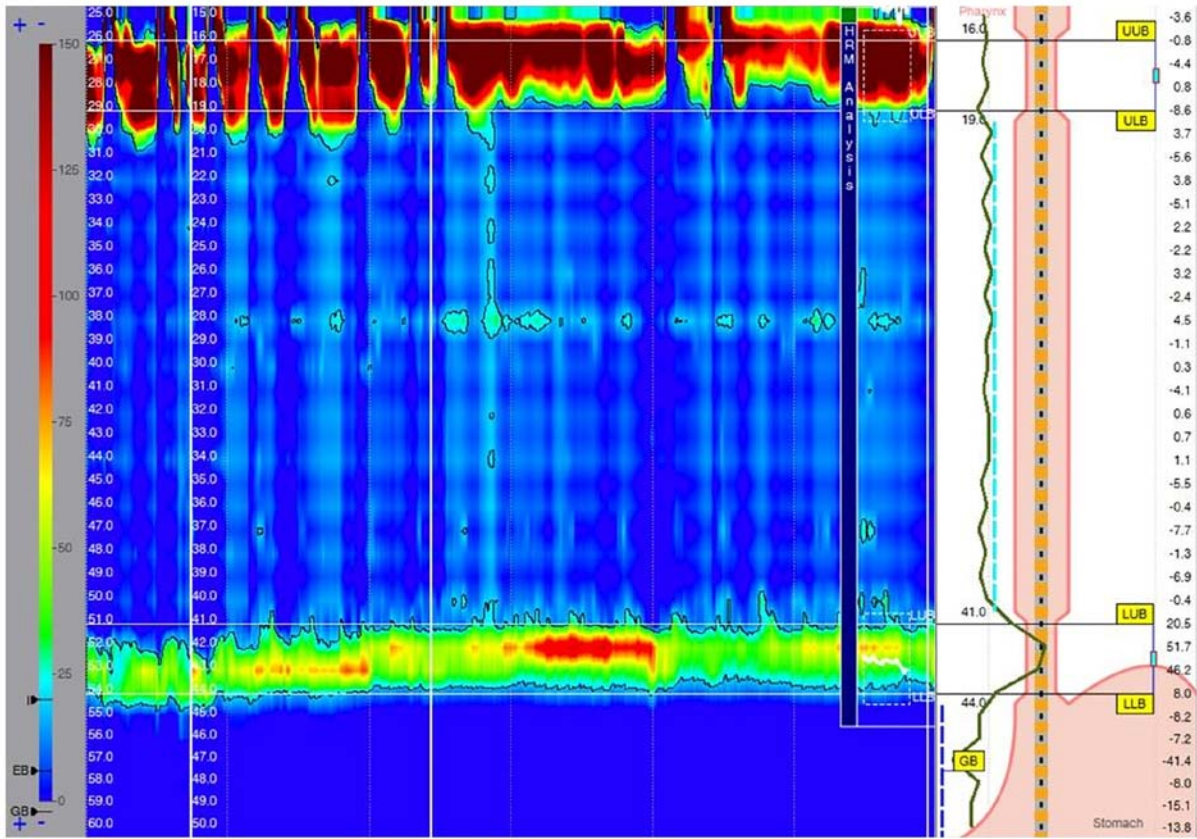


Figure 3. Esophageal high resolution manometry image depicting the first wet swallow of case 2. This was not followed by a peristaltic wave, and was therefore classified as failed. There was no relaxation of the lower esophageal sphincter. Several dry swallows are shown in the image, and none were followed by peristaltic waves.

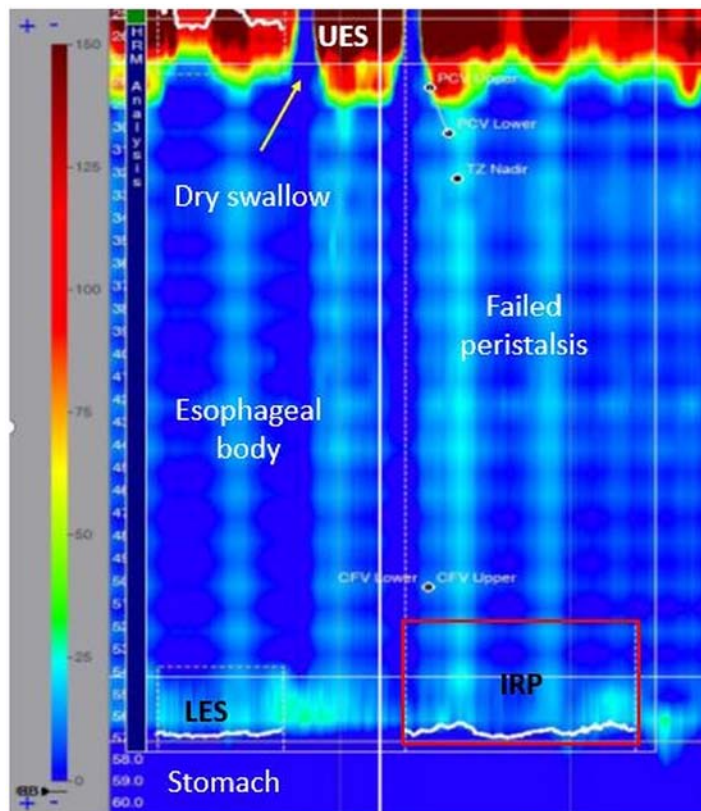


Figure 4. Esophageal high resolution manometry image depicting a wet swallow of case 4. The wet swallow was preceded by a dry swallow (indicated by the arrow). The resting pressure of the LES was normal, with little change during swallowing. There was no peristaltic wave, nor panesophageal pressurization. UES, upper esophageal sphincter; LES, lower esophageal sphincter; IRP, integrated relaxation pressure.

reported in healthy controls by López-Verdugo *et al* (12) The patients described as cases 5 and 6 had a neutrophil to lymphocyte ratio <1. As compared with cases 2 and 3, cases 5 and 6 had higher Eckardt scores (7 and 11, respectively). There was no difference between these two categories of patients regarding the subtype of achalasia. Case 2 had the highest LES pressure and IRP. van Lennep *et al* (4) performed a survey regarding current practices in managing pediatric achalasia. Access and experience in esophageal HRM limit its use in children with achalasia, and only one-third of the responders in this survey would change their therapeutic approach based on the evaluation by HRM and achalasia subtype.

Achalasia is a chronic, progressive disease, and treatment does not currently provide a cure (10). At present, the treatment options available are aimed at reducing the obstruction caused by the incomplete relaxation of the LES (10). Choosing the right treatment option can be challenging. The latest guidelines regarding management of achalasia in adults state that pneumatic endoscopic dilation, laparoscopic Heller myotomy and POEM are equally effective in type I and II achalasia, while POEM would be a better treatment option for type III achalasia, as it allows a more extensive myotomy (13). In children, there is no clear consensus thus far.

The novel therapeutic approach, POEM, was utilized in 4 of the patients described in the present study. POEM was first used in 2008 as a treatment option for adults with achalasia (14). A total of 14 years later, an increasing number of centers are reporting good results from this procedure in children affected by achalasia. In a review by van Lennep *et al* (4), POEM was available in children in only 11 (29%) of the reporting centers; 7 in Europe, 3 in North America and 1 in Asia. As opposed to Heller myotomy, POEM has the advantage of a shorter time needed for the procedure, a lower rate of complications and a shorter time spent in the hospital (15). The long-term clinical success rate of POEM in children with achalasia is higher than in adults, as shown by a meta-analysis by Zhong *et al* (16). The main long-term complication after POEM is gastroesophageal reflux disease (GERD). Inoue *et al* (17) suggested in a pilot study that completing POEM with endoscopic fundoplication might reduce the incidence of GERD. Given the high risk of GERD after POEM (in up to 60% of cases), the current guidelines for adults recommend endoscopic monitoring for GERD, and lifelong proton pump inhibitor therapy after POEM (18). GERD appears to be equally common as in adults after POEM in children after 4 years of follow-up, as reported in the study by Nabi *et al* (19). In systematic reviews, Sharp and St Peter (20) and Goneidy *et al* (21) concluded that no treatment option can yet be considered a standard in children with achalasia, as comparative data are still lacking. Goneidy *et al* (21) documented reports of 94 patients who underwent POEM. Even though the success rate has been shown to be high for this procedure (99.3%), it is nonetheless a new technique, and data regarding long-term follow-up are inconsistent (21). In the current study, the complication rate after this procedure was higher compared with that after Heller myotomy and endoscopic esophageal dilatation (24.4 vs. 12.8 and 5%, respectively). In the patients of the present study, adverse events after POEM were minor and resolved spontaneously (2 patients had a pneumoperitoneum and 1 had a pneumomediastinum).

Miao *et al* (22) reported observations on 21 patients diagnosed with achalasia, with a mean age of 5.5 years. All the patients were treated with POEM. Only one-half of the children were assessed by esophageal manometry (22). The mean pressure of the resting LES was 25.4 mmHg, with a range between 18.5 and 40 mmHg, which was lower than the values detected in the patients in the present study. It was suggested that POEM should be performed as soon as possible, before causing distension of the esophagus, since the complete incision of the circular muscle seemed to be therapeutic in children (22). In a more recent study, 17/19 patients (89%) experienced sustained symptomatic relief after POEM (23). As concluded by a recent review (24), POEM is a promising technique in the pediatric population, with a high efficacy and low rate of adverse events.

The clinical data and results of the investigations in 7 children with achalasia were reviewed in the present study, which is a small number of cases. A total of 4 patients were evaluated with both conventional and esophageal HRM. Both of these methods evaluate the motor function of the esophagus, but esophageal HRM allows a more accurate description of the relaxation of the LES and a global assessment of peristalsis (9).

There are still few centers with all the necessary resources (both technical and human) to evaluate and treat children with achalasia properly. The merit of the present study is that it demonstrates the novel investigations and treatment options currently available for children with achalasia. The 4 children with type II achalasia were the first patients treated with POEM in Cluj-Napoca in which a subtype was also established with esophageal HRM. The results from the present study and other studies (15,16,19-22,24,25) support this treatment option for children with achalasia. The team that contributed to the management of the patients in the present study comprised multiple specialists: Pediatric gastroenterologists (who performed the diagnostic endoscopy and conventional esophageal manometry), gastroenterologists specializing in adults (including one trained in POEM and pneumatic dilation), radiologists and a nurse who performed the esophageal HRM. POEM has been performed in adults in the center since 2013 (26) and in children since 2016 (25). A significant limitation of the present case series is its small number of subjects. The patients were not investigated for previous viral infections, and investigations for autoimmune disorders were incomplete. In addition, the follow-up data of the patients were not reported. The study will be completed in the future, with follow-up clinical data of the patients and surveillance endoscopy and esophageal pH-impedance monitoring for GERD included in an upcoming study.

In summary, the first cases of pediatric patients in our Cluj-Napoca, Romania, diagnosed with achalasia using esophageal HRM were reported in the present study. POEM was successfully performed in 4 children with type II achalasia, with only minor adverse events after the procedure.

Acknowledgements

Not applicable.

Funding

No funding was received.

Availability of data and materials

The datasets used and/or analyzed during the current study are available from the corresponding author on reasonable request.

Authors' contributions

DP made substantial contributions to the conception and design of the study, acquisition of clinical data and conventional esophageal manometry results, analysis and interpretation of the data, drafting of the manuscript, and ensuring that questions of accuracy or integrity of the work were appropriately investigated and resolved. RP also made a substantial contribution to the conception and design of the study, as well as the acquisition of clinical data, conventional esophageal manometry results and high-resolution esophageal manometry results, analysis and interpretation of the data. TB performed the high-resolution esophageal manometries, analyzed and interpreted the results, selected the images and contributed to the critical revision of intellectual content. LD performed the high-resolution esophageal manometries, and analyzed and interpreted the results. CA performed the barium-swallow tests in the patients and interpreted the images. DD performed the high-resolution esophageal manometries, analyzed and interpreted the results, and revised the work for important intellectual content. MT performed the peroral endoscopic myotomy and pneumatic dilatations in the patients, and also revised the work for important intellectual content. DF made a substantial contribution to the conception and design of the study, and the acquisition, analysis and interpretation of the data, revised the work for important intellectual content, and ensured that questions of accuracy or integrity of the work were appropriately investigated and resolved. DP and DF confirm the authenticity of all the raw data. All authors have read and approved the final manuscript.

Ethics approval and consent to participate

The present study was approved by the Ethics Committee of 'Iuliu Hațieganu' University of Medicine and Pharmacy (Cluj-Napoca, Romania) and written informed consent was obtained from the parents of the patients (approval no AVZ80; approval date, 28.03.2022).

Patient consent for publication

Written informed consent for the publication of the data was obtained from the parents of the patients and from the patients.

Competing interests

The authors declare that they have no competing interests.

References

1. Furuzawa-Carballeda J, Aguilar-León D, Gamboa-Domínguez A, Valdovinos MA, Nuñez-Álvarez C, Martín-del-Campo LA, Enríquez AB, Coss-Adame E, Svarch AE, Flores-Nájera A, *et al*: Achalasia-An autoimmune inflammatory disease: A cross-sectional Study. *J Immunol Res* 2015: 729217, 2015.
2. van Lennep M, van Wijk MP, Omari TIM, Benninga MA and Singendonk MMJ: Clinical management of pediatric achalasia. *Expert Rev Gastroenterol Hepatol* 12: 391-404, 2018.
3. Kahrilas PJ, Bredeoord AJ, Fox M, Gyawali CP, Roman S, Smout AJ and Pandolfino JE; International High Resolution Manometry Working Group: The Chicago classification of esophageal motility disorders, v3.0. *Neurogastroenterol Motil* 27: 160-174, 2015.
4. van Lennep M, van Wijk MP, Omari TIM, Salvatore S, Benninga MA and Singendonk MMJ; European Society for Paediatric Gastroenterology, Hepatology and Nutrition Motility Working Group: Clinical management of pediatric achalasia: A survey of current practice. *J Pediatr Gastroenterol Nutr* 68: 521-526, 2019.
5. Eckardt VF, Aigherr C and Bernhard G: Predictors of outcome in patients with achalasia treated by pneumatic dilation. *Gastroenterology* 103: 1732-1738, 1992.
6. Moosmann J, Krusemark A, Dittrich S, Ammer T, Rauh M, Woelfle J, Metzler M and Zierk J: Age- and sex-specific pediatric reference intervals for neutrophil-to-lymphocyte ratio, lymphocyte-to-monocyte ratio, and platelet-to-lymphocyte ratio. *Int J Lab Hematol* 44: 296-301, 2022.
7. Singendonk MM, Smits MJ, Heijting IE, van Wijk MP, Nurko S, Rosen R, Weijenberg PW, Abu-Assi R, Hoekman DR, Kuizenga-Wessel S, *et al*: Inter- and intrarater reliability of the Chicago Classification in pediatric high-resolution esophageal manometry recordings. *Neurogastroenterol Motil* 27: 269-276, 2015.
8. Patel DA, Naik R, Slaughter JC, Higginbotham T, Silver H and Vaezi MF: Weight loss in achalasia is determined by its phenotype. *Dis Esophagus* 31: 1-8, 2018.
9. Nurko S: Motility Disorders in Children. *Pediatr Clin North Am* 64: 593-612, 2017.
10. Nurko S: The Esophagus: motor disorders. In: *Pediatric Gastrointestinal disease*. Walker WA (ed). B.C. Decker Inc, Philadelphia, PA, pp317-350, 2000.
11. Romero-Hernández F, Furuzawa-Carballeda J, Hernández-Molina G, Alejandro-Medrano E, Nuñez-Álvarez CA, Hernández-Ramírez DF, Azamar-Llamas D, Olivares-Martínez E, Breña B, Palacios A, *et al*: Autoimmune comorbidity in achalasia patients. *J Gastroenterol Hepatol* 33: 203-208, 2018.
12. López-Verdugo F, Furuzawa-Carballeda J, Romero-Hernández F, Coss-Adame E, Valdovinos MA, Priego-Ranero A, Olvera-Prado H, Narváez-Chavez S, Peralta-Figueroa J and Torres-Villalobos G: Hematological indices as indicators of silent inflammation in achalasia patients: A cross-sectional study. *Medicine (Baltimore)* 99: e19326, 2020.
13. Vaezi MF, Pandolfino JE, Yadlapati RH, Greer KB and Kavitt RT: ACG clinical guidelines: Diagnosis and management of achalasia. *Am J Gastroenterol* 115: 1393-1411, 2020.
14. Inoue H, Minami H, Kobayashi Y, Sato Y, Kaga M, Suzuki M, Satodate H, Odaka N, Itoh H and Kudo S: Peroral endoscopic myotomy (POEM) for esophageal achalasia. *Endoscopy* 42: 265-271, 2010.
15. Lee Y, Brar K, Doumouras AG and Hong D: Peroral endoscopic myotomy (POEM) for the treatment of pediatric achalasia: A systematic review and meta-analysis. *Surg Endosc* 33: 1710-1720, 2019.
16. Zhong C, Tan S, Huang S, Peng Y, Lü M and Tang X: Clinical outcomes of peroral endoscopic myotomy for achalasia in children: A systematic review and meta-analysis. *Surg Endosc* 34: doaa112, 2021.
17. Inoue H, Ueno A, Shimamura Y, Manolakis A, Sharma A, Kono S, Nishimoto M, Sumi K, Ikeda H, Goda K, *et al*: Peroral endoscopic myotomy and fundoplication: A novel NOTES procedure. *Endoscopy* 51: 161-164, 2019.
18. Oude Nijhuis RAB, Zaninotto G, Roman S, Boeckxstaens GE, Fockens P, Langendam MW, Plumb AA, Smout A, Targarona EM, Trukhmanov AS, *et al*: European guidelines on achalasia: United European Gastroenterology and European Society of Neurogastroenterology and Motility recommendations. *United European Gastroenterol J* 8: 13-33, 2020.
19. Nabi Z, Ramchandani M, Basha J, Goud R, Darisetty S and Reddy DN: POEM is a durable treatment in children and adolescents with Achalasia Cardia. *Front Pediatr* 10: 812201, 2022.
20. Sharp NE and St Peter SD: Treatment of idiopathic achalasia in the pediatric population: A systematic review. *Eur J Pediatr Surg* 26: 143-149, 2016.

21. Goneidy A, Cory-Wright J, Zhu L and Malakounides G: Surgical management of esophageal achalasia in pediatrics: A systematic review. *Eur J Pediatr Surg* 30: 13-20, 2020.
22. Miao S, Wu J, Lu J, Wang Y, Tang Z, Zhou Y, Huang Z, Ying H and Zhou P: Peroral endoscopic myotomy in children with achalasia: A relatively long-term single-center study. *J Pediatr Gastroenterol Nutr* 66: 257-262, 2018.
23. Tashiro J, Petrosyan M and Kane TD: Current management of pediatric achalasia. *Transl Gastroenterol Hepatol* 6: 33, 2021.
24. Mencin AA, Sethi A, Barakat MT and Lerner DG: Peroral endoscopic myotomy (POEM) in children: A state of the art review. *J Pediatr Gastroenterol Nutr* 75: 231-236, 2022.
25. Choné A, Familiari P, von Rahden B, Desai P, Inoue H, Shimamura Y, Eleftheriadis N, Yamashita K, Khashab MA, Shiwaku H, *et al*: Multicenter evaluation of clinical efficacy and safety of per-oral endoscopic myotomy in children. *J Pediatr Gastroenterol Nutr* 69: 523-552, 2019.
26. Tefas C, Boroş C, Ciobanu L, Surdea-Blaga T, Tanţău A and Tanţău M: POEM: Five years of experience in a single East European Center. *J Gastrointestin Liver Dis* 29: 323-328, 2020.



This work is licensed under a Creative Commons Attribution-NonCommercial-NoDerivatives 4.0 International (CC BY-NC-ND 4.0) License.