SPANDIDOS PUBLICATIONS

EXPERIMENTAL AND THERAPEUTIC MEDICINE 25: 285, 2023

Multilocular thymic cyst detected during COVID-19 treatment in an HIV-positive adult man: A case report and literature review

HIROTO HATANO[1], RYUSUKE SUMIYA[1], KENTO MISUMI[2], HIDEKI MIYAZAKI[2], TAKESHI IKEDA[1] and SATOSHI NAGASAKA[1]

[1]Department of General Thoracic Surgery and [2]Pathology Division of Clinical Laboratory, National Center for Global Health and Medicine, Tokyo 162-8655, Japan

Received December 30, 2022; Accepted April 6, 2023

DOI: 10.3892/etm.2023.11984

Abstract. A multilocular thymic cyst (MTC) is a rare mediastinal tumor with multiloculated cyst-like structures in the anterior mediastinum. This tumfor is associated with inflammatory diseases, including human immunodeficiency virus (HIV) infection. The present study reports a case of MTC detected during coronavirus disease 2019 (COVID-19) treatment in an adult who was tested HIV positive. An anterior mediastinal tumor was incidentally detected on computed tomography in a 52-year-old man with a 20-year history of HIV infection on the 9th day of COVID-19. The patient was asymptomatic with no notable physical findings. Magnetic resonance imaging revealed a 28-mm bilocular cyst. Robot-assisted thoracoscopic tumor resection was performed. Pathological examination showed that the cyst was lined with squamous or cuboidal epithelium, and the cystic lesion wall was mainly composed of thymic tissue with follicular hyperplasia. Based on these findings, the patient was diagnosed with MTC. To date, only 15 MTC cases have been reported in patients with HIV, and the majority of cases showed HIV infection-related symptoms such as lymphoid interstitial pneumonia and parotid gland enlargement. The present case was atypical for an HIV-related MTC because it did not involve HIV infection-related symptoms, suggesting the possibility for an alternative etiology such as COVID-19. Further reports on MTC development in patients with COVID-19 are required to elucidate the relationship between MTC and COVID-19.

Introduction

A multilocular thymic cyst (MTC) is a rare mediastinal tumor which is recognized by a radiologic finding of a multiloculated cyst-like structure in the anterior mediastinum (1). It often develops following inflammatory diseases such as Sjogren's syndrome, human immunodeficiency virus (HIV) infection and acquired immunodeficiency syndrome (AIDS) (1). Because similar radiologic features can be observed in other tumors, such as thymoma, thymic carcinoma, Hodgkin lymphoma, and seminoma (2), a pathological examination is necessary for final diagnosis. Particularly, with the improvement in AIDS prognosis, HIV-associated tumor cases have been increasing, and caution needs to be exercised in differential diagnosis (3). MTC in people living with HIV/AIDS (PLWHA) often involves other HIV/AIDS-related symptoms such as lymphoid interstitial pneumonia (LIP) and parotid gland enlargement (4), and asymptomatic cases are rare.

Since the beginning of the coronavirus disease of 2019 (COVID-19) pandemic, COVID-19 has been associated with incidentalomas (5,6), as well as various complications owing to its pro-inflammatory behavior (7), including formation of the cystic lesions such as hepatic cyst enlargement (8) and pneumatocele formation (9,10). Severity of COVID-19 is known to be modified by co-infected pathogens, and individuals who are HIV-infected are reported to be at higher risk of severe disease (11,12). However, the relationship between COVID-19 and MTC development in PLWHA remains unknown. Here, we present a case of asymptomatic MTC that was incidentally found on a computed tomography (CT) scan during COVID-19 treatment in a male patient who was HIV positive.

Case report

A 52-year-old man with a 20-year history of HIV infection who was undergoing antiretroviral therapy was admitted to our hospital with a COVID-19 pneumonia. On CT scan performed on day 9 of COVID-19, an anterior mediastinal tumor was incidentally detected (Fig. 1). There was no history of smoking, and the clinical history included type-1 diabetes mellitus (Islet Antigen-2 antibody positive), hypertension, renal failure, and syphilis. The patient was asymptomatic with no notable findings on physical examination. Blood examination showed renal dysfunction (urea nitrogen, 25.7 mg/dl; creatinine, 2.41 mg/dl) and hyperglycemia (fasting blood sugar, 112 mg/dl; hemoglobin A1c, 8.3%; glycoalbumin, 21.0%). Rapid plasma reagin, Treponema pallidum antibody, HIV antigen, and HIV

Correspondence to: Dr Ryusuke Sumiya, Department of General Thoracic Surgery, National Center for Global Health and Medicine, 1-21-1 Toyama, Shinjuku, Tokyo 162-8655, Japan
E-mail: rsumiya@hosp.ncgm.go.jp

Key words: multilocular thymic cyst, human immunodeficiency virus, acquired immune deficiency syndrome, mediastinal tumor, robot-assisted surgery, case report

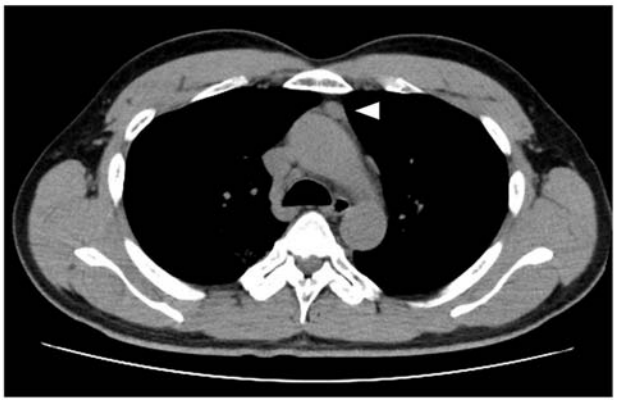

Figure 1. Computed tomography scan showing 22-mm anterior mediastinal tumor (white arrow).

antibody tests were positive. Anti-acetylcholine receptor antibody test was negative, ruling out the possibility of myasthenia gravis. There was no significant elevation in tumor markers, including human chorionic gonadotropin β, alpha-fetoprotein, squamous cell carcinoma antigen, cytokeratin 19 fragments, and carcinoembryonic antigen. Regarding HIV control, the cluster of differentiation 4 count was decreased (576/μl), and the HIV RNA load was less than 20 copies/ml. Magnetic resonance imaging revealed a 28-mm bilocular cyst. One of the two chambers showed low intensity on T1-weighted images and high intensity on T2-weighted images, whereas the other chamber showed high intensity on both T1-weighted and T2-weighted images. No infiltration of the capsule or adjacent organs was observed (Fig. 2). As malignancy could not be excluded, robot-assisted thoracoscopic resection of the anterior mediastinal tumor was performed.

Intraoperatively, the tumor was a cystic lesion within the thymus located just anterior to the pericardium and caudal to the left brachiocephalic vein. There were diffuse smaller cystic lesions within the thymus, and the non-cystic thymic tissue exhibited an uneven surface, suggesting hyperplasia. Thymectomy was performed. The resected tissue was composed of multiple cysts of various sizes containing exudative turbid yellow fluid (total protein, 6.3 g/dl; lactate dehydrogenase, 1676 U/L) with lymphocyte predominance (white blood cells, 44.0x10^3/l; lymphocyte, 94%).

Hematoxylin and eosin staining was performed on the formalin-fixed paraffin-embedded surgically resected thymic tissue sections of 4 μm thickness. A light microscope was used for observation. Pathologically, the cysts were lined with squamous or cuboidal epithelium. The cyst wall was primarily composed of thymic tissue with follicular hyperplasia, and Hassall's corpuscles were noted. Cholesterol granuloma formation adjacent to the cysts was also observed. Signs of malignancy were not observed (Fig. 3). Based on these findings, the patient was diagnosed with MTC. The postoperative course was uneventful, and the patient is currently being followed up at an outpatient clinic; to date there are no signs of recurrence.

Discussion

MTC is a rare disease, accounting for approximately 3% of anterior mediastinal tumors (13). It is recognized by a multiloculated cyst-like structure in the anterior mediastinum on CT, and a pathological examination is necessary for final diagnosis. Pathologically, the inner surface of the cysts is lined by cuboidal, squamous, or columnar epithelia. The cyst wall comprises thymic tissue containing Hassall's corpuscles and hyperplastic lymphoid follicles with a well-formed germinal center. Hyalinization, calcification, and cholesterol granuloma formation can also be observed within the cyst walls (1,14). MTC is associated with inflammatory diseases, including human immunodeficiency virus (HIV) infection and acquired immunodeficiency syndrome (AIDS). In our case, MTC developed in a man who was HIV positive. Although a bilocular cyst in the anterior mediastinum was observed on imaging, the resected thymic tissue exhibited a multiloculated cyst formation. The pathological findings were consistent with typical MTC characteristics.

To further understand the clinical characteristics of MTC in PLWHA, a literature review was conducted. Literature was collected through a PubMed search under the following query: ((multilocular thymic cyst[Title]) OR (multilocular thymic cysts[Title])) AND ((hiv[Title]) OR (human immunodeficiency virus[Title]) OR (acquired immunodeficiency syndrome[title]) OR (aids[title])). A total of seven studies reported 15 cases reported on MTC in PLWHA (4,15-20). The main clinical characteristics of the 16 cases, including ours, are listed in Table S1 and its summary is presented in Table I. MTC in PLWHA is most commonly reported in children, with 12 of the

Table I. Summary of 16 cases (15 previous cases and the present case) of multilocular thymic cyst in people living with HIV/acquired immunodeficiency syndrome.

Characteristics	Total
Median age, years (range)	10 (2-52)
Age, n (%)	
<15 years	12 (75)
15-35 years	0 (0)
>35 years	4 (25)
Male sex, n (%)	11 (68.8)
Median $CD4^+$ T-cell count, n (IQR)	308 (191-416)
Median HIV-positive years, years (IQR)	9 (3-11.5)
Associated symptoms, n (%)	
LIP	7 (43.8)
Lymphadenopathy	6 (37.5)
Parotid gland enlargement	5 (31.3)
Hepatic enlargement	5 (31.3)
Chest pain	4 (25)
Fever	2 (12.5)
Cough	1 (6.3)
None	1 (6.3)
Surgical intervention, n (%)	
Yes	7 (43.8)
No	9 (56.2)

IQR, interquartile range; LIP, lymphoid interstitial pneumonia; HIV, human immunodeficiency virus.

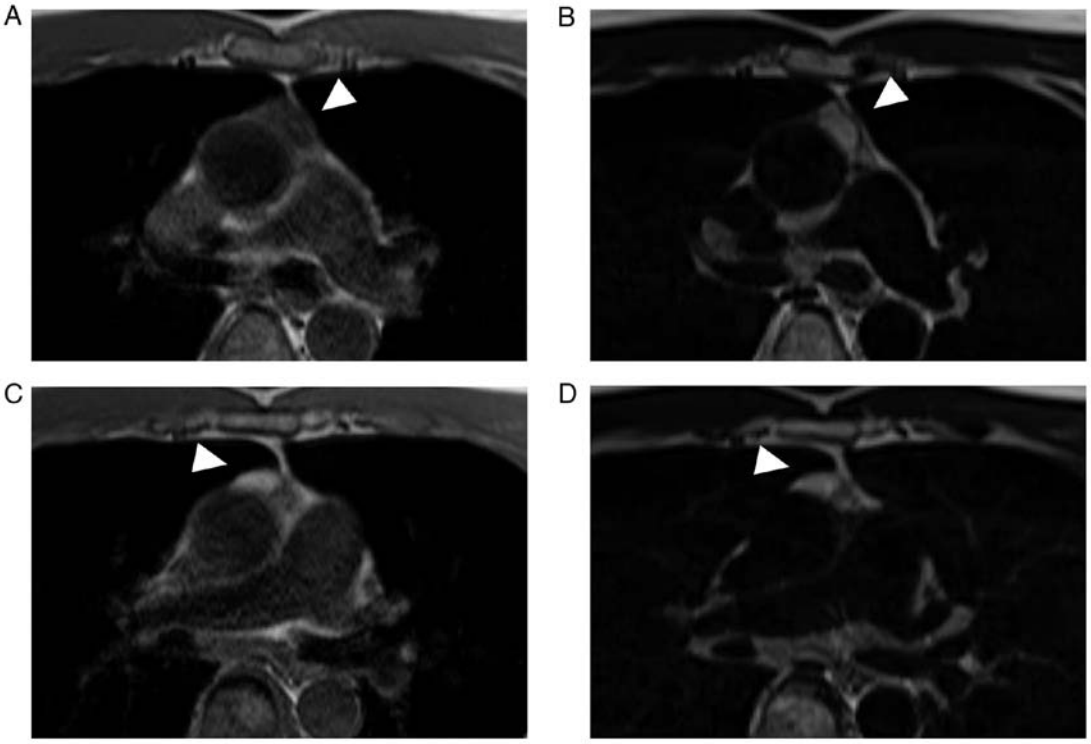

Figure 2. Magnetic resonance images showing a 28-mm bilocular cyst (white arrow). One of the two chambers shows (A) low intensity on T1-weighted images and (B) high intensity on T2-weighted images, whereas the other chamber shows high intensity on both (C) T1-weighted and (D) T2-weighted images.

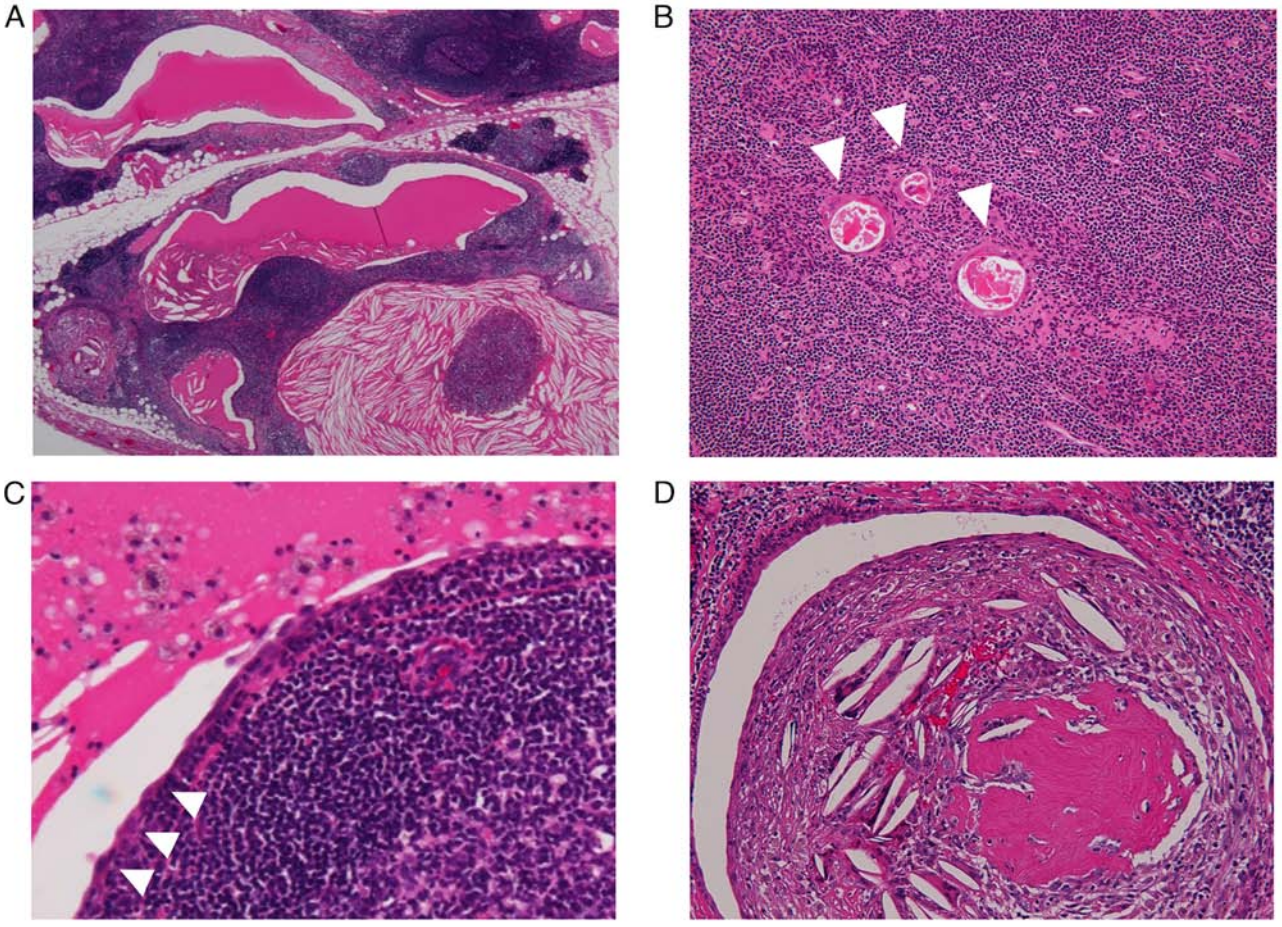

Figure 3. Pathology of resected tissue. The cyst wall is mainly composed of thymic tissue with (A) follicular hyperplasia (magnification, x12.5) and (B) Hassall's corpuscles are observed (white arrows) (magnification, x40). Cysts are lined by (C) squamous (white arrows) or cuboidal epithelium, x100. (D) Cholesterol granuloma formation is also observed (magnification, x40).

16 cases occurring at the age of 15 years or younger. Four cases including ours occur in adults, with age of onset in middle age ranging from 35 to 52 years old (4,16,19). Most of the cases had only mildly reduced CD4 counts, with a median CD4 count of 308/μl. Median time from HIV infection to MTC development was 9 years, with 10 of 16 cases developed within 10 years after HIV infection. Our case has a 21-year history of HIV infection and a relatively high CD4 count of 576/μl, which is atypical compared to previous cases. Most patients had comorbidities or symptoms such as LIP and parotid gland enlargement, and only one patient was asymptomatic (15). Asymptomatic case was a pediatric case, with no obvious differences in CD4 counts or duration of HIV infection compared to other cases. Seven of the 16 patients underwent tumor resection, and the others were followed up without surgical intervention. There have been no reports of postoperative recurrence. In five of the nine patients who did not undergo surgical intervention, the tumor resolved or decreased in size. One patient showed tumor enlargement during the first six months after diagnosis, but the size stabilized thereafter (15). Of the remaining three cases, tumor diameter remained unchanged in one case and the post-diagnostic course was not stated in two cases (4,15,19). Although MTC must be differentiated from other malignant tumors, it is associated with a good prognosis when accurately diagnosed using needle biopsy or based on findings during resection.

Our case was atypical for an HIV-related MTC because it did not involve the typical comorbidities associated with HIV infection. Considering that MTC was detected on the 9th day of SARS-CoV-2 infection, it is possible that the MTC was associated with COVID-19. While there have been no reports of MTC development related to COVID-19, cystic lesions such as hepatic cyst enlargement (8) and pneumatocele formation (9,10) have been found to be associated with COVID-19. Furthermore, patients with COVID-19 commonly exhibit thymus hyperplasia, which is seen in the context of MTC (21). Our case alone cannot prove the etiological relationship between COVID-19 and MTC development; however, previous reports suggest the possibility for this relationship. Biologically, the expression of angiotensin-converting enzyme 2 and type 2 transmembrane serine proteases, which are SARS-CoV-2 receptors and proteases (22), has not yet been quantified in the thymus, and the affinity of SARS-CoV-2 for the thymus remains unknown. More case reports on MTC development in patients with COVID-19 and related biological investigations are needed for further discussion on the relationship between COVID-19 and MTC development.

In conclusion, we encountered a rare case of MTC detected during COVID-19 evaluation and treatment in an adult living with HIV. More reports on MTC cases in patients with COVID-19 are needed to elucidate the relationship between MTC and COVID-19.

Acknowledgements

Not applicable.

Funding

This study was supported by the National Center for Global Health and Medicine COVID-19 Gift Fund.

Availability of data and materials

The datasets used and/or analyzed during the current study are available from the corresponding author on reasonable request.

Authors' contributions

HH and RS acquired data and wrote the manuscript. KM and HM analyzed and interpreted pathology data. TI and SN made substantial contributions to conception and design. HH and RS confirm the authenticity of all the raw data. All authors read and approved the manuscript.

Ethics approval and consent to participate

Not applicable.

Patient consent for publication

Written informed consent was obtained from the patient for publication of this report and any accompanying images.

Competing interests

The authors declare that they have no competing interests.

References

1. Suster S and Rosai J: Multilocular thymic cyst: An acquired reactive process. Study of 18 cases. Am J Surg Pathol 15: 388-398, 1991.
2. Oramas DM and Moran CA: Multilocular thymic cyst (MTC) and other tumors with MTC features: Pitfalls in diagnosis. Semin Diagn Pathol 39: 105-112, 2022.
3. Yarchoan R, Ramaswami R and Lurain K: HIV-associated malignancies at 40: much accomplished but much to do. Glob Health Med 3: 184-186, 2021.
4. Leonidas JC, Berdon WE, Valderrama E, Neveling U, Schuval S, Weiss SJ, Hilfer C and Godine L: Human immunodeficiency virus infection and multilocular thymic cysts. Radiology 198: 377-379, 1996.
5. Gokce A, Hatipoglu M, Kandemir NO and Akkas Y: Thoracic incidentaloma in a chest computed tomography scan of a patient with COVID-19. Br J Hosp Med (Lond) 82: 1-3, 2021.
6. Huynh I: When COVID-19 saves lives: Accidental cancer diagnosis in an epidemic context. Ethics Med Public Health 18: 100666, 2021.
7. Anka AU, Tahir MI, Abubakar SD, Alsabbagh M, Zian Z, Hamedifar H, Sabzevari A and Azizi G: Coronavirus disease 2019 (COVID-19): An overview of the immunopathology, serological diagnosis and management. Scand J Immunol 93: e12998, 2021.
8. D'Amico FE, Glavas D, Noaro G, Bassi D, Boetto R, Gringeri E, De Luca M and Cillo U: Case report: Liver cysts and SARS-CoV-2: No evidence of virus in cystic fluid. Front Surg 8: 677889, 2021.
9. Shi H, Han X, Jiang N, Cao Y, Alwalid O, Gu J, Fan Y and Zheng C: Radiological findings from 81 patients with COVID-19 pneumonia in Wuhan, China: A descriptive study. Lancet Infect Dis 20: 425-434, 2020.
10. Hamad AM and El-Saka HA: Post COVID-19 large pneumatocele: Clinical and pathological perspectives. Interact Cardiovasc Thorac Surg 33: 322-324, 2021.
11. Malekifar P, Pakzad R, Shahbahrami R, Zandi M, Jafarpour A, Rezayat SA, Akbarpour S, Shabestari AN, Pakzad I, Hesari E, *et al*: Viral coinfection among COVID-19 Patient Groups: An update systematic review and meta-analysis. Biomed Res Int 2021: 5313832, 2021.
12. Soltani S, Zakeri A, Zandi M, Kesheh MM, Tabibzadeh A, Dastranj M, Faramarzi S, Didehdar M, Hafezi H, Hosseini P and Farahani A: The role of bacterial and fungal human respiratory microbiota in COVID-19 Patients. Biomed Res Int 2021: 6670798, 2021.

13. Davis RD Jr, Oldham HN Jr and Sabiston DC Jr: Primary cysts and neoplasms of the mediastinum: Recent changes in clinical presentation, methods of diagnosis, management, and results. Ann Thorac Surg 44: 229-237, 1987.
14. Izumi H, Nobukawa B, Takahashi K, Kumasaka T, Miyamoto H, Yamazaki A, Sonobe S, Uekusa T and Suda K: Multilocular thymic cyst associated with follicular hyperplasia: Clinicopathologic study of 4 resected cases. Hum Pathol 36: 841-844, 2005.
15. Kontny HU, Sleasman JW, Kingma DW, Jaffe ES, Avila NA, Pizzo PA and Mueller BU: Multilocular thymic cysts in children with human immunodeficiency virus infection: Clinical and pathologic aspects. J Pediatr 131: 264-270, 1997.
16. Shi X, Nasseri F, Berger DM and Nachiappan AC: Large multilocular thymic cyst: A rare finding in an HIV positive adult female. J Clin Imaging Sci 2: 55, 2012.
17. Tamagno M, Bibas BJ, Bernardi F, Lian YC, Bammann RH, Fernandez A and Jatene FB: Giant multilocular thymic cyst in an HIV-infected adolescent. J Pediatr Surg 46: 1842-1845, 2011.
18. Mishalani SH, Lones MA and Said JW: Multilocular thymic cyst. A novel thymic lesion associated with human immunodeficiency virus infection. Arch Pathol Lab Med 119: 467-470, 1995.
19. Chhieng DC, Demaria S, Yee HT and Yang GC: Multilocular thymic cyst with follicular lymphoid hyperplasia in a male infected with HIV. A case report with fine needle aspiration cytology. Acta Cytol 43: 1119-1123, 1999.
20. Shalaby-Rana E, Selby D, Ivy P, Schutzbank T, Chan M, Chandra R and Majd M: Multilocular thymic cyst in a child with acquired immunodeficiency syndrome. Pediatr Infect Dis J 15: 83-86, 1996.
21. Cuvelier P, Roux H, Couëdel-Courteille A, Dutrieux J, Naudin C, Charmeteau de Muylder B, Cheynier R, Squara P and Marullo S: Protective reactive thymus hyperplasia in COVID-19 acute respiratory distress syndrome. Crit Care 25: 4, 2021.
22. Hoffmann M, Kleine-Weber H, Schroeder S, Krüger N, Herrler T, Erichsen S, Schiergens TS, Herrler G, Wu NH, Nitsche A, *et al*: SARS-CoV-2 cell entry depends on ACE2 and TMPRSS2 and is blocked by a clinically proven protease inhibitor. Cell 181: 271-280.e8, 2020.