

Primary intra-abdominal desmoid fibromatosis associated with familial adenomatous polyposis: A case report

LEI ZHANG¹, YAOTUN ZHENG², XIAOQIAN YU³, KANG YU⁴ and SHENGJIE ZHU⁵

Departments of ¹Hepatobiliary Surgery, ²Anesthesia and ³Obstetrics, Weihai Central Hospital, Weihai, Shandong 264200; ⁴Department of Research and Development, Tianjin Lianchuang Technology Development Co., Ltd., Tianjin 300000; ⁵Department of Oncology, Weihai Central Hospital, Weihai, Shandong 264200, P.R. China

Received August 6, 2022; Accepted February 15, 2023

DOI: 10.3892/etm.2023.12007

Abstract. Desmoid fibromatosis (DF) is a clonal proliferative disorder of myofibroblasts, which arises, with a low incidence, in soft tissue, including within the abdomen. The incidence of DF is associated with familial adenomatous polyposis (FAP), and is more common following FAP surgery. It is rare for a patient to make his/her first visit to hospital due to DF symptoms associated with FAP. In the present report, a case of mesenteric DF associated with FAP is described. This case also had incomplete intestinal obstruction due to DF. By summarizing previous studies examining DF and FAP treatment, combined with the disease characteristics of this patient, the clinical treatment strategy for DF associated with FAP was explored.

Introduction

Desmoid fibromatosis (DF) is prone to recurrence following surgery, with a high local recurrence rate of 17.6-30.7% (1-4). Surgery is the preferred treatment for familial adenomatous polyposis (FAP), and DF usually occurs after FAP surgery (5). The incidence of DF in patients with FAP ranges between 10 and 30% and is 1,000 times higher than that noted in the general population (5,6). Based on the disease characteristics of DF, it may be stable for a long time or even subside naturally (7). Meanwhile, mesenteric DF surgery can easily cause short bowel syndrome, affecting the quality of life of patients. After performing FAP radical surgery, it is therefore feasible to choose a waiting strategy for DF observation. An additional summary of clinical cases and findings of evidence-based medicine is required in future for effective evaluation.

Case report

A 32-year-old male patient was admitted to Weihai Central Hospital (Weihai, China) in October 2021 due to experiencing abdominal pain and distension for 3 days. The abdominal pain was paroxysmal dull pain around the umbilicus, which was without other radiating pain. There was no history of surgery or trauma. The family history revealed adenomatous polyposis coli (APC) in both the mother and sister; the mother had passed away due to colon cancer. Physical examination indicated a slightly distended abdomen, an absence of gastrointestinal type or peristaltic waves and the lack of abdominal wall varices. The examination further revealed periumbilical tenderness, absence of rebound tenderness and lack of abdominal muscle tension. No significant mass was obvious in the whole abdomen. Both Murphy's sign and shifting dullness were negative. The abdomen plain computed tomography (CT; Fig. 1A) indicated a slightly low-density shadow of ~4.8x5.7 cm in the abdominal cavity, surrounded by a dilated intestinal canal, and a liquid-gas interface. In contrast-enhanced CT (Fig. 1B), the solid lesion exhibited mild-to-moderate enhancement with fairly clear margins. In summary, the patient was diagnosed with an abdominal space-occupying lesion (considering the source of mesenchyme) with intestinal obstruction.

The admission diagnosis was abdominal occupancy and incomplete intestinal obstruction. Due to intestinal obstruction, it was not possible to perform bowel preparation. The patient was examined by gastroscopy. The mucosa of the gastric fundus, body and sinuses were congested. Dozens of polyps were scattered at the gastric mucosa, the largest one was ~6 mm in diameter, and the surface was congested (Fig. 2A and B). Chronic inflammation of the mucosa with erosion and reactive hyperplasia of specific glands was noted by gastroscopic biopsy (Fig. 2C).

Conservative treatment methods, including diet prohibition, gastrointestinal decompression and parenteral nutrition, did not relieve the intestinal obstruction. A laparoscopic exploration was accordingly performed. Intraoperatively, a coiled small intestinal canal was detected, which was found to adhere to the tumor. Following loosening of the adhesion, the tumor was located at the root of the small intestine mesentery, surrounded by inflammatory exudation, without invasion of the intestinal wall. Considering the family history of the patient, FAP could

Correspondence to: Mrs. Shengjie Zhu, Department of Oncology, Weihai Central Hospital, 3 West Mishan East Road, Weihai, Shandong 264200, P.R. China
E-mail: zhushengjie1981@163.com

Key words: intra-abdominal desmoids fibromatosis, familial adenomatous polyposis, treatment strategy

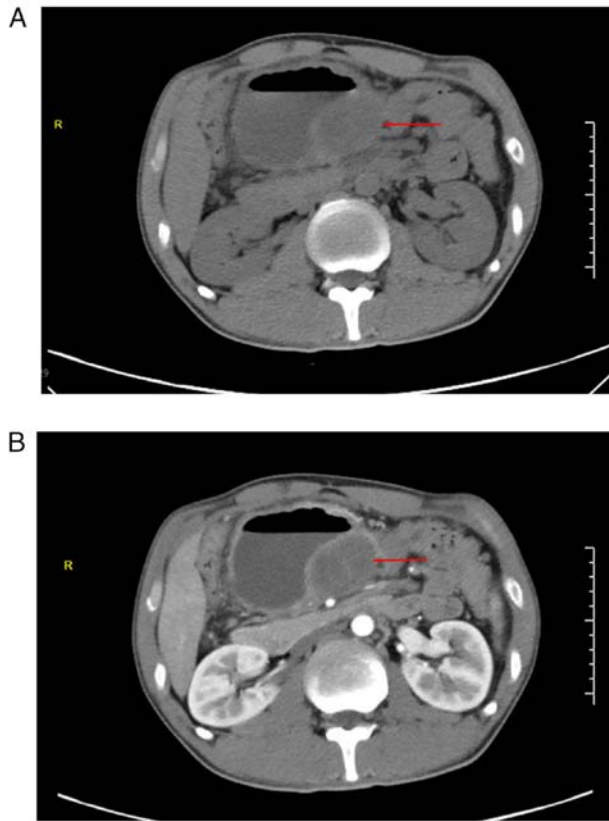


Figure 1. Preoperative imaging examination of patients. (A) Abdominal plain CT. The red arrow indicates an intra-abdominal tumor (~4.8x5.7 cm) surrounded by a dilated intestinal canal and a liquid-gas interface. (B) Abdominal contrast-enhanced CT. The red arrow indicates an intraperitoneal mass. The solid lesion showed mild-to-moderate enhancement with fairly clear margins. CT, computed tomography.

not be excluded; therefore, the mesenteric mass was biopsied. Microscopically, proliferating spindle cells arranged in bundles, with mild cell morphology and interstitial collagenization with mucus degeneration (Fig. 3A-C). The postoperative pathology was invasive fibromatosis (also known as DF) with the following immunohistochemical results noted: β -catenin (partial nuclear positive), smooth muscle actin (partial positive), desmin (scattered positive), CD117 (negative), Ki-67 (positive; 5%), CD34 (vascular positive), S-100 (negative) and SRY-box transcription factor 10 (negative) (Fig. 3D-K).

IHC staining was performed on a BenchMark XT (Roche Diagnostics) automatic IHC staining device. All procedures were performed as per the manufacturer's protocols. The endogenous peroxidases and protein were blocked using the Endogenous Biotin Blocking kit (cat. no. PV-6000; OriGene Technologies, Inc.) at 37°C for 4 min. The following primary antibodies were used: Anti- β -catenin (cat. no. ZA-0646; working solution), anti-SMA (cat. no. ZM-0003; working solution), anti-desmin (cat. no. ZA-0610; working solution), anti-CD117 (cat. no. ZA-0523; working solution), anti-Ki-67 (cat. no. ZM-0166; working solution), anti-CD34 (cat. no. ZA-0550; working solution), anti-S-100 (cat. no. ZA-0225; working solution) and anti-SOX10 (cat. no. ZA-0624; working solution) (all OriGene Technologies, Inc.). Primary antibodies were added and incubated for 15 min at 37°C. A light microscope was used for observation.

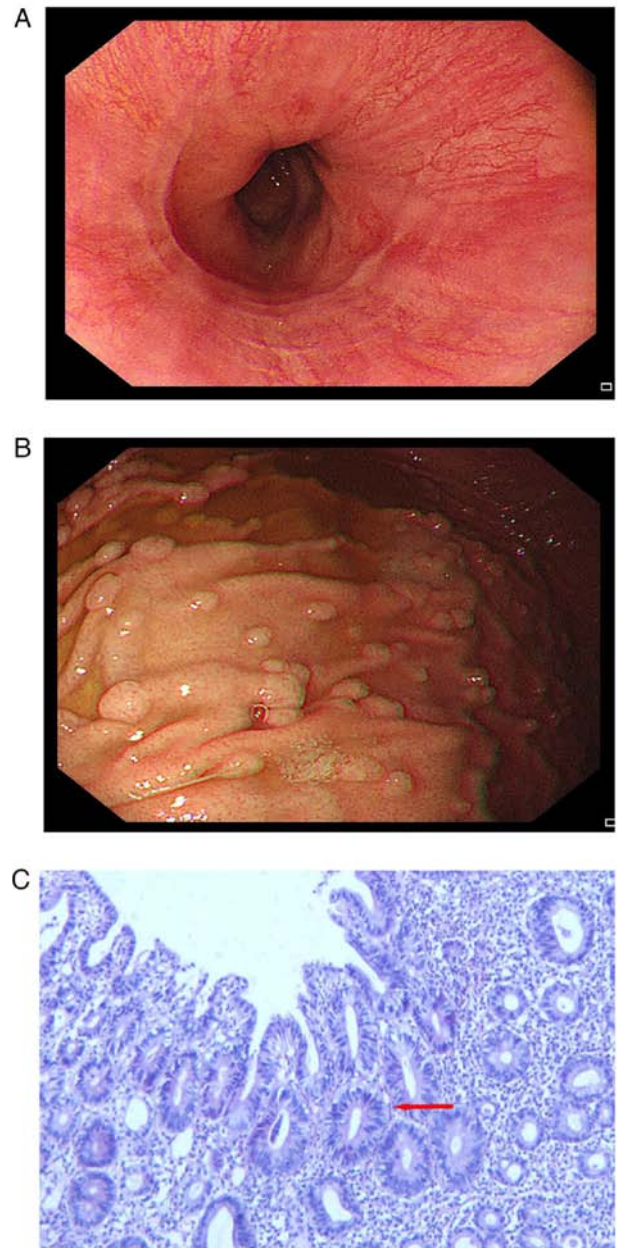


Figure 2. Gastroscopy and pathology. (A) Gastroscopic image of esophageal mucosa. (B) Gastroscopic image of gastric mucosa. The mucosa of the gastric sinus was also congested. (C) Pathological specimens from gastroscopy showed chronic inflammation of the mucosa with erosion and reactive hyperplasia of some glands. The red arrow indicates reactive hyperplastic glands (H&E; magnification, x200).

Following the operation, the intestinal obstruction of the patient was relieved. Colonoscopy examination (Fig. 4A) indicated dense and flat polyps 3-10 mm in diameter in the total colon and rectum. A lobulated polyp of ~25 mm in diameter with dilated surface ducts was detected ~40 cm from the anal verge (Fig. 4B). Multiple subplial lobulated polyps 10-15 mm in diameter were detected ~27 cm from the anal verge (Fig. 4C). No abnormal signs were detected in the anal canal. A confined operation of total proctocolectomy (TPC) with ileal pouch-anal anastomosis (IPAA) was performed. Two macroadenomas and hundreds of tubular adenomas were removed. Postoperative pathology of the two large adenomas: Adenoma 1 was a tubular adenoma

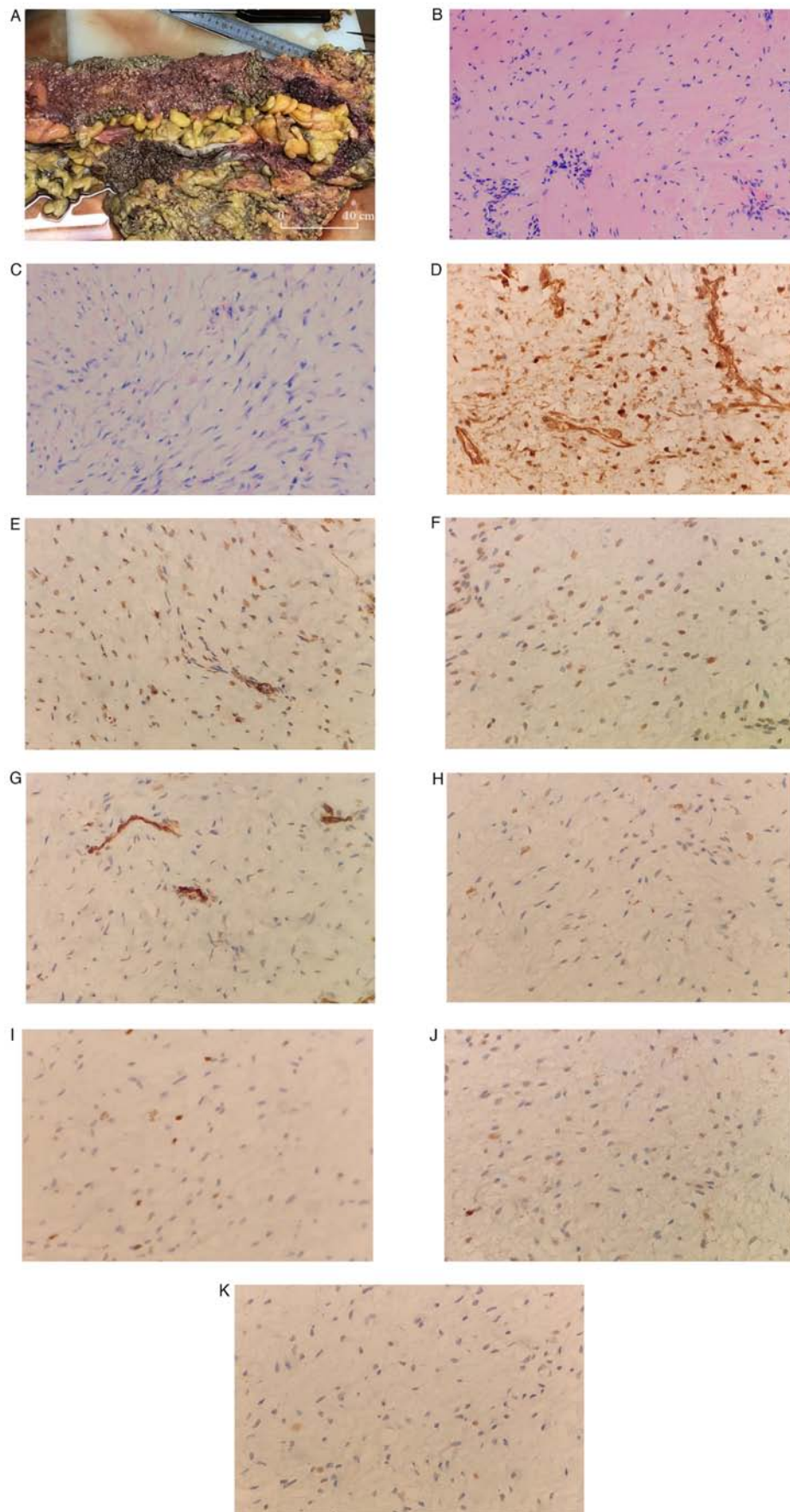


Figure 3. Continued. An excised portion of the colon. (A) Mucosal surface of the large intestine was densely covered with polyps. (B and C) Proliferating spindle cells arranged in bundles, with mild cell morphology and interstitial collagenization with mucus degeneration. (B) H&E (magnification, x100). (C) H&E (magnification, x200). Immunohistochemistry of the biopsy determined the sample to be (D) β -catenin (partial nuclear positive), (E) smooth muscle actin (partial positive), (F) desmin (scattered positive), (G) CD117 (negative), (H) Ki-67 (positive; 5%), (I) CD34 (vascular positive), (J) S-100 (negative) and (K) SRY-box transcription factor 10 (negative). (D-K) Magnification, x400.

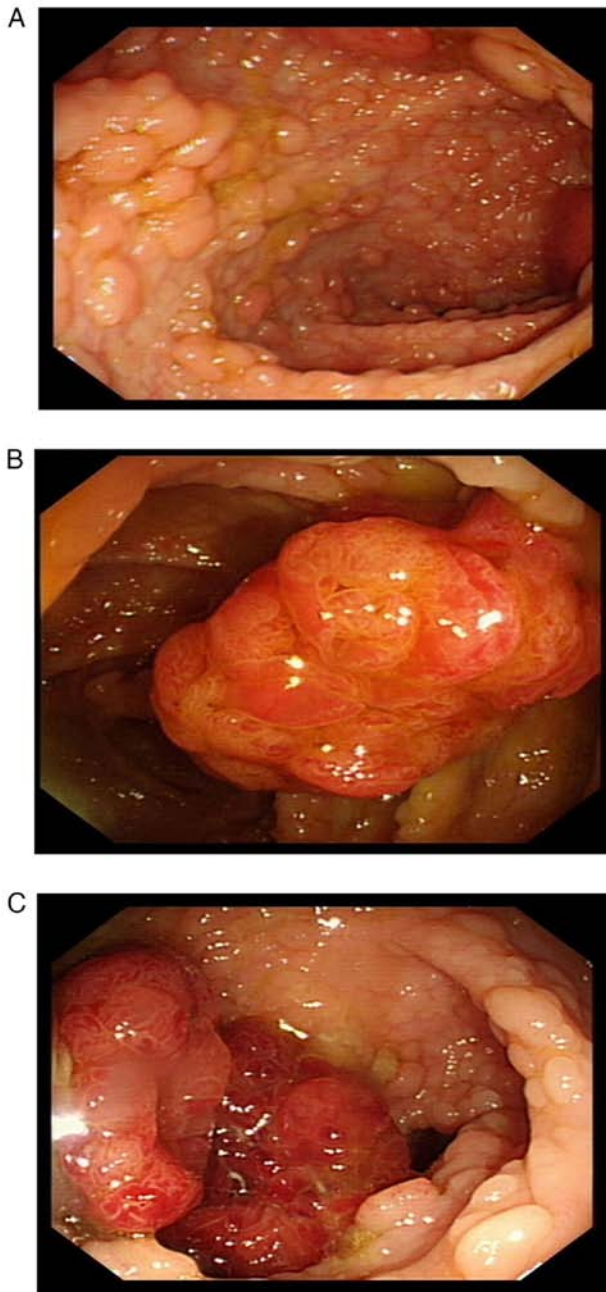


Figure 4. Colonoscopy examination. (A) Dense and flat polyps 3-10 mm in diameter in the whole colon and rectum. (B) A lobulated polyp ~25 mm in diameter with dilated surface ducts was detected ~40 cm from the anal verge. (C) Multiple pedicled and sessile lobulated polyps 10-15 mm in diameter were detected ~27 cm from the anal verge.

(low-grade intraepithelial neoplasia, some high-grade intraepithelial neoplasia; Fig. 5A); adenoma 2 was a tubular adenoma (high-grade intraepithelial neoplasia; Fig. 5B) with focal adenocarcinoma. Postoperative pathology of the tubular adenoma: Hundreds of pieces (low-grade intraepithelial neoplasia), 0.3-1.0 cm in diameter, consistent with familial adenomatous polyposis. No lesions were found on the surgical line. No cancer was found in 11 peri-intestinal lymph nodes (0/11). The patient was followed up in the outpatient clinic for 1 year, where CT scans were performed every 6 months. The patient has since been stable up to the last examination in June 2022.

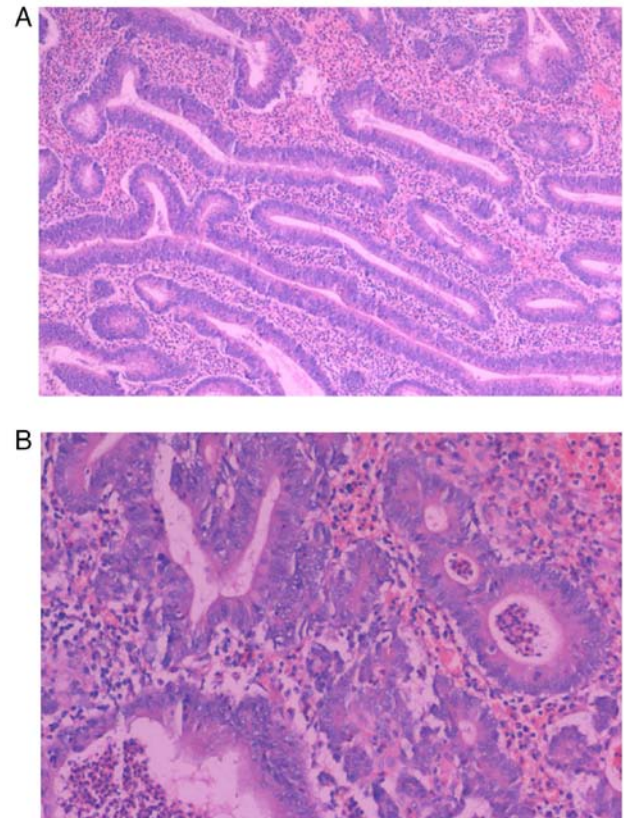


Figure 5. Pathology of surgical specimen. (A) Low-grade intraepithelial neoplasia with partial high-grade intraepithelial neoplasia macroadenoma (H&E; magnification, x400). (B) High-grade intraepithelial neoplasia macroadenoma with focal adenocarcinoma (H&E; magnification, x200).

Discussion

DF is a clinically rare clonal proliferative disease, originating from the mesenchymal tissue, and is a borderline tumor (8). Certain cases of aggressive fibromatosis with variable clinical courses may remain stable for a long time and some may grow invasively to surround the organs. Other cases of DF may even regress spontaneously (9). Although not prone to distant metastasis, DF is prone to recurrence following surgery with a high local recurrence rate of 17.6-30.7% (1-4). Primary DF is rare but a common concomitant disease of FAP. The incidence of DF in patients with FAP ranges between 10 and 30% and is 1,000 times higher than that noted in the general population (5,6).

FAP is an autosomal dominant inherited disease. It is considered that FAP is mainly caused by mutations in the oncogene APC located on the fifth chromosome. FAP can develop in adolescence, accounting for ~1% of the total incidence of precancerous colorectal cancer (10). FAP lesions present as widespread adenomatous polyps in the colorectum and may also occur in the upper gastrointestinal tract or even throughout the gastrointestinal tract of patients (11). The development of FAP to colorectal cancer is almost inevitable without treatment, and surgery is the preferred treatment strategy in addition to regular monitoring (7). Surgical interventions are available, including for suspicious canceration, multiple >6-mm adenomas, a significant increase in the number of adenomas after multiple examinations,

pathological indications of highly atypical hyperplastic adenomas, obstruction or bleeding. There are three surgery options for this disease: TPC with IPAA, total abdominal colectomy with ileorectal anastomosis (IRA) and TPC with end ileostomy (12). It has been reported that IPAA and IRA are routinely used as preventive surgery for FAP, while the risk of DF following IPAA surgery is significantly higher than that following IRA. The probability of DF was increased sequentially when comparing patients who underwent small bowel rectal anastomosis, small bowel anal anastomosis and small bowel stoma (13). Nieuwenhuis *et al* (14) followed up 62 cases of postoperative DF following FAP for a median time of 8 years and reported no difference in progression-free survival between patients treated with and without surgery (33% vs. 49%; $P=0.163$). A total of 9 out of the 36 patients (25%) who underwent surgery succumbed to the disease due to recurrence.

Patients with DF have a high rate of local recurrence following surgery. Rutenberg *et al* (15) reported a postoperative recurrence rate of 24-77% for DF. Conventional treatment of DF includes non-steroidal anti-inflammatory drugs, anti-estrogens, cytotoxic chemotherapy and radiotherapy, in addition to local resection (12). Research shows that targeted drugs such as sorafenib have a good control effect on patients with AF, with a total effective rate of treatment of 33% (16). Considering the likely complications associated with surgery and radiotherapy and the unpredictable progression of DF, which may grow, stabilize over time or even subside spontaneously, a watchful waiting treatment strategy becomes reasonable and feasible (7). Tumor regression occurs in 20-30% of patients during watchful waiting. This may occur in DF in any part of the body but is more likely in intra-abdominal DF (17). Bonvalot *et al* (18) performed a survival analysis of patients with DF, with one group treated with a watchful waiting strategy and the other treated with microscopically completed surgery and aggressive drug therapy. There was no difference between the two groups in terms of sex, age, tumor size and other baseline levels. The results indicated no difference in the 3-year progression-free survival rate between the two groups after a median follow-up time of 76 months (waiting group, 68% vs. surgery group, 65%; $P>0.05$).

There have been clinical reports about DF secondary to FAP. The present patient was diagnosed with DF and FAP at the same time at the first visit and the symptoms were caused by DF. Previous literature has reported additional retreatment strategies for induction of new DF following FAP surgery and DF recurrence following local excision (1-4). In the present case, the patient had been diagnosed with DF combined with FAP, with surgical indications including suspicious canceration, multiple >6-mm adenomas and highly atypical hyperplastic adenoma. However, since the DF tumor was located at the root of the mesentery of the small intestine, the majority of the small intestine had to be resected to remove the DF tumor, which would be likely to cause short bowel syndrome following surgery and seriously affect the quality of life of the patient. Finally, the treatment option proposed for this patient was to undergo an initial FAP surgery followed by a subsequent watchful waiting strategy to monitor DF changes, whilst considering the natural course of DF. In the present case, it was noted that the inflammatory adhesions around the DF tumor body had been loosened

and the obstruction caused by the inflammatory adhesions had been released. This suggested that DF had not yet caused tissue invasion to the intestinal wall or other organs.

In conclusion, the present study demonstrated that an individualized treatment strategy was important for the patient when DF was combined with FAP. The surgical intervention should be selected carefully according to the anatomical location of DF. A consensus was established in the present study on the surgical approach for FAP. It is considered that the retention of additional functional organs, such as the intestine, is more important to improve the quality of life of the patient when dealing with intra-abdominal DF combined with FAP. Surgical resection may not be the first option; non-surgical treatments, such as watchful waiting and drug treatment, could also benefit patients with DF combined with FAP.

The disadvantage of the current study is that no radical treatment had been carried out for the DF tumor, and the watchful-waiting strategy may lead to disease progression in the future. Whether the proposed treatment strategy can benefit patients requires a comprehensive evaluation by regular follow-up examinations such as symptoms, signs and imaging examinations, and a large amount of clinical trial data.

Acknowledgements

Not applicable.

Funding

No funding was received.

Availability of data and materials

The datasets used and/or analyzed during the current study are available from the corresponding author on reasonable request.

Authors' contributions

LZ and SZ contributed to the original conception of the study. LZ, SZ and KY wrote the manuscript. LZ, YZ and XY analyzed and interpreted the imaging findings. KY and YZ obtained and analyzed pathological images. KY and SZ edited and reviewed the prepublication version of the manuscript. LZ and SZ confirm the authenticity of all the raw data. All authors have read and approved the final manuscript.

Ethics approval and consent to participate

The studies involving human participants were reviewed and approved by the Ethics Committee of Weihai Central Hospital (Weihai, China; approval no. LL-2022-139).

Patient consent for publication

Written informed consent for the publication of the patient's clinical information and images was obtained from the patient.

Competing interests

The authors declare that they have no competing interests.

References

1. Crago AM, Denton B, Salas S, Dufresne A, Mezhir JJ, Hameed M, Gonen M, Singer S and Brennan MF: A prognostic nomogram for prediction of recurrence in desmoid fibromatosis. *Ann Surg* 258: 347-353, 2013.
2. Mullen JT, Delaney TF, Kobayashi WK, Szymonifka J, Yeap BY, Chen YL, Rosenberg AE, Harmon DC, Choy E, Yoon SS, *et al*: Desmoid tumor: Analysis of prognostic factors and outcomes in a surgical series. *Ann Surg Oncol* 19: 4028-4035, 2012.
3. Bonvalot S, Tzanis D and Bouhadiba T: Desmoid tumors: Are there still any surgical indications? *Bull Cancer* 107: 364-370, 2020 (In French).
4. He XD, Zhang YB, Wang L, Tian ML, Liu W, Qu Q, Li BL, Hong T, Li NC and Na YQ: Prognostic factors for the recurrence of sporadic desmoid-type fibromatosis after macroscopically complete resection: Analysis of 114 patients at a single institution. *Eur J Surg Oncol* 41: 1013-1019, 2015.
5. Devata S and Chugh R: Desmoid tumors: A comprehensive review of the evolving biology, unpredictable behavior, and myriad of management options. *Hematol Oncol Clin North Am* 27: 989-1005, 2013.
6. Kummer S, O'Sullivan Coyne G, Do KT, Turkbey B, Meltzer PS, Polley E, Choyke PL, Meehan R, Vilimas R, Horneffer Y, *et al*: Clinical activity of the γ -secretase inhibitor PF-03084014 in adults with desmoid tumors (aggressive fibromatosis). *Clin Oncol* 35: 1561-1569, 2017.
7. Turner B, Alghamdi M, Henning JW, Kurien E, Morris D, Bouchard-Fortier A, Schiller D, Puloski S, Monument M, Itani D and Mack LA: Surgical excision versus observation as initial management of desmoid tumors: A population based study. *Eur J Surg Oncol* 45: 699-703, 2019.
8. Kasper B, Baumgarten C, Garcia J, Bonvalot S, Haas R, Haller F, Hohenberger P, Penel N, Messiou C, van der Graaf WT, *et al*: An update on the management of sporadic desmoid-type fibromatosis: A european consensus initiative between sarcoma Patients EuroNet (SPAEN) and european organization for research and treatment of cancer (EORTC)/soft tissue and bone sarcoma group (STBSG). *Ann Oncol* 28: 2399-2408, 2017.
9. Lewis JJ, Boland PJ, Leung DH, Woodruff JM and Brennan MF: The enigma of desmoid tumors. *Ann Surg* 229: 866-872, 1999.
10. Righetti AE, Jacomini C, Parra RS, de Almeida AL, Rocha JJ and Fères O: Familial adenomatous polyposis and desmoid tumors. *Clinics (Sao Paulo)* 66: 1839-1842, 2011.
11. Samadder NJ, Baffy N, Giridhar KV, Couch FJ and Riegert-Johnson D: Hereditary cancer syndromes-A primer on diagnosis and management, part 2: Gastrointestinal cancer syndromes. *Mayo Clin Proc* 94: 1099-1116, 2019.
12. Monahan KJ, Bradshaw N, Dolwani S *et al*: Guidelines for the management of hereditary colorectal cancer from the British Society of Gastroenterology (BSG)/Association of Coloproctology of Great Britain and Ireland (ACPGBI)/United Kingdom Cancer Genetics Group (UKCGG)[J]. *Gut* 69: 411-444, 2020.
13. Zhenzhen W and Yaozong Y: Risk factors of invasive fibroma in familial adenomatous polyposis. *Chin J Dig* 34: 640-642, 2014.
14. Nieuwenhuis MH, Mathus-Vliegen EM, Baeten CG, Nagengast FM, van der Bijl J, van Dalsen AD, Kleibeuker JH, Dekker E, Langers AM, Vecht J, *et al*: Evaluation of management of desmoid tumours associated with familial adenomatous polyposis in Dutch patients. *Br J Cancer* 104: 37-42, 2011.
15. Rutenberg MS, Indelicato DJ, Knapik JA, Lagmay JP, Morris C, Zlotecki RA, Scarborough MT, Gibbs CP and Marcus RB: External-beam radiotherapy for pediatric and young adult desmoid tumors. *Pediatr Blood Cancer* 57: 435-442, 2011.
16. Gounder MM, Mahoney MR, Van Tine BA, Ravi V, Attia S, Deshpande HA, Gupta AA, Milhem MM, Conry RM, Movva S, *et al*: Sorafenib for advanced and refractory desmoid tumors. *N Engl J Med* 379: 2417-2428, 2018.
17. Roussin S, Mazouni C, Rimareix F, Honoré C, Terrier P, Mir O, Dômont J, Le Péchoux C, Le Cesne A and Bonvalot S: Toward a new strategy in desmoid of the breast? *Eur J Surg Oncol* 41: 571-576, 2015.
18. Bonvalot S, Eldweny H, Haddad V, Rimareix F, Missenard G, Oberlin O, Vanel D, Terrier P, Blay JY, Le Cesne A and Le Péchoux C: Extra-abdominal primary fibromatosis: Aggressive management could be avoided in a subgroup of patients. *Eur J Surg Oncol* 34: 462-468, 2008.



This work is licensed under a Creative Commons Attribution-NonCommercial-NoDerivatives 4.0 International (CC BY-NC-ND 4.0) License.