

# Outcome in TFCC repair using micro anchor and trans-osseous technique

YOUSEF KHAIR<sup>1</sup>, AYMAN MUSTAFA<sup>1</sup>, SAAB MESTRIHI<sup>1</sup>, EHAB AZZAM<sup>1</sup>,  
MOTAZ AL-QASAIMEH<sup>1</sup>, DMOUR AWAD<sup>2,3</sup> and ALEXA OVIDIU<sup>2,3</sup>

<sup>1</sup>Department of Orthopaedics, Royal Medical Services, Zahran, Amman 11183, Jordan;

<sup>2</sup>Department of Orthopaedics, University of Medicine and Pharmacy 'Grigore T. Popa', Iasi 700115;

<sup>3</sup>Orthopaedics Clinic, Clinical Emergency Hospital Sf Spiridon, Iasi 700111, Romania

Received January 28, 2023; Accepted September 15, 2023

DOI: 10.3892/etm.2023.12256

**Abstract.** The triangular fibrocartilage complex (TFCC) is an intrinsic stabiliser of the distal radioulnar joint (DRUJ), which serves an important role in wrist movement, forearm rotation and grip strength. A stable DRUJ is a key requirement for pain-free movement of the wrist. TFCC tears are a common ulnar-sided wrist pain associated with decreased grip strength and impaired function. TFCC tears are classified according to the location and cause. The Palmer classification delineates tears into traumatic type 1 and degenerative type 2. The present study investigated the clinical outcomes of using micro suture anchors in open repair in comparison with trans-osseous TFCC repair. From July 2017 to July 2020, 51 patients underwent open repair of TFCC tear by hand and upper limb surgeons in Royal Rehabilitation Center at King Hussein Medical Center (Amman, Jordan). Stability of DRUJ and tenderness at the ulnar aspect of the wrist were evaluated by Disability of the Arm, Shoulder and Hand (DASH) and Modified Mayo Wrist Score (MMWS) pre- and post-operatively. A total of 38 patients (27 male and 11 females) underwent open repair using micro suture anchors and 13 (7 male and 6 female) by trans-osseous repair. A total of 51 patients in the follow-up 6-48 months had significant improvement in pain and range of motion. A total of 45 patients showed improved grip strength and were pain-free; six patients showed improvement of grip strength and decreased pain. For the patients who underwent TFCC repair by micro suture anchors, there was an improvement of MMWS from 70 to 90%, and for those who underwent TFCC repair by trans-osseous technique, MMWS improved from 65 to 85%. There was also significant improvement in DASH score post-operatively with both techniques, from

60 to 15% in the trans-osseous technique and from 70 to 15% in the suture anchors. Open repair of TFCC tears using either micro anchor or trans-osseous repair led to pain-free range of motion, improved grip strength, stable DRUJ and improvement in DASH and MMWS scores, with no significant differences in clinical outcome between techniques.

## Introduction

Triangular fibrocartilage complex (TFCC) tears are a common cause of ulnar-sided wrist pain and usually affect the grip strength and wrist range of motion (1-3). TFCC injuries were noted to increase with age, with a 49% prevalence among patients aged  $\geq 70$  and a 27% prevalence among those aged  $\leq 30$  (4). TFCC also plays an important role in the stability of the distal radioulnar joint (DRUJ) by its foveal attachment (1,2). The DRUJ joint consists of six primary components, which are the dorsal and volar radioulnar ligaments, central articular disc, meniscus homologue, ulnar collateral ligament, extensor carpi ulnaris (ECU) sub-sheath and the origin of ulnolunate and ulnotriquetrial ligaments (2). The radioulnar ligaments are separated into the deep fibres, known as the ligamentum subcruentum, which are attached to the ulnar fovea (5), while superficial fibres are attached to the ulnar styloid.

The peripheral part of the TFCC is well vascularised, while the central portion is avascular (6). Lesions of the TFCC are classified according to the Palmer classification as either traumatic (type I) or degenerative (type II) depending on the cause of injury. Depending on the location of the tear within the TFCC, type 1 is further classified into 1A isolated central tears, 1B tears located on the ulnar side of the TFCC, also called ulnar avulsion of the TFCC, 1C tears on the distal tear of the TFCC (the origin of the ulnolunate and ulnotriquetrial ligaments) and 1D radial avulsion (6,7). A traumatic tear of the ulnar side of the TFCC (type IB) is one of the most common causes of ulnar-sided discomfort and impairment in the wrist (7-9).

Ultrasound imaging is a non-invasive method that uses high-frequency sound waves to generate real-time images of internal structures, enabling detection of translational movement in the DRUJ without radiation or contrast agents (10).

---

*Correspondence to:* Dr Dmour Awad, Department of Orthopaedics, University of Medicine and Pharmacy 'Grigore T. Popa', 16 Universitatii Street, Iasi 700115, Romania  
E-mail: awaddmour@gmail.com

**Key words:** triangular fibrocartilage complex, open repair, trans-osseous, micro suture anchor, distal radio-ulnar joint

It allows for visualizing joint motion during active exercise, facilitating the early identification of DRUJ instability and the development of improved treatment approaches (3,11).

Grayscale ultrasound imaging faces challenges due to TFCC varied echogenicity, making it difficult to distinguish injury from normal tissue. The central disk of the TFCC lacks blood supply, while the periphery receives blood from nearby vessels (2). Doppler signals are typically absent, but in certain cases, small vessels along the ulnocarpal ligament may be observable. The increased vascularity at the deep border of the ulnocarpal ligament and the outer margin of the TFCC, along with other indications such as joint widening and visible gaps, aid in diagnosing TFCC injury (3). Power Doppler, a specialized ultrasound technique that detects blood flow, along with dynamic imaging during functional tasks, enhances the diagnostic accuracy of TFCC injury (11).

For diagnosing tears in the TFCC, arthroscopy has been considered the gold standard. However, arthroscopy and magnetic resonance (MR) arthrography, despite their efficacy, present certain drawbacks, such as invasiveness, prolonged procedural durations, high cost and being operator dependent (8,12-14). By contrast, high-resolution conventional MRI offers a valuable non-invasive alternative for diagnosing TFCC tears. This imaging modality provides an accurate imaging protocol that detects the location and extent of injury without invasive procedures. Studies have demonstrated the efficacy of high-resolution conventional MRI in visualizing most surgically relevant TFCC pathology, making it a reliable diagnostic tool (2,12).

Ultrasound and high-resolution MRI offer non-invasive, accurate imaging for detecting DRUJ instability and diagnosing TFCC tears. These advancements improve diagnostics and may lead to more effective treatment options for DRUJ and TFCC injury (3,6).

Ulnar-sided wrist pain caused by TFCC injury is treated initially using non-operative methods, including immobilization, physiotherapy, cortisone injection (15,16). Surgery is considered once non-operative treatment has failed. Surgical interventions include arthroscopic debridement and arthroscopic-assisted (outside-in, inside-out, all-inside) or open repair. Ulnar shortening osteotomy is used to decrease the load on the ulnocarpal joint, in the case of ulna abutment association from ulna positive variance (1,17).

Treatment is chosen depending on the location of the tear (15,18). Tears in the peripheral superficial parts of the TFCC are sutured to the dorsal ulnocarpal capsule and the ECU sub-sheath (18). TFCC tears in the deep part, which is the main stabilizer of the DRUJ, or any injury to its foveal insertion can cause instability (19). Foveal avulsions are considered as atypical variation on type 1B TFCC tear (20) and are usually treated by reattaching the avulsed TFCC region either by trans-osseous sutures or suture anchors, which can be performed by either open or arthroscopically assisted repair (18,20). To the best of our knowledge, however, functional outcomes are comparable and there is no clear evidence regarding which technique gives better results (15).

The present retrospective study aimed to compare functional and clinical outcomes between open TFCC repair using micro suture anchors and using trans-osseous sutures.

## Materials and methods

*Study overview and patient selection.* The present retrospective comparative study aimed to evaluate the clinical and functional outcomes of open TFCC repair using micro suture anchors and trans-osseous sutures. The study included 51 patients who underwent open surgical repair between July 2017 and March 2021 performed by hand and upper limb surgeons at the Royal Rehabilitation Centre, King Hussein Medical Centre (Amman, Jordan). A total of 38 patients (27 males and 11 females) underwent open repair using micro suture anchors, while 13 (7 males and 6 females) underwent trans-osseous repair.

*Assessment and data collection.* The present study included patients with a specific tear pattern involving the Palmer portion of the TFCC, known as TFCC tear Palmer type 1B. These tears are typically caused by trauma or injury. The patient population consisted of individuals between the ages of 18 and 55 years to ensure a consistent and comparable group for analysis, taking into account potential age-related factors such as bone density, vascularization, comorbidities, muscle mass and strength, that could affect the outcomes of TFCC repair. The minimum follow-up time for patients was 6 months, with a mean follow-up period of 27 months. This duration allowed comprehensive evaluation of long-term outcomes and the assessment of the stability and effectiveness of the surgical technique. Patients with arthritic changes in DRUJ or ulnocarpal abutment, as well as those with wrist pathology in the contralateral side, were excluded to maintain a homogeneous patient population without confounding factors that could influence the outcome.

Grip strength assessment was performed using dynamometer. Immediate preoperative assessments were conducted, followed by evaluations at 2 weeks, and subsequently at 6, 12 and annually thereafter, compared with the contralateral side. Wrist range of motion and presence or absence of pain and local tenderness were recorded. Modified Mayo Wrist Score (MMWS) was performed pre- and post-operatively, as was the Disability of the Arm, Shoulder and Hand (DASH) score (1,21-23). Pre-operative wrist MRI was used for diagnostic purposes.

*Surgical procedure.* Both surgical techniques utilized a longitudinal skin incision at the dorsal aspect of the wrist between the fifth (extensor digiti minimi) and sixth extensor compartments (extensor carpi ulnaris; Fig. 1). The fifth extensor compartment was opened, and the extensor digiti minimi tendon was retracted to ensure adequate exposure of the surgical field. Moving proximally, the sub sheath of the extensor carpi ulnaris was opened and retracted in an ulnar direction. This step facilitated clear visualization of the underlying structures and allowed further exploration and manipulation of the target area. Then, an L-shaped capsulotomy was performed, extending longitudinally along the margin of the sigmoid notch and angled towards the ulna, proximal to the dorsal radioulnar ligament of the TFCC. A second capsulotomy was performed transversely along the distal edge of the dorsal radioulnar ligament to expose the distal surface of the TFCC (Fig. 2). The implementation of

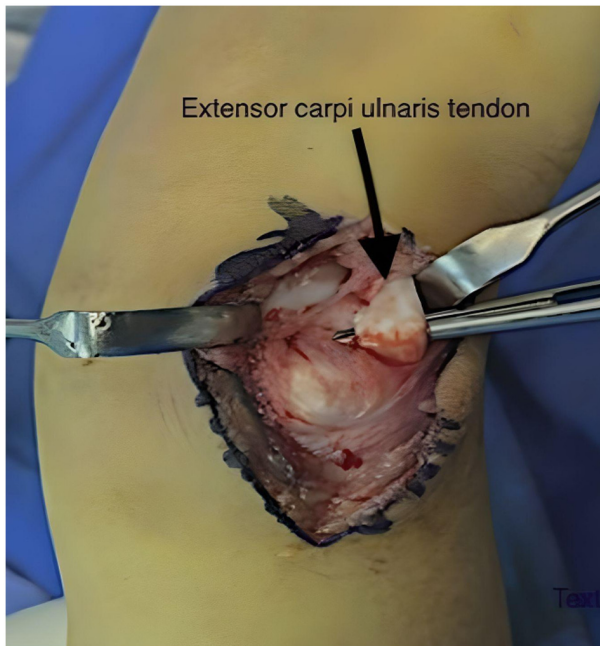


Figure 1. Extensor carpi ulnaris tendon.

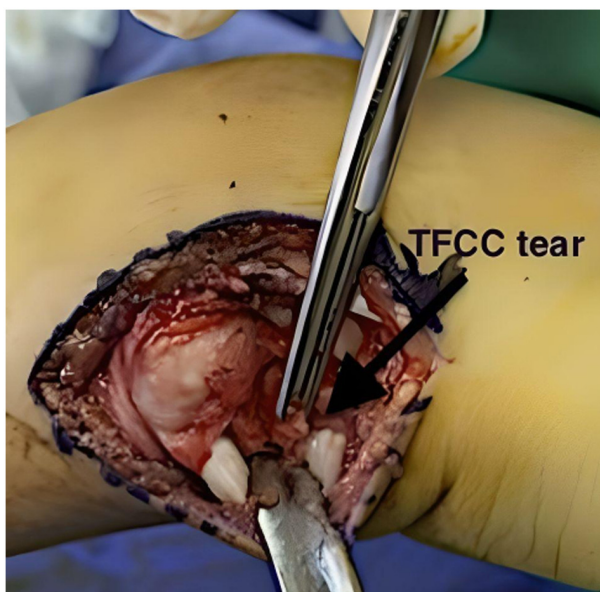


Figure 2. Site of TFCC tear. TFCC, triangular fibrocartilage complex.

these capsulotomies in a standardized manner ensured consistent and controlled access to targeted structures, allowing for a thorough evaluation and appropriate management of the TFCC during the repair process.

**Trans-osseous group.** In the trans-osseous suture technique, 0.062-inch K-wire was used to create two holes in the distal ulna. These holes were carefully positioned, passing from the dorsal aspect of the ulnar neck to the ulnar fovea. Subsequently, two horizontal mattress 2-0 sutures were passed distally to proximally through the periphery of the TFCC and the K-wire holes (Fig. 3). This configuration ensured secure attachment and stabilization of the TFCC. Sutures were tied over the ulnar

neck with the DRUJ joint reduced before suturing the TFCC, and the forearm positioned in neutral rotation. To reinforce the repair, the dorsal DRUJ capsule, and retinaculum were closed together, while ensuring that the extensor digiti minimi tendon was superficial to the retinaculum. The closure was not excessively imbricated to avoid potential loss of pronation.

**Suture anchor group.** In the suture anchor technique, the micro suture anchor was carefully positioned and inserted at the ulnar fovea (Fig. 4), a key anatomical landmark within the wrist joint (2). This small but robust anchor serves as a stable point of attachment for the repair process (Fig. 3). Subsequently, two horizontal mattress sutures, using high-quality suturing material, were passed through the periphery of the TFCC, ensuring secure and reliable fixation. These sutures reattached the TFCC firmly to the ulnar fovea (Fig. 5), re-establishing its proper anatomical position and restoring its key role in wrist stability and function.

Following the surgical procedure, a long arm splint was applied to the forearm, with the forearm rotated 45° towards the most stable joint position, which was often in supination. This splint was maintained for 2 weeks. At this point, the splint was converted to a sugar tongue splint, worn for an additional 4 weeks. Finally, a removable splint was utilized for the subsequent 4 weeks to regain motion and facilitate the healing process.

**Statistical analysis.** Data were analysed using SPSS (version 27; <https://www.ibm.com/products/spss-statistics>). A paired t-test was applied to assess paired data, comparing the pre- and post-operative outcomes within each surgical technique group.  $P < 0.05$  was considered to indicate a statistically significant difference. Data were presented as mean  $\pm$  SD.

## Results

**Functional assessment and comparison of surgical techniques.** All patients who underwent open TFCC repair either by trans-osseous or micro anchor suture underwent a periodic thorough assessment and evaluation of degree of pain, wrist range of motion and grip strength using a dynamometer, with assessment of both DASH and MMWS, to compare the pre- and post-operative functional status for both surgical techniques.

**Range of motion enhancement.** Significant improvements in range of motion were observed in both the trans-osseous suture and the suture anchor technique for patients undergoing open TFCC repair. In the trans-osseous suture group, patients experienced significant gains in range of movement, with mean flexion increasing from 37 to 46°, extension from 39 to 51°, radial deviation from 8 to 13° and ulnar deviation from 18 to 26° (Table I). Similarly, in the suture anchor group, patients exhibited significant enhancements in the range of movement. Mean flexion increased from 39 to 51°, extension from 41 to 56°, radial deviation from 10 to 14° and ulnar deviation from 21 to 32° (Table II). These findings suggest that both the trans-osseous suture and the suture anchor technique were highly effective in improving wrist range of motion. The substantial improvements observed in flexion, extension, radial

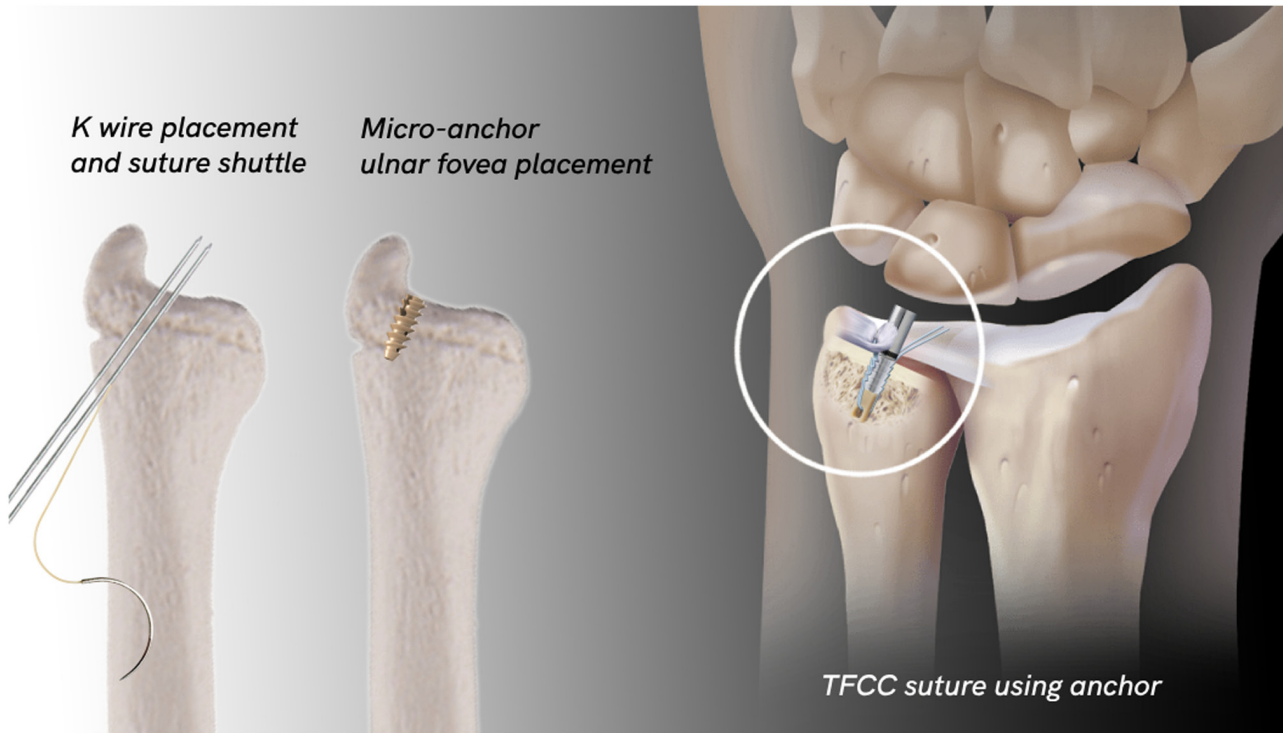


Figure 3. Micro anchor and trans-osseous technique illustration. TFCC, triangular fibrocartilage complex.

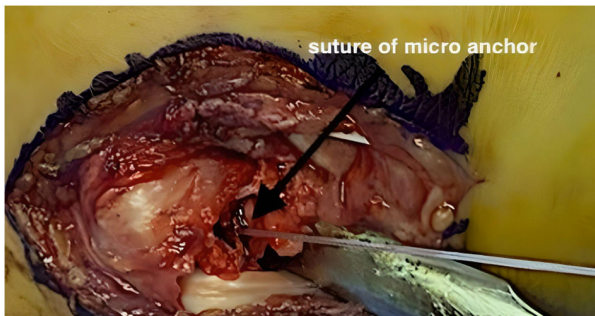


Figure 4. Suture of the micro anchor inserted in the ulna fovea.

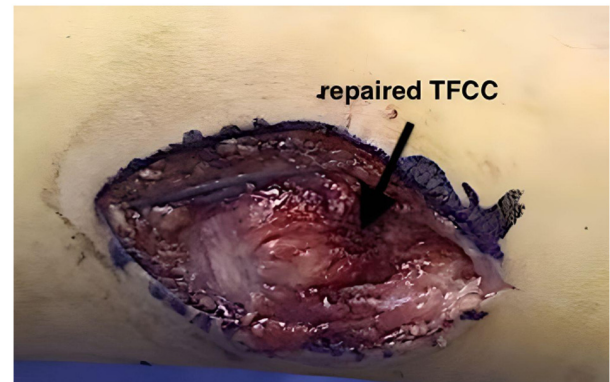


Figure 5. Repaired TFCC. TFCC, triangular fibrocartilage complex.

deviation and ulnar deviation demonstrate the positive impact of these surgical techniques on enhancing range of movement in patients undergoing open TFCC repair (Tables I and II).

**Pain improvement.** Significant improvements in pain were observed in both surgical techniques, as indicated by the MMWS and DASH score. In the trans-osseous suture group, the pain score showed a marked improvement after 6 months, increasing from 65% pre-operatively to 85% post-operatively, demonstrating a significant enhancement in pain relief. Similarly, in the suture anchor group, the pain score improved significantly from 70% pre-operatively to 90% post-operatively, indicating a significant increase in pain relief (Table III).

DASH score was used to assess the improvement in pain. The results revealed a substantial improvement in pain from the preoperative to postoperative period. Specifically, the pain decreased significantly from 60 to 15% in the trans-osseous suture group and from 70 to 15% in the suture anchor group. In the micro suture anchor technique, all patients achieved a

pain-free state after a mean follow-up of 7 months, indicating a substantial improvement in pain intensity. However, one patient showed pain improvement from 0 points preoperatively to 15 points postoperatively according to the MMWS (Table III).

Similarly, in the trans-osseous technique, nearly all patients were pain-free after a mean follow-up of 9 months. Only one patient experienced improvement in pain intensity over a longer post-operative period, showing pain improvement from 5 points preoperatively to 20 points postoperatively according to the MMWS. Overall, the MMWS and DASH scores provide strong evidence of significant improvements in pain following surgery in both the trans-osseous suture and the suture anchor group (Table IV).

**Grip strength enhancement.** Grip strength, measured using a dynamometer and compared with the contralateral healthy side, showed significant improvements in patients undergoing

Table I. Mean wrist ROM improvement using the trans-osseous suture technique (compared with the contralateral side).

Movement	Pre-operative ROM, °	Post-operative ROM, °	Improvement, °	P-value
Flexion	36.9±5.6	46.2±4.5	9	<0.001
Extension	38.9±4.5	51.2±6.0	12	<0.001
Radial deviation	7.9±2.1	13.2±2.5	5	0.016
Ulnar deviation	18.1±4.5	26.3±4.0	8	<0.001

ROM, range of movement.

Table II. Mean wrist ROM improvement using micro anchor suture technique (compared with the contralateral side).

Movement	Pre-operative ROM, °	Post-operative ROM, °	Improvement, °	P-value
Flexion	39.1±5.9	51.0±4.5	12	<0.001
Extension	41.0±7.5	56.0±3.9	15	<0.001
Radial deviation	10.0±2.0	14.1±2.0	4	0.016
Ulnar deviation	20.9±5.5	31.9±1.6	11	<0.001

ROM, range of movement.

Table III. Pain improvement according to MMWS and DASH score.

Pain assessment	Trans-osseous suture	Micro anchor
Pre-operative pain MMWS score, %	65	70
Post-operative pain MMWS score, %	85	90
MMWS pain improvement, % (P-value <0.001)	20	20
DASH pain improvement, % (P-value <0.001)	45	55
Pain-free range of movement, %	90	97

MMWS, Modified Mayo Wrist Score; DASH, disability of the arm, shoulder and hand.

Table IV. MMWS and DASH score improvement.

Score	Trans-osseous (%)	Micro anchor (%)	P-value
MMWS	85	90	<0.05
DASH	15	15	>0.05

MMWS, Modified Mayo Wrist Score; DASH, disability of the arm, shoulder and hand.

open TFCC repair using trans-osseous sutures. The mean grip strength increased from 60% preoperatively to 90% postoperatively according to the MMWS, indicating 50% improvement in grip strength following the trans-osseous suture technique (Table V).

In patients undergoing open TFCC repair using suture anchors, there was an improvement in grip strength postoperatively. The mean grip strength increased from 65%

preoperatively to 90% postoperatively according to the MMWS, demonstrating a significant 38% improvement in grip strength following the suture anchor technique. These findings highlight the effectiveness of both surgical techniques in enhancing grip strength in patients undergoing open TFCC repair (Table V).

### Discussion

The present study aimed to compare the clinical and functional outcomes of open TFCC repair using trans-osseous suture and micro anchor suture technique.

Foveal disruption of TFCC is a common condition associated with DRUJ instability. TFCC tears significantly impact wrist function and lead to persistent pain and instability. Conservative treatment is the primary approach for managing all types of TFCC injury. This treatment modality aims to alleviate symptoms and provides symptomatic relief in ~33% of patients (1). While non-surgical treatments are successful for TFCC tears without DRUJ instability, surgical intervention is necessary in cases where conservative measures

Table V. Grip strength assessment.

Surgical technique	Pre-operative grip strength, %	Post-operative grip strength, %	Grip strength improvement, %	P-value
Trans-osseous suture	60	90	50	<0.001
Micro anchor	65	90	38	0.01

fail to provide relief (16,24). If the TFCC is avulsed from the foveal insertion, a reattachment procedure to re-fix the foveal insertion of radio-ularn ligaments to the bone is the treatment of choice to restore DRUJ stability and function (1).

Surgical repair techniques have predominantly focused on addressing type 1B tears in TFCC (1). Both open (which have been successfully utilized for decades) (1), and arthroscopic repair (recognized for their reliability and effectiveness) (15), have shown comparable results in terms of DRUJ instability for TFCC tears (15,25,26). Moreover, these techniques have demonstrated efficacy in relieving ulnar-sided wrist pain commonly associated with TFCC tears (26). Anderson *et al* (21) compared open and arthroscopic repair techniques in 76 patients with TFCC tears. The findings indicated no significant differences in clinical outcomes, including grip strength, range of motion, visual analogue scale, DASH and Patient Reported Wrist Evaluation scores and only a minor decrease in wrist flexion-extension in the open repair group. However, both groups experienced recurrent DRUJ instability necessitating re-intervention, indicating the need for improved primary treatment strategies (21). Furthermore, no notable disparities were observed in postoperative range of motion, grip strength or functional outcome scores between the two techniques, highlighting the lack of evidence to recommend one approach over the other in clinical practice (15). Conversely, arthroscopic treatment for peripheral tears consistently yields positive outcomes, with various studies reporting success rates ranging from 60 to 90% (1,21).

Previous studies have conducted retrospective evaluations of outcome measures to assess the effectiveness of treatment: These measures typically include parameters such as pain, DRUJ instability, range of motion, grip strength, MMWS and DASH score (1,21-23).

The assessment of grip strength is widely used to evaluate the functional status and clinical outcomes of the upper extremity after trauma or surgery (1,21,25,27). It serves as a valuable measure to determine the recovery progress and set realistic expectations for patients during preoperative consultation (22). In the present study, there was significant improvement in grip strength post-operatively for both trans-osseous and the micro anchors suture techniques. The improvement in grip strength was 90% for both techniques, consistent with another study supporting the positive impact of these surgical techniques on grip strength (10,27). Furthermore, the trans-osseous suture group showed mean improvement in grip strength of 30 percentage points, while the suture anchor group showed mean improvement of 25 percentage points. Although the difference between the groups was not statistically significant, it suggests a slightly greater improvement in grip strength in the trans-osseous suture group. These results highlight the

effectiveness of both techniques in enhancing grip strength, with the trans-osseous suture technique potentially yielding a slightly greater improvement.

The limitation of wrist range of motion can greatly impact daily activities and functional ability. Therefore, improvements in wrist range of motion following treatment indicates a successful intervention and enhanced wrist function (22). Here, the use of the micro anchors suture technique resulted in a 90% improvement, while the trans-osseous suture technique showed an 80% improvement. Notably, 97% of patients who underwent open TFCC repair using the micro anchors suture technique achieved pain-free range of motion, compared with 90% in the trans-osseous suture group, consistent with previous research demonstrating pain improvement following surgery (25,27).

Additionally, in the trans-osseous suture group, there was a mean increase of  $\sim 41.5^\circ$  in flexion,  $\sim 45.0^\circ$  in extension,  $\sim 10.5^\circ$  in radial deviation and  $\sim 22.0^\circ$  in ulnar deviation. Similarly, the suture anchor group showed significant improvements in range of motion, with a mean increase of  $\sim 45.0^\circ$  in flexion,  $\sim 48.5^\circ$  in extension,  $\sim 12.0^\circ$  in radial deviation and  $\sim 26.5^\circ$  in ulnar deviation. These results highlight the positive impact of both techniques on wrist range of motion, with the suture anchor technique potentially leading to slightly greater improvements.

Both MMWS and DASH scores have been widely utilized to assess the effectiveness of surgical treatments for similar conditions such as foveal tears and DRUJ instabilities (21,23). For the MMWS, there was a 90% improvement in patients who underwent open TFCC repair using the micro anchors suture technique, while those who underwent the trans-osseous suture technique exhibited an 85% improvement, consistent with previous studies that reported similar improvements in the MMWS following open repair (21,27). Regarding the DASH score, both techniques demonstrated a 15% improvement. Both the trans-osseous and micro anchors suture techniques were viable options for open TFCC repair, yielding favourable clinical and functional outcomes. However, there were slightly better results with the suture anchor technique regarding pain relief, wrist range of motion and MMWS.

Both techniques showed significant improvement in grip strength. The trans-osseous suture technique exhibited slightly better outcomes, as evidenced by a greater percentage point improvement. This suggests that the trans-osseous suture technique may offer a slight advantage in terms of grip strength recovery.

In terms of wrist range of motion, both techniques yielded satisfactory results. However, the micro anchor technique showed better outcomes in terms of pain relief, wrist range of motion, and improvement in MMWS. Although the differences between the two techniques were not significant, indicating

comparable clinical outcomes, the micro anchor technique demonstrated slightly better results.

MMWS and DASH score provide a comprehensive assessment of wrist function, pain and patient satisfaction. The improvements in these scores suggest successful intervention and enhanced wrist function following open TFCC repair using either technique.

The contralateral side of all patients demonstrated normal measurements and values for all the criteria assessed, including grip strength within the normal range. This fact is attributed to the rigorous patient selection process, which excluded individuals with pathological conditions in the contralateral wrists. By ensuring the normalcy of the contralateral side, it served as a reliable baseline for comparing and evaluating the functional outcomes of the post-operative results. The presence of normal mean grip strength on the contralateral side further underscores the significance of the observed improvements in grip strength following open TFCC repair using both the trans-osseous suture technique and the micro suture anchors suture technique.

The present study supported the effectiveness of open TFCC repair using both the micro anchor and trans-osseous suture techniques in managing pain, improving grip strength and enhancing wrist range of motion. The micro anchor technique demonstrated a higher success rate, with all patients experiencing pain relief. However, it is important to acknowledge the limitations of the study, such as the small sample size, and further research with larger cohorts and robust methodologies is necessary to validate these results and determine the optimal surgical approach for pain management in TFCC repair.

To summarize, the present study highlighted the positive impact of both the micro anchor and trans-osseous suture techniques in open TFCC repair. While the micro anchor technique showed a higher success rate in pain relief, further research is needed to validate these findings in larger cohorts. Both techniques effectively improved grip strength and wrist range of motion, with the trans-osseous suture technique potentially offering a slight advantage in grip strength recovery. These results support surgical interventions for TFCC injuries and underscore the importance of future research to optimize surgical decision-making and functional outcomes in TFCC repair.

### Acknowledgements

Not applicable.

### Funding

No funding was received.

### Availability of data and materials

The datasets used and/or analyzed during the current study are available from the corresponding author on reasonable request.

### Authors' contributions

YK and SM performed surgery, designed the study and revised the manuscript. AM designed the study and revised

the manuscript. EA and MQ performed surgery, analyzed data and wrote the manuscript. DA performed the literature search, designed the study, analyzed and interpreted data and wrote the manuscript. AO performed the literature review, analyzed and interpreted data and revised the manuscript. YK and SM confirm the authenticity of all the raw data. All authors have read and approved the final manuscript.

### Ethics approval and consent to participate

The present study was approved by Royal Medical Services, Jordan Ethical Committee, Amman, Jordan (approval no. 27). Written and oral consent to participate was obtained from all participants.

### Patient consent for publication

Written and oral consent for publication of data and images was obtained from all participants.

### Competing interests

The authors declare that they have no competing interests.

### References

- Jawed A, Ansari MT and Gupta V: TFCC injuries: How we treat? *J Clin Orthop Trauma* 11: 570-579, 2020.
- Haugstvedt JR, Langer MF and Berger RA: Distal radioulnar joint: Functional anatomy, including pathomechanics. *J Hand Surg Eur Vol* 42: 338-345, 2017.
- Wu WT, Chang KV, Mezian K, Naňka O, Yang YC, Hsu YC, Hsu PC and Özçakar L: Ulnar Wrist Pain Revisited: Ultrasound diagnosis and guided injection for triangular fibrocartilage complex injuries. *J Clin Med* 8: 1540, 2019.
- Chan JJ, Teunis T and Ring D: Prevalence of triangular fibrocartilage complex abnormalities regardless of symptoms rise with age: Systematic review and pooled analysis. *Clin Orthop Relat Res* 472: 3987-3994, 2014.
- Spies CK, Müller LP, Oppermann J, Hahn P and Unglaub F: Instability of the distal radioulnar joint-an overview of clinical and radiological procedures regarding their efficacies. *Handchir Mikrochir Plast Chir* 46: 137-150, 2014 (In German).
- Ng AWH, Griffith JF, Fung CSY, Lee RKL, Tong CSL, Wong CWY, Tse WL and Ho PC: MR imaging of the traumatic triangular fibrocartilaginuous complex tear. *Quant Imaging Med Surg* 7: 443-460, 2017.
- Atzei A, Luchetti R and Garagnani L: Classification of ulnar triangular fibrocartilage complex tears. A treatment algorithm for Palmer type IB tears. *J Hand Surg Eur Vol* 42: 405-414, 2017.
- Zhan H, Bai R, Qian Z, Yang Y, Zhang H and Yin Y: Traumatic injury of the triangular fibrocartilage complex (TFCC)-a refinement to the Palmer classification by using high-resolution 3-T MRI. *Skeletal Radiol* 49: 1567-1579, 2020.
- McNamara CT, Colakoglu S and Iorio ML: A systematic review and analysis of palmer type I triangular fibrocartilage complex injuries: Outcomes of treatment. *J Hand Microsurg* 12: 116-122, 2020.
- Jung HS, Kim SH, Jung CW, Woo SJ, Kim JP and Lee JS: Arthroscopic transosseous repair of foveal tears of the triangular fibrocartilage complex: A systematic review of clinical outcomes. *Arthroscopy* 37: 1641-1650, 2021.
- Hung CY, Chang KV and Özçakar L: Dynamic and doppler ultrasound imaging for the diagnosis of triangular fibrocartilage complex injury and ulnocarpal wrist instability. *Am J Phys Med Rehabil* 95: e111-e112, 2016.
- Casadei K and Kiel J: Triangular Fibrocartilage Complex. In: *StatPearls* (Internet). StatPearls Publishing, Treasure Island, FL, 2022.

13. Boer BC, Vestering M, van Raak SM, van Kooten EO, Huis In 't Veld R and Vochteloo AJH: MR arthrography is slightly more accurate than conventional MRI in detecting TFCC lesions of the wrist. *Eur J Orthop Surg Traumatol* 28: 1549-1553, 2018.
14. Cody ME, Nakamura DT, Small KM and Yoshioka H: MR Imaging of the triangular fibrocartilage complex. *Magn Reson Imaging Clin N Am* 23: 393-403, 2015.
15. Andersson JK, Åhlén M and Andernord D: Open versus arthroscopic repair of the triangular fibrocartilage complex: A systematic review. *J Exp Orthop* 5: 6, 2018.
16. Lee JK, Hwang JY, Lee SY and Kwon BC: What is the natural history of the triangular fibrocartilage complex tear without distal radioulnar joint instability? *Clin Orthop Relat Res* 477: 442-449, 2019.
17. Saito T, Sterbenz JM and Chung KC: Chronologic and geographic trends of triangular fibrocartilage complex repair. *Hand Clin* 33: 593-605, 2017.
18. Liu EH, Suen K, Tham SK and Ek ET: Surgical repair of triangular fibrocartilage complex tears: A systematic review. *J Wrist Surg* 10: 70-83, 2021.
19. Matsumoto T, Tang P, Fujio K, Strauch RJ and Rosenwasser MP: The optimal suture placement and bone tunnels for TFCC repair: A cadaveric study. *J Wrist Surg* 7: 375-381, 2018.
20. Kim B, Yoon HK, Nho JH, Park KH, Park SY, Yoon JH and Song HS: Arthroscopically assisted reconstruction of triangular fibrocartilage complex foveal avulsion in the ulnar variance-positive patient. *Arthroscopy* 29: 1762-1728, 2013.
21. Anderson ML, Larson AN, Moran SL, Cooney WP, Amrami KK and Berger RA: Clinical comparison of arthroscopic versus open repair of triangular fibrocartilage complex tears. *J Hand Surg Am* 33: 675-682, 2008.
22. Lee SH and Gong HS: Grip strength measurement for outcome assessment in common hand surgeries. *Clin Orthop Surg* 14: 1-12, 2022.
23. Atzei A, Luchetti R and Braidotti F: Arthroscopic foveal repair of the triangular fibrocartilage complex. *J Wrist Surg* 4: 22-30, 2015.
24. Im J, Kang SJ and Lee SJ: A comparative study between conservative and surgical treatments of triangular fibrocartilage complex injury of the wrist with distal radius fractures. *Clin Orthop Surg* 13: 105-109, 2021.
25. Feitz R, van der Oest MJW, van der Heijden EPA, Slijper HP, Selles RW and Hovius SER; Hand-Wrist Study Group: Patient-reported outcomes and function after reinsertion of the triangular fibrocartilage complex by open surgery. *Bone Joint J* 103-B: 711-717, 2021.
26. Luchetti R, Atzei A, Cozzolino R, Fairplay T and Badur N: Comparison between open and arthroscopic-assisted foveal triangular fibrocartilage complex repair for post-traumatic distal radio-ulnar joint instability. *J Hand Surg Eur Vol* 39: 845-855, 2014.
27. Moritomo H: Open repair of the triangular fibrocartilage complex from palmar aspect. *J Wrist Surg* 4: 2-8, 2015.



Copyright © 2023 Khair et al. This work is licensed under a Creative Commons Attribution-NonCommercial-NoDerivatives 4.0 International (CC BY-NC-ND 4.0) License.