

# A novel human papillomavirus-induced ‘doughnut wart’ lesion treated with 5-aminolevulinic acid photodynamic therapy: A case report

KE LI, YITAO QIAN, WENJING ZHA and LEI SHI

Department of Dermatology, Huadong Hospital, Fudan University, Shanghai Key Laboratory of Clinical Geriatric Medicine, Shanghai Institute of Geriatric Medicine, Shanghai 200040, P.R. China

Received April 16, 2025; Accepted October 9, 2025

DOI: 10.3892/etm.2026.13088

**Abstract.** The present study reports ‘doughnut wart’, a novel human papillomavirus (HPV)-associated viral wart characterized by central regression and peripheral ring-shaped proliferation after cryotherapy or other treatments, likely due to treatment-altered microenvironments promoting viral spread. A 21-year-old female with a post-cryotherapy plantar doughnut wart was treated with CO<sub>2</sub> laser debridement followed by three weekly 5-aminolevulinic acid photodynamic therapy (ALA-PDT) sessions. Complete healing was achieved with no recurrence at 1 year. During the sixth follow-up visit in June 2025, samples were collected from the patient for HPV detection, which confirmed the absence of recurrence. ALA-PDT eliminates HPV-infected cells through reactive oxygen species, activates local immunity (including immunogenic cell death) and preserves skin barriers, offering a precise, recurrence-reducing approach superior to conventional therapies, which can disrupt barriers and promote viral spread.

## Introduction

Skin warts are benign proliferative lesions caused by human papillomavirus (HPV) infection. The present study reports a novel type of viral wart that occurs after treatments such as cryotherapy. In this case, the warts at the original site regress,

but new warts form and spread outward along the surrounding disrupted skin tissue, creating doughnut-shaped, papillomatous proliferation, termed ‘doughnut wart’. It was first described in 1959 and is considered a rare complication that arises during the treatment of viral warts (1).

Viral warts often show resistance to cryotherapy (2). Although cryotherapy targets the infected tissue, the treatment may create a local skin microenvironment at the treated site that is unfavorable for viral survival. Paradoxically, this unfavorable environment may instead promote the virus to spread outward to adjacent tissues, where the relatively intact skin microenvironment is more conducive to viral growth (3). This alteration of the skin microenvironment forces the viral warts to spread to adjacent tissues more favorable for their growth and may be related to the local tissue response induced by cryotherapy, which inhibits viral survival or proliferation in the treated area. Meanwhile, the surrounding normal tissues are not directly affected by cryotherapy and may still provide relatively favorable conditions for the virus, which may lead to further viral spread (3).

5-Aminolevulinic acid photodynamic therapy (ALA-PDT) is a modern, minimally invasive technique (4-6). PDT has been recommended by numerous guidelines as an I-A class (strongly recommended, with evidence level A) treatment method for condyloma acuminatum in cavities such as the anal canal, urethral opening, urethra and cervical canal (7). Compared to traditional treatment methods such as electrocautery and microwave therapy, multiple studies have shown that PDT has good effects in treating stubborn plantar warts, with higher clearance rates and cure rates, and lower recurrence rates. Its effects are due to the precursor photosensitizer ALA, which, in the presence of oxygen, absorbs light of an appropriate wavelength and converts it into the photosensitive compound protoporphyrin IX, triggering a photodynamic reaction. This leads to the generation of reactive oxygen species (ROS), which induce cytotoxicity in HPV-infected cells, provoking a local inflammatory response that attracts immune cells to the lesion site (8,9). Subsequently, immune cells release pro-inflammatory cytokines, further enhancing local inflammation and promoting an antiviral immune response through immune cell activation (10). The count of CD8<sup>+</sup> T cells significantly increased, and at the same time,

---

*Correspondence to:* MD PhD Lei Shi, Department of Dermatology, Huadong Hospital, Fudan University, Shanghai Key Laboratory of Clinical Geriatric Medicine, Shanghai Institute of Geriatric Medicine, 221 West Yan'an Road, Shanghai 200040, P.R. China

E-mail: shi\_lei@fudan.edu.cn

*Abbreviations:* HPV, human papillomavirus; ALA-PDT, 5-aminolevulinic acid photodynamic therapy; PpIX, protoporphyrin IX; ROS, reactive oxygen species; ICD, immunogenic cell death; DAMPs, damage-associated molecular patterns

*Key words:* doughnut wart, photodynamics therapy, HPV

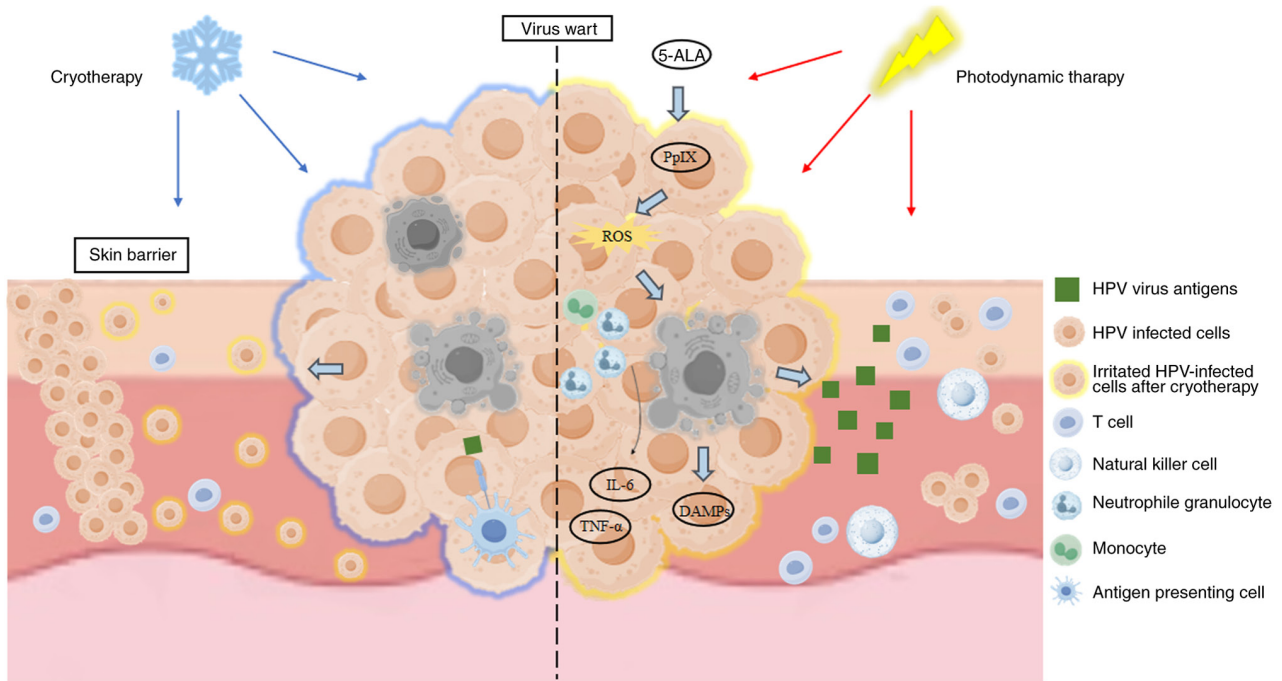


Figure 1. Comparison of the mechanistic differences between cryotherapy and PDT for the treatment of viral warts. The left side of the picture represents that cryotherapy destroys HPV-infected cells using low temperatures, but it may damage the skin barrier, weaken the local immune environment, and induce viral escape and spread, forming a doughnut wart. In addition, HPV may inhibit T-cell recognition by downregulating major histocompatibility complex class I expression and further promote viral transmission. PDT, as shown on the right side of the schematic, used ROS produced by a photosensitizer (5-ALA) to selectively destroy the lesional tissue and activate immune cells (such as T cells and natural killer cells) in normal tissues around the lesion to enhance the local immune microenvironment, effectively eliminating potentially infected cells and preventing further spread of the virus. It may be speculated that PDT induces immunogenic cell death, releases DAMPs (such as high mobility group box 1, adenosine triphosphate and calreticulin), activates antigen-presenting cells, such as dendritic cells, promotes specific immune responses and reduces the risk of recurrence and transmission. PDT, photodynamic therapy; HPV, human papillomavirus; DAMPs, damage-associated molecular patterns; ROS, reactive oxygen species; 5-ALA, 5-aminolevulinic acid; PpIX, protoporphyrin IX.

they exhibited a higher cytotoxic potential. These cells directly target the infected cells, inducing apoptosis and infiltrating the lesion area (Fig. 1). PDT also induces immunogenic cell death (ICD), releasing damage-associated molecular patterns that activate the immune system (11). More importantly, PDT disrupts vascular structures and induces devascularization, limiting the survival environment of virus-infected cells (12).

### Case report

A 21-year-old Chinese female presented at Huadong Hospital (Shanghai, China) in July 2021 with a history of cryotherapy for a viral wart on the left plantar foot 3 months earlier. The lesion had not healed. The central part of the lesion regressed 2 months post-cryotherapy, but a larger, ring-shaped, doughnut-like wart had gradually formed around the original site. Upon examination, a gray-brown, 2.8x2.2 cm ring-shaped plaque with a keratinized, rough surface was observed at the lesion site. Given the spread of the wart following cryotherapy, PDT was selected to enhance immune effects.

After using a CO<sub>2</sub> laser to remove the wart (Fig. 2A), the patient underwent the first PDT session in August 2021 (Fig. 2B). A 20% ALA ointment was applied and covered for 3 h, followed by LED red light (633 nm, 80 mW/cm<sup>2</sup>) irradiation for 30 min. PDT was performed once every week for a total of three sessions. The original ulcer had healed after 7 days, leaving behind a blood scab (Fig. 2C). One week later, the blood scab detached, revealing fresh granulation tissue

(Fig. 2D). The ulcer in the lesion area had gradually healed 2 weeks after treatment, and by one month after treatment, the ulcer had almost completely healed (Fig. 2E). At 1 year post-treatment, the ulcer was fully healed, the plantar wart had completely disappeared and only small scars remained (Fig. 2F).

A follow-up examination was conducted in June 2025 and HPV genotyping was performed. The clinical examination confirmed that the lesion had completely healed, and no recurrence or new warts were found. The photos taken during the follow-up further proved the continuous clearance of the ring-shaped warts (Fig. S1). A swab specimen was obtained in August 2025 from the keratinous debris of a plantar doughnut warts in the dermatology outpatient department of Huadong Hospital (Shanghai, China). The sample was cryopreserved in liquid nitrogen and submitted to a commercial laboratory for HPV genotyping, including HPV1, HPV2, HPV4, HPV27 and HPV57. Specific primers were used for each HPV subtype, as shown in Table S1; the PCR reaction system was configured as specified in Table S2; the thermal cycling procedure is given in Table S3. Genotyping results indicated that HPV1 and HPV27 were positive (Data S1). These findings indicate that even if clinical manifestations completely disappear, certain skin HPV subtypes may still exist in a latent form but will not cause active lesions. These findings emphasize the importance of continuous monitoring even after clinical cure. The clinical images and HPV genotyping results from the follow-up are provided in Fig. S1 and Data S1.

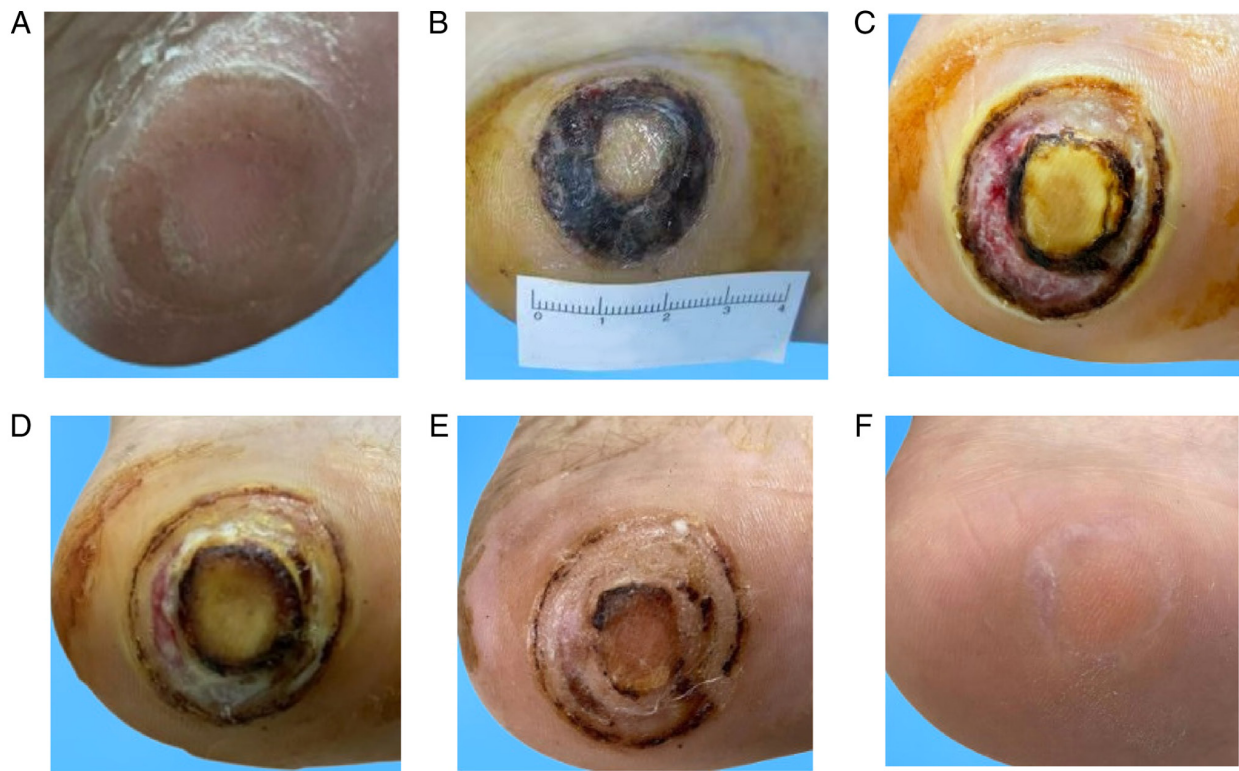


Figure 2. A doughnut wart and its PDT. (A) A typical doughnut wart formed after cryotherapy. (B) After 1 week of CO<sub>2</sub> laser combined with PDT, the wart was significantly reduced; (C) after two times of PDT, the wart further subsided at 1 week; (D) two weeks after two times of PDT, the lesion had significantly improved; (E) 4 weeks after the second PDT, the ulcer was basically healed. (F) No recurrence of the lesions was found and the plantar wart had disappeared completely after 1 year of treatment. PDT, photodynamic therapy.

## Discussion

Doughnut warts can form not only after cryotherapy but also after laser treatment, topical salicylic acid and microwave therapy, although these cases are rarely reported. For example, a 7-year-old girl developed ring-shaped wart lesions around two existing warts on the left index finger after one month of treatment with 17% salicylic acid (8). In these types of cases, HPV is not fully eradicated but instead spreads due to an altered skin microenvironment created by the treatment (13). This environment weakens the skin's barrier, allowing residual HPV to infect surrounding keratinocytes and form doughnut warts. Electrocautery and microwave therapy have also been widely employed for the management of common viral warts (14). Electrocautery enables the precise ablation of lesional tissue with immediate hemostasis and minimal injury to surrounding skin, promoting rapid recovery and a low recurrence rate. Similarly, microwave therapy induces localized hyperthermia, which denatures viral proteins and stimulates host immune responses. Haase *et al* (15) used microwave therapy to treat plantar warts, achieving positive results. Of the 150 plantar warts treated, 83.3% disappeared after two to three treatments. However, no published studies have specifically evaluated electrocautery or microwave therapy for treating doughnut warts. Both ALA-PDT and *Candida* antigen are promising therapeutic options currently. The clearance rate of plantar warts treated with local injection of *Candida* antigen at the base of doughnut warts reaches 82.5% with mild adverse reactions (16).

*Candida* local immunotherapy achieves the therapeutic goal by stimulating a systemic immune response to eliminate HPV-infected cells. By contrast, the complete cure rate of ALA-PDT for plantar warts is 88%, with common adverse reactions including pain and edema. ALA-PDT directly destroys HPV-infected cells through ROS generated, recruits and activates local immune cells and reshapes the local immune microenvironment (17). Cryotherapy may promote the dissemination and reactivation of HPV through multiple mechanisms. First, cryoablation can impair local immune cell function and disrupt the cutaneous barrier within the lesion, facilitating viral spread. Specifically, cryotherapy has been shown to stimulate HPV DNA replication, driving basal keratinocytes to migrate toward the epidermal surface and release infectious virions. This process further compromises the epidermal barrier and enhances viral dissemination (18). Second, although cryotherapy elicits a local immune response, it may simultaneously weaken the immune milieu in adjacent tissues, allowing latent viruses to reactivate. Once reactivated, migrating keratinocytes can disseminate these latent virions into untreated surrounding areas, leading to recurrent infection and the emergence of new lesions, which often manifest as characteristic doughnut warts (19). Treatments like cryotherapy can damage the skin, impairing immune cell function and promoting viral spread. Furthermore, HPV DNA replication is stimulated, leading to further viral activity as basal keratinocytes move to the skin surface and release infectious particles that damage the skin's barrier and facilitate viral spread (18).

Unlike cryotherapy, PDT preserves the skin's natural barrier, preventing HPV spread and reducing the risk of doughnut wart formation (Fig. 1). PDT generates ROS, which target and eliminate infected cells while sparing normal tissue, reducing recurrence. The selective photosensitizer is absorbed more by lesional tissue than by healthy tissue, minimizing damage to surrounding skin (20).

HPV evades immune clearance by downregulating antiviral responses, reducing major histocompatibility-I expression and inhibiting the T-cell recognition of infected cells (20). Viral warts often exhibit immune-suppressive features, resembling cold tumors with insufficient T-cell infiltration, which makes them difficult to clear. PDT induces ICD, releasing HPV antigens and activating the immune response in surrounding tissue, promoting the recruitment and activation of antiviral immune cells to eliminate infected cells (Fig. 1). Chemokines released during PDT attract immune cells to the treatment area, effectively targeting residual HPV.

CO<sub>2</sub> laser therapy employs a CO<sub>2</sub> laser to ablate wart tissue and is widely used to remove periungual and plantar warts. This approach vaporizes the bulk of the lesion, disrupts virus-infected keratinocytes and liberates viral particles that can provoke a systemic immune response (21). The mechanism of PDT in treating viral warts lies in destroying the infected cells within the warts through oxidation reactions, thereby reducing viral replication (22). As doughnut warts were observed after cryotherapy, PDT was incorporated into the treatment regimen. ALA has limited transdermal penetration, but the CO<sub>2</sub> laser can remove hyperkeratotic warts and enhance drug delivery to deeper layers, increasing the concentration at the lesion site. The recurrence rate of CO<sub>2</sub> laser treatment is >30%. The effective rate after 8 weeks of treatment is relatively low (13.04%), and its tolerance is inferior to ALA-PDT (23). PDT has the potential to eliminate latent viral infections, thereby reducing the recurrence rate. On the other hand, it can recruit and activate immune cells, including neutrophils, macrophages and dendritic cells, to enhance the local immune response (24). By combining CO<sub>2</sub> laser with ALA-PDT photodynamic therapy, the recurrence rate is significantly reduced (2%), the effective rate after 8 weeks of treatment increases (36%), and the pain level also shows a significant and marked reduction (25). ALA-PDT offers a more precise, comprehensive treatment approach than physical treatments, such as freezing or laser, which may cause the wart to spread and the subsequent formation of doughnut warts (26). However, despite its therapeutic potential, PDT remains considerably more expensive than alternative modalities and is frequently associated with post-treatment photosensitivity reactions, most commonly erythema, burning sensation, pain or hypersensitivity. Fortunately, these adverse responses are transient and typically resolve spontaneously within several days of treatment (27).

The present case highlights the successful treatment of a 'doughnut wart', a novel HPV-associated lesion that can arise following treatments like cryotherapy. The combination of CO<sub>2</sub> laser debridement and ALA-PDT provided a highly effective treatment regimen for this patient, leading to complete healing with no recurrence over 1 year. The present case reinforces the advantages of ALA-PDT in managing resistant warts, demonstrating its potential to preserve the skin's natural barrier, reduce recurrence, and enhance immune responses through the induction of immunogenic cell death. Furthermore, it emphasizes the

importance of continuous monitoring for latent HPV infections even after clinical resolution. ALA-PDT offers a promising, non-invasive alternative to conventional wart treatments, particularly in cases where viral spread occurs post-treatment.

### Acknowledgements

Not applicable.

### Funding

The study was supported by the National Natural Science Foundation of China (grant no. 82473556), Huadong Hospital Elite Talent (grant no. JYRC2204), and the Clinical Research Plan of Shanghai Municipal Hospital Skin Clinic Clinical Capability Promotion and Enhancement Specialized Alliance (grant no. SHDC22025306).

### Availability of data and materials

The data generated in the present study may be requested from the corresponding author.

### Authors' contributions

LS designed the study and was responsible for the histopathological analysis. KL was responsible for collecting and initially analyzing the medical record data. YTQ conducted a literature review and revised and supplemented the manuscript. WJZ was responsible for the clinical assessment of the case and the writing of the discussion section. YTQ and WJZ have checked and confirmed the authenticity of all the raw data. All the authors were involved in the conception of the study and the analysis of the data. They have all read and approved the final manuscript, and unanimously agreed to the final version of the paper.

### Ethics approval and consent to participate

Not applicable.

### Patient consent for publication

The patient provided written informed consent for their photographs and medical information to be published in print and online and the understanding that this information may be publicly available.

### Competing interests

The authors declare that they have no competing interests.

### References

1. Findlay GH: Wart relapses at the edges of therapeutic cantharidin blisters. *Arch Dermatol* 80: 589-590, 1959.
2. Berth-Jones J and Hutchinson PE: Modern treatment of warts: Cure rates at 3 and 6 months. *Br J Dermatol* 127: 262-265, 1992.
3. Youn SH, Kwon IH, Park EJ, Kim KH and Kim KJ: A two-week interval is better than a three-week interval for reducing the recurrence rate of hand-foot viral warts after cryotherapy: A retrospective review of 560 hand-foot viral warts patients. *Ann Dermatol* 23: 53-60, 2011.

4. Xie J, Ao C, Li J, Jiang L, Liu H and Zeng K: 5-aminolevulinic acid photodynamic therapy for condyloma acuminatum of urethral meatus. *J Dermatolog Treat* 30: 714-717, 2019.
5. Li J, Yi Y and Zhu W: Three stages of 5-aminolevulinic acid-photodynamic therapy for condyloma acuminatum of external urethral meatus. *Zhong Nan Da Xue Xue Bao Yi Xue Ban* 36: 1115-1119, 2011 (In Chinese).
6. Ao C, Xie J, Wang L, Li S, Li J, Jiang L, Liu H and Zeng K: 5-aminolevulinic acid photodynamic therapy for anal canal condyloma acuminatum: A series of 19 cases and literature review. *Photodiagnosis Photodyn Ther* 23: 230-234, 2018.
7. Fehr MK, Hornung R, Degen A, Schwarz VA, Fink D, Haller U and Wyss P: Photodynamic therapy of vulvar and vaginal condyloma and intraepithelial neoplasia using topically applied 5-aminolevulinic acid. *Lasers Surg Med* 30: 273-279, 2002.
8. Sethy M, Srinivas CR, Krishna V and Chadalavada P: Doughnut wart following salicylic acid application: A rare case report. *Indian Dermatol Online J* 12: 451-453, 2021.
9. Wu A, Niu J, Hong Z, Gu L, Huang Y and Qiu L: The effects of 5-aminolevulinic acid photodynamic therapy on the local immune response of women with cervical intraepithelial neoplasia grade 2. *Front Immunol* 14: 1211114, 2023.
10. Shanazarov N, Grishacheva T, Aitkaliyev A, Salmaganbetova Z, Smailova S, Imankulova B, Afanasiev M and Dushkin A: Assessment of systemic reaction to inflammation induced by photodynamic therapy in cervical intraepithelial neoplasia. *Photodiagnosis Photodyn Ther* 50: 104416, 2024.
11. Xiong Y, Yong Z, Zhao Q, Hua A, Wang X, Chen X, Yang X and Li Z: Hydroxyethyl starch-based self-reinforced nanomedicine inhibits both glutathione and thioredoxin antioxidant pathways to boost reactive oxygen species-powered immunotherapy. *Biomaterials* 311: 122673, 2024.
12. Aebischer D, Przygórzewska A and Bartusik-Aebischer D: The latest look at PDT and immune checkpoints. *Curr Issues Mol Biol* 46: 7239-7257, 2024.
13. Venuti A, Lohse S, Tommasino M and Smola S: Cross-talk of cutaneous beta human papillomaviruses and the immune system: Determinants of disease penetrance. *Philos Trans R Soc Lond B Biol Sci* 374: 20180287, 2019.
14. Israr M, DeVoti JA, Lam F, Abramson AL, Steinberg BM and Bonagura VR: Altered monocyte and langerhans cell innate immunity in patients with recurrent respiratory papillomatosis (RRP). *Front Immunol* 11: 336, 2020.
15. Haase O, Barkawi A, Mrowka P and Krengel S: Microwave therapy for the treatment of resistant plantar warts: A randomized, placebo-controlled clinical trial. *Arch Dermatol Res* 317: 208, 2025.
16. Nofal A, Adel L, Fawzy M and Elkholy BM: Intralesional immunotherapy for multiple recalcitrant plantar warts: Candida antigen is superior to intralesional purified protein derivative. *Dermatol Ther* 35: e15440, 2022.
17. Wang H, Xiong L, Xia Y and Wang X: 5-aminolevulinic acid-based photodynamic therapy induces both necrosis and apoptosis of keratinocytes in plantar warts. *J Cosmet Laser Ther* 22: 165-170, 2020.
18. Witchev DJ, Witchev NB, Roth-Kauffman MM and Kauffman MK: Plantar warts: Epidemiology, pathophysiology, and clinical management. *J Am Osteopath Assoc* 118: 92-105, 2018.
19. García-Oreja S, Álvaro-Afonso FJ, Tardáguila-García A, López-Moral M, García-Madrid M and Lázaro-Martínez JL: Efficacy of cryotherapy for plantar warts: A systematic review and meta-analysis. *Dermatol Ther* 35: e15480, 2022.
20. Kim M, Jung HY and Park HJ: Topical PDT in the treatment of benign skin diseases: Principles and new applications. *Int J Mol Sci* 16: 23259-23278, 2015.
21. Hughes PS and Hughes AP: Absence of human papillomavirus DNA in the plume of erbium:YAG laser-treated warts. *J Am Acad Dermatol* 38: 426-428, 1998.
22. Chen Y, Mei Y, Gu L, Li X, Guo P, Chen L and He D: A novel PDT: 5-aminolevulinic acid combined 450 nm blue laser photodynamic therapy significantly promotes cell death of HR-HPV infected cells. *Artif Cells Nanomed Biotechnol* 51: 22-32, 2023.
23. Tu P, Zhang H, Zheng H, Gu H, Xu J, Tao J, Wang H, Zhu X and Wang X: 5-Aminolevulinic photodynamic therapy versus carbon dioxide laser therapy for small genital warts: A multicenter, randomized, open-label trial. *J Am Acad Dermatol* 84: 779-781, 2021.
24. Dudzik T, Domański I and Makuch S: The impact of photodynamic therapy on immune system in cancer-an update. *Front Immunol* 15: 1335920, 2024.
25. Li Y, Wang Q, Zhong W, Pan X, Zhang M and Chi L: Clinical efficacy of CO2 laser combined with 5-aminolevulinic acid photodynamic therapy in treating periungual and plantar warts. *Am J Transl Res* 16: 7364-7373, 2024.
26. Wu C, Qiu X, He C and Ci C: Effect of 5-aminolevulinic acid photodynamic therapy with transfer factor capsules in the treatment of multiple plantar warts. *Biomed Res Int* 2022: 1220889, 2022.
27. Hu YE, Dai SF, Wang B, Qu W and Gao JL: Therapeutic effects of topical 5-aminolevulinic acid photodynamic therapy. *Pak J Med Sci* 32: 961-964, 2016.