

# Expression of p16<sup>INK4a</sup> and MIB-1 in relation to histopathology and HPV types in cervical adenocarcinoma

SUSANNE MULLER<sup>1</sup>, CARMEN FLORES-STAINO<sup>2</sup>, BARBRO SKYLDBERG<sup>2</sup>, ANN-CATHRIN HELLSTRÖM<sup>4</sup>  
BO JOHANSSON<sup>3</sup>, BJORN HAGMAR<sup>6</sup>, KENG-LING WALLIN<sup>5</sup> and SONIA ANDERSSON<sup>1</sup>

<sup>1</sup>Department for Clinical Science, Intervention and Technology, Division of Obstetrics and Gynecology, <sup>2</sup>Laboratory of Clinical Pathology and Cytology, Department of Laboratory Medicine, <sup>3</sup>Division of Clinical Virology, Department of Laboratory Medicine, Karolinska University Hospital at Huddinge, Karolinska Institutet, S-141 86 Stockholm;

<sup>4</sup>Department of Gynecologic Oncology, Radiumhemmet, <sup>5</sup>Department of Molecular Medicine and Surgery, Karolinska University Hospital, Solna, Karolinska Institutet 171 76 Stockholm, Sweden;

<sup>6</sup>Institute of Pathology, The National University Hospital, 0027 Oslo, Norway

Received July 24, 2007; Accepted September 20, 2007

**Abstract.** A total of 101 primary cervical adenocarcinomas were analyzed for the presence of p16<sup>INK4a</sup> and MIB-1 expression in correlation with the presence of 'high-risk' types of human papillomavirus (HR-HPV) and clinical outcome. We found that adenocarcinoma grading showed a significant negative correlation to p16<sup>INK4a</sup> levels (p=0.001): i.e. we found less intense p16 staining in poorly differentiated tumors than in more highly differentiated tumors as well as a highly significant correlation between HPV infection and higher levels of p16<sup>INK4a</sup> staining (p=0.00), which was similar for different HPV-types. Tumor suppressor protein p16<sup>INK4a</sup> levels were higher in HPV positive than in HPV negative tumors. Higher levels of the proliferation marker MIB-1 were associated with poorer outcome. Higher MIB-1 levels were seen in tumors with a lower grade and higher stage at diagnosis. Moreover, MIB-1 levels seem to be higher in tumors due to infection with HPV 16 and 18 compared with HPV 45. MIB-1 may be a helpful marker in grading adenocarcinoma: a high level of expression of MIB-1 indicates a low grade of tumor, whereas high expression of

p16<sup>INK4a</sup> indicates a highly differentiated of the tumor. Thus, immunostaining for p16<sup>INK4a</sup> appears to be a useful diagnostic tool for cervical adenocarcinoma.

## Introduction

Worldwide, uterine cervical carcinoma is the second most common cancer in women and a major cause of cancer-related mortality (1). Due to a combination of organized and sporadic cytology screening, the incidence of squamous cell carcinomas has steadily decreased over the past four decades. However, the incidence of cervical adenocarcinomas has increased during the same period (2-5). In Sweden, the incidence of cervical adenocarcinomas has doubled during the last four decades (3). Apparently, screening programs have only a limited effect on the early detection of adenocarcinoma (3).

It is well established that human papillomavirus (HPV) is the predominant etiological factor in cervical cancer (6). More than 99% of squamous cell carcinomas harbor oncogenic types of HPV, with HPV 16 being the most frequently encountered (6-10), while the detection rate in adenocarcinoma has been reported to vary between 32 and 90% (11-14).

A transforming infection leads to malignant dedifferentiation of the infected cell. Transformation is provoked by interaction of the viral oncogenes of high risk (HR) HPV-E6 and HPV-E7 with different cell cycle proteins. The E7 protein of HR-HPV binds to the tumor suppressor gene Rb and causes a release of the proliferation transcription factor E2F, as well as degradation of pRb. In normal cells Rb blocks the effect of the cyclin-dependent kinase inhibitor p16<sup>INK4a</sup>. The p16 protein is involved in cell cycle regulation, by acting as a tumor suppressor that inhibits cyclin-dependent kinase 4 and 6, thereby decelerating the cell cycle. It usually acts as a down-regulator of cell proliferation. Prolonged extinction of the pRb gene function by the E7 protein leads to upregulation and thereby overexpression of p16 (8).

---

*Correspondence to:* Dr Sonia Andersson, Department for Clinical Science, Intervention and Technology, Division of Obstetrics and Gynecology, Karolinska University Hospital, Huddinge, Karolinska Institutet, 141 86 Stockholm, Sweden  
E-mail: sonia.andersson@telia.com

Dr Keng-Ling Wallin, Department of Molecular Medicine and Surgery, Karolinska Institutet, Karolinska University Hospital-Solna, SE-171 76 Stockholm, Sweden  
E-mail: keng-ling.wallin@ki.se

*Key words:* cervical adenocarcinoma, p16<sup>INK4a</sup> antigen, human papillomavirus, MIB-1

Expression of p16 triggers negative feedback control of the pRb protein, thereby further enhancing p16<sup>INK4a</sup> levels (15). Thus, increased expression of p16<sup>INK4a</sup> represents active expression of the E7 viral oncogene and inactivation of pRb in dysplastic cells and might be a sensitive surrogate marker for such HR-HPV infections (16,17). Overexpression of p16 protein has been demonstrated in squamous cell carcinoma and precursor lesions associated with HR-HPV (18-21). Klaes *et al* reported that p16 immunostaining may be a powerful tool to identify squamous cell carcinomas and preinvasive lesions (21). Some studies revealed a pronounced overexpression of p16 in cervical adenocarcinoma (22,23). Differentiation between adenocarcinoma *in situ* (AIS) and invasive adenocarcinoma of the cervix arising from benign endocervical lesions is difficult. These diagnostic difficulties led to a search for both early and specific markers of endocervical neoplasia.

The MIB-1 antibody directed against the Ki-67 antigen is a marker of mitotically active cells. Ki-67 is a proliferation antigen which is expressed in the nuclei of growing cells. It is present in the G1, S, G2 and M phases of the cell cycle, but not expressed in the G0 phase. It discriminates proliferating from resting cells. Thus, it is an excellent marker of the fraction of growing cells in a cell population and helps to specifically determine the activity of this fraction. The MIB-1 immunostaining pattern is used to assess the proliferation index of a cell population and can be used for grading dysplasia in cervical biopsies (24). Since reduced MIB-1 staining is seen in atrophy and increased in dysplasia (25), it is useful in histopathologically uncertain cases, by helping to distinguish between postmenopausal changes and dysplasia in histological sections. It has been suggested that higher MIB-1 labeling intensity is an indicator of increased proliferation activity associated with unfavorable clinical outcome, increased tumor size and more advanced stage of cancer (26,27).

In the present study, our aim was to evaluate the relation between p16<sup>INK4a</sup> and MIB-1 expression in a series of paraffin-embedded biopsies of primary cervical adenocarcinomas and to correlate the staining pattern with clinical parameters.

## Patients and methods

**Tumor material.** The study includes formaldehyde-fixed paraffin embedded tumor tissue specimens from 101 primary cervical adenocarcinomas diagnosed and surgically treated at Karolinska University Hospital-Huddinge between 1992 and 2000 (Table I). All tumor cases were identified from the Swedish National Cancer Registry maintained by the National Board of Health and Welfare. This registry includes all cases of malignant tumors diagnosed histopathologically after 1959, in which each tumor is identified by a topographical and histopathological code. All tumor samples were collected with informed consent and approval from the local ethics committees.

The clinical information for these cases is summarized in Table I and has in part been previously published (28). The histopathological diagnoses were based on WHO criteria. The 101 tumors were classified as cervical adenocarcinomas and all lacked any squamous cell component. The original

Table I. Age at diagnosis, stage, histology and HPV among patients with cervical adenocarcinoma.

	n	%
Age at diagnosis (years)		
20-29	1	1
30-39	24	23.8
40-49	27	26.7
50-59	18	17.8
60+	30	29.7
Stage <sup>a</sup>		
ACIS <sup>b</sup>	8	7.9
I	56	55.4
II	11	10.9
III	9	8.9
Histology		
High	42	41.6
Moderate	35	34.7
Poor	12	11.9
HPV-negative	37	36.6
HPV-positive	64	63.4
16	30	46.9
18	27	42.2
45	6	9.4

<sup>a</sup>Staging according to the FIGO (Fédération Internationale de Gynécologie et d'Obstétrique) classification for cervical cancer.

<sup>b</sup>Samples contained only superficial mucosal proliferation not showing obvious signs of infiltration into the surrounding stroma.

diagnoses were revised or approved by one pathologist (BH). Eight adenocarcinomas showed only superficial proliferation of the mucosa and no obvious signs of infiltration into the surrounding stroma were present. These tumors were regarded as '*in situ* adenocarcinomas' and the remaining 93 tumors as 'infiltrating cervical adenocarcinomas'. Information on the stage of differentiation was available for 89 of the tumors. Forty-two tumors were well differentiated (41.6%), 35 moderately differentiated (34.7%) and twelve were poorly differentiated (11.9%). The FIGO classification was used for clinical staging of the cervical cancers. Information about clinical stage was available in 76 cases. Most of the patients in our study (56 cases) were classified as stage I (74%), eleven as stage II (14%) and nine as stage III (12%). All patients were retrospectively followed-up from time of diagnosis until January 2007 and disease recurrence and survival data were recorded.

**HPV status.** Results from HPV screening analyses have been previously published for all cases by Andersson *et al* (13). Briefly, the analyses were performed on extracted DNA obtained from a 10- $\mu$ m thick section of paraffin blocks, the

preceding section of which had been used for morphological diagnosis. A fragment of 150 bp was amplified from the L1 region with GP5+/GP6+ primers, HPV-typed by direct DNA sequencing and comparison to known HPV sequences using the BLAST algorithm ([www.ncbi.nlm.nih.gov/BLAST](http://www.ncbi.nlm.nih.gov/BLAST)). Sixty-three of the 101 tumors were found to be HPV positive; 30 tumors were infected with HPV16, 27 with HPV 18 and 6 with HPV 45 (Table I). Mean age at time of diagnosis was 51 years (range 29-85 years). For women with HPV negative tumors mean age was 59 years (range 38-85 years) and for patients with HPV positive tumors, 47 years (range 28-78 years).

**Immunohistochemistry for p16 and MIB-1.** Immunohistochemical staining was performed with the CINtec® Histology Kit (Code No. K5336, Dako Cytomation, Glostrup, Denmark) following the manufacturer's recommendations and using the Dako Autostainer. This kit contains Tris EDTA buffer (x10) pH 9.0 intended for epitope retrieval. A Coplin jar filled with the diluted epitope retrieval buffer, 1:10 distilled water, was placed in a water bath and heated to 95-99°C. Deparaffinized sections were then incubated for 10 min while maintaining a temperature of 95-99°C. Jars with slides were removed from the water bath and left to cool at room temperature for 20 min, followed by washing for 5 min in Wash Buffer (Code No. S3006, Dako Cytomation) diluted 1:10 with distilled water. The automated procedure began with 1x rinse (1x rinse equals 4 min) in wash buffer diluted 1:10 with distilled water [Wash Buffer (x10), Code No. S3006, Dako Cytomation]. Endogenous peroxidase activity was abolished by incubating slides for 5 min in Peroxidase-Blocking Solution (Dako REAL™, Code No. S2023, Dako Cytomation). Slides were rinsed 1x, after which 200 µl of the primary antibody to the p16<sup>INK4a</sup> protein clone E6H4 was dropped onto each slide, followed by incubation for 30 min. Slides were rinsed once. Reaction products were visualized by incubating slides for 30 min with the Visualization Reagent (a horseradish peroxidase/goat anti-mouse immunoglobulin-labeled dextran polymer) and, after 2 rinses, incubating for 10 min in a 1:40 solution of DAB chromogen (3,3'-diaminobenzidine) in DAB Buffered Substrate, also from the CINtec® Histology Kit. Slides were then washed in distilled water for 1 min and counterstained for 2 min in Harris Hematoxylin solution diluted 1:2 with distilled water. After 2 min of washing in water, slides were then dehydrated in ethanol to xylene and mounted in a water-free permanent mounting medium with mounting glass. Tissue sections containing cervical cancer were used as positive controls for p16<sup>INK4a</sup>, while negative controls consisted of incubated doublet-slides in the Negative Control Reagent contained in the kit, instead of primary antibodies.

Immune staining was independently evaluated by two observers (CF-S and BH) and was considered positive for p16<sup>INK4a</sup> when both observers agreed that the nuclei were clearly stained. In addition, cells with a distinct cytoplasmic immunoreaction were scored as positive. Image analysis was carried out as previously described (29). Scoring of the immunohistochemistry results was performed on the basis of both staining intensity and percentage of immunoreactive epithelial cells (30,31). Scoring criteria for p16<sup>INK4a</sup>, expressed

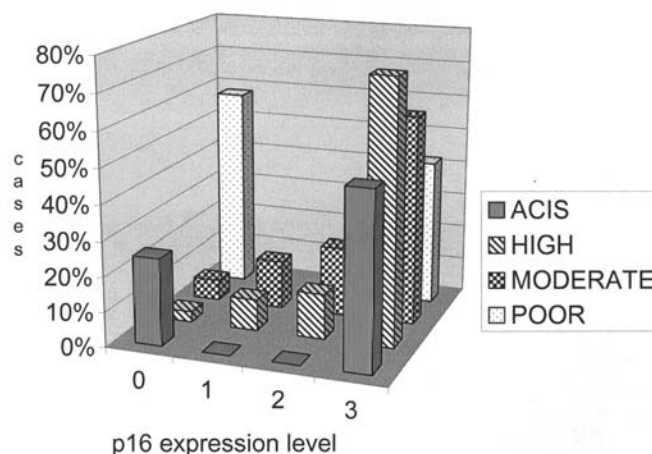


Figure 1. Different scores of p16 expression in samples with various grade of differentiation of cervical adenocarcinoma. Frequency of different scores of p16 antigen expression in all samples, distributed over the four grades, as shown in 97 cases. Vertical hatched bars, ACIS (6 cases); crosshatched bars, highly differentiated tumors (41 cases); chess hatched bars, moderately differentiated tumors (32 cases); and punctuated bars, 5 cases where histology showed poor differentiation.

as percentages (%): (negative)-(no expression); <20-weak staining ( $\pm$ ); 20-30-weak or moderate staining (+); 31-50-moderate or strong staining (++); >50-strong staining (+++). The scores +, ++ and +++ were considered positive for p16<sup>INK4a</sup> (30,31).

To detect the Ki-67 antigen we used monoclonal mouse antibody (clone MIB-1), (Code No. M7240, Dako). The sections were deparaffinized, rehydrated, and microwave-treated in target retrieval solution diluted 1:10 with distilled water (Dako REAL Target Retrieval Solution (x10) Code No. S2023, Dako Cytomation) for 2x5 min at 500 W. Thereafter slides were subjected to the Autostainer procedure and treated together with the p16<sup>INK4a</sup> slides as described above. Ki-67 positivity was scored 1-3 in a manner similar to p16, but only with respect to nuclear staining and with attention to heterogeneity in distribution.

**Statistical analyses.** Data were analyzed using SPSS (Statistical Programs for Social Sciences). Cox regression analysis was performed to evaluate the impact of different biomarkers on survival. ANOVA analysis was used to elucidate the relation between two variables. A p-value of <0.05 was considered statistically significant.

## Results

**p16<sup>INK4a</sup> expression in relation to histology.** In 97 cases the material sufficed for immunological analysis of the p16<sup>INK4a</sup> antigen (Figs. 1 and 3). We were able to demonstrate reactivity to this antigen in 75% (6/8) of ACIS cases, in 95% (41/42) of well differentiated cases, in 91% (32/35) of cases with moderately differentiated tumors, and in only 41% (5/12) of cases diagnosed as poorly differentiated cervical adenocarcinomas. A significant negative correlation was found between p16<sup>INK4a</sup> expression levels (p=0.001) and histological grading; i.e., we found lower level of p16

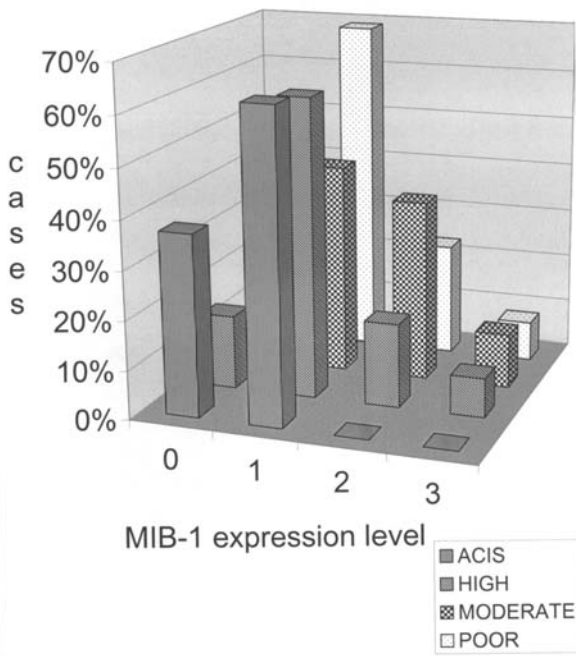


Figure 2. Different scores of MIB-1 expression in samples with various grade of differentiation of cervical adenocarcinoma. Ninety-nine cervical adenocarcinomas were evaluated for the expression of MIB-1 antigen. Vertical hatched bars, ACIS (5 cases); crosshatched bars, highly differentiated tumors (40 cases); chess hatched bars, moderately (35 cases); and punctuated bars, 13 cases with poor differentiation histology.

staining intensity in poorly differentiated tumors than in highly differentiated carcinomas.

We found no correlation between p16<sup>INK4a</sup> expression and stage of disease at time of diagnosis. Similarly, we found no

difference in p16<sup>INK4a</sup> staining intensity between pre-invasive (ACIS) and invasive cancer within the lesions.

*p16<sup>INK4a</sup> expression in relation to different types of HR-HPV.* Table II shows a summary our results regarding the relationship among the different types of HR-HPV and expression of p16<sup>INK4a</sup> antigen. A total of 97 tumors were analyzed for p16 antigen expression.

Of the HPV 16 positive samples scored for p16<sup>INK4a</sup> 7% were +, 10% were ++ and 83% were +++. For HPV 18, 4% were +, 15% were ++ and 81% were +++ when scored for p16<sup>INK4a</sup>. The frequency of different expression levels of p16<sup>INK4a</sup> in HPV 45 positive cases were as follows: 0% +, 17% ++, and 83% +++. Regardless of HPV type, none of the HPV positive cases was negative for p16<sup>INK4a</sup>.

We found a highly significant correlation between HPV infection and higher levels of p16<sup>INK4a</sup> staining (p=0.00), similar for different HPV types. Thirty-four HPV-negative tumors were also analyzed for p16 antigen. We found that 40% (13/34) did not show any reactivity for p16, whereas the remaining 60% of HPV-negative tumors showed varying reactivity scores; moreover, eight tumors showed strong reactivity.

*MIB-1 expression in relation to histology.* Ninety-nine cervical adenocarcinomas were evaluated for expression of MIB-1 antigen. We found that reactivity increased with severity of the lesion: 63% in ACIS, 83% among the highly differentiated tumors, 94% in the group with moderate differentiation (Figs. 2 and 3). An interesting observation was that for all cases in which histology showed poor differentiation, expression of MIB-1 was 100%. Carcinoma grading correlated positively with MIB-1 levels (p=0.031);

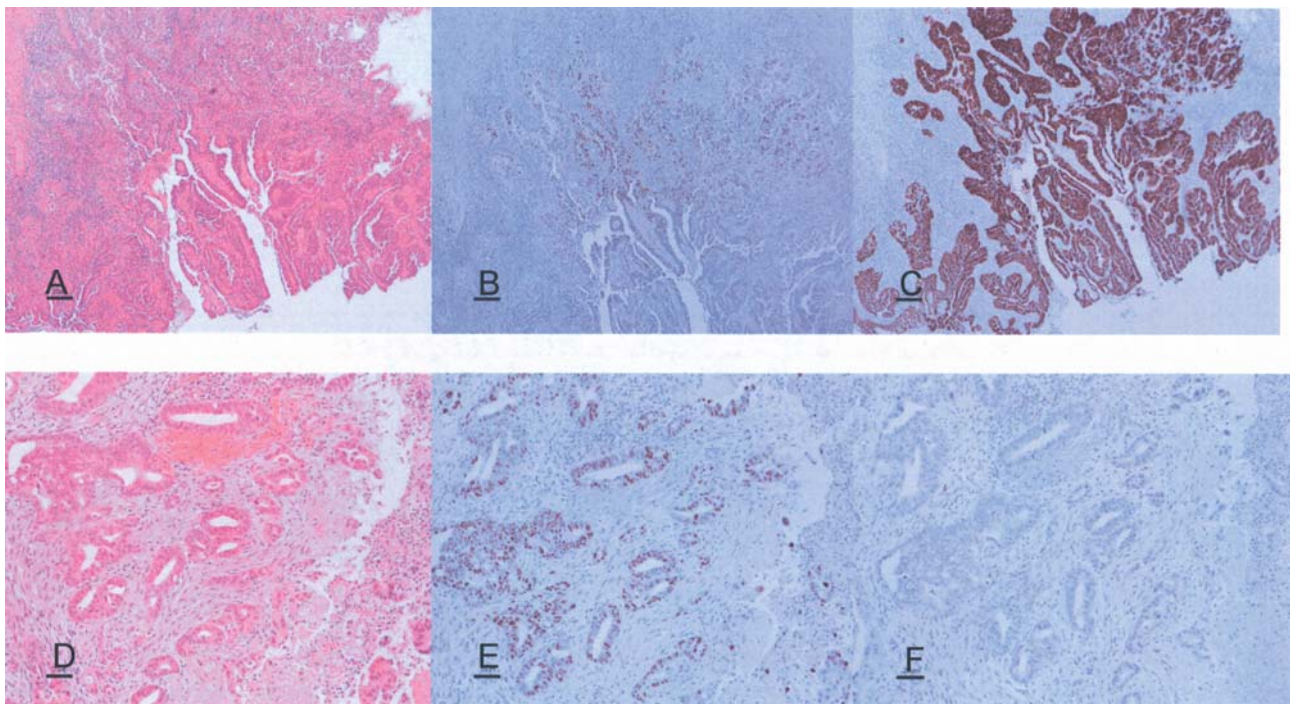


Figure 3. p16<sup>INK4a</sup> and Ki-67 expression in high and poorly differentiated cervical adenocarcinoma. Highly differentiated tumor (A) H&E stain, (B) Ki-67 and (C) p16<sup>INK4a</sup>. Poorly differentiated tumor (D) H&E stain, (E) Ki-67 and (F) p16<sup>INK4a</sup>.

Table II. p16<sup>INK4a</sup> expression intensity in relation to presence of different HPV types.

p16 <sup>INK4a</sup> expression intensity	0 n (%)	+	++	+++	Total no.
		n (%)	n (%)	n (%)	
HPV 16	0 (0)	2 (7)	3 (10)	25 (83)	30
HPV 18	0 (0)	1 (4)	4 (15)	22 (81)	27
HPV 45	0 (0)	0 (0)	1 (17)	5 (83)	6

Table III. MIB-1 expression intensity in relation to presence of different HPV types.

MIB-1 expression intensity	0 n (%)	+	++	+++	Total no.
		n (%)	n (%)	n (%)	
HPV 16	5 (17)	18 (60,0)	7 (23)	0 (0)	30
HPV 18	2 (7)	14 (52)	6 (22)	5 (19)	27
HPV 45	1 (17)	2 (33)	2 (33)	1 (17)	6

we found higher MIB-1 levels in more poorly differentiated tumors. Level of reactivity correlated significantly with histology ( $p=0.004$ ). Thus, we found significantly higher MIB-1 labeling to be associated with higher stage at diagnosis ( $p=0.038$ ). Lower MIB-1 levels were seen in ACIS compared with invasive cancer, but the difference was not significant ( $p=0.06$ ).

**MIB-1 expression in relation to HR-HPV.** The results concerning the correlation of MIB-1 staining and different HR-HPV types are summarized in Table III. In HPV 16-positive cases the frequency of + staining for MIB-1 was 60%, for ++ staining 23% and for +++ staining 0%. In HPV 18-positive cases, 52% showed +, 22% showed ++ and 19% showed +++ for MIB-1 staining. In HPV 45-positive samples, 33% were +, 33% ++ and 17% +++ for MIB-1. In 17% of the HPV 16-positive cases, 7% of the HPV 18-positive cases, and 17% of the HPV 45-positive cases no MIB-1 expression was shown. A significant correlation with high staining levels of MIB-1 for HPV type 16 ( $p=0.029$ ) and HPV type 18 ( $p=0.05$ ) was found.

**Patient outcome with respect to HPV and MIB-1.** The mean age of women with HPV-negative tumors was 59 years (range 38-85 years) and for patients with HPV-positive tumors 47 years (range 28-78 years). HPV infection was significantly correlated with better outcome (survival) in our data ( $p=0.017$ ). After adjusting for age this level of significance disappeared ( $p=0.38$ ). p16<sup>INK4a</sup> staining intensity showed no positive correlation with survival ( $p=0.73$ ). Levels of the MIB-1 proliferation marker correlated negatively with

survival after adjusting for age ( $p=0.004$ ), indicating poorer outcome for patients with higher MIB-1 levels.

## Discussion

Due to significant subjectivity and low sensitivity in interpreting Pap smears and cervical biopsy specimens, an active search is underway for better biomarkers that may prove useful in clinical practice for diagnosing early cervical adenocarcinomas and neoplastic glandular lesions. Further difficulties arise in the staging of adenocarcinoma based on morphology and histology in the absence of a clearly defined preinvasive phase. Moreover, in Pap smear screening, glandular epithelial cells do not exfoliate to the same extent as squamous cells. Furthermore, the highly subjective criteria of histopathological interpretations may lead to equivocal interpretation and therefore a relatively high rate of false-negative and false-positive results. Thus, sensitivity for detecting precursor lesions of adenocarcinoma is much lower than that for squamous cell carcinomas (32).

Our study analyzed 101 primary cervical adenocarcinomas for the expression of the tumor suppressor protein p16<sup>INK4a</sup> and for the proliferation marker Ki-67 (MIB-1). The gene for the tumor suppressor protein p16<sup>INK4a</sup> has reportedly been inactivated in many forms of human cancer, whereas in cervical cancer, a strong nuclear and cytoplasmic overexpression of p16<sup>INK4a</sup> protein has been observed (33). The overexpression of p16<sup>INK4a</sup> in cervical cancer and its precursor lesions is thought to result from the functional inactivation of the pRb protein by the HR-HPV E7 oncoprotein (20). It has been suggested that p16<sup>INK4a</sup> transcription may be directly induced by transcription factor E2F, released from pRb after binding to the HR-HPV E7 protein (15). Klaes *et al* demonstrated that the use of p16<sup>INK4a</sup> immunostaining allows precise identification of CIN and cervical cancer lesions in cervical biopsy specimens, and can significantly reduce false-negative and false-positive interpretation in cervical cancer screening (20). Furthermore, expression of p16<sup>INK4a</sup> may be a predictor of rapid progression, as seen in a longitudinal study (29) and its expression may suggest the presence of transformed cells, even if the lesions appear morphologically normal. The specificity of the staining has been discussed by Murphy *et al*, who found pitfalls in the method with respect to cervical glandular lesions and showed limited applicability for p16<sup>INK4a</sup> in regard to such lesions (34). Nielsen *et al* demonstrated p16<sup>INK4a</sup> staining in some areas of squamous metaplasia with relatively few Ki-67 positive cells in the same area (35).

Our earlier study showed a correlation between CIN grade and p16<sup>INK4a</sup> expression levels for squamous cell neoplasia, in which more advanced lesions show stronger reactivity. However, we found some of the HR-HPV positive lesions lacked p16<sup>INK4a</sup> expression, which might be explained by the regressive nature of these particular cases (36).

Non-dysplastic cells express p16<sup>INK4a</sup> at a very low level that is not detectable by immunochemical means. In a few cells, however, weak physiological expression can occur during cellular stress; for example, in response to squamous cell metaplasia. In the past, researchers tested p16<sup>INK4a</sup> as a marker for persistence of HPV infection, an indicator for histo-

logical grading, and as a predictor of progression to cancer (37,38). They found that p16<sup>INK4a</sup> levels were also elevated in the majority of HR-HPV related cervical cancers as an indicator of aberrant expression of viral oncogenes. However, the majority of these studies were performed on squamous cell lesions that showed a high sensitivity for the marker.

Our material shows that reactivity to p16<sup>INK4a</sup> antigen can be demonstrated in 75% of ACIS cases, 95% of well differentiated lesions, 91% of cases with moderate differentiation and only 41% of cases in which histology showed poor differentiation of cervical adenocarcinomas. Thus, the grade of tumor differentiation was significantly negatively correlated with p16<sup>INK4a</sup> expressions levels ( $p=0.001$ ), showing lower p16<sup>INK4a</sup> staining intensity in poorly differentiated tumors. One study by Missaoui *et al* (22) found expression of p16<sup>INK4a</sup> in all cases of invasive adenocarcinoma, but the authors did not correlate their findings with degree of tumor differentiation. Lee *et al* reported that overexpression of p16<sup>INK4a</sup> was associated with tumor recurrence and poor clinical outcome in patients with prostate cancer (39). However, Ishikawa *et al* found no correlation between p16<sup>INK4a</sup> expression and subtypes of adenocarcinoma, cancer stage, recurrence, or patient age (40). Our finding that the level of p16<sup>INK4a</sup> expression correlates negatively with histological grade may suggest that well differentiated tumors still have a better ability to express tumor suppressor genes, whereas poorly differentiated tumors may have completely lost this ability. Thus, the use of p16<sup>INK4a</sup> as a marker will not identify highly dedifferentiated tumors, but may serve as an additional identification tool for more highly differentiated tumors.

Our results concur with those who found that none of the HPV positive tumors, regardless of HPV type, was negative for p16<sup>INK4a</sup> and that a highly significant correlation exists between HPV infection and higher levels of p16<sup>INK4a</sup> (22). It is notable that all tumors which harbored HPV 45 showed high or moderate expression of p16<sup>INK4a</sup>. The etiology of cervical adenocarcinoma has yet to be fully elucidated, and the degree of association with HPV infection varies among different studies. In our previous study we found that 71% of adenocarcinomas were HPV-positive, whereas in this study about 64% of the tumors were HPV-positive. Probably p16<sup>INK4a</sup>-impaired gene expression contributes to carcinogenesis in some adenocarcinomas, since 40% of our HPV-negative tumors lacked detectable p16<sup>INK4a</sup> overexpression. Loss of functional p16<sup>INK4a</sup> may result in uncontrolled cellular proliferation. In contrast, the overexpression of p16<sup>INK4a</sup> observed in the majority of HPV-negative cervical adenocarcinomas indicates that HPV-independent mechanisms can also lead to overexpression of p16 in these tumors, unless they are due to an undetected past or present infection.

In our data, the correlation between p16<sup>INK4a</sup> staining intensity and survival, which showed worse outcome for higher p16<sup>INK4a</sup> levels, was inconclusive. A study by Alfsen *et al* revealed that high p16<sup>INK4a</sup> expression was a strong predictor of poor prognosis in cervical adenocarcinoma (41). In contrast to these findings, another study on squamous cell cancers showed that low p16<sup>INK4a</sup> expression was associated with decreased overall, but not disease-free survival (42).

However, HPV-positive tumors seemed to be associated with better prognosis.

Ki-67 (MIB-1) has been suggested as an alternative specific marker of progression in both cytology (43) and histopathology (27,44). Cameron *et al* suggested combining its use with p16 in histopathology (45).

Some studies have indicated that MIB-1 immunostaining may be useful in distinguishing endocervical neoplasia from benign endocervical lesions. Cina *et al* described Ki-67 staining as negligible to low in the normal endocervix (46). In our study we found that MIB-1 labeling intensity correlated to both cancer staging and grade, with higher levels of MIB-1 staining associated with higher stage at diagnosis and more poorly differentiated tumors.

We found that MIB-1 levels correlated positively with HR-HPV infection, especially with HPV types 16 and 18. This might indicate a higher proliferating potential for HPV types 16 and 18 compared with HPV 45. It has previously been postulated, that HPV 18 is associated with a more aggressive form of cervical cancer than other HPV types (47). Infection with HPV 16 has also been reported to contribute to a significantly higher risk for progression than infections with other HPV types (48).

We also found a significant positive correlation between p16<sup>INK4a</sup> labeling and MIB-1 levels. Our data show that higher levels of MIB-1, representing the Ki-67 proliferation antigen, have a significant association with poorer outcomes. This result is consistent with previous studies of squamous cell carcinomas, which suggested that higher MIB-1 levels were powerful predictors of shorter survival (49). However, according to other investigations, MIB-1 expression seemed to have no clinical value for predicting long-term disease-free survival (50,51).

In conclusion, levels of the tumor suppressor protein p16<sup>INK4a</sup> are lower in poorly differentiated tumors and in HPV-positive tumors than in HPV-negative tumors. Higher levels of the proliferation marker MIB-1 are associated with poorer outcome. Higher MIB-1 levels are seen in tumors that had a lower grade and higher stage at time of diagnosis. Moreover, MIB-1 levels seem to be higher in tumors due to infection with HPV 16 and 18 compared with HPV 45. MIB-1 may be a helpful marker for grading endocervical malignancies since high expression of MIB-1 indicates a poorly differentiated tumor, whereas high expression of p16<sup>INK4a</sup> indicates a highly differentiated tumor. Thus, immunostaining for both p16<sup>INK4a</sup> and MIB-1 appears to be a useful diagnostic tool for cervical adenocarcinoma.

### Acknowledgments

The authors wish to express their gratitude to Bo Nilsson for his support with the statistical analysis. This study was supported by the Swedish Cancer Foundation, the Swedish Research Council, the Medical Research Council and Cancer Society in Stockholm, the Stockholm County Council and the Swedish Labour Market Insurance.

### References

1. Parkin DM, Pisani P and Ferlay J: Estimates of the worldwide incidence of 25 major cancers in 1990. *Int J Cancer* 80: 827-841, 1999.

2. Vizcaino AP, Moreno V, Bosch FX, *et al*: International trends in incidence of cervical cancer: II. Squamous-cell carcinoma. *Int J Cancer* 86: 429-435, 2000.
3. Bergstrom R, Sparen P and Adami HO: Trends in cancer of the cervix uteri in Sweden following cytological screening. *Br J Cancer* 81: 159-166, 1999.
4. Sasieni P and Adams J: Changing rates of adenocarcinoma and adenosquamous carcinoma of the cervix in England. *Lancet* 357: 1490-1493, 2001.
5. Smith HO, Tiffany MF, Qualls CR and Key CR: The rising incidence of adenocarcinoma relative to squamous cell carcinoma of the uterine cervix in the United States - a 24-year population based study. *Gynecol Oncol* 78: 97-105, 2000.
6. Zur Hausen H: Human papillomaviruses in the pathogenesis of anogenital cancer. *Virology* 184: 9-13, 1991.
7. Walboomers JM, Jacobs MV, Manos MM, *et al*: Human papillomavirus is a necessary cause of invasive cervical cancer worldwide. *J Pathol* 189: 12-19, 1999.
8. Zur Hausen H: Papillomaviruses and cancer: from basic studies to clinical application. *Nat Rev Cancer* 2: 342-350, 2002.
9. Bosch FX, Manos MM, Munoz N, *et al*: Prevalence of human papillomavirus in cervical cancer: a worldwide perspective. International biological study on cervical cancer (IBSCC) Study Group. *J Natl Cancer Inst* 87: 796-802, 1995.
10. Munoz N: Human papillomavirus and cancer: the epidemiological evidence. *J Clin Virol* 19: 1-5, 2000.
11. Andersson S, Rylander E, Larsson B, Strand A, Silfversvard C and Wilander E: The role of human papillomavirus in cervical adenocarcinoma carcinogenesis. *Eur J Cancer* 37: 246-250, 2001.
12. Skyldberg BM, Murray E, Lambkin H, Kelehan P and Auer GU: Adenocarcinoma of the uterine cervix in Ireland and Sweden: human papillomavirus infection and biologic alterations. *Mod Pathol* 12: 675-682, 1999.
13. Andersson S, Rylander E, Larson B, *et al*: Types of human papillomavirus revealed in cervical adenocarcinomas after DNA sequencing. *Oncol Rep* 10: 175-179, 2003.
14. Tenti P, Romagnoli S, Silini E, *et al*: Human papillomavirus types 16 and 18 infection in infiltrating adenocarcinoma of the cervix: PCR analysis of 138 cases and correlation with histologic type and grade. *Am J Clin Pathol* 106: 52-56, 1996.
15. Khleif SN, DeGregori J, Yee CL, *et al*: Inhibition of cyclin D-CDK4/CDK6 activity is associated with an E2F-mediated induction of cyclin kinase inhibitor activity. *Proc Natl Acad Sci USA* 93: 4350-4354, 1996.
16. Dray M, Russell P, Dalrymple C, *et al*: p16(INK4a) as a complementary marker of high-grade intraepithelial lesions of the uterine cervix. I: Experience with squamous lesions in 189 consecutive cervical biopsies. *Pathology* 37: 112-124, 2005.
17. Masumoto N, Fujii T, Ishikawa M, *et al*: P16 overexpression and human papillomavirus infection in small cell carcinoma of the uterine cervix. *Hum Pathol* 34: 778-783, 2003.
18. Agoff SN, Lin P, Morihara J, Mao C, Kiviat NB and Koutsky LA: p16(INK4a) expression correlates with degree of cervical neoplasia: a comparison with Ki-67 expression and detection of high-risk HPV types. *Mod Pathol* 16: 665-673, 2003.
19. Keating JT, Cviko A, Riethdorf S, *et al*: Ki-67, cyclin E and p16INK4 are complimentary surrogate biomarkers for human papilloma virus-related cervical neoplasia. *Am J Surg Pathol* 25: 884-891, 2001.
20. Klaes R, Friedrich T, Spitkovsky D, *et al*: Overexpression of p16(INK4A) as a specific marker for dysplastic and neoplastic epithelial cells of the cervix uteri. *Int J Cancer* 92: 276-284, 2001.
21. Klaes R, Benner A, Friedrich T, *et al*: p16INK4a immunohistochemistry improves interobserver agreement in the diagnosis of cervical intraepithelial neoplasia. *Am J Surg Pathol* 26: 1389-1399, 2002.
22. Missaoui N, Hmissa S, Frappart L, *et al*: p16INK4A overexpression and HPV infection in uterine cervix adenocarcinoma. *Virchows Arch* 448: 597-603, 2006.
23. Lin ZH, Shen XH, Jin Z, *et al*: Human papillomavirus genotyping by oligonucleotide microarray and p16 expression in uterine cervical intraepithelial neoplasm and in invasive carcinoma in Korean women. *Pathol Int* 55: 491-496, 2005.
24. Baak JP and Kruse AJ: Use of biomarkers in the evaluation of CIN grade and progression of early CIN. *Methods Mol Med* 119: 85-99, 2005.
25. Mittal K, Mesia A and Demopoulos RI: MIB-1 expression is useful in distinguishing dysplasia from atrophy in elderly women. *Int J Gynecol Pathol* 18: 122-124, 1999.
26. Heatley MK: What is the value of proliferation markers in the normal and neoplastic cervix? *Histol Histopathol* 13: 249-254, 1998.
27. Kruse AJ, Baak JP, Janssen EA, *et al*: Low- and high-risk CIN 1 and 2 lesions: prospective predictive value of grade, HPV and Ki-67 immuno-quantitative variables. *J Pathol* 199: 462-470, 2003.
28. Andersson S, Larson B, Hjerpe A, *et al*: Adenocarcinoma of the uterine cervix: the presence of human papillomavirus and the method of detection. *Acta Obstet Gynecol Scand* 82: 960-965, 2003.
29. Wang JL, Zheng BY, Li XD, Angstrom T, Lindstrom MS and Wallin KL: Predictive significance of the alterations of p16INK4A, p14ARF, p53 and proliferating cell nuclear antigen expression in the progression of cervical cancer. *Clin Cancer Res* 10: 2407-2414, 2004.
30. Sano T, Oyama T, Kashiwabara K, Fukuda T and Nakajima T: Expression status of p16 protein is associated with human papillomavirus oncogenic potential in cervical and genital lesions. *Am J Pathol* 153: 1741-1748, 1998.
31. Klussmann JP, Gultekin E, Weissenborn SJ, *et al*: Expression of p16 protein identifies a distinct entity of tonsillar carcinomas associated with human papillomavirus. *Am J Pathol* 162: 747-753, 2003.
32. Krane JF, Granter SR, Trask CE, Hogan CL and Lee KR: Papanicolaou smear sensitivity for the detection of adenocarcinoma of the cervix: a study of 49 cases. *Cancer* 93: 8-15, 2001.
33. Saqi A, Pasha TL, McGrath CM, Yu GH, Zhang P and Gupta P: Overexpression of p16INK4A in liquid-based specimens (SurePath) as marker of cervical dysplasia and neoplasia. *Diagn Cytopathol* 27: 365-370, 2002.
34. Murphy N, Heffron CC, King B, *et al*: p16INK4A positivity in benign, premalignant and malignant cervical glandular lesions: a potential diagnostic problem. *Virchows Arch* 445: 610-615, 2004.
35. Nielsen GP, Stemmer-Rachamimov AO, Shaw J, Roy JE, Koh J and Louis DN: Immunohistochemical survey of p16INK4A expression in normal human adult and infant tissues. *Lab Invest* 79: 1137-1143, 1999.
36. Andersson S, Wangsa D, Flores-Staino C, *et al*: Expression of p16(INK4a) in relation to histopathology and viral load of 'high-risk' HPV types in cervical neoplastic lesions. *Eur J Cancer* 42: 2815-2820, 2006.
37. Branca M, Ciotti M, Santini D, *et al*: p16(INK4A) expression is related to grade of cin and high-risk human papillomavirus but does not predict virus clearance after conization or disease outcome. *Int J Gynecol Pathol* 23: 354-365, 2004.
38. Negri G, Vittadello F, Romano F, *et al*: p16INK4a expression and progression risk of low-grade intraepithelial neoplasia of the cervix uteri. *Virchows Arch* 445: 616-620, 2004.
39. Lee CT, Capodiec P, Osman I, *et al*: Overexpression of the cyclin-dependent kinase inhibitor p16 is associated with tumor recurrence in human prostate cancer. *Clin Cancer Res* 5: 977-983, 1999.
40. Ishikawa M, Fujii T, Masumoto N, *et al*: Correlation of p16INK4A overexpression with human papillomavirus infection in cervical adenocarcinomas. *Int J Gynecol Pathol* 22: 378-385, 2003.
41. Alfsen GC, Reed W, Sandstad B, Kristensen GB and Abeler VM: The prognostic impact of cyclin dependent kinase inhibitors p21WAF1, p27Kip1 and p16INK4/MTS1 in adenocarcinomas of the uterine cervix: an immunohistochemical evaluation of expression patterns in population-based material from 142 patients with international federation of gynecology and obstetrics stage I and II adenocarcinoma. *Cancer* 98: 1880-1889, 2003.
42. Van de Putte G, Holm R, Lie AK, Trope CG and Kristensen GB: Expression of p27, p21 and p16 protein in early squamous cervical cancer and its relation to prognosis. *Gynecol Oncol* 89: 140-147, 2003.
43. Sahebali S, Depuydt CE, Segers K, Vereecken AJ, Van Marck E and Bogers JJ: Ki-67 immunocytochemistry in liquid based cervical cytology: useful as an adjunctive tool? *J Clin Pathol* 56: 681-686, 2003.
44. Lorenzato M, Caudroy S, Bronner C, *et al*: Cell cycle and/or proliferation markers: what is the best method to discriminate cervical high-grade lesions? *Hum Pathol* 36: 1101-1107, 2005.

45. Cameron RI, Maxwell P, Jenkins D and McCluggage WG: Immunohistochemical staining with MIB1, bcl2 and p16 assists in the distinction of cervical glandular intraepithelial neoplasia from tubo-endometrial metaplasia, endometriosis and microglandular hyperplasia. *Histopathology* 41: 313-321, 2002.
46. Cina SJ, Richardson MS, Austin RM and Kurman RJ: Immunohistochemical staining for Ki-67 antigen, carcino-embryonic antigen and p53 in the differential diagnosis of glandular lesions of the cervix. *Mod Pathol* 10: 176-180, 1997.
47. Barnes W, Delgado G, Kurman RJ, *et al*: Possible prognostic significance of human papillomavirus type in cervical cancer. *Gynecol Oncol* 29: 267-273, 1988.
48. Syrjanen KJ: Spontaneous evolution of intraepithelial lesions according to the grade and type of the implicated human papillomavirus (HPV). *Eur J Obstet Gynecol Reprod Biol* 65: 45-53, 1996.
49. Ho DM, Hsu CY and Chiang H: MIB-1 labeling index as a prognostic indicator for survival in patients with FIGO stage IB squamous cell carcinoma of the cervix. *Gynecol Oncol* 76: 97-102, 2000.
50. Avall-Lundqvist EH, Silfversward C, Aspenblad U, Nilsson BR and Auer GU: The impact of tumour angiogenesis, p53 over-expression and proliferative activity (MIB-1) on survival in squamous cervical carcinoma. *Eur J Cancer* 33: 1799-1804, 1997.
51. Graflund M, Sorbe B and Karlsson M: MIB-1, p53, bcl-2 and WAF-1 expression in pelvic lymph nodes and primary tumors in early stage cervical carcinomas: correlation with clinical outcome. *Int J Oncol* 20: 1041-1047, 2002.