

Hypersomnia as the first presentation in a patient with insulinoma: A case report and review of the literature

JIALI PU, BAORONG ZHANG and XINZHEN YIN

Department of Neurology, Second Affiliated Hospital, College of Medicine,
Zhejiang University, Hangzhou, Zhejiang 310009, P.R. China

Received April 14, 2016; Accepted June 13, 2016

DOI: 10.3892/mco.2016.969

Abstract. Insulinoma is a rare neuroendocrine tumor. Hypersomnia as the first presentation in a patient with insulinoma is even more rare and may be easy to misdiagnose. We are herein reporting a case of insulinoma initially presenting with prolonged sleep time and extreme difficulty in waking. The abovementioned symptoms occurred every 2-3 months. Over the last 2 months, the attacks had become more frequent and severe. On computed tomography examination, a 12x9-mm cystic nodule was detected in the uncinate process of the pancreas, which was pathologically diagnosed as insulinoma. Since resection, the symptom of hypersomnia has not occurred again. The aim of the present report was to raise awareness among physicians to consider insulinoma in the differential diagnosis of hypersomnia in patients without other known diseases.

Introduction

Insulinoma is a rare neuroendocrine tumor (annual incidence, 4/1,000,000 individuals), which is derived from β -cells in the pancreas and secretes insulin (1). The main clinical manifestations include altered mental status, visual disturbances, amnesia, coma and abnormal behavior (2,3). Seizures are also common in patients with insulinoma (4-7). Insulinoma is often misdiagnosed as neurological diseases, due to its insidious and deceptive symptoms. In retrospective reviews, $\leq 64\%$ patients with insulinoma presenting with neuropsychiatric symptoms were misdiagnosed with neurological disorders (8,9). However, hypersomnia is an extremely rare clinical presentation in patients with insulinoma, with only 2 cases reported in the literature to date (10,11). We herein report the case

of a male patient who was admitted to our Department of Neurology for severe excessive daytime sleepiness associated with insulinoma-induced hypoglycemia.

Case report

A 62-year-old man was admitted to our hospital for recurrent episodes of prolonged sleepiness over the last 3 years. Initially, the patient presented with prolonged sleep time and extreme difficulty to wake up; after the attacks, his usual sleep pattern was spontaneously recovered. The abovementioned symptoms occurred every 2-3 months. Over the last 2 months, the attacks became increasingly frequent and severe, occurring as often as every 3 days. The patient continuously slept for 20-24 h daily; his spouse also noted abnormal behaviors, such as that the patient was unable to concentrate, suffered from mild memory loss, was unable to speak and was scantily dressed within the first half an hour after waking up.

The body mass index of the patient was 19.2 kg/m². Surprisingly, the neurological examination was normal and the mini-mental status examination score was 25. The fingertip blood glucose test on admission and the cerebrospinal fluid examination were normal. Brain magnetic resonance imaging and routine electroencephalography (EEG) also did not reveal any abnormalities.

On the second day of admission, an extremely low level of blood glucose (20.7 mg/dl) was observed. However, the patient reported no symptoms of shakiness, palpitations, perspiration or numbness. Medicated sugared water was administered to reverse the hypoglycemic status. The pituitary and adrenal hormone levels were normal. In order to identify the cause of hypoglycemia, a 75-g oral glucose tolerance test was performed. The results revealed a low plasma glucose level (34.56 mg /dl) at baseline, with a corresponding insulin level of 410.2 IU/ml. A repeat test revealed a plasma glucose level of 33.1 mg/dl, with a corresponding insulin level of 226.87 IU/ml. Thus, the diagnosis of idiopathic hypersomnia was taken into consideration.

A computed tomography (CT) scan was performed and it revealed a 12x9-mm cystic nodule in the uncinate process of the pancreas (Fig. 1). The patient was referred to the Department of General Surgery and underwent resection of the tumor. On histopathological examination, the tumor was confirmed to be an insulinoma. The blood glucose levels

Correspondence to: Dr Xinzhen Yin, Department of Neurology, Second Affiliated Hospital, College of Medicine, Zhejiang University, 88 Jiefang Road, Hangzhou, Zhejiang 310009, P.R. China
E-mail: xinzhen_yin@163.com

Key words: insulinoma, hypersomnia, manifestation, surgical resection, prognosis

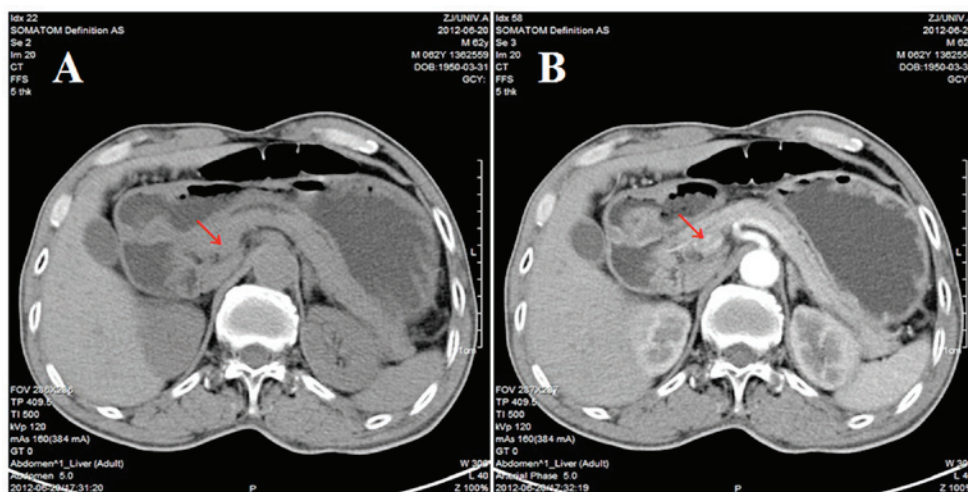


Figure 1. Computed tomography (CT) scan of the upper abdomen. (A) The CT scan did not reveal any abnormalities (arrow indicates the location of the tumor). (B) On enhanced CT scan, a 12x9-mm cystic nodule was identified in the uncinate process of the pancreas (arrow), exhibiting high density, which was diagnosed as insulinoma on histopathological examination.

fluctuated between 100.8 and 189 mg/dl after the operation, whereas during the 2-year follow-up, the glucose levels fluctuated between 98.6 and 111.6 mg/dl and hypersomnia did not occur again.

Discussion

In the present case, hypersomnia was the main neurological symptom for which the patient sought medical consultation. The extremely low blood glucose level raised the suspicion that hypersomnia and hypoglycemia were induced by insulinoma. In order to identify whether hypersomnia was due to hypoglycemia, blood glucose monitoring was simultaneously performed. The patient was entirely free from hypersomnia during >18 months of follow-up following insulinoma resection. Thus, it was concluded that the hypersomnia was caused by insulinoma-induced hypoglycemia.

Insulinoma is the most common pancreatic endocrine tumor; it is derived from β -cells and secretes excessive insulin. Insulinoma was often misdiagnosed as primary neurological or psychiatric disorders, due to the transient EEG abnormalities observed during hypoglycemic episodes. Insulinoma presenting as seizures or paroxysmal disorders has been commonly reported (4-7), suggesting it may lead to brain injury due to hypoglycemia. However, insulinoma-related hypersomnia is extremely rare, with only 2 cases reported in the literature to date: Maestri *et al* (10) reported the case of a 32-year-old woman with a history of increased need for sleep, difficulty in waking up, a very low blood glucose level (32 mg/dl) and a hypodense mass in the pancreatic tail on CT scan, which indicated that insulinoma patients may present with hypersomnia. Additionally, Dhume *et al* (11) reported another case of insulinoma associated with unconsciousness following repeated episodes of inability to arise from sleep and convulsions. It has been reported that hypoglycemia may induce autonomic failure in diabetic patients (12). In the present case, maintaining normal glucose levels eliminated hypersomnia and reversed the EEG findings to normal. When healthy individuals and diabetic patients maintained non-rapid

eye movement sleep, the sympathetic responses to hypoglycemia were decreased (13). Furthermore, hypersomnia was completely eliminated in patients following insulinoma resection. All other possible causes, including medical, neurological and psychiatric disorders or medications, were excluded. Therefore, hypersomnia was attributed to insulinoma-induced hypoglycemia. Similar to the present case, the diagnosis of insulinoma was delayed in those cases due to misattribution of the symptoms to psychiatric or neurological disorders. This delayed diagnosis may be detrimental to the patients, since hypersomnia may precede syncope due to hypoglycemia. Early diagnosis may prevent the fatal outcome of such patients, although it may be difficult due to the non-specific clinical manifestations. Hence, the aim of the present case report is to raise awareness among physicians to consider insulinoma in the differential diagnosis of hypersomnia in patients without other known diseases.

Regarding treatment, surgical resection of insulinoma is required. According to the literature, surgical resection of insulinoma is curative in ~90% of the cases (1). In addition, routine glucose monitoring should be included in the management of these patients. Annual follow-up is also required.

In conclusion, this was a rare case of insulinoma manifesting as hypersomnia. This case highlights the need to recognize that, on rare occasions, hypersomnia may be an unusual manifestation of insulinoma. Surgical resection is the recommended treatment for insulinoma presenting as hypersomnia and the prognosis appears to be favorable.

This study was approved by the Department of Medicine of the Second Affiliated Hospital, Zhejiang University and the informed consent was obtained from the patient for the publication of the case details.

Acknowledgements

The present study was supported by the Zhejiang Province Foundations of Department of Science and Technology (grant no. 2012C23088) and the Health and Family Planning Commission of Zhejiang Province (grant no. 2012KYB099).

References

1. Service FJ, McMahon MM, O'Brien PC and Ballard DJ: Functioning insulinoma-incidence, recurrence, and long-term survival of patients: A 60-year study. *Mayo Clin Proc* 66: 711-719, 1991.
2. Shin JJ, Gorden P and Libutti SK: Insulinoma: Pathophysiology, localization and management. *Future Oncol* 6: 229-237, 2010.
3. Boukhman MP, Karam JH, Shaver J, Siperstein AE, Duh QY and Clark OH: Insulinoma-experience from 1950 to 1995. *West J Med* 169: 98-104, 1998.
4. Bazil CW and Pack A: Insulinoma presenting as seizure disorder. *Neurology* 56: 817-818, 2001.
5. Wang S, Hu HT, Wen SQ, Wang Z, Zhang BR and Ding MP: An insulinoma with clinical and electroencephalographic features resembling complex partial seizures. *J Zhejiang Univ Sci B* 9: 496-499, 2008.
6. Gupta M, Batra A, Hirve M, Chowdhury D, Khwaja GA and Mishra PK: Paroxysmal dystonic choreoathetosis with symptomatic seizures secondary to hypoglycemia caused by insulinoma. *Ann Indian Acad Neurol* 14: 313-315, 2011.
7. Striano P and Striano S: Insulinoma presenting as refractory late-onset epilepsy. *Epilepsia* 47: 452; author reply 452, 2006.
8. Ding Y, Wang S, Liu J, Yang Y, Liu Z, Li J, Zhang B, Chen Y and Ding M: Neuropsychiatric profiles of patients with insulinomas. *Eur Neurol* 63: 48-51, 2010.
9. Dizon AM, Kowalyk S and Hoogwerf BJ: Neuroglycopenic and other symptoms in patients with insulinomas. *Am J Med* 106: 307-310, 1999.
10. Maestri M, Monzani F, Bonanni E, Di Coscio E, Cignoni F, Dardano A, Iudice A and Murri L: Insulinoma presenting as idiopathic hypersomnia. *Neurol Sci* 31: 349-352, 2010.
11. Dhume VM, Amarapurkar AD, Rege JD, Kandalkar BM and Varthakavi P: Insulinoma-a case report. *Indian J Pathol Microbiol* 47: 540-541, 2004.
12. Cryer PE: Mechanisms of hypoglycemia-associated autonomic failure and its component syndromes in diabetes. *Diabetes* 54: 3592-3601, 2005.
13. Jones TW, Porter P, Sherwin RS, Davis EA, O'Leary P, Frazer F, Byrne G, Stick S and Tamborlane WV: Decreased epinephrine responses to hypoglycemia during sleep. *N Engl J Med* 338: 1657-1662, 1998.