

# Red nodular melanoma of the penile foreskin: A case report and literature review

YUKI MARUYAMA, TAKUYA SADAHIRA, YOSUKE MITSUI, KOICHIRO WADA,  
RYUTA TANIMOTO, YASUYUKI KOBAYASHI, MOTOO ARAKI, MASAMI WATANABE,  
TOYOHICO WATANABE and YASUTOMO NASU

Department of Urology, Okayama University Graduate School of Medicine, Okayama, Okayama 700-8558, Japan

Received June 21, 2018; Accepted August 2, 2018

DOI: 10.3892/mco.2018.1697

**Abstract.** The penis is an extremely rare primary site for malignant melanomas, and the clinical presentation may vary greatly. We herein present the case of a 71-year-old male patient who presented with a 6-year history of two slow growing, asymptomatic red macules on the penile foreskin. On physical examination, the mobility of the foreskin was good, and there was no metastasis on computed tomography and magnetic resonance imaging. The patient underwent segmental circumcision for treatment and histological diagnosis, and the histological examination revealed a malignant melanoma. As cancer cells were identified at the edge of the tissue specimen and computed tomography-positron emission tomography revealed increased uptake of  $^{18}\text{F}$ -fluorodeoxyglucose in the penis, wider resection and a right sentinel lymph node biopsy were performed; both specimens came back negative. Two years after the surgery, there has been no evidence of locoregional recurrence or distant metastases. The aim of this report is to alert physicians to include melanoma in the differential diagnosis of red-pigmented lesions of the penile foreskin.

## Introduction

Malignant melanoma of the penis is extremely rare, accounting for <1.4% of all primary penile malignant lesions and 0.1-0.2% of all extraocular melanomas (1,2). Malignant melanoma of the penis occurs most frequently on the glans penis (55%), followed by the prepuce (28%), penile shaft (9%) and urethral meatus (8%) (3). As malignant melanoma of the penis is rare, the pathogenesis and risk factors have not been well established. At the time of the first visit, malignant melanoma of the penis is often in an advanced stage, and ~50% of the patients develop metastatic lesions to the inguinal region (4).

The primary treatment of melanoma of the penis and urethra is surgical, although there is a lack of consensus regarding the extent of treatment that is indicated (5). We herein present the case of a patient with malignant melanoma of the penile foreskin who underwent circumcision for histological diagnosis and treatment.

## Case report

A 71-year-old Japanese male patient presented to the Department of Urology, Okayama University Hospital (Okayama, Japan) with two non-healing lesions on the penile foreskin, which had been growing gradually for 5 years and had enlarged over the last year. The patient's medical and family history was unremarkable.

On physical examination, two hemorrhagic red-pigmented lesions and an ulcer on the penile foreskin were observed (Fig. 1). No metastasis was evident on computed tomography (CT) and magnetic resonance imaging, and the foreskin had good mobility; thus, the lesions were considered to be confined to the foreskin.

Segmental circumcision was performed for histological diagnosis and treatment. The histological examination revealed a malignant melanoma. The atypical melanocytic cells proliferated in the dermis and invaded into the basal cells of the epidermis (Fig. 2A). The tumor thickness was 11 mm, and the surface was ulcerated. According to the classification of the Union for International Cancer Control, the tumor was stage IIC (pT4bN0M0). No tumor cells were detected on the resection margins of the specimens; however, the distance of the lesion from the margins was <1 cm. In addition, positron emission tomography (PET)/CT revealed increased uptake of  $^{18}\text{F}$ -fluorodeoxyglucose in the penis (standardized uptake value=3.23; Fig. 2B). Considering the possibility of the residual tumor or metastasis, an extended circumcision and right sentinel lymph node biopsy (SLNB) were performed following sentinel lymph node scintigraphy with Tc-99m-phytate (Fig. 2C). There were no histological findings consistent with residual tumor or metastasis (Fig. 2D). Adjuvant interferon treatment was initiated, although it was discontinued due to intense pain associated with the subcutaneous injection. The patient remained alive and had no recurrence at the 2-year follow-up evaluation on January 2018.

---

*Correspondence to:* Dr Takuya Sadahira, Department of Urology, Okayama University Graduate School of Medicine, 2-5-1 Shikata-cho, Kita-ku, Okayama, Okayama 700-8558, Japan  
E-mail: t.sadahira@gmail.com

**Key words:** melanoma, circumcision, penile foreskin, penis

## Discussion

Primary malignant melanoma of the penis is extremely rare. Malignant melanoma is one of the most aggressive tumors, as it can metastasize to any tissue or organ without symptoms. The incidence of melanoma is rapidly increasing, with an overall rate of 33% in men and 23% in women between 2002 and 2006 (6). As a primary lesion, melanoma of the penis accounts for <0.2% of all melanomas and 1.4% of all primary penile malignant lesions (1,2). Penile malignant melanoma most frequently involves the glans penis (55%), followed by the prepuce (28%), penile shaft (9%) and urethral meatus (8%) (3). Malignant melanoma of the penis is mainly a disease of the elderly; specifically, men aged 50-70 years are most frequently diagnosed with this disease. By contrast, cutaneous melanomas in other areas of the body are mostly diagnosed in the 40-49-year age group. The 2- and 5-year overall survival (OS) rates for malignant melanoma of the penis are 63 and 31%, respectively, while the 5-year OS rate is  $\geq 50\%$  for cutaneous melanomas (7,8). This difference in OS may be attributed to metastasis at the initial visit. Although 84% of patients with cutaneous melanomas initially present with localized disease, 43-62% of patients with melanoma of the penis present with lymph node involvement. As penile lesions are a sensitive subject for men, there is usually a delay in seeking medical advice until the lesions enlarge (9); thus, diagnosis is usually delayed.

The typical melanoma is black in color; however, melanomas may occasionally have a red or brown appearance, as in the present case. Red melanomas are frequently diagnosed as amelanotic melanomas (AMs), the incidence of which is estimated to be between 1.8 and 8.1% of all melanoma cases (10). AMs lack pigment. The histological examination in the present case revealed minimal deposition of melanin pigment in the tumor cells; therefore, the pathological findings in our case were similar to those of an AM. Melanomas are divided into the following four clinical subtypes: Lentigo maligna melanoma; superficial spreading melanoma; nodular melanoma; and acral lentiginous melanoma. Among these subtypes, acral lentiginous melanoma is most common in Japan, and usually develops in non-sun-damaged sites, such as the soles, palms, or subungual areas. Our patient was diagnosed with a nodular melanoma, which is characterized by the highest malignant potential among all subtypes, with a large depth of invasion and frequent metastasis (11).

Prediction of the clinical course of melanoma is mainly based on tumor thickness; however, the assessment of tumor thickness alone is not sufficient. Other important factors associated with the prognosis of melanomas include tumor diameter ( $\geq 15$  mm), extent of involvement of local structures, and whether there is evidence of metastases to the inguinal or pelvic lymph nodes (12). The American Joint Committee on Cancer (AJCC) staging protocol for melanoma, which is currently the most widely accepted, confirms that tumor thickness and ulceration are the most important predictors in the TNM classification (8). Our patient was diagnosed with AJCC stage IIC (pT4bM0N0) melanoma of the penis.

The primary treatment of melanoma of the glans penis and urethra is surgery; however, the main area of controversy lies with the extent of surgery for localized disease (13). In

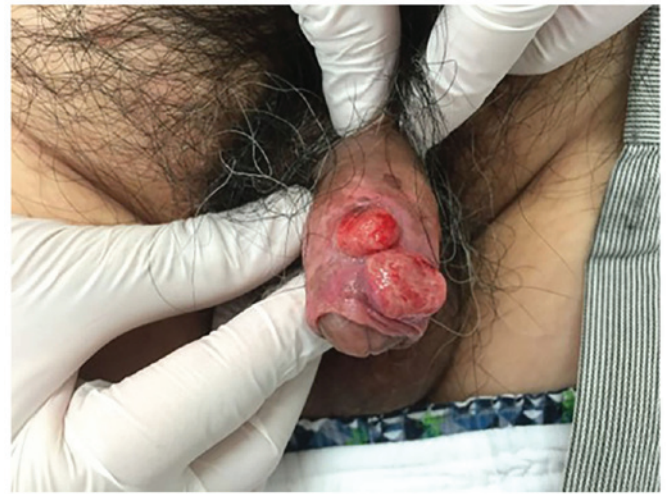

Figure 1. Macroscopic appearance of nodular malignant melanoma involving the penile foreskin.

the 1970s and 1980s, some authors suggested an aggressive surgical approach, with total amputation of the penis, perineal urethrostomy, and radical inguinal, iliac and obturator lymph node dissection (14). A recent study, however, recommends a more conservative, wide local excision (15). Several prospective randomized trials have been conducted to define the surgical margins for melanomas, and it was concluded that margins  $>2$  cm are not associated with a superior OS, regardless of the melanoma thickness (16,17). Based on the 2017 National Comprehensive Cancer Network (NCCN) guidelines, a 2.0-cm clinical margin is recommended when the tumor is  $>2.0$  mm in thickness. In our patient, the foreskin maintained good mobility; therefore, the tumor was considered to be confined to the penile foreskin and a segmental circumcision was recommended. However, the clinical margin was  $<1.0$  cm; thus, the resection was extended to 1.5 cm.

Elective lymph node dissection is not recommended in patients with malignant melanoma of the penis due to the low probability of positive findings (20%), and lack of impact on the OS compared with expectant management (18). By contrast, SLNB is considered to be useful in the evaluation of melanomas with a thickness of  $\geq 1$  mm according to the NCCN guidelines. In the case of very thin melanomas (IA or B), the positive SLNB rate is low ( $\leq 5\%$ ) and is not associated with a significant benefit, while thicker tumors ( $\geq 4$  mm) have a 34.4% positive rate (19). To identify the sentinel lymph node, lymph node scintigraphy prior to biopsy is useful (20). If the SLNB is negative, regional lymph node dissection is not necessary. As the tumor was thicker (11 mm) in the present case, SLNB was performed to detect metastasis following sentinel lymph node scintigraphy with Tc-99m-phytate.

The prognosis of stage II and III disease is poor due to the lack of effective systemic chemotherapy. It has been reported that six cycles of combination chemotherapy (decabazine, carmustine, cisplatin and tamoxifen) achieve an overall response rate of 45% and a complete response rate of 12-14% (21). It is considered that 5% of patients with stage III melanoma may be curable (21,22). Several trials have demonstrated that treatment with high doses of adjuvant interferon in high-risk melanoma reduced the risk of recur-

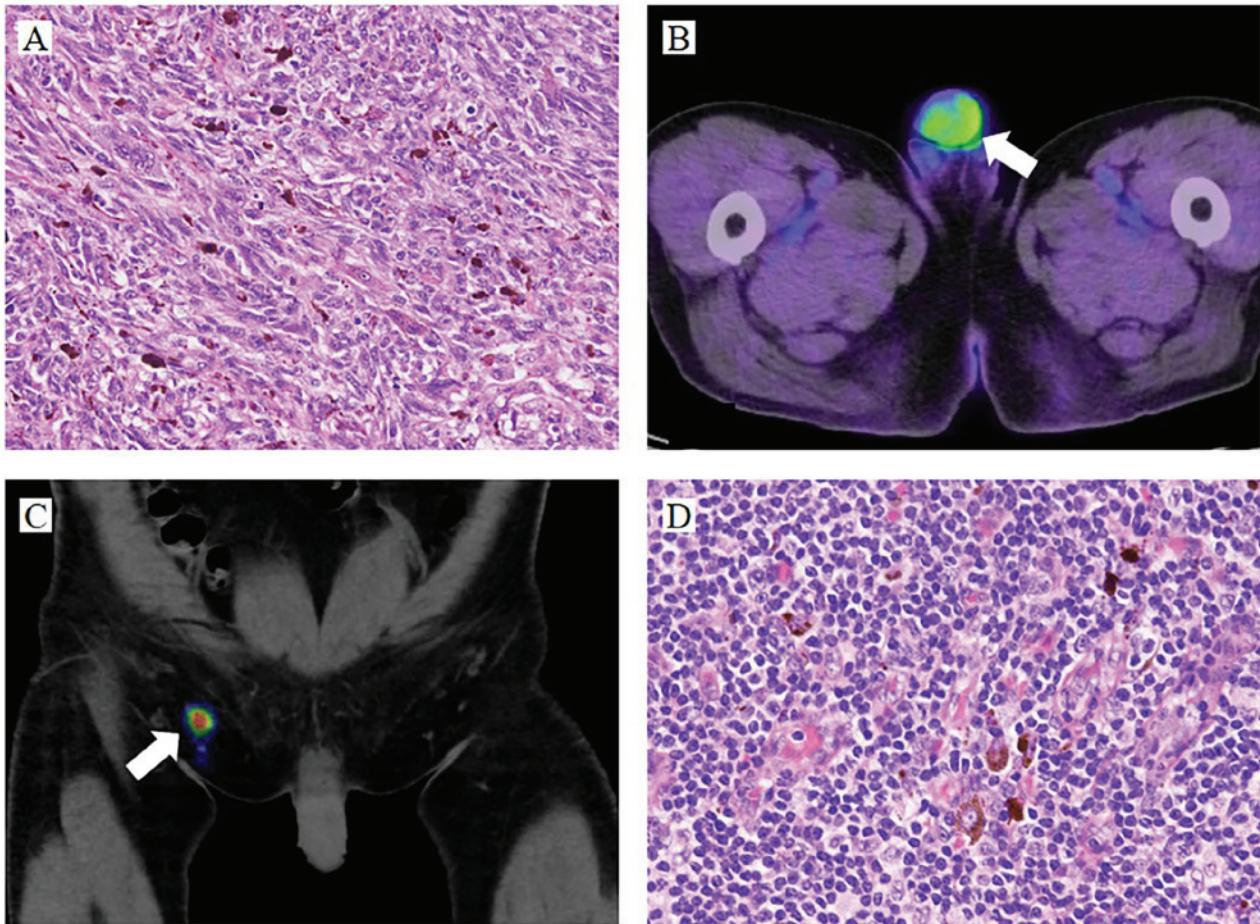


Figure 2. (A) The histological characteristics of the penile lesion included atypical melanocytic cells proliferating in the dermis and invading the basal cells of the epidermis [hematoxylin and (H&E) staining; magnification, x400]. (B) Increased uptake of  $^{18}\text{F}$ -fluorodeoxyglucose (arrow) was detected in the penis (standardized uptake value, 3.23) on computed tomography-positron emission tomography. (C) A right sentinel lymph node was emphasized by scintigraphy with Tc-99m-phytate (arrow). (D) The histological examination of the sentinel lymph node biopsy revealed that the inguinal lymph nodes maintained a normal structure with some melanin pigment (H&E staining; magnification, x400).

rence and prolonged the median disease-free survival (23,24). The Eastern Cooperative Oncology Group trial E1684 demonstrated that an adjuvant high-dose interferon regimen increased the median relapse-free survival (RFS) from 1 to 1.7 years ( $P=0.0023$ ), and the OS from 2.8 to 3.8 years ( $P=0.0237$ ) compared with observation alone (23). Ipilimumab, which is a monoclonal antibody targeting the immune checkpoint receptor CTLA-4, has also been approved for adjuvant treatment of patients with completely resected stage III melanoma, with reported improvement of progression-free survival and OS (25). Adjuvant radiation therapy decreases lymph node field recurrence; however, RFS or OS exhibited no statistically significant differences, whereas grade 2-4 toxicities occurred frequently (26). In our patient, the melanoma was thicker and considered to have a high risk of recurrence; therefore, interferon was attempted as adjuvant chemotherapy.

As late recurrences (>10 years after diagnosis) are well-documented, it is recommended that all melanoma patients undergo skin examinations and surveillance at least once a year for life according to the NCCN guidelines. Among patients with stage IIB-IV melanomas, a comprehensive history and physical examination with specific emphasis on the regional nodes and skin should be undertaken every

3-12 months for 5 years, and annually thereafter, as clinically indicated.

Malignant melanomas of the penis, particularly the penile foreskin, are extremely rare. Early detection and diagnosis are associated with a good prognosis, as early melanoma is curable. Thus, early and appropriate aggressive surgical therapy following effective adjuvant therapy is recommended. In the present case, melanoma was not diagnosed at the initial examination due to the red color. However, physicians should bear in mind that the clinical presentation of malignant melanomas of the penis may vary greatly. The present case may assist physicians reach an accurate diagnosis in future cases of malignant melanoma of the penile foreskin.

#### Acknowledgements

The authors would like to thank the clinical laboratory technicians of Okayama University Hospital for their technical support.

#### Funding

No funding was received.

### Availability of data and materials

Not applicable.

### Authors' contributions

YM wrote the manuscript. TS was a major contributor to writing the manuscript. YM collected imaging data. KW and RT conceived and designed the study. YK performed the surgery. TW performed the patient's examination. MW and YN critically revised the manuscript for intellectual content. The final version of the manuscript has been read and approved by all authors.

### Ethics approval and consent to participate

Not applicable.

### Patient consent for publication

Written informed consent was obtained from the patient for publication of this case report and any accompanying images.

### Competing interests

All the authors declare that they have no competing interests.

### References

1. Stillwell TJ, Zincke H, Gaffey TA and Woods JE: Malignant melanoma of the penis. *J Urol* 140: 72-75, 1988.
2. Brady KL, Mercurio MG and Brown MD: Malignant tumors of the penis. *Dermatol Surg* 39: 527-547, 2013.
3. Tallerman A: Malignant melanoma of the penis. *Urol Int* 27: 66-80, 1972.
4. Rogers RS III and Gibson LE: Mucosal, genital, and unusual clinical variants of melanoma. *Mayo Clin Proc* 72: 362-366, 1997.
5. Hankins CL, Kotwal S, Majumder S, Weston P, Phipps A and Ananthanam AJ: Multifocal melanoma of the glans penis. *Plast Reconstr Surg* 118: 33e-38e, 2006.
6. Jemal A, Saraiya M, Patel P, Cherala SS, Barnholtz-Sloan J, Kim J, Wiggins CL and Wingo PA: Recent trends in cutaneous melanoma incidence and death rates in the United States, 1992-2006. *J Am Acad Dermatol* 65 (5 Suppl 1): S17-S25.e1-3, 2011.
7. van Geel AN, den Bakker MA, Kirkels W, Horenblas S, Kroon BB, de Wilt JH, Eggermont AM, Mooi WJ and van der Aa MN: Prognosis of primary mucosal penile melanoma: A series of 19 Dutch patients and 47 patients from the literature. *Urology* 70: 143-147, 2007.
8. Balch CM, Gershenwald JE, Soong SJ, Thompson JF, Atkins MB, Byrd DR, Buzaid AC, Cochran AJ, Coit DG, Ding S, *et al*: Final version of 2009 AJCC melanoma staging and classification. *J Clin Oncol* 27: 6199-6206, 2009.
9. Siegel RL, Miller KD and Jemal A: Cancer statistics, 2015. *CA Cancer J Clin* 65: 5-29, 2015.
10. Ortega FT, Kondo RN, Belinetti FM, Okamura MO and Tuma B: Primary cutaneous amelanotic melanoma and gastrointestinal stromal tumor in synchronous evolution. *An Bras Dermatol* 92: 707-710, 2017.
11. Kibbi N, Kluger H and Choi JN: Melanoma: Clinical presentations. *Cancer Treat Res* 167: 107-129, 2016.
12. De Giorgi V, Grazzini M, Massi D, Rossari S, Gori A, Janowska A, Bruscinò N and Lotti T: Melanoma of the penis: A clinical dermoscopic case study. *Acta Derm Venereol* 90: 87-88, 2010.
13. Manivel JC and Fraley EE: Malignant melanoma of the penis and male urethra: 4 case reports and literature review. *J Urol* 139: 813-816, 1988.
14. Bracken RB and Diokno AC: Melanoma of the penis and the urethra: 2 case reports and review of the literature. *J Urol* 111: 198-200, 1974.
15. Fenn NJ, Johnson RC, Sharma AK, Attanoos RL and Horgan K: Malignant melanoma of the penis. *Eur J Surg Oncol* 22: 548-549, 1996.
16. Hayes AJ, Maynard L, Coombes G, Newton-Bishop J, Timmons M, Cook M, Theaker J, Bliss JM, Thomas JM; UK Melanoma Study Group, *et al*: Wide versus narrow excision margins for high-risk, primary cutaneous melanomas: Long-term follow-up of survival in a randomised trial. *Lancet Oncol* 17: 184-192, 2016.
17. Thomas JM, Newton-Bishop J, A'Hern R, Coombes G, Timmons M, Evans J, Cook M, Theaker J, Fallowfield M, O'Neill T, *et al*: Excision margins in high-risk malignant melanoma. *N Engl J Med* 350: 757-766, 2004.
18. Cascinelli N, Morabito A, Santinami M, MacKie RM and Belli F: Immediate or delayed dissection of regional nodes in patients with melanoma of the trunk: A randomised trial. WHO melanoma programme. *Lancet* 351: 793-796, 1998.
19. Han D, Zager JS, Shyr Y, Chen H, Berry LD, Iyengar S, Djulbegovic M, Weber JL, Marzban SS, Sondak VK, *et al*: Clinicopathologic predictors of sentinel lymph node metastasis in thin melanoma. *J Clin Oncol* 31: 4387-4393, 2013.
20. Leijte JA, Kroon BK, Valdés Olmos RA, Nieweg OE and Horenblas S: Reliability and safety of current dynamic sentinel node biopsy for penile carcinoma. *Eur Urol* 52: 170-177, 2007.
21. Reintgen D and Saba H: Chemotherapy for stage 4 melanoma: A three-year experience with cisplatin, DTIC, BCNU, and tamoxifen. *Semin Surg Oncol* 9: 251-255, 1993.
22. Li Y, Yuan H, Wang A, Zhang Z, Wu J and Wei Q: Malignant melanoma of the penis and urethra: One case report. *World J Surg Oncol* 12: 340, 2014.
23. Kirkwood JM, Ibrahim JG, Sondak VK, Richards J, Flaherty LE, Ernstoff MS, Smith TJ, Rao U, Steele M and Blum RH: High- and low-dose interferon alfa-2b in high-risk melanoma: First analysis of intergroup trial E1690/S9111/C9190. *J Clin Oncol* 18: 2444-2458, 2000.
24. Kirkwood JM, Ibrahim JG, Sosman JA, Sondak VK, Agarwala SS, Ernstoff MS and Rao U: High-dose interferon alfa-2b significantly prolongs relapse-free and overall survival compared with the GM2-KLH/QS-21 vaccine in patients with resected stage IIB-III melanoma: Results of intergroup trial E1694/S9512/C509801. *J Clin Oncol* 19: 2370-2380, 2001.
25. Eggermont AM, Chiarion-Sileni V, Grob JJ, Dummer R, Wolchok JD, Schmidt H, Hamid O, Robert C, Ascierto PA, Richards JM, *et al*: Adjuvant ipilimumab versus placebo after complete resection of high-risk stage III melanoma (EORTC 18071): A randomised, double-blind, phase 3 trial. *Lancet Oncol* 16: 522-530, 2015.
26. Henderson MA, Burmeister BH, Ainslie J, Fisher R, Di Iulio J, Smithers BM, Hong A, Shannon K, Scolyer RA, Carruthers S, *et al*: Adjuvant lymph-node field radiotherapy versus observation only in patients with melanoma at high risk of further lymph-node field relapse after lymphadenectomy (ANZMTG 01.02/TROG 02.01): 6-year follow-up of a phase 3, randomised controlled trial. *Lancet Oncol* 16: 1049-1060, 2015.