

Assessment of laparoscopic training for gynecological malignancies using Thiel-embalmed human cadavers

TOMOKA USAMI, TORU FUJIOKA, AYAKA YOSHIDA, HITOMI MIYAUE,
TOSHIAKI YASUOKA, YUKA UCHIKURA, KAZUKO TAKAGI, YUKO MATSUBARA,
TAKASHI MATSUMOTO, KEIICHI MATSUBARA and TAKASHI SUGIYAMA

Department of Obstetrics and Gynecology, Ehime University Graduate School of Medicine, Toon, Ehime 791-0295, Japan

Received February 22, 2018; Accepted August 16, 2018

DOI: 10.3892/mco.2018.1715

Abstract. The introduction of laparoscopic surgery has also been beneficial for patients with gynecological malignancies. In this respect, surgeons should receive related training in the context of human resource development. Hands-on training was introduced using Thiel-embalmed human cadavers (THCs) in 2014. To determine the usefulness of THCs, they were evaluated in terms of tissue color, consistency and operative tactility, among others, compared with *in vivo* laparoscopic training for gynecological malignancies. Hands-on training sessions using THCs were held for a total of 11 times at Ehime University Graduate School of Medicine between March 2014 and October 2017. Training on THCs included advanced laparoscopic procedures for radical hysterectomy type III. At the end of each training session, data were collected using a standardized, anonymous questionnaire termed the Likert scale. THCs ensured flexibility and plasticity of tissues and organs; therefore, the working space was similar to that in the living body under pneumoperitoneum. After analyzing the quality and consistency of tissue and organ color compared with *in vivo* conditions, most of the participants agreed or strongly agreed regarding the uterus, adnexa and ureter, but not regarding the large blood vessels. The highest scores were observed in the authenticity of the anatomical condition of each organ. Most participants strongly agreed that training using THCs would help improve their laparoscopic skills with a high level of satisfaction. Furthermore, most participants reported that they would recommend this training to other obstetrician-gynecologists. Laparoscopic training for gynecological malignancies using THCs was comparable to the *in vivo* conditions in terms of surgical view and operative tactility. Therefore, THCs may be an excellent training tool

for improving laparoscopic surgical skills for gynecological malignancies.

Introduction

Since the introduction of laparoscopic surgery in gynecology, there have been significant advances in minimally invasive surgery (MIS), and laparoscopic surgery is becoming the gold standard approach for malignancies as well as benign conditions in gynecology. Laparoscopic surgery for patients with endometrial cancer has been covered by insurance from April 2014 onwards, and laparoscopic radical hysterectomy for patients with cervical cancer was approved as advanced medical treatment in December 2014 in Japan. However, laparoscopic surgery requires special skills, and education of the operator is necessary in the context of human resource development. Moreover, skill-enhancing laparoscopic training programs are urgently needed.

Among the various training tools, dry box training is not suitable for dissection, incision and coagulation with an electric scalpel. In addition, live animals, such as pigs, differ from humans anatomically as they have a bicornuate uterus. Moreover, anesthesiology personnel is required for laparoscopic training using a live anesthetized pig, adding to the total cost of training. Human cadavers have recently been introduced in laparoscopic training (1-7). In particular, the human cadaver appears to be the best anatomic and clinical-like model for surgical procedure training (8), and the validity of laparoscopic training using fresh-frozen cadavers has been previously reported (7). However, fresh-frozen cadavers are very costly, as they must be preserved in a large freezer, and are also associated with the risk of infections.

Thiel *et al* developed a low-odor embalming technique in which the color, consistency and transparency of the tissues are very well preserved. Furthermore, the efficacy of the method for disinfection was confirmed by bacteriological tests (9). Giger *et al* reporting on laparoscopic training on Thiel-embalmed human cadavers (THCs) suggested that this may be an excellent additional model to teach advanced skills for bariatric, hernia and colon surgery (10). In this report, the assessment was focused on the authenticity, consistency and tactility of the THCs through the use of questionnaires.

Correspondence to: Dr Toru Fujioka, Department of Obstetrics and Gynecology, Ehime University Graduate School of Medicine, Shitsukawa, Toon, Ehime 791-0295, Japan
E-mail: fujioka@m.ehime-u.ac.jp

Key words: Thiel human cadaver, laparoscopic training, education, gynecological surgery

Hands-on training using THC's was introduced in our center in December 2012. Studies using cadavers in our center are conducted according to Guidelines for Cadaver Dissection in Education and Research of Clinical Medicine (Japan Surgical Society and Japanese Association of Anatomists) (11). Laparoscopic training for gynecological surgery using THC's was initiated in 2014. To evaluate the usefulness of THC's, we analyzed the authenticity of tissue color, consistency and operative tactility of THC's compared with *in vivo* laparoscopic training for advanced gynecological surgery using a similar method to that previously reported by Giger *et al* (10).

Materials and methods

Hands-on training courses using THC's were held at Ehime University Graduate School of Medicine between March 2014 and October 2017. Obstetricians and gynecologists from Ehime University Hospital and the main district hospital participated in the training. The training on THC's included advanced laparoscopic procedures, such as laparoscopic radical hysterectomy type III, involving the identification of the ureter, and lymphadenectomy, as well as hysterectomy and bilateral salpingo-oophorectomy. One THC was used by two participants, and the set-up time was 6 h.

At the end of the training, data were collected using a standardized, anonymous questionnaire termed Likert scale (1, strongly disagree; 2, disagree; 3, neither agree nor disagree; 4, agree; and 5, strongly agree). The survey items on the questionnaire included color of tissues and organs, consistency, authenticity of anatomical condition, operative tactility compared with *in vivo* surgery, disturbance by odors and overall satisfaction with the training course. Data are provided as mean \pm standard deviation. The training using THC's described above was undertaken with the approval of the Ethics Committee of our institution. Informed consent was also obtained from the participants prior to enrolling.

Results

Hands-on training courses using THC's were held a total of 11 times at Ehime University Graduate School of Medicine between March 2014 and October 2017. The participants from our hospital and five other medical facilities included 17 obstetricians and gynecologists who had been performing laparoscopic surgery with >10 years of expertise and experience as a doctor.

Laparoscopic training comprised hands-on training on laparoscopic radical hysterectomy type III as follows: Identification and isolation of the ureter, opening of the left paravesical space and pelvic lymphadenectomy, dissection of the posterior leaf of the vesicouterine ligament and isolation of the left cardinal ligament, as well as hysterectomy and bilateral salpingo-oophorectomy (Fig. 1).

Assessment of each organ of the THC's. When analyzing the quality of tissue or organ color compared with *in vivo* conditions, agreement or strong agreement was stated by the majority of the participants regarding the uterus (3.8 \pm 0.7), adnexa (3.8 \pm 0.8) and ureter (3.7 \pm 0.7), but not for large blood vessels (2.9 \pm 0.8). Furthermore, equivalent results were obtained

regarding tissue and organ consistency compared with *in vivo* conditions as follows: Uterus (3.9 \pm 1.0), adnexa (4.1 \pm 0.8) and ureter (3.6 \pm 1.0); however, strong agreement was not stated for large blood vessels (2.8 \pm 0.7). The highest scores were observed regarding the authenticity of anatomical condition compared with *in vivo* surgery: Uterus (4.6 \pm 0.6), adnexa (4.6 \pm 0.6), ureter (4.5 \pm 0.6) and large blood vessels (4.2 \pm 0.7). Moreover, when asking whether operative tactility during training was comparable with *in vivo* surgery, equivalent results were obtained for color and consistency: Uterus (4.1 \pm 0.9), adnexa (4.1 \pm 0.8) and ureter (3.6 \pm 0.9); however, there were no strong agreement statements for large blood vessels (2.7 \pm 0.7). The assessment of each organ of the THC's is summarized in Table I.

Assessment of laparoscopic training using THC's. No offensive odors by THC's were reported by any of the participants during training; in addition, there were no disagreement or strong disagreement statements regarding offensive odors (3.9 \pm 0.6). Additionally, the majority of the participants strongly agreed that the training using THC's would help improve their laparoscopic skills (4.8 \pm 0.4) with a high level of satisfaction (4.8 \pm 0.4). Furthermore, most participants also reported that they would recommend this training to other obstetrician-gynecologists (4.7 \pm 0.5). The assessment of laparoscopic training using THC's is summarized in Table II.

Discussion

Since the introduction of laparoscopic surgery, there has been an increasing need for laparoscopic interventions over the last few decades with the advances in surgical practice and medical equipment. Laparoscopic surgery has recently become the gold standard approach for malignancies as well as benign conditions in gynecology. Laparoscopic surgery requires special skills, and laparoscopic training programs to improve technical skills are urgently needed. Moreover, education of the operator is necessary in the context of human resource development. In addition to training tools, such as dry box training and live animals, human cadavers were recently introduced in laparoscopic training (1-7). Due to the anatomy and tissue fidelity, human cadaver models appear to be optimal for surgical procedure training (8), and the validity of laparoscopic training using fresh-frozen cadavers has been previously reported (7).

In particular, Thiel *et al* developed a low-odor embalming technique with which the color, consistency and transparency of the tissue are well-preserved. High standards of preservation were confirmed without releasing harmful substances into the environment. The concentration of formaldehyde in room air remained under the limit of detection. The efficacy for disinfection when using this method has been confirmed with bacteriological tests (9). The tissue quality, elasticity and handling of THC's are satisfactory, and they have been previously used for teaching and urological skills training (12). The efficacy and role of training using THC's were also reported in other departments (12-17). Furthermore, the validity and reliability of THC's have also been reported in transperitoneal laparoscopic nephrectomy training (18), as well as in various advanced laparoscopic training courses for colon, hernia and bariatric surgery (10).

Table I. Assessment of each organ of the THC.

Questions	Uterus (n=17)	Adnexa (n=17)	Ureter (n=17)	Large blood vessels (n=17)
Is the quality of organ color of THC's comparable to <i>in vivo</i> surgery?	3.8±0.7	3.8±0.8	3.7±0.7	2.9±0.8
Is the quality of organ consistency of THC's comparable to <i>in vivo</i> surgery?	3.9±1.0	4.1±0.8	3.6±1.0	2.8±0.7
Is the anatomical condition on THC's authentic to <i>in vivo</i> findings?	4.6±0.6	4.6±0.6	4.5±0.6	4.2±0.7
Is the operative tactility during training on THC's comparable to <i>in vivo</i> surgery?	4.1±0.9	4.1±0.8	3.6±0.9	2.7±0.7

Data are presented as mean ± standard deviation. THC's, Thiel-embalmed human cadavers.

Table II. Assessment of laparoscopic training using THC's (n=17).

Statement	Agreement (Likert scale)
I was not disturbed by odors during training on THC's	3.9±0.6
The training will help me to improve my laparoscopic skills	4.8±0.4
I am very satisfied with the training	4.8±0.4
I will recommend the training to other obstetrician-gynecologists	4.7±0.5

Data are presented as mean ± standard deviation. THC's, Thiel-embalmed human cadavers.

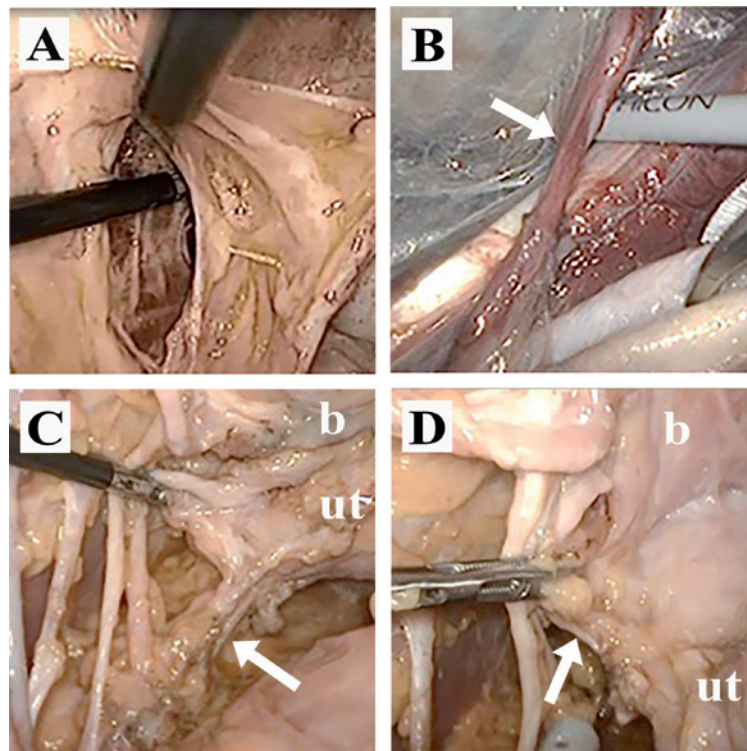


Figure 1. Laparoscopic appearances of Thiel-embalmed human cadavers. (A) Opening of the left paravesical space. (B) Isolation of the right ureter (arrow). (C) Isolation of the left cardinal ligament (arrow). (D) Posterior leaf of the vesicouterine ligament (arrow). ut, uterus; b, bladder.

THC's ensure excellent conditions, with flexibility and plasticity of tissues and organs. Enough working space was

provided, similar to *in vivo* conditions under pneumoperitoneum. The authenticity of organ color was comparable to

in vivo findings in the uterus, adnexa, and ureter, but not in large blood vessels. Similar results were reported for the authenticity of organ consistency and operative tactility. The highest scores were obtained for the authenticity of the anatomical condition of each organ. The high anatomical authenticity of THCs was confirmed as none of the participants stated disagree or strongly disagree. Alternatively, large blood vessels, such as the inferior vena cava and iliac vein, were relaxed and there was no pulse or bleeding following injury. Hence, a lower agreement rate was observed regarding the authenticity of large blood vessels other than the anatomical condition.

None of the participants answered disagree or strongly disagree regarding offensive odors during training. These results support one of the characteristics of THCs, namely that the concentration of formaldehyde in room air remains under the limit of detection. Furthermore, the level of satisfaction with the training using THCs was high; in addition, most participants stated agree or strongly agree that the training using THCs will help improve their laparoscopic skills, and that they would recommend this training to other obstetrician-gynecologists.

However, there remain other issues: First, the number of THCs available for training is limited and uncertain, since all cadavers were personal donations by will to the Anatomy of the Ehime University. Furthermore, the cost per cadaver for embalming and preservation is high (~1,000 USD). Finally, the medical equipment used in laparoscopic surgery must also be rented.

In our experience, training using THCs is an excellent tool enabling advanced laparoscopic training for gynecological malignancies. However, it is necessary to reduce the total cost of this type of training for it to be held periodically and continuously.

In conclusion, laparoscopic training for gynecological malignancies using THCs was comparable to the *in vivo* conditions in terms of surgical view and operative tactility. Therefore, THCs constitute a valuable training tool for improving the laparoscopic surgical skills for gynecological malignancies. However, it is necessary to reduce the total costs of training using THCs to make it sustainable.

References

1. Fernandes CF, Ruano JM, Kati LM, Noguti AS, Girão MJ and Sartori MG: Assessment of laparoscopic skills of gynecology and obstetrics residents after a training program. *Einstein (Sao Paulo)* 14: 468-472, 2016 (In English, Portuguese).
2. Antosh DD, Auguste T, George EA, Sokol AI, Gutman RE, Iglesia CB, Desale SY and Park AJ: Blinded assessment of operative performance after fundamentals of laparoscopic surgery in gynecology training. *J Minim Invasive Gynecol* 20: 353-359, 2013.
3. Botchorishvili R, Rabischong B, Larrain D, Khoo CK, Gaia G, Jardon K, Pouly JL, Jaffeux P, Aublet-Cuvelier B, Canis M and Mage G: Educational value of an intensive and structured interval practice laparoscopic training course for residents in obstetrics and gynecology: A four-year prospective, multi-institutional recruitment study. *J Surg Educ* 69: 173-179, 2012.
4. Urwitz-Lane RS, Lee RH, Peyre S, Rahman S, Kwok L and Muderspach L: Impact of laparoscopic experience on performance on laparoscopic training drills among obstetrics and gynecology residents: A pilot study. *J Minim Invasive Gynecol* 16: 72-75, 2009.
5. Kirby TO, Numnum TM, Kilgore LC and Straughn JM: A prospective evaluation of a simulator-based laparoscopic training program for gynecology residents. *J Am Coll Surg* 206: 343-348, 2008.
6. Kirwan WO, Kaar TK and Waldron R: Starting laparoscopic cholecystectomy-the pig as a training model. *Ir J Med Sci* 160: 243-246, 1991.
7. Sharma M and Horgan A: Comparison of fresh-frozen cadaver and high-fidelity virtual reality simulator as methods of laparoscopic training. *World J Surg* 36: 1732-1737, 2012.
8. Lam F, Jankova L, Dent OF, Molloy MP, Kwun SY, Clarke C, Chapuis P, Robertson G, Beale P, Clarke S, *et al*: Identification of distinctive protein expression patterns in colorectal adenoma. *Proteomics Clin Appl* 4: 60-70, 2010.
9. Thiel W: The preservation of the whole corpse with natural color. *Ann Anat* 174: 185-195, 1992 (In German).
10. Giger U, Frésard I, Häfliger A, Bergmann M and Krähenbühl L: Laparoscopic training on Thiel human cadavers: A model to teach advanced laparoscopic procedures. *Surg Endosc* 22: 901-906, 2008.
11. Japan Surgical Society and Japanese Association of Anatomists: Guidelines for cadaver dissection in education and research of clinical medicine. *Kaibogaku Zasshi* 87: 21-23, 2012 (In Japanese).
12. Healy SE, Rai BP, Biyani CS, Eisma R, Soames RW and Nabi G: Thiel embalming method for cadaver preservation: A review of new training model for urologic skills training. *Urology* 85: 499-504, 2015.
13. Charbonney E, Delisle S, Savary D, Bronchti G, Rigollet M, Drouet A, Badat B, Ouellet P, Gosselin P, Mercat A, *et al*: A new physiological model for studying the effect of chest compression and ventilation during cardiopulmonary resuscitation: The Thiel cadaver. *Resuscitation* 125: 135-142, 2018.
14. Munirama S, Zealley K, Schwab A, Columb M, Corner GA, Eisma R and McLeod GA: Trainee anaesthetist diagnosis of intraneural injection-a study comparing B-mode ultrasound with the fusion of B-mode and elastography in the soft embalmed Thiel cadaver model. *Br J Anaesth* 117: 792-800, 2016.
15. Maruyama D, Chaki T, Omote M, Hirata N, Yamauchi M and Yamakage M: Movements of the double-lumen endotracheal tube due to lateral position with head rotation and tube fixation: A Thiel-embalmed cadaver study. *Surg Radiol Anat* 37: 841-844, 2015.
16. Munirama S, Satapathy AR, Schwab A, Eisma R, Corner GA, Cochran S, Soames R and McLeod GA: Translation of sono-elastography from Thiel cadaver to patients for peripheral nerve blocks. *Anaesthesia* 67: 721-728, 2012.
17. Albery J, Filler TJ, Schmal F and Peuker ET: Thiel method fixed cadaver ears. A new procedure for graduate and continuing education in middle ear surgery. *HNO* 50: 739-742, 2002 (In German).
18. Rai BP, Stolzenburg JU, Healy S, Tang B, Jones P, Sweeney C, Somani BK, Biyani CS and Nabi G: Preliminary validation of Thiel embalmed cadavers for laparoscopic radical nephrectomy. *J Endourol* 29: 595-603, 2015.