

Teriparatide may accelerate the growth of a pre-existing malignant tumor in an elderly patient with osteoporosis: A case report

TETSUYA OGAWA¹, SHUSA OHSHIKA¹, MICHIRO YANAGISAWA¹,
AKIRA KUROSE² and YASUYUKI ISHIBASHI¹

Departments of ¹Orthopedic Surgery and ²Anatomic Pathology,
Hirosaki University Graduate School of Medicine, Hirosaki, Aomori 036-8562, Japan

Received March 2, 2019; Accepted November 28, 2019

DOI: 10.3892/mco.2019.1966

Abstract. The present report describes a case in which teriparatide, which is widely used to treat osteoporosis, may have accelerated the growth of an undiagnosed pre-existing bone tumor of the femur. A 76-year-old woman visited hospital with pain in the right thigh after falling from a ladder. A non-pathological femoral shaft fracture was diagnosed by plain radiography. There were no findings of pathological fracture on the examination. In addition, the patient underwent intramedullary femoral nail fixation and started teriparatide treatment for osteoporosis. The teriparatide was discontinued after 2 months due to nausea. A total of 6 months after surgery, the woman visited Hirosaki University Hospital with abnormal swelling of the right thigh. Following a diagnosis of high-grade malignant mesenchymal bone tumor by needle biopsy, the patient underwent right hip disarticulation. Pathological examination provided a definitive diagnosis of osteoblastic osteosarcoma. The present case is a reminder that teriparatide may accelerate the growth of a pre-existing malignant tumor and that fractures, particularly in elderly patients, should be screened for pathological fracture prior to administering teriparatide.

Introduction

The number of people with osteoporosis has increased as the population ages. Osteoporosis is often treated with teriparatide (1), which has been demonstrated to promote bone healing and prevent fragility fractures in both rats and humans (2-9). Along with its numerous clinical advantages, teriparatide has

some less well-known contraindications, such as a history of radiation therapy (10), the presence of primary malignant and metastatic bone tumors (11), and Paget's disease (12), all conditions under which teriparatide may induce osteosarcoma.

Initial preclinical studies in rats revealed that teriparatide increases the risk of osteosarcoma development. Vahle *et al* reported that rats given daily injections of recombinant human parathyroid hormone develop proliferative bone lesions, and some rats develop osteosarcoma (13). Watanabe *et al* reported that teriparatide can induce osteosarcoma in rats, depending on the dose and duration of treatment (14). Vahle *et al* reported a safe teriparatide dose for rats in 2004 (15). Two cases of osteosarcoma following the administration of teriparatide have been reported in the USA. However, in one case, the causality between teriparatide and the osteosarcoma could not be established (10). In addition, in the other case the patient was treated with radiation therapy before teriparatide administration; therefore, it is unclear whether the teriparatide administration or radiation therapy were associated with osteosarcoma onset (11). In the present case, the patient had never received any radiation therapy and there was no history of Paget's disease. To date, there are no reported cases of definite teriparatide-induced osteosarcoma in humans in the USA (12,16) or Japan (17), to the best of our knowledge.

The present study presents the case of an elderly patient with severe osteoporosis in which teriparatide may have accelerated the growth of a pre-existing malignant tumor. This case serves as a caveat against the misdiagnosis of a pathological fracture as a normal fracture in elderly patients, particularly before teriparatide administration. Therefore, care should be taken to diagnose femoral fractures in elderly patients.

Case report

A 76-year-old Japanese woman was doing farm work on a ladder and fell 50 cm to the ground. The patient felt pain in her right thigh and was unable to stand. She then visited National Hospital Organization Hirosaki Hospital (Hirosaki, Japan) in September, 2016 and was diagnosed with a right femoral-shaft fracture (Fig. 1). The patient had no history of illness and had never undergone radiotherapy in the past. The laboratory data,

Correspondence to: Dr Shusa Ohshika, Department of Orthopedic Surgery, Hirosaki University Graduate School of Medicine, 5 Zaifu-cho, Hirosaki, Aomori 036-8562, Japan
E-mail: ohshika@hirosaki-u.ac.jp

Key words: bone, femoral fracture, osteoporosis, osteosarcoma, parathyroid hormone, pathological fracture, teriparatide

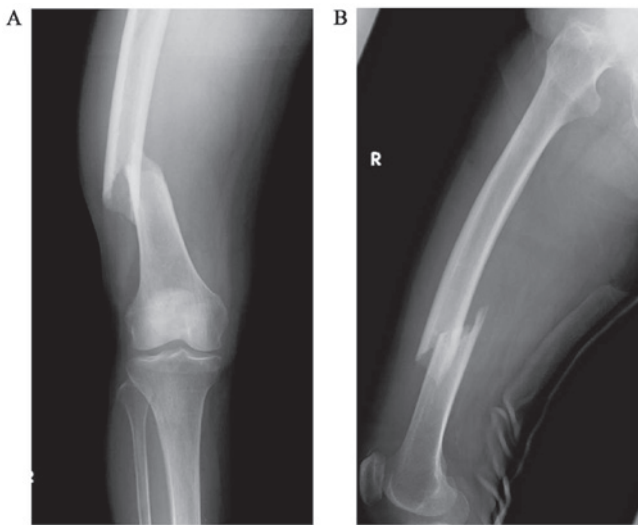


Figure 1. Preoperative radiographs. The patient visited a local hospital after a fall. Plain radiographs revealed a right femoral diaphyseal fracture at the time of initial presentation. The fracture site appeared rough, but there were no abnormal findings around the fracture site, such as periosteal reactions, osteolytic changes or osteoblastic changes. (A) Front view. (B) Side view.

including C-reactive protein (CRP), alkaline phosphatase (ALP) and lactate dehydrogenase (LDH) levels, were within normal range, and the fracture was treated immediately by intramedullary nail fixation (Fig. 2). A postoperative bone density test identified severe osteoporosis. The patient was treated with a daily regimen of teriparatide (20 $\mu\text{g}/\text{day}$); however, the drug was discontinued after 2 months due to the onset of nausea. A total of 6 months after the initial surgery, the patient visited Hirosaki University Hospital on April, 2017 with abnormal swelling of the right thigh. At presentation, the right thigh had a circumference approximately twice as large as that of the left thigh, and the right knee had a limited range of motion. Blood tests revealed that the CRP, ALP and LDH levels were slightly elevated, but all tumor markers, including AFP, CA125, CA19-9, CEA and SCC were negative. Plain radiography demonstrated incomplete bone union of the right femoral diaphysis and a periosteal reaction with a sunburst-like appearance around the fracture (Fig. 3). Magnetic resonance imaging (MRI) revealed a soft tissue mass around the femur, with a low-intensity to iso-intense signal on T1-weighted images and a mixed low to high signal intensity on STIR images (Fig. 4). The soft tissue mass also exhibited diffuse and heterogeneous contrast enhancement. Another mass with similar characteristics was identified in the gluteus medius muscle, in a region that would lie along the pathway of the intramedullary nail insertion. No significant accumulation was observed on a whole-body bone scintigraph, except for the right femoral and right gluteus medius muscle regions (Fig. 5). A high-grade malignant mesenchymal bone tumor was diagnosed by needle biopsy. The patient underwent right hip disarticulation with resection of the gluteus medius muscle. The cells were rich in polymorphisms, and strong heteromorphic tumor cells forming osteoids were observed (Fig. 6). The definitive pathological diagnosis was an osteoblastic osteosarcoma of the right femur. Adjuvant chemotherapy was not performed due to the patient's advanced age. The patient provided informed consent.

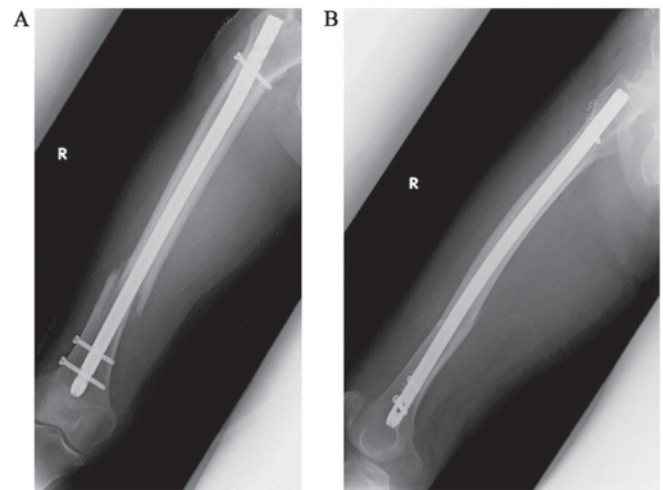


Figure 2. Postoperative radiographs. Plain radiographs of the right femur following the initial surgery. (A) Front view. (B) Side view.

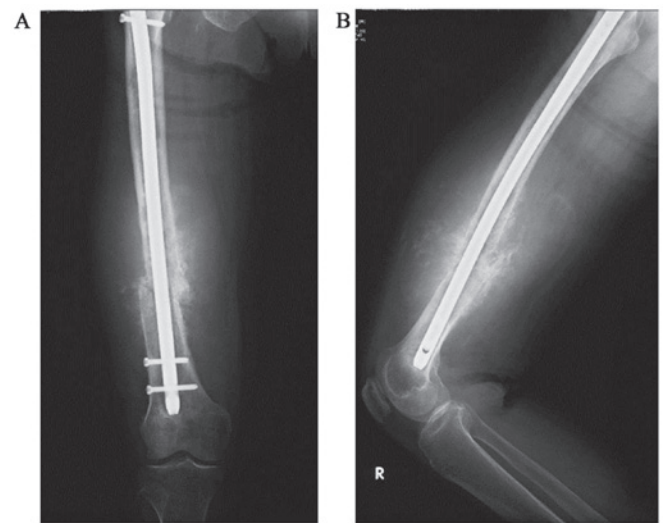


Figure 3. Radiographs obtained 6 months after the original surgery. A total of 6 months after the initial fracture, the patient visited Hirosaki University Hospital (Hirosaki, Japan) with abnormal swelling of the right thigh and limited range of motion in the right knee. Plain radiographs revealed incomplete bone union of the right femoral diaphyseal fracture, and a periosteal reaction with a sunburst-like appearance around the fracture. (A) Front view. (B) Side view.

Discussion

The present case provides an important reminder that teriparatide may accelerate the growth of a pre-existing malignant tumor in an elderly patient. A previous study demonstrated that teriparatide increases the risk of osteosarcoma in rats, according to the dose and duration of administration (15). In the USA, two patients with osteosarcoma after teriparatide administration have been reported (10,11). In addition, other case reports have described four patients with primary hyperparathyroidism in whom chronically elevated parathyroid hormone levels induced osteosarcoma (18-20). The period of teriparatide administration was only 2 months, which is a limitation of this case as the recommended administration of teriparatide in osteoporosis is up to 24 months (16). The short

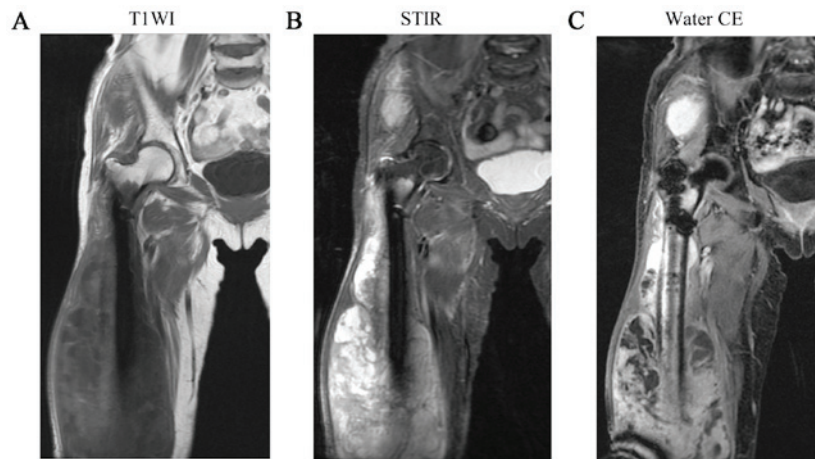


Figure 4. Coronal MRI. MRI demonstrated (A) a low-intensity to iso-intense signal on T1WI images, and (B) a mixed low to high signal intensity on STIR images. (C) Coronal MRI on water selective excitation post-contrast images revealed a mixed low to high signal intensity. Another mass with similar characteristics was found in the right gluteus medius muscle region. MRI, magnetic resonance imaging; T1WI, T1-weighted; STIR, short-T1 inversion recovery; CE, contrast-enhanced.

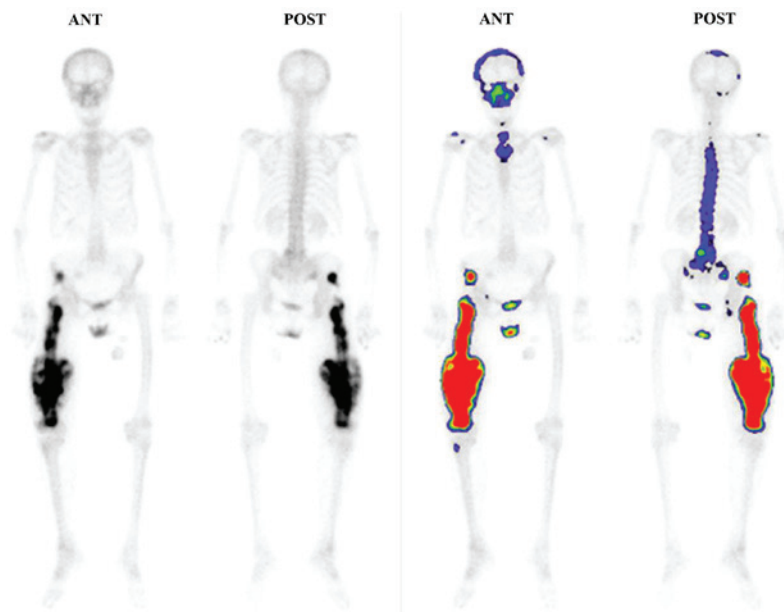


Figure 5. Bone scintigraphy examination. Bone scintigraphy examination revealed tumors in the right thigh and the right gluteus medius muscle. ANT, anterior; POST, posterior.

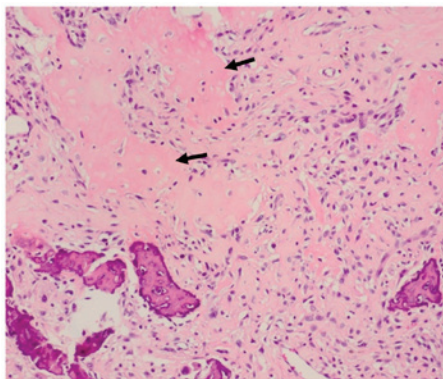


Figure 6. Histological findings. Hematoxylin/eosin-stained surgical specimen of the right thigh tumor (magnification, x20). The cells were rich in polymorphisms, and strong heteromorphic tumor cells forming osteoids (arrows) were observed. The definitive diagnosis was osteoblastic osteosarcoma.

administration period makes it unlikely that the osteosarcoma arose from a non-pathological fracture. Although the initial radiographs did not reveal any malignant bone lesions in the present case, there may have been a diffuse permeating malignant lesion; it is likely that that would have accelerated the growth of a pre-existing malignant tumor.

The present case study also emphasizes the importance of diagnosing femoral fractures in the elderly, due to the possibility of pathological fractures from malignant disease. Epidemiologically, diaphyseal femoral fractures are not as common as proximal femoral fractures (21,22). In the present case, a pathological fracture should have been considered because the fracture resulted from a fall from a relatively low height, and because the patient mentioned that they had experienced pain in the right thigh 1 week before the injury. These atypical clinical elements suggest that the femoral

diaphyseal fracture was a pathological fracture. However, at the initial presentation, the plain radiographs did not reveal any periosteal reaction, osteolytic or osteoblastic change around the fracture site, or other abnormalities that may have made it easier to recognize a pathological fracture. As elderly individuals have a high risk of malignant disease, atypical clinical elements should prompt the clinician to consider the possibility of a pathological fracture. In such cases, clinicians should not hesitate to perform CT scans and/or an MRI.

Acknowledgements

Not applicable.

Funding

No funding was received.

Availability of data and materials

The datasets used and analyzed during the current study are available from the corresponding author on reasonable request.

Authors' contributions

TO, SO, MY, YI participated in the treatment of the patient. AK performed the pathological diagnosis. All the authors have read and approved the final version of this manuscript.

Ethics approval and consent to participate

Not applicable.

Patient consent for publication

The patient provided written informed consent for publication.

Competing interests

The authors declare that they have no competing interests.

References

- Soen S, Fujiwara S, Takayanagi R, Kajimoto K, Tsujimoto M, Kimura S, Sato M, Kregge JH and Enomoto H: Real-world effectiveness of daily teriparatide in Japanese patients with osteoporosis at high risk for fracture: Final results from the 24-month Japan Fracture Observational Study (JFOS). *Curr Med Res Opin* 33: 2049-2056, 2017.
- Alkhiary YM, Gerstenfeld LC, Krall E, Westmore M, Sato M, Mitlak BH and Einhorn TA: Enhancement of experimental fracture-healing by systemic administration of recombinant human parathyroid hormone (PTH 1-34). *J Bone Joint Surg Am* 87: 731-741, 2005.
- Aspenberg P and Johansson T: Teriparatide improves early callus formation in distal radial fractures. *Acta Orthop* 81: 234-236, 2010.
- Della Rocca GJ, Crist BD and Murtha YM: Parathyroid hormone: Is there a role in fracture healing? *J Orthop Trauma* 24 (Suppl 1): S31-S35, 2010.
- Hodsman AB, Bauer DC, Dempster DW, Dian L, Hanley DA, Harris ST, Kendler DL, McClung MR, Miller PD, Olszynski WP, *et al*: Parathyroid hormone and teriparatide for the treatment of osteoporosis: A review of the evidence and suggested guidelines for its use. *Endocr Rev* 26: 688-703, 2005.
- Im GI and Lee SH: Effect of teriparatide on healing of atypical femoral fractures: A systemic review. *J Bone Metab* 22: 183-189, 2015.
- Neer RM, Arnaud CD, Zanchetta JR, Prince R, Gaich GA, Reginster JY, Hodsman AB, Eriksen EF, Ish-Shalom S, Genant HK, *et al*: Effect of parathyroid hormone (1-34) on fractures and bone mineral density in postmenopausal women with osteoporosis. *N Engl J Med* 344: 1434-1441, 2001.
- Puzas JE, Houck J and Bukata SV: Accelerated fracture healing. *J Am Acad Orthop Surg* 14: S145-S151, 2006.
- Rowshan HH, Parham MA, Baur DA, McEntee RD, Cauley E, Carriere DT, Wood JC, Demsar WJ and Pizarro JM: Effect of intermittent systemic administration of recombinant parathyroid hormone (1-34) on mandibular fracture healing in rats. *J Oral Maxillofac Surg* 68: 260-267, 2010.
- Subbiah V, Madsen VS, Raymond AK, Benjamin RS and Ludwig JA: Of mice and men: Divergent risks of teriparatide-induced osteosarcoma. *Osteoporos Int* 21: 1041-1045, 2010.
- Harper KD, Kregge JH, Marcus R and Mitlak BH: Osteosarcoma and teriparatide? *J Bone Miner Res* 22: 334, 2007.
- Andrews EB, Gilsenan AW, Midkiff K, Sherrill B, Wu Y, Mann BH and Masica D: The US postmarketing surveillance study of adult osteosarcoma and teriparatide: Study design and findings from the first 7 years. *J Bone Miner Res* 27: 2429-2437, 2012.
- Vahle JL, Sato M, Long GG, Young JK, Francis PC, Engelhardt JA, Westmore MS, Linda Y and Nold JB: Skeletal changes in rats given daily subcutaneous injections of recombinant human parathyroid hormone (1-34) for 2 years and relevance to human safety. *Toxicol Pathol* 30: 312-321, 2002.
- Watanabe A, Yoneyama S, Nakajima M, Sato N, Takao-Kawabata R, Isogai Y, Sakurai-Tanikawa A, Higuchi K, Shimoi A, Yamatoya H, *et al*: Osteosarcoma in Sprague-Dawley rats after long-term treatment with teriparatide [human parathyroid hormone (1-34)]. *J Toxicol Sci* 37: 617-629, 2012.
- Vahle JL, Long GG, Sandusky G, Westmore M, Ma YL and Sato M: Bone neoplasms in F344 rats given teriparatide [rhPTH(1-34)] are dependent on duration of treatment and dose. *Toxicol Pathol* 32: 426-438, 2004.
- Gilsenan A, Harding A, Kellier-Steele N, Harris D, Midkiff K and Andrews E: The Forteo Patient Registry linkage to multiple state cancer registries: Study design and results from the first 8 years. *Osteoporos Int* 29: 2335-2343, 2018.
- Nishikawa A, Ishida T, Taketsuna M, Yoshiki F and Enomoto H: Safety and effectiveness of daily teriparatide in a prospective observational study in patients with osteoporosis at high risk of fracture in Japan: Final report. *Clin Interv Aging* 11: 913-925, 2016.
- Smith J, Huvos AG, Chapman M, Rabbs C and Spiro RH: Hyperparathyroidism associated with sarcoma of bone. *Skeletal Radiol* 26: 107-112, 1997.
- Betancourt M, Wirfel KL, Raymond AK, Yasko AW, Lee J and Vassilopoulou-Sellin R: Osteosarcoma of bone in apatient with primary hyperparathyroidism: A case report. *J Bone Miner Res* 18: 163-166, 2003.
- Jutte PC, Rosso R, de Paolis M, Errani C, Pasini E, Campanacci L, Bacci G, Bertoni F and Mercuri M: Osteosarcoma associated with hyperparathyroidism. *Skeletal Radiol* 33: 473-476, 2004.
- Court-Brown CM and Caesar B: Epidemiology of adult fractures: A review. *Injury* 37: 691-697, 2006.
- Thorngren KG, Hommel A, Norrman PO, Thorngren J and Wingstrand H: Epidemiology of femoral neck fractures. *Injury* 33 (Suppl 3): C1-C7, 2002.



This work is licensed under a Creative Commons Attribution-NonCommercial-NoDerivatives 4.0 International (CC BY-NC-ND 4.0) License.