

5-ALA vs. fluorescein guided resection for high-grade gliomas: A systematic review and meta-analysis

EVANGELOS KOGIAS¹, GEORGE FOTAKOPOULOS¹, VASILIKI EPAMEINONDAS GEORGAKOPOULOU²,
IRAKLIS KAGKOURAS³, DEMETRIOS A. SPANDIDOS⁴, NIKOLAOS TRAKAS⁵ and NIKOLAOS FOROGLOU¹

¹Department of Neurosurgery, AHEPA University Hospital, Aristotle University of Thessaloniki, 54636 Thessaloniki, Greece; ²Department of Pathophysiology, Laiko General Hospital, National and Kapodistrian University of Athens, 11527 Athens, Greece; ³Department of Surgery, Worcestershire Acute Hospital, WR51DD, Worcester, United Kingdom; ⁴Laboratory of Clinical Virology, School of Medicine, University of Crete, 71003 Heraklion, Greece; ⁵Department of Biochemistry, Sismanogleio Hospital, 15126 Athens, Greece

Received August 26, 2025; Accepted January 14, 2026

DOI: 10.3892/mco.2026.2927

Abstract. High-grade gliomas (HGGs) are characterized by aggressive biological behavior and dismal prognosis. Both 5-aminolevulinic acid (5-ALA) and other fluorescence-guided surgery (FGS) techniques are used to maximize tumor resection while preserving neurological function. The present study synthesizes current evidence and compares these two approaches in the neurosurgical management of HGGs. A systematic literature search was conducted to identify clinical studies evaluating 5-ALA-guided resection and alternative FGS techniques in patients with HGGs. A total of 41 studies were included, comprising 36 in the qualitative review and 5 in the quantitative meta-analysis. Data were extracted regarding study characteristics, patient demographics, tumor type, median progression-free survival, overall survival (OS), pre- and postoperative Karnofsky Performance Status (KPS ≥ 70 within 30 days), and postoperative neurological deficits (defined as a newly developed decrease in Glasgow Coma Scale score of ≥ 2 points, hemiparesis, or aphasia). The pooled population consisted of 732 patients, with 503 (68.7%) undergoing 5-ALA-guided resection and 229 (31.3%) treated with FGS. The mean patient age across studies was 57.9 years. The present meta-analysis demonstrated that 5-ALA-guided surgery was associated with improved outcomes in terms of postoperative neurological deficits, maintenance of KPS ≥ 70 , and OS compared with other FGS techniques. However, the presence of publication bias and the heterogeneity of the underlying data limit the strength of these findings and underscores the need for further high-quality comparative

trials before definitive conclusions can be drawn regarding the superiority of one method over the other.

Introduction

High-grade gliomas (HGGs), encompassing WHO grade III-IV malignant brain tumors, are characterized by aggressive growth and poor prognosis, with a median survival of ~12-15 months despite multimodal therapy (1). The current standard of care involves maximal safe surgical resection followed by radiotherapy and chemotherapy. The extent of resection (EOR) is a critical prognostic factor, as more complete tumor removal is consistently associated with longer overall survival (OS) and progression-free survival (PFS) in patients with HGGs (1,2).

Achieving gross total resection (GTR) under conventional white-light microscopy remains challenging due to the highly infiltrative nature of gliomas and the difficulty in distinguishing tumor tissue from normal brain parenchyma at the resection margins. To address this limitation, fluorescence-guided surgery (FGS) has emerged as an important adjunct, enhancing intraoperative visualization of tumor tissue and thereby improving the likelihood of achieving maximal resection (3-5).

Two fluorescent agents are most widely used in HGG surgery: 5-aminolevulinic acid (5-ALA) and sodium fluorescein (SF). 5-ALA is a prodrug metabolized within tumor cells to protoporphyrin IX (PpIX), a fluorescent molecule that selectively accumulates in malignant glioma cells and emits a characteristic red-violet fluorescence under blue-light excitation (1,6,7). Oral administration of 5-ALA (20 mg/kg) 3-4 h prior to surgery has been approved for malignant glioma resection in adults, following a pivotal randomized trial that demonstrated significantly higher GTR rates with 5-ALA guidance compared with white-light resection (1,8).

By contrast, SF is an intravenous fluorescent dye that extravasates through areas of blood-brain barrier (BBB) disruption. When activated by 460-500 nm blue light and observed through a 540-690 nm yellow filter, fluorescein highlights tumor tissue as green-yellow fluorescence within the surgical field (1). Although SF has been used sporadically in neurosurgery for decades, its adoption has increased

Correspondence to: Professor George Fotakopoulos, Department of Neurosurgery, AHEPA University Hospital, Aristotle University of Thessaloniki, 1 Kyriakidi Street, 54636 Thessaloniki, Greece
E-mail: gfortakop@yahoo.gr

Key words: 5-ALA, high-grade gliomas, fluorescein-guided resection, 5-ALA vs. fluorescein, fluorescence-guided surgery

markedly in recent years due to the development of dedicated microscope filters (for example, YELLOW-560 filter) and its favorable safety profile at low doses (3-5 mg/kg) (1). Unlike 5-ALA, SF is not tumor-cell specific, as it marks all areas of BBB breakdown. However, it offers practical advantages, including bigger range of indications and more practical administration (1).

Both 5-ALA and SF aim to maximize tumor removal while minimizing neurological morbidity. Importantly, 5-ALA is supported by Level I evidence and regulatory approval, whereas SF remains an off-label but increasingly popular alternative with an increasing body of supportive clinical data (1).

The present systematic review compares 5-ALA and SF in HGG surgery, evaluating their relative effectiveness in maximizing resection, impact on patient outcomes, safety profiles, cost considerations, and practical advantages or limitations. In addition, the present meta-analysis directly compares the clinical outcomes associated with these two modalities, providing an updated and comprehensive synthesis of current evidence to inform neurosurgical practice.

Materials and methods

For the present meta-analysis and literature review, a systematic literature search was performed to identify clinical studies evaluating 5-ALA-guided resection and fluorescein-guided surgery (FGS) in HGGs (9). The search strategy and study selection process is detailed in the PRISMA flow diagram and protocol. Two investigators (GF, a neurosurgeon and GC, a gastric cancer surgeon) individually extracted information from the enclosed articles using the epidemiology principles of meta-analysis. The search strategy retrieved 501 titles and abstracts [PubMed (<https://pubmed.ncbi.nlm.nih.gov/>) :305; Embase (<https://www.embase.com>) :146; Cochrane Library (<https://www.cochranelibrary.com/>) :24; Scopus (<https://www.scopus.com/>) :26]. Eligible studies included randomized controlled trials (RCTs), prospective observational studies, retrospective cohorts, and relevant meta-analyses. Both comparative and single-arm studies were considered, provided they reported outcomes in adult patients with HGGs (primarily glioblastomas and anaplastic gliomas) undergoing resection with either 5-ALA or fluorescein guidance.

The search strategy used the following key words: '5-ALA AND HGGs', '5-ALA AND Fluorescein Guided Resection', 'Fluorescein Guided Resection AND HGGs', and '5-ALA AND Fluorescein Guided Resection AND HGGs'. The final search was conducted on June 18, 2025. Only full-text articles in English were included. Non-English language papers and studies focusing on low-grade gliomas were excluded. In addition, articles with unclear/confusing results or articles with less than 3 included cases, were excluded. To minimize publication bias, the final aim was to collect a homogeneous pool of manuscripts and thus studies were included only if they compared outcomes between the two modalities or provided sufficient outcome data for analysis. Articles focused solely on technical aspects or novel imaging adjuncts were considered for contextual discussion if they contained data on resection rates or clinical outcomes.

A total of 41 articles met the eligibility criteria: 36 studies were included in the qualitative review (1-36), and 5

comparative studies were included in the quantitative synthesis (meta-analysis) (37-41) (Fig. 1). Eligible studies reported at least one of the following outcomes: EOR, GTR rate, survival outcomes (PFS and OS), adverse events, or measures of fluorescence effectiveness (for example, sensitivity/specificity of tumor visualization, cost-effectiveness analyses).

Data were systematically extracted from each study, including: First author, year of publication, total sample size, patient demographics (age, sex), tumor type, median PFS, OS, pre- and postoperative Karnofsky Performance Status (KPS ≥ 70 within 30 days of surgery), and postoperative neurological deficits. Neurological deficits were defined as newly developed impairments such as a ≥ 2 -point reduction in the Glasgow Coma Scale (GCS), hemiparesis, or aphasia (Table SI).

Risk of bias was assessed using the Cochrane Collaboration tool for randomized studies (42) and the Newcastle-Ottawa Scale (NOS) for non-randomized studies (43) (Table I). Statistical analyses were conducted using Review Manager (RevMan 5.3, Nordic Cochrane Centre, Cochrane Collaboration, Copenhagen, Denmark). Odds ratios (ORs) with 95% confidence intervals (CIs) were calculated for dichotomous outcomes. An OR < 1 indicated a favorable outcome for the 5-ALA group. Statistically significant threshold was set at $P < 0.05$. Heterogeneity among studies was assessed using the Chi-square test and quantified with the I^2 statistic, with $P < 0.05$ or $I^2 > 50\%$ indicating significant heterogeneity. Random-effects models were applied in the presence of significant heterogeneity, while fixed-effects models were used otherwise.

Results

The final set comprised 36 studies. These included two phase III RCTs evaluating 5-ALA-guided resection versus conventional microsurgery (1,11); One multicenter randomized trial of FGS versus placebo (dark-light) control (12); several prospective single-arm studies of fluorescence guidance, including a Phase II trial of fluorescein in glioblastoma (12) and multiple Phase I-II studies of 5-ALA in various clinical contexts (10,13-15); a number of retrospective comparative series (16,28,29,37,39); one case-control study (14); as well as systematic reviews (11,15,17,18,26,27) and meta-analyses (11) focused on intraoperative imaging modalities.

The evidence base for 5-ALA is supported by large-scale trials, notably the pivotal study by Stummer *et al* (19), the recent French RESECT trial (11), and multicenter long-term experiences (11,12). By contrast, the evidence for fluorescein is more limited, primarily deriving from smaller RCTs (12), institutional series, and more recent comparative analyses. Additionally, studies investigating these agents in combination with other intraoperative technologies (for example, MRI, ultrasound) or in other tumor types (such as brain metastases and pediatric tumors) were included to provide contextual insights into their broader clinical applicability (1). The characteristics of all included studies are summarized in Table SI.

5-ALA studies. The pivotal RCTs by Stummer *et al* (19) and Picart *et al* (11) established the efficacy of 5-ALA in improving resection rates in newly diagnosed glioblastomas (1). Numerous retrospective multicenter cohorts and single-institution series

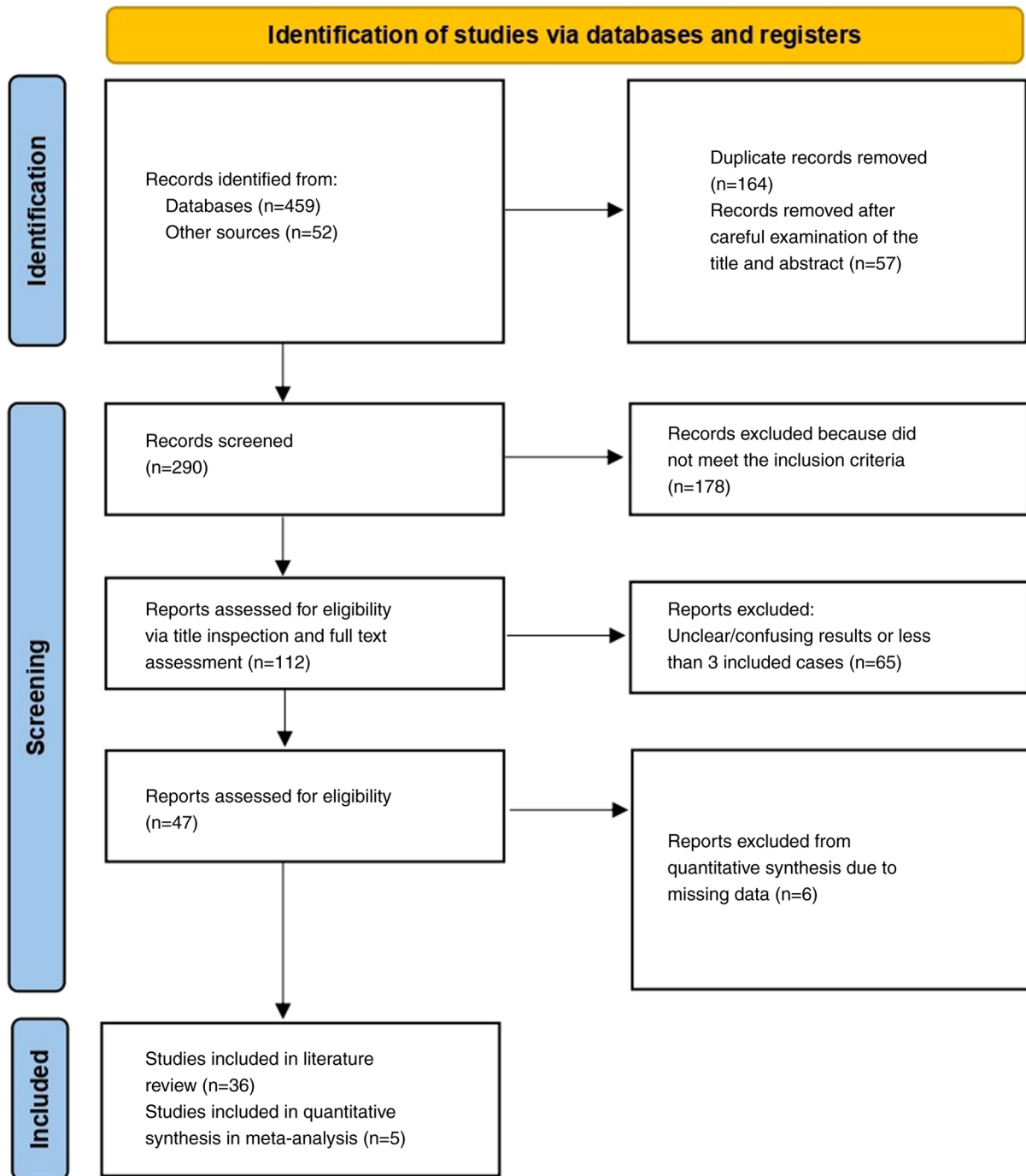


Figure 1. Flowchart of the study selection process.

further demonstrated that 5-ALA guidance significantly increases the likelihood of GTR without compromising patient safety (1). Several additional investigations explored correlations between intraoperative 5-ALA fluorescence, tumor pathology, and patient outcomes, reinforcing its role as a reliable intraoperative tool (11).

Fluorescein (SF) studies. Early evidence of fluorescein's utility was provided by small institutional series and a pilot double-blind trial (12), which demonstrated improved resection rates when using a dedicated yellow filter. A subsequent multicenter Phase II trial [‘FLUOGLIO’, Acerbi *et al.*, (12)]

in 2014 reported complete resection rates of 82-83% in glioblastoma surgery. More recently, a large retrospective controlled study of 347 patients compared fluorescein-guided surgery with white-light resection, showing superior EOR and improved survival in the fluorescein group (13). Consistent findings across multiple single-center series, several synthesized in a 2021 meta-analysis, further confirmed that FGS is a safe and effective technique for maximizing tumor resection in HGGs (14).

Meta-analysis-comparative studies. Direct head-to-head comparisons between 5-ALA and fluorescein-guided surgery

are limited. From an initial pool of 511 studies, 112 were considered potentially eligible (Fig. 1). After applying all exclusion criteria, 41 studies remained. Further exclusion of studies focusing exclusively on one modality reduced the final dataset to 5 comparative studies (37-41). Across these 5 studies, the mean patient age was 57.9 years. The pooled cohort consisted of 732 patients with HGGs, of whom 503 (68.7%) underwent 5-ALA-guided resection (Group A) and 229 (31.3%) underwent fluorescein-guided resection (Group B) (Table II).

Postoperative neurological deficit. All five studies provided data on neurological outcomes (37-41). Among patients treated with 5-ALA, 70 of 503 (9.5%) developed new neurological deficits, compared with 73 of 229 (9.9%) in the fluorescein group (Table II). The pooled analysis demonstrated a statistically significant difference favoring 5-ALA [(OR=0.88; 95% CI (0.17-4.57); $P<0.05$)]. However, heterogeneity was substantial [$I^2=90\%$; $P=0.88$] (Fig. 2A), and funnel plot analysis indicated publication bias (Fig. 2B).

Postoperative KPS ≥ 70 . Information on postoperative KPS ≥ 70 within 30 days was reported in all five studies (37-41). The pooled results suggested a statistically significant difference between the two groups [OR=49.46; 95% CI (-2.21-101.13); $P<0.05$], though heterogeneity was extremely high ($I^2=100\%$, $P=0.06$) (Fig. 3A). Funnel plot inspection again revealed evidence of publication bias (Fig. 3B) (Table II).

OS. Data on OS were available from all five studies (37-41). The pooled analysis showed a significant difference in favor of 5-ALA [OR=4.05; 95% CI (1.33-6.77); $P<0.05$]. Nonetheless, heterogeneity was substantial ($I^2=98\%$; $P<0.05$) (Fig. 4A), and the funnel plot demonstrated publication bias (Fig. 4B; Table II).

Extent of resection and GTR rate. Both 5-ALA and fluorescein significantly increase the extent of tumor resection in HGGs compared with conventional white-light microsurgery. The pivotal 2006 ALA-Glioma Study by Stummer *et al* (19) demonstrated that 5-ALA guidance nearly doubled the rate of complete resection of contrast-enhancing tumor (65% with 5-ALA vs. 36% with white-light, $P<0.0001$). This finding has been consistently validated in subsequent studies. The multicenter RESECT trial reported GTR rates of 79.1% with 5-ALA versus 47.8% in controls ($P=0.0002$) (11).

For fluorescein-guided surgery, reported GTR rates are comparably high. A prospective phase II trial in glioblastoma achieved complete resection in 82.6% of patients (12), and a meta-analysis confirmed that fluorescein significantly improves GTR rates compared with non-fluorescent surgery (12,14,16). In a large retrospective study, Schebesch *et al* (13) showed that fluorescein guidance led to significantly higher GTR rates and greater mean extent of resection than white-light microsurgery.

Direct comparisons between the two modalities suggest broadly equivalent resection outcomes. In the largest comparative study to date, Hansen *et al* (37) found no significant difference in median extent of resection between 5-ALA-guided and fluorescein-guided groups (96.9 vs. 97.4%;

$P=0.46$) (10). Similarly, the proportion of patients with only microscopic residual tumor ($<0.175\text{ cm}^3$) did not differ significantly (29.5 vs. 36.2%; $P=0.39$) (37). These results suggest that in experienced hands, fluorescein can achieve resection completeness comparable to 5-ALA. Importantly, both techniques outperform conventional microsurgery: A network meta-analysis ranked fluorescence guidance (5-ALA or fluorescein) and intraoperative MRI as superior to white-light surgery for maximizing GTR in HGGs (15). In summary, both agents reliably enable high EOR, with GTR rates frequently exceeding 80%, whereas white-light resection typically achieves $\leq 50\%$ (1,12).

Survival outcomes. Maximal resection is a well-established determinant of survival in glioblastoma, and the rationale for fluorescence guidance is to increase GTR rates and thereby improve PFS and OS. The original 5-ALA trial demonstrated a significant improvement in 6-month PFS (41 vs. 21% with white-light surgery) (1), though no significant OS difference was observed, likely due to crossover and subsequent adjuvant therapies. Similarly, the RESECT trial did not show a significant OS benefit (24-month OS: $\sim 30\%$ with 5-ALA vs. 37% in controls, $P=0.89$), nor a significant PFS difference (11). Notably, in RESECT, both arms achieved higher-than-expected PFS rates ($\sim 69-70\%$), and multivariate analysis identified GTR, not the choice of fluorophore, as the independent predictor of survival (11).

For fluorescein, most evidence derives from non-randomized studies. Schebesch *et al* (13) reported that fluorescein-guided resection was associated with significantly longer median PFS and OS compared with white-light surgery, with fluorescein use emerging as an independent prognostic factor in multivariate analysis. A network meta-analysis by Naik *et al* (15) similarly found that fluorescein guidance was associated with improved OS versus no fluorescence, whereas pooled data for 5-ALA did not show a statistically significant OS advantage. However, this apparent difference must be interpreted cautiously, as the fluorescein data come predominantly from observational cohorts subject to selection bias.

Head-to-head comparisons again suggest broadly similar outcomes. In the study by Hansen *et al* (37), median OS was longer in the fluorescein group (19.7 months) compared with the 5-ALA group (14.8 months), though this difference did not reach statistical significance ($P=0.06$). PFS was marginally higher with fluorescein (9.2 vs. 8.7 months, $P=0.03$) (37), but the retrospective design limits firm conclusions.

Taken together, current evidence does not support a definitive survival advantage of one fluorophore over the other. Both 5-ALA and fluorescein contribute to improved PFS and OS indirectly, insofar as they enable higher rates of complete resection. Importantly, neither technique has been associated with increased neurological morbidity; instead, both are intended to facilitate maximal safe resection, which remains the key determinant of long-term outcomes (11).

Discussion

Both 5-ALA and fluorescein have demonstrated clear benefits in facilitating maximal resection of HGGs. The present meta-analysis indicated that 5-ALA was associated with

Table I. Newcastle-Ottawa Scale (NOS) quality assessment of final article pool.

| First author/s, year | Study design | Selection | Newcastle-Ottawa Scale | | | (Refs.) |
|--------------------------------|---------------|-----------|------------------------|----------|--------------|---------|
| | | | Comparability | Exposure | Total scores | |
| Eljamel <i>et al</i> , 2008 | Retrospective | 3 | 3 | 3 | 9 | (39) |
| Hansen <i>et al</i> , 2019 | Retrospective | 3 | 3 | 3 | 9 | (37) |
| Baig Mirza <i>et al</i> , 2021 | Retrospective | 3 | 2 | 2 | 7 | (40) |
| Baig Mirza <i>et al</i> , 2022 | Retrospective | 3 | 3 | 3 | 9 | (41) |
| Zeppa <i>et al</i> , 2022 | Retrospective | 3 | 3 | 2 | 8 | (38) |

Table II. Pooled effect estimates of 5-ALA vs. fluorescein-guided resection in high-grade gliomas.

| Parameter | Included Trials, n=5 | Number of events | | Overall effect | | | Heterogeneity | |
|------------------------------------|----------------------|------------------|------------------|-----------------|----------------|---------|--------------------|----------|
| | | 5-ALA | FGS | Effect estimate | 95% CI | P-value | I ² (%) | P-value |
| Postoperative Neurological Deficit | 5 | 70/503 (9.5%) | 73/229 (9.9%) | 0.88 | (0.17-4.57) | 0.88 | 90 | <0.00001 |
| Postoperative KPS≥70 | 5 | Mean ± SD | | 49.46 | (-2.21-101.13) | 0.06 | 100 | <0.00001 |
| OS | 5 | 92.8±95.0 | 43.4±25.3 | 4.05 | (1.33-6.77) | <0.05 | 98 | <0.00001 |

FGS, fluorescence-guided surgery; 5-ALA, 5-aminolevulinic acid; KPS, Karnofsky Performance Scale; OS, overall survival; I², percentage of total variation across studies that is due to heterogeneity rather than chance; CI, confidence interval; SD, standard deviation.

improved outcomes in terms of postoperative neurological deficits, postoperative KPS ≥70, and OS compared with fluorescein. However, significant heterogeneity and evidence of publication bias mitigate the strength of these findings, precluding definitive conclusions regarding superiority of one technique over the other.

5-ALA's principal advantage lies in its tumor specificity. After metabolic conversion to protoporphyrin IX, 5-ALA accumulates predominantly in high-grade tumor cells, producing a highly specific fluorescent signal that correlates with tumor cell density and offers near-perfect positive predictive value (1,19,34). Its efficacy is supported by the highest level of evidence, including a Phase III randomized trial demonstrating superior resection rates versus white-light surgery (1), and its regulatory approval facilitates clinical adoption. In addition, 5-ALA fluorescence can extend beyond MRI-visible contrast enhancement and, in some settings, enables adjunctive photodynamic therapy (22,23,33,35). Limitations include preoperative dosing requirements, need for blue-light optics, transient photosensitivity, restricted utility in lower-grade gliomas and high cost (1,11,30-32).

Fluorescein, by contrast, is inexpensive, easy to administer intravenously at the start of surgery, and widely available (1,7,32). It does not require extensive preoperative preparation, has minimal side effects, and allows surgery under near-normal illumination, which preserves visualization of vasculature and facilitates uninterrupted workflow (1,31). Fluorescein is also versatile, as it highlights

any contrast-enhancing lesion, including metastases and pediatric tumors (1). Its disadvantages are mainly related to limited tumor specificity, as it accumulates in any area of BBB disruption, raising the possibility of false positives in cases of radiation necrosis or inflammation (17,18,20). It may also fail to detect infiltrative tumor beyond enhancing margins, where 5-ALA may still fluoresce (20). Practical considerations include the need for a dedicated yellow filter and occasional difficulties with color contrast in bloody fields (20,31).

An important aspect of comparing 5-ALA and fluorescein is the safety profile of each agent and its impact on surgical morbidity. Both agents have been shown to be very safe in patients with HGG, with low rates of drug-specific adverse events and no increase in permanent neurological deficit rates attributable to their use (11,19).

5-ALA safety. Oral 5-ALA is generally well tolerated. In the 5-ALA arm of the RESECT trial (88 patients), adverse events related to 5-ALA were rare: Only 4.6% of patients experienced transient photosensitivity reactions and 1.1% had transient elevated liver enzymes ('hepatic cytolysis') (19). No significant differences in postoperative Karnofsky performance or neurological deficits were observed between 5-ALA and control groups indicating that fluorescence guidance did not lead to higher neurological risk (11,19). However, 5-ALA does have known side effects and practical precautions. Because it can cause cutaneous photosensitivity for ~24 h, treated patients must avoid direct bright light exposure post-operatively (11).

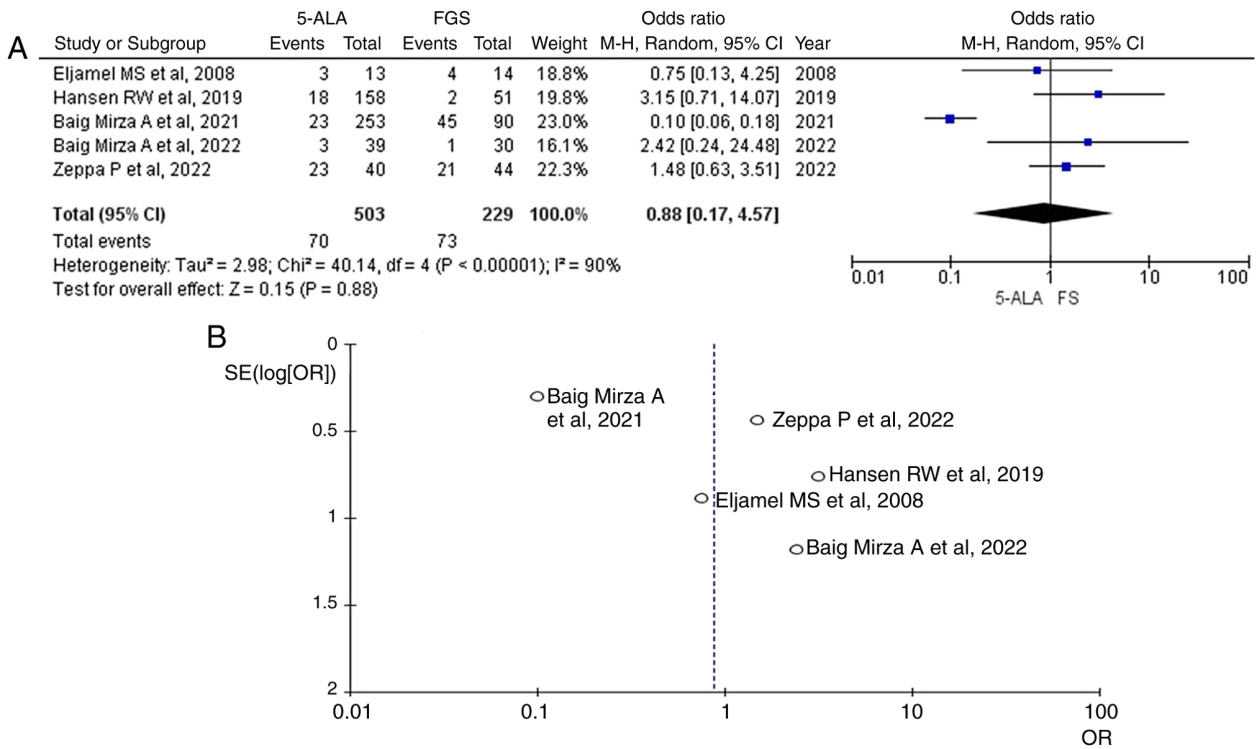


Figure 2. (A) Forest plot for postoperative neurological deficit, with the results demonstrated a statistically significant difference between groups [OR: 0.88, 95% CI: (0.17,4.57), P<0.00001], but with heterogeneity (P=0.88, I²=90%). (B) Funnel plots for Postoperative Neurological deficit in the two groups with heterogeneity (P=0.88, I²=90%). I², percentage of total variation across studies that is due to heterogeneity rather than chance; CI, confidence interval; OR, odds ratio.

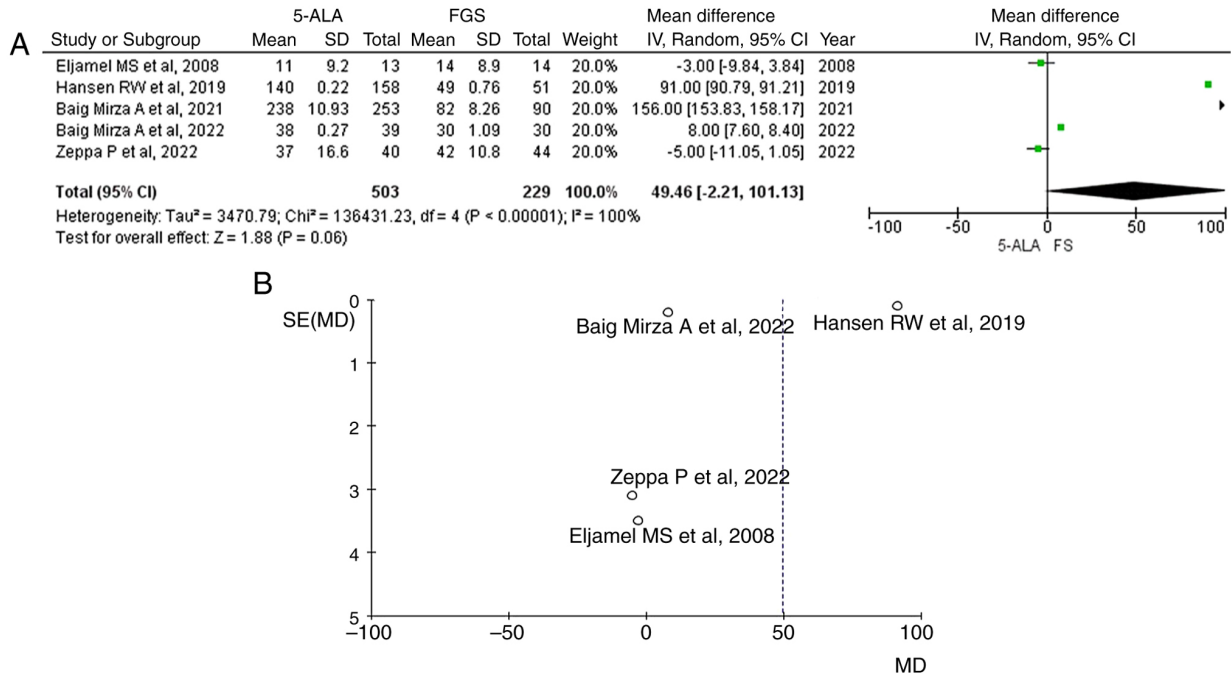


Figure 3. (A) Forest plot for Postoperative KPS ≥70, with the results demonstrated a statistically significant difference between groups [OR=49.46; 95% CI: (-2.21, 101.13); P<0.00001] but with heterogeneity (P=0.06 and I²=100%). (B) Funnel plots for Postoperative KPS≥70 in the two groups with high heterogeneity (P=0.06 and I²=100%). I², percentage of total variation across studies that is due to heterogeneity rather than chance; CI, confidence interval; KPS, Karnofsky Performance Scale.

Some patients report mild nausea or hypotension related to 5-ALA ingestion, and very rarely allergic reactions have been noted (though none was severe in reported trials). Overall, the

incidence of serious adverse reactions to 5-ALA is low, and no long-term toxicities have been identified with its intermittent use in surgery.

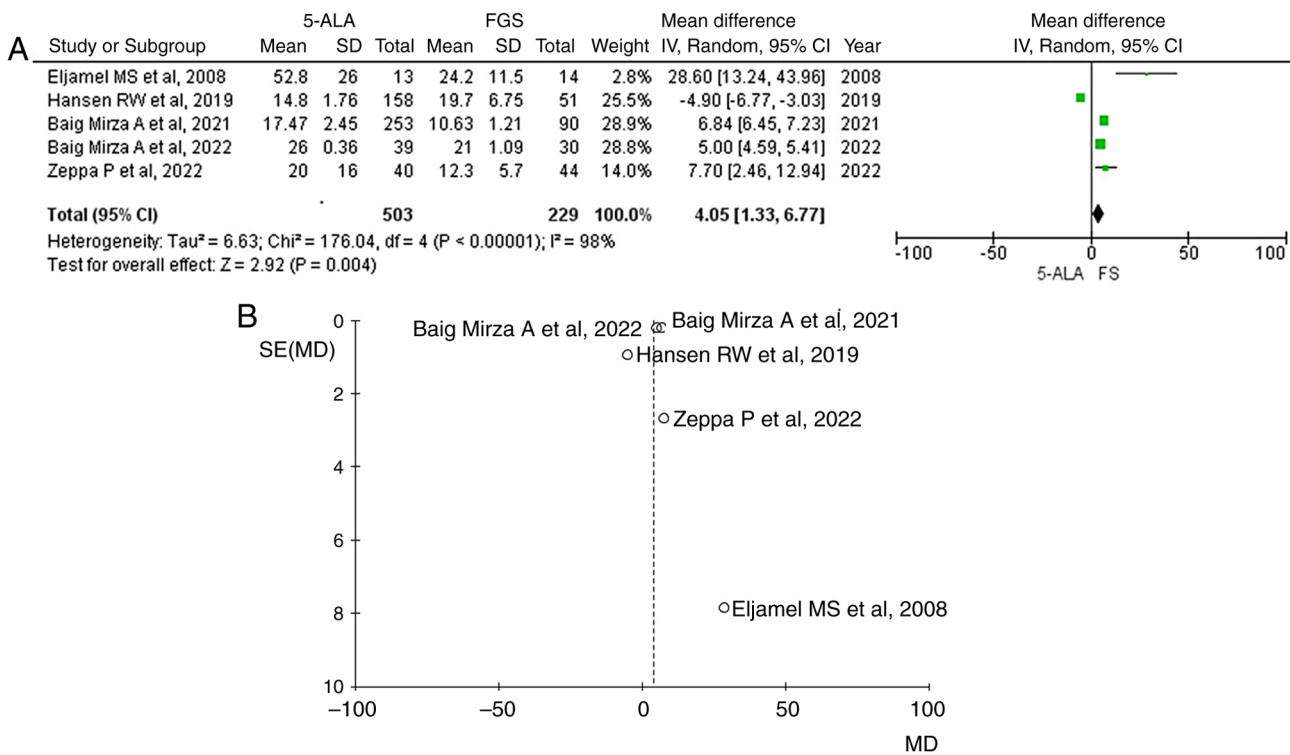


Figure 4. (A) Forest plot for OS, with the results demonstrated a statistically significant difference between groups [OR=4.05; 95% CI: (1.33, 6.77); P<0.00001] but a high heterogeneity was found (P<0.05 and I²=98%). (B) Funnel plots for OS in the two groups with high heterogeneity (P<0.05 and I²=98%). I², percentage of total variation across studies that is due to heterogeneity rather than chance; CI, confidence interval; OS, overall survival.

Fluorescein safety. Modern fluorescein-guided neurosurgery typically uses a low-dose regimen (3-5 mg/kg IV) at induction of anesthesia, which has an excellent safety profile. Across numerous series totaling hundreds of patients, there have been no significant adverse reactions attributed to fluorescein at this dosage (12). For instance, in the FLUOGLIO trial (46 patients), no fluorescein-related toxic events were recorded (12). Similarly, Martinez *et al* (44) reported no complications in 47 patients; importantly, they did not observe any cases of anaphylaxis, hypotension, or end-organ toxicity (14). Older literature on fluorescein (using higher doses of ~20 mg/kg without filtered microscopy) noted rare side effects such as transient skin discoloration, nausea, or very infrequently anaphylactic shock, but such issues have not been reported with the current low-dose, filtered technique. As with 5-ALA, fluorescein guidance has not been associated with increased neurological deficits, in fact, one study noted that the fluorescein-guided group had a slightly shorter operative time and trend toward fewer complications than controls (16). A practical point is that fluorescein will turn the patient's urine bright yellow for ~1 day as it is excreted, but this is harmless.

In terms of surgical safety, both methods are intended to improve the surgeon's ability to resect tumor while avoiding eloquent areas, and neither has shown a detriment to functional outcomes. The field of fluorescence-guided neurosurgery is advancing rapidly, with several emerging technologies poised to expand its utility. One promising area is next-generation fluorophores, particularly near-infrared (NIR) agents operating at 700-1,000 nm, which allow deeper tissue penetration and reduced background autofluorescence, enabling visualization of subcortical tumor (23-25). Another frontier is

tumor-targeted molecular probes. Unlike 5-ALA and fluorescein, which mark metabolic activity or BBB disruption, newer probes aim at specific tumor markers. For example, an EGFR-targeted probe (cetuximab-IRDye800) has been tested in EGFR-positive glioblastomas (21,36), while antibodies and peptides against IL13R α 2 and integrins are under early investigation. Dual-modality agents, labeled for both PET and NIR fluorescence, have also been developed, such as GRPR-targeting probes that guide resection of otherwise non-enhancing gliomas (24).

Combined modalities may further enhance resection safety. Integration with intraoperative MRI (26) or quantitative fluorescence analysis has shown promise; for instance, Valdés *et al* (33) demonstrated that spectroscopic measurement of protoporphyrin can identify residual tumor below visual detection thresholds (27,28). Theranostic approaches are also being explored, including nanoparticles capable of dual imaging and therapy, with some NIR-responsive platforms combining tumor visualization with drug delivery or photothermal ablation (39).

There were also systematic reviews and network meta-analyses using three-way comparison of three modalities (intraoperative MRI with 5 ALA or FGS) leading to greater rates of GTR in HGGs (6,15). However, the present meta-analysis focusing on correct comparative studies may constitute valuable research in this field, as more clearly explicit the real usefulness of these two modalities (5-ALA and FGS) separately.

The present systematic review has several limitations. First, direct head-to-head trials comparing 5-ALA and fluorescein remain scarce. Most included studies differed in patient populations, tumor grades and outcome definitions,

resulting in significant heterogeneity and limiting quantitative synthesis. Numerous fluorescein studies were small, single-arm series without control groups, raising the risk of publication bias and overestimation of benefit (17,18,20). Blinding is inherently impossible in this field, introducing observer bias, and surgeon behavior may be influenced by the presence of fluorescence itself.

Second, available data were limited, particularly regarding long-term survival with fluorescein, which is largely inferred from indirect evidence. Most studies emphasized short-term endpoints such as extent of resection or early postoperative outcomes, rather than durable oncological control. Unpublished data, conference abstracts and non-English studies were also excluded, which may omit emerging trial results.

Third, methodological quality varied. While 5-ALA has strong Phase III trial evidence (1), most fluorescein studies remain observational with intermediate to high risk of bias. Although it was attempted to focus on objective MRI-confirmed resection rates, the lack of uniform methodology across studies restricts comparability. Also, according to the fifth edition of the WHO Classification of Tumors of the Central Nervous System, published in 2021, new tumor types and subtypes are introduced, some based on novel diagnostic technologies such as DNA methylome profiling, and these may be helpful for the management of HGMs (45). In addition, gliomas exhibit a broad range of molecular alterations, including gene mutations, amplifications and deletions, that influence tumor development and patient prognosis. Key biomarkers include IDH1/2 mutations, as well as alterations in TP53, ATRX, PTEN and EGFR. Additional important features include 1p/19q codeletion, TERT promoter mutations and CDKN2A/B deletions. Thus, further analysis and data are needed for more accurate results regarding HGMs prognosis (45). Last but not at least, another limitation was that both 5-ALA-guided resection and other FGS methods have limited sensitivity and specificity, including the false-positive and false-negative rates (46).

Despite these limitations, current evidence consistently supports the role of both 5-ALA and fluorescein in enhancing the extent of glioma resection. Each technique has distinct advantages and trade-offs, and both can be applied safely in routine neurosurgical practice. Ongoing comparative trials, standardized outcome reporting, and cost-effectiveness analyses will be crucial to clarify their relative roles and optimize fluorescence-guided strategies in malignant glioma surgery.

In conclusion, in HGG surgery, fluorescence guidance has become an indispensable strategy to maximize tumor resection. 5-ALA and fluorescein each have well-demonstrated benefits in this regard. 5-ALA offers tumor-selective visualization and a robust evidence base, whereas fluorescein provides versatility and cost-effectiveness with comparable resection outcomes. Neurosurgeons should be familiar with both modalities and their respective pros and cons. In practice, usage may be tailored to the clinical scenario and resource setting. Ongoing innovations promise to further refine fluorescence-guided resection, but at present, 5-ALA and fluorescein remain the two cornerstone options that have measurably improved surgical outcomes for patients with malignant gliomas. The ultimate goal is to achieve the maximal safe resection for every patient, a goal that, thanks to these fluorescence techniques, is more attainable than ever before.

Acknowledgements

Not applicable.

Funding

No funding was received.

Availability of data and materials

Not applicable.

Authors' contributions

EK and GF conceptualized the study. EK, NF, GF, NT, IK, VEG and DAS made a substantial contribution to data interpretation and analysis and wrote and prepared the draft of the manuscript. GF and NF analyzed the data and provided critical revisions. All authors contributed to manuscript revision, read and approved the final version of the manuscript.

Ethics approval and consent to participate

Not applicable.

Patient consent for publication

Not applicable.

Competing interests

The authors declare that they have no competing interests.

Use of artificial intelligence tools

During the preparation of this work, artificial intelligence tools were used to improve the readability and language of the manuscript or to generate images, and subsequently, the authors revised and edited the content produced by the artificial intelligence tools as necessary, taking full responsibility for the ultimate content of the present manuscript.

References

- Ahrens LC, Krabbenhöft MG, Hansen RW, Mikic N, Pedersen CB, Poulsen FR and Korshøj AR: Effect of 5-aminolevulinic acid and sodium fluorescein on the extent of resection in high-grade gliomas and brain metastasis. *Cancers (Basel)* 14: 617, 2022.
- Gandhi S, Meybodi AT, Belykh E, Cavallo C, Zhao X, Syed MP, Moreira LB, Lawton MT, Nakaji P and Preul MC: Survival outcomes among patients with high-grade glioma treated with 5-aminolevulinic acid-guided surgery: A systematic review and meta-analysis. *Front Oncol* 9: 620, 2019.
- Cordova JS, Gurbani SS, Holder CA, Olson JJ, Schreibmann E, Shi R, Guo Y, Shu HK, Shim H and Hadjipanayis CG: Semi-automated volumetric and morphological assessment of glioblastoma resection with fluorescence-guided surgery. *Mol Imaging Biol* 18: 454-462, 2016.
- Richter JCO, Haj-Hosseini N, Hallbeck M and Wårdell K: Combination of hand-held probe and microscopy for fluorescence guided surgery in the brain tumor marginal zone. *Photodiagnosis Photodyn Ther* 18: 185-192, 2017.

5. Patil CG, Walker DG, Miller DM, Butte P, Morrison B, Kittle DS, Hansen SJ, Nufer KL, Byrnes-Blake KA, Yamada M, *et al*: Phase I safety, pharmacokinetics, and fluorescence imaging study of tozuleristide (BLZ-100) in adults with newly diagnosed or recurrent gliomas. *Neurosurgery* 85: E641-E649, 2019.
6. Valerio JE, de Jesús Aguirre Vera G, Zumaeta J, Rea NS, Gomez MP, Mantilla-Farfan P, Valente L and Alvarez-Pinzon AM: Comparative analysis of 5-ALA and fluorescent techniques in high-grade glioma treatment. *Biomedicines* 13: 1161, 2025.
7. Stummer W, Tonn JC, Mehdorn HM, Nestler U, Franz K, Goetz C, Bink A and Pichlmeier U; ALA-Glioma Study Group: Counterbalancing risks and gains from extended resections in malignant glioma surgery: A supplemental analysis from the randomized 5-aminolevulinic acid glioma resection study. *Clinical article. J Neurosurg* 114: 613-623, 2011.
8. Lau D, Hervey-Jumper SL, Chang S, Molinaro AM, McDermott MW, Phillips JJ and Berger MS: A prospective phase II clinical trial of 5-aminolevulinic acid to assess the correlation of intraoperative fluorescence intensity and degree of histologic cellularity during resection of high-grade gliomas. *J Neurosurg* 124: 1300-1309, 2016.
9. Page MJ, McKenzie JE, Bossuyt PM, Boutron I, Hoffmann TC, Mulrow CD, Shamseer L, Tetzlaff JM, Akl EA, Brennan SE, *et al*: The PRISMA 2020 statement: An updated guideline for reporting systematic reviews. *BMJ* 372: n71, 2021.
10. Stummer W, Nestler U, Stockhammer F, Krex D, Kern BC, Mehdorn HM, Vince GH and Pichlmeier U: Favorable outcome in the elderly cohort treated by concomitant temozolomide radiochemotherapy in a multicentric phase II safety study of 5-ALA. *J Neurooncol* 103: 361-370, 2011.
11. Picart T, Pallud J, Berthiller J, Dumot C, Berhouma M, Ducray F, Armoiry X, Margier J, Guerre P, Varlet P, *et al*: Use of 5-ALA fluorescence-guided surgery versus white-light conventional microsurgery for the resection of newly diagnosed glioblastomas (RESECT study): a French multicenter randomized phase III study. *J Neurosurg* 140: 987-1000, 2023.
12. Acerbi F, Broggi M, Schebesch KM, Höhne J, Cavallo C, De Laurentis C, Eoli M, Anghileri E, Servida M, Boffano C, *et al*: Fluorescein-guided surgery for resection of high-grade gliomas: A multicentric prospective phase II study (FLUOGLIO). *Clin Cancer Res* 24: 52-61, 2018.
13. Schebesch KM, Höhne J, Rosengarth K, Noeva E, Schmidt NO and Proescholdt M: Fluorescein-guided resection of newly diagnosed high-grade glioma: Impact on extent of resection and outcome. *Brain Spine* 2: 101690, 2022.
14. Francaviglia N, Iacopino DG, Costantino G, Villa A, Impallaria P, Meli F and Maugeri R: Fluorescein for resection of high-grade gliomas: A safety study control in a single center and review of the literature. *Surg Neurol Int* 8: 145, 2017.
15. Naik A, Smith EJ, Barreau A, Nyaeme M, Cramer SW, Najafali D, Krist DT, Arnold PM and Hassaneen W: Comparison of fluorescein sodium, 5-ALA, and intraoperative MRI for resection of high-grade gliomas: A systematic review and network meta-analysis. *J Clin Neurosci* 98: 240-247, 2022.
16. Xi C, Jinli S, Jianyao M, Yan C, Huijuan L, Zhongjie S, Zhangyu L, Liwei Z, Yukui L, Sifang C and Guowei T: Fluorescein-guided surgery for high-grade glioma resection: A five-year-long retrospective study at our institute. *Front Oncol* 13: 1191470, 2023.
17. Schupper AJ, Rao M, Mohammadi N, Baron R, Lee JYK, Acerbi F and Hadjipanayis CG: Fluorescence-guided surgery: A review on timing and use in brain tumor surgery. *Front Neurol* 12: 682151, 2021.
18. Mansour HM, Shah S, Aguilar TM, Abdul-Muqith M, Gonzales-Portillo GS and Mehta AI: Enhancing glioblastoma resection with NIR fluorescence imaging: A systematic review. *Cancers (Basel)* 16: 3984, 2024.
19. Stummer W, Stepp H, Wiestler OD and Pichlmeier U: Randomized, prospective double-blinded study comparing 3 different doses of 5-aminolevulinic acid for fluorescence-guided resections of malignant gliomas. *Neurosurgery* 81: 230-239, 2017.
20. Della Puppa A, Ciccarino P, Lombardi G, Rolma G, Cecchin D and Rossetto M: 5-Aminolevulinic acid fluorescence in high grade glioma surgery: Surgical outcome, intraoperative findings, and fluorescence patterns. *Biomed Res Int* 2014: 232561, 2014.
21. Cramer SW and Chen CC: Photodynamic therapy for the treatment of glioblastoma. *Front Surg* 6: 81, 2020.
22. Molina ES and Brokinkel B: Letter to the editor. Sodium fluorescein versus 5-aminolevulinic acid to visualize high-grade gliomas. *J Neurosurg* 133: 1627-1630, 2020.
23. Shi X, Zhang Z, Zhang Z, Cao C, Cheng Z, Hu Z, Tian J and Ji N: Near-infrared window II fluorescence image-guided surgery of high-grade gliomas prolongs the progression-free survival of patients. *IEEE Trans Biomed Eng* 69: 1889-1900, 2022.
24. Cesca BA, Martin KP, Caverzan MD, Oliveda PM and Ibarra LE: State-of-the-art photodynamic therapy for malignant gliomas: Innovations in photosensitizers and combined therapeutic approaches. *Explor Target Antitumor Ther* 6: 1002303, 2025.
25. Tao T, Li G, Zhou K, Pan Q, Wu D, Lai L, Gao M, Li S, Chen L, Han RPS, *et al*: Discovery of fatty acid translocase CD36-targeting near-infrared fluorescent probe enables visualization and imaging-guided surgery for glioma. *Anal Chem* 97: 3687-3695, 2025.
26. Panciani PP, Fontanella M, Schatlo B, Garbossa D, Agnoletti A, Ducati A and Lanotte M: Fluorescence and image guided resection in high grade glioma. *Clin Neurol Neurosurg* 114: 37-41, 2012.
27. Henderson F Jr, Belykh E, RaOS AD and Schwartz TH: Qualitative head-to-head comparison of headlamp and microscope for visualizing 5-ALA fluorescence during resection of glioblastoma. *Neurosurg Focus Video* 6: V7, 2022.
28. Chen L, Zhang J, Chi C, Che W, Dong G, Wang J, Du Y, Wang R, Zhu Z, Tian J, *et al*: Lower-grade gliomas surgery guided by GRPR-targeting PET/NIR dual-modality image probe: A prospective and single-arm clinical trial. *Theranostics* 14: 819-829, 2024.
29. Inogés S, Tejada S, de Cerio AL, Pérez-Larraya JG, Espinós J, Idoate MA, Domínguez PD, de Eulate RG, Aristu J, Bendandi M, *et al*: A phase II trial of autologous dendritic cell vaccination and radiochemotherapy following fluorescence-guided surgery in newly diagnosed glioblastoma patients. *J Transl Med* 15: 104, 2017.
30. Chung IW and Eljamel S: Risk factors for developing oral 5-aminolevulinic acid-induced side effects in patients undergoing fluorescence guided resection. *Photodiagnosis Photodyn Ther* 10: 362-367, 2013.
31. Feigl GC, Ritz R, Moraes M, Klein J, Ramina K, Gharabaghi A, Kriscsek B, Danz S, Bornemann A, Liebsch M and Tatagiba MS: Resection of malignant brain tumors in eloquent cortical areas: a new multimodal approach combining 5-aminolevulinic acid and intraoperative monitoring. *J Neurosurg* 113: 352-357, 2010.
32. Roberts DW, Olson JD, Evans LT, Kolste KK, Kanick SC, Fan X, Bravo JJ, Wilson BC, Leblond F, Marois M and Paulsen KD: Red-light excitation of protoporphyrin IX fluorescence for subsurface tumor detection. *J Neurosurg* 128: 1690-1697, 2018.
33. Valdés PA, Leblond F, Kim A, Harris BT, Wilson BC, Fan X, Tosteson TD, Hartov A, Ji S, Erkmén K, *et al*: Quantitative fluorescence in intracranial tumor: Implications for ALA-induced PpIX as an intraoperative biomarker. *J Neurosurg* 115: 11-17, 2011.
34. Nabavi A, Thurm H, Zountsas B, Pietsch T, Lanfermann H, Pichlmeier U and Mehdorn M; 5-ALA Recurrent Glioma Study Group: Five-aminolevulinic acid for fluorescence-guided resection of recurrent malignant gliomas: A phase II study. *Neurosurgery* 65: 1070-1076, 2009.
35. Zimmermann A, Ritsch-Marte M and Kostron H: mTHPC-mediated photodynamic diagnosis of malignant brain tumors. *Photochem Photobiol* 74: 611-616, 2001.
36. Li C, Sullivan PZ, Cho S, Nasrallah MP, Buch L, Chen HC and Lee JYK: Intraoperative molecular imaging with second window indocyanine green facilitates confirmation of contrast-enhancing tissue during intracranial stereotactic needle biopsy: A case series. *World Neurosurg* 126: e1211-e1218, 2019.
37. Hansen RW, Pedersen CB, Halle B, Korshøj AR, Schulz MK, Kristensen BW and Poulsen FR: Comparison of 5-aminolevulinic acid and sodium fluorescein for intraoperative tumor visualization in patients with high-grade gliomas: A single-center retrospective study. *J Neurosurg* 133: 1324-1331, 2019.
38. Zeppa P, De Marco R, Monticelli M, Massara A, Bianconi A, Di Perna G, Crasto SG, Cofano F, Melcarne A, Lanotte MM and Garbossa D: Fluorescence-guided surgery in glioblastoma: 5-ALA, SF or both? Differences between fluorescent dyes in 99 consecutive cases. *Brain Sci* 12: 555, 2022.
39. Eljamel MS, Goodman C and OSeley H: ALA and Photofrin fluorescence-guided resection and repetitive PDT in glioblastoma multiforme: A single centre Phase III randomised controlled trial. *Lasers Med Sci* 23: 361-367, 2008.
40. Mirza AB, Christodoulides I, Lavrador JP, Giamouriadis A, Vastani A, Boardman T, Ahmed R, Norman I, Murphy C, Devi S, *et al*: 5-Aminolevulinic acid-guided resection improves the overall survival of patients with glioblastoma—a comparative cohort study of 343 patients. *Neurooncol Adv* 3: vdab047, 2021.

41. Mirza AB, Lavrador JP, Christodoulides I, Boardman TM, Vastani A, Al Banna Q, Ahmed R, Norman ICF, Murphy C, Devi S, *et al*: 5-Aminolevulinic acid-guided resection in grade III Tumors-A comparative cohort study. *Oper Neurosurg (Hagerstown)* 22: 215-223, 2022.
42. Sterne JAC, Savović J, Page MJ, Elbers RG, Blencowe NS, Boutron I, Cates CJ, Cheng HY, Corbett MS, Eldridge SM, *et al*: RoB 2: A revised tool for assessing risk of bias in randomised trials. *BMJ* 366: 14898, 2019.
43. Stang A: Critical evaluation of the Newcastle-Ottawa scale for the assessment of the quality of nonrandomized studies in meta-analyses. *Eur J Epidemiol* 25: 603-605, 2010.
44. Martinez-Castellanos MA, Velez-Montoya R, Price K, Henaine-Berra A, García-Aguirre G, Morales-Canton V and Cernichiaro-Espinosa LA: Vascular changes on fluorescein angiography of premature infants with low risk of retinopathy of prematurity after high oxygen exposure. *Int J Retina Vitreous* 3: 2, 2017.
45. Louis DN, Perry A, Wesseling P, Brat DJ, Cree IA, Figarella-Branger D, Hawkins C, Ng HK, Pfister SM, Reifenberger G, *et al*: The 2021 WHO classification of tumors of the central nervous system: A summary. *Neuro Oncol* 23: 1231-1251, 2021.
46. Gautheron A, Bernstock JD, Picart T, Guyotat J, Valdés PA and Montcel B: 5-ALA induced PpIX fluorescence spectroscopy in neurosurgery: A review. *Front Neurosci* 18: 1310282, 2024.



Copyright © 2026 Kogias et al. This work is licensed under a Creative Commons Attribution-NonCommercial-NoDerivatives 4.0 International (CC BY-NC-ND 4.0) License.