

Severe hepatitis E virus genotype 3b in a patient with alcohol-associated liver disease: A case report

TATSUO KANDA¹, SHUHEI ARIMA¹, REINA SASAKI-TANAKA¹, MAI TOTSUKA¹,
MASAYUKI HONDA¹, RYOTA MASUZAKI¹, NAOKI MATSUMOTO¹, MASAHIRO OGAWA¹,
MASAHARU TAKAHASHI², HIROAKI OKAMOTO² and HIROFUMI KOGURE¹

¹Division of Gastroenterology and Hepatology, Department of Medicine, Nihon University School of Medicine, Tokyo 173-8610; ²Division of Virology, Department of Infection and Immunity, Jichi Medical University School of Medicine, Shimotsuke, Tochigi 329-0498, Japan

Received January 30, 2024; Accepted March 6, 2024

DOI: 10.3892/mi.2024.146

Abstract. Hepatitis E virus (HEV) infection occasionally causes acute-on-chronic liver failure in patients with alcohol-associated cirrhosis. These reports have been published mainly from highly HEV genotype 1-endemic countries. The present study describes the case of a patient with severe HEV genotype 3b infection and alcohol-associated liver disease. A male patient in his 70s who consumed alcohol, and who had begun consuming alcohol at the age of 12, had high levels of alanine aminotransferase (ALT) and total bilirubin. The peak levels of ALT and total bilirubin were 1,067 IU/l and 26.3 mg/dl, respectively. A computed tomography scan revealed an atrophic liver. Upon admission, both anti-HEV immunoglobulin A and HEV RNA were positive, and his HEV was genotype 3b. He also had chronic kidney disease, as his estimated glomerular filtration rate was <45 ml/min/1.73 m², and ribavirin could not be used. The abnormal levels of the liver function parameters of the patient gradually improved due to conservative treatment, and he was discharged on day 43. On the whole, the present study demonstrates that careful attention should be paid to patients with viral hepatitis, including hepatitis E, when alcohol-associated liver disease is present. Novel anti-HEV drugs need to be developed for severe HEV infections with chronic kidney disease.

Introduction

Hepatitis E virus (HEV) infection occurs in an estimated 20 million individuals, leading to an estimated 3.3 million

symptomatic cases in developing and developed countries worldwide (1). Infection by HEV genotypes 1 and 2, which infect humans via the fecal-oral routes through the intake of contaminated foods and water, has mainly been reported in Southeast Asia and Mexico (2-5). HEV genotypes 3 and 4 are associated with zoonotic infection and are observed worldwide (6-9).

Acute hepatic insult manifesting as jaundice and coagulopathy, and complicated within 4 weeks by ascites and/or encephalopathy in patients with previously diagnosed or undiagnosed chronic liver disease is defined as acute-on-chronic liver failure (ACLF) (10). HEV genotype 1 plays a crucial role in acute viral hepatitis and ACLF in developing countries (11). Acute HEV genotype 1 infection is a leading cause of ACLF in Bangladesh and India (12,13).

HEV genotype 3 can also induce chronic infection in immunocompromised individuals and ACLF in patients with underlying liver disease (14-16). It has been reported that patients with HEV genotype 3 or 4 are susceptible to treatment with ribavirin (16).

Recently, the authors treated a Japanese male patient with severe acute HEV genotype 3b infection and alcohol-associated liver disease. The present study reports this case and discusses the possibility of ACLF induced by HEV genotype 3 infection and its treatment.

Case report

A patient male in his 70s who consumed alcohol experienced abdominal distention, loss of appetite, epigastric pain and dark urine (jaundice). After 5 days, he visited the local clinic near his residence, and the worsening of his liver function was observed by the obtained test results. The following day, he was referred and admitted to Nihon University Itabashi Hospital (Tokyo, Japan).

Due to the patient's history of cerebral infarction, hypertension, diabetes mellitus and hyperuricemia, he regularly visited the local clinic. Aspirin, valsartan, amlodipine besylate, furosemide, sitagliptin phosphate hydrate, ipragliflozin L-proline, febuxostat and magnesium oxide were prescribed. He had also undergone surgery for his springer finger, and cefaclor,

Correspondence to: Dr Tatsuo Kanda, Division of Gastroenterology and Hepatology, Department of Medicine, Nihon University School of Medicine, 30-1 Oyaguchi-Kamicho, Itabashi-ku, Tokyo 173-8610, Japan
E-mail: kandatatsuo@gmail.com; kanda.tatsuo@nihon-u.ac.jp

Key words: acute-on-chronic liver failure, alcohol, decompensated cirrhosis, hepatitis E virus genotype 3b, horse sashimi

Table I. Laboratory data of the patient upon admission (on day 0).

Item	Values	Item	Values	Item	Values
WBC	5,600 / μ l	AST	708 IU/l	NH ₃	43 μ g/dl
RBC	479x10 ⁴ / μ l	ALT	1,067 IU/l	anti-HIV	Negative
Hemoglobin	14.5 g/dl	LDH	410 IU/l	HBsAg	Negative
Platelets	132x10 ³ / μ l	ALP	491 IU/l	anti-HBc	Positive
Neutrophils	70.1%	γ-GTP	443 IU/l	anti-HBc IgM	Negative
Basophils	0.4%	CPK	66 U/ml	anti-HCV	Negative
Eosinophils	1.1%	T. Bil	6.6 mg/dl	anti-HAV IgM	Negative
Monocytes	7.7%	D. Bil	5.3 mg/dl	anti-HEV IgA	Positive
Lymphocytes	20.6%	TP	6.5 g/dl	HEV RNA	Positive
PT, INR	94%, 1.04	Albumin	3.4 g/dl	ANA	Negative
T. CHO	130 mg/dl	BUN	48.7 mg/dl	AMA M2	Negative
TG	194 mg/dl	Creatinine	2.2 mg/dl	IgG	1,391 mg/dl
Glucose	161 mg/dl	eGFR	24.2 ml/min/1.73 m²	IgA	336 mg/dl
HbA1c	8.6%	CRP	3.4 mg/dl	IgM	143 mg/dl

Non-bold values indicate within the normal limits. WBC, white blood cell count; RBC, red blood cell count; PT, prothrombin time; INR, international normalized ratio; T. CHO, total cholesterol; TG, triglyceride; HbA1c, hemoglobin A1c; AST, aspartate aminotransferase; ALT, alanine aminotransferase; LDH, lactate dehydrogenase; ALP, alkaline phosphatase; γ -GTP, γ -glutamyl transpeptidase; T. Bil, total bilirubin; D. Bil, direct bilirubin; TP, total protein; BUN, blood urea nitrogen; eGFR, estimated glomerular filtration rate; CRP, C-reactive protein; CPK, creatine phosphokinase; NH₃, ammonia; anti-HIV, anti-human immunodeficiency virus antibody; HBsAg, hepatitis B surface antigen; anti-HBc, anti-hepatitis B core antibody; Ig, immunoglobulin; anti-HCV, anti-hepatitis C virus antibody; anti-HAV, anti-hepatitis A virus antibody; anti-HEV, anti-hepatitis E virus antibody; GT, genotype; ANA, anti-nuclear antibody; AMA M2, anti-mitochondrial M2 antibody.

loxoprofen sodium salt and lebamipide were prescribed. He began to consume alcohol at 12 years of age. He had also consumed horse sashimi 1 month prior. He had no history of transfusion, tattooing, drug abuse or drug allergies, and had not recently traveled abroad. He had no family history of liver disease.

The height of the patient was 161 cm and his body weight was 69 kg. His blood pressure, pulse rate and body temperature were 157/93 mmHg, 71/min and 36.1°C, respectively. A physical examination revealed that he was conscious; he had hepatic encephalopathy grade <2, and he had conjunctival icterus. Abdominal distention was observed.

The laboratory data of the patient obtained upon admission are presented in Table I, indicating marked liver dysfunction and a history of hepatitis B virus (HBV) infection. At 2 weeks following admission, positivity for anti-HEV immunoglobulin A (IgA) antibody (Institute of Immunology, Co. Ltd., Tokyo, Japan) was revealed. The patient was found to be HEV RNA-positive and he had acute HEV genotype 3b infection, as determined according to previously described methods (17). Furthermore, using stored serial serum samples, the IgG, IgM and IgA classes of HEV antibodies were determined as previously described (18), and all these HEV antibodies tested positive until the end of the observation period (day 83) (Table II). He also had chronic kidney disease with a severely decreased estimated glomerular filtration rate (category G4) (19) and type 2 diabetes mellitus.

An abdominal computed tomography scan indicated an atrophic liver and cirrhosis, although no gastrointestinal

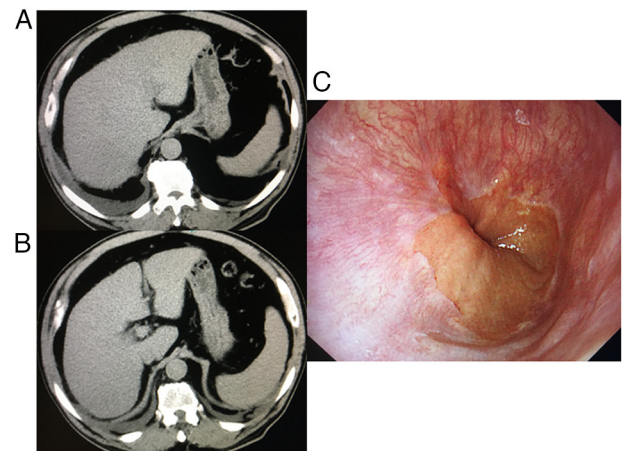


Figure 1. Abdominal CT scan and upper gastrointestinal endoscopic images. (A and B) Abdominal CT scan indicating signs of liver cirrhosis with para-umbilical vein dilatation, mild splenomegaly and right pleural effusion. (C) An upper gastrointestinal endoscopic examination did not reveal any esophageal varices. CT, computed tomography.

varices were present, according to the endoscopy (Fig. 1). An abdominal ultrasound sonography revealed collateral veins and splenomegaly; his liver stiffness was 41.2 kPa according to transient elastography, indicating liver cirrhosis and inflammation, although he never experienced any episodes of ascites, jaundice, hepatic encephalopathy, or variceal bleeding (20). The patient was diagnosed with severe acute HEV genotype 3b and alcohol-associated liver cirrhosis.

Table II. Changes in biochemical and virological parameters of the patient following admission.

Day	AST (IU/l)	ALT (IU/l)	T. Bil (mg/dl)	Cre (mg/dl)	Anti-HEV IgG	COI	Anti-HEV IgM	COI	Anti-HEV IgA	COI	HEV RNA
0	708	1,067	6.6	2.2	1.724	+	2.728	+	1.963	+	+
1	533	849	6.2	1.9	1.766	+	2.517	+	2.135	+	+
5	145	315	10.3	1.4							
7	181	270	15.4	1.3							
8	192	247	15.6	1.2							
11	273	294	22.7	1.3							
13	287	320	25.9	1.4	2.680	+	2.099	+	2.279	+	+
14	246	285	24.2	1.4	2.617	+	1.901	+	2.264	+	+
15	221	277	26.3	1.4	2.630	+	1.838	+	2.218	+	+
18	92	141	24.7	1.5	2.616	+	1.777	+	2.203	+	+
20	68	97	23.5	1.6	2.583	+	1.741	+	2.207	+	+
22	66	72	22.3	1.6	2.502	+	1.718	+	2.236	+	+
25	62	56	18.1	1.5	2.476	+	1.748	+	2.236	+	+
26	54	48	15.2	1.5	2.482	+	1.688	+	2.163	+	+
27	55	47	13.7	1.4	2.562	+	1.679	+	2.053	+	+
29	69	51	13.1	1.4	2.562	+	1.720	+	2.061	+	+
32	58	49	9.3	1.3	2.582	+	1.595	+	1.848	+	+
34	62	54	8.2	1.4	2.628	+	1.577	+	1.840	+	-
36	56	52	7.1	1.4	2.562	+	1.420	+	1.771	+	-
39	60	61	6.5	1.4	2.514	+	1.508	+	1.845	+	-
41	43	49	5.1	1.4	2.556	+	1.440	+	1.710	+	-
43	41	48	4.3	1.3	2.814	+	1.453	+	1.672	+	-
48	51	48	3.7	1.3	2.812	+	1.456	+	1.564	+	-
61	37	37	2.3	1.3	2.751	+	1.592	+	1.265	+	-
83	30	32	1.4	1.2	2.770	+	1.026	+	0.992	+	-

+ Symbols shown in bold font indicate more than the COI. The OD values of 0.152, 0.440 and 0.642 were used as the COI for the anti-HEV IgG, anti-HEV IgM and anti-HEV IgA, respectively (18). Day 0, day of admission; day 43, day of hospital discharge; COI, cut-off index; AST, aspartate aminotransferase; ALT, alanine aminotransferase; T. Bil, total bilirubin; Cre, creatinine; Anti-HEV, anti-hepatitis E virus antibody; Ig, immunoglobulin; +, positive; -, negative.

Due to his alcohol consumption shortly prior, indications for liver transplantation were not assessed. As ribavirin could not be used due to renal dysfunction (21), only conservative treatment was administered. However, his abnormal liver function tests gradually improved, although his HEV RNA was detectable by the highly sensitive nested reverse transcription-polymerase chain reaction with primers targeting the ORF2/ORF3 overlapping region (22) until day 32 after admission. The peak alanine aminotransferase (ALT) and total bilirubin levels were 1,067 IU/l and 26.3 mg/dl, respectively. He was ultimately discharged, and he left the hospital on foot on day 43 (Table II and Fig. 2).

Discussion

Barbosa *et al* (21) reported four ACLF/death patients with an HEV genotype 3 infection, and HEV should be considered

an acute insult in the acute decompensation of cirrhosis and ACLF. The present study also observed ACLF, which was associated with HEV genotype 3b and alcohol-induced acute insult and chronic liver disease in a patient in Japan.

Barbosa *et al* (21) reported that 50% of the patients with HEV genotype 3 infection were male, the median age was 63 years (range, 51-76 years), and the median ALT level at presentation was 2,486 U/l (range, 1,146-3,134 U/l) in the majority of cases of HEV-related ACLF. Among the causes of cirrhosis in these 4 patients, in 1 and 3 patients, this was caused by non-alcoholic steatohepatitis and alcohol-use, respectively (21). The data of the patient described in the present study were in agreement with this previous report (21).

The peak ALT level was 1,067 IU/l in the present case. High ALT levels may provide an indication for the diagnosis of acute HEV infection (21,23). Barbosa *et al* (21) also used ribavirin in 3 patients; however, in the present study, ribavirin

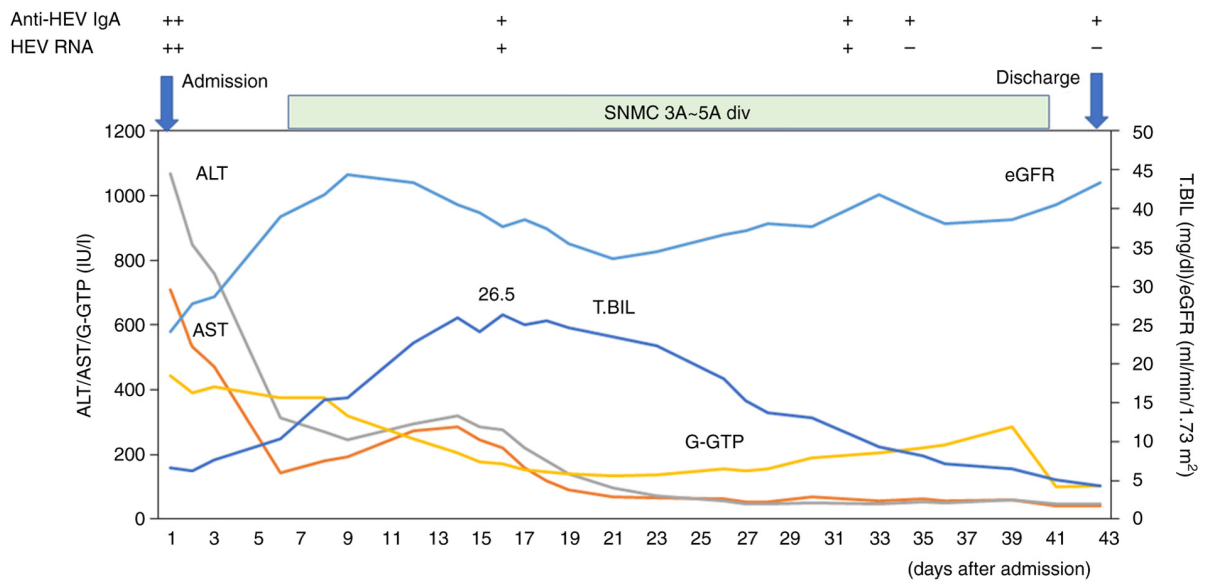


Figure 2. Clinical course of the patient in the present study. AST, aspartate aminotransferase; ALT, alanine aminotransferase; γ -GTP, γ -glutamyl transpeptidase; T. Bil, total bilirubin; eGFR, estimated glomerular filtration rate; anti-HEV IgA, anti-hepatitis E virus antibody immunoglobulin A; SNMC, Stronger Neo-Minophagen C with glycyrrhizin-containing preparation.

could not be used due to renal dysfunction. In general, pregnancy, severe anemia or renal dysfunction prohibit the use of ribavirin.

Although the present study did not measure HEV viral loads, HEV RNA became undetectable on day 34 in the present case (Table II). It appears to be more beneficial for patients to eradicate the hepatitis virus causing the hepatitis. More effective anti-HEV drugs need to be developed for severe HEV infection, particularly, in pregnant females (24). HEV-infected patients with cirrhosis with or without HBV infection may develop ACLF, which is associated with a high mortality rate (~70%) (25-27).

The patient in the present study had consumed horse sashimi approximately 1 month prior to the onset of his symptoms, such as abdominal distention, loss of appetite, epigastric pain and dark urine (jaundice). It has been reported that anti-HEV IgG antibody and/or HEV RNA are positive in workhorses or horses in Egypt (28), China (29), the Netherlands (30), Bulgaria (31) and Germany (32). However, since whether horses play a role in the transmission of HEV remains unknown, further studies are warranted in this regard.

HEV has been reported to be the most common cause of infection in 95 (46.1%) of 206 patients with acute sporadic viral hepatitis and 60 (67.4%) of 89 patients with ACLF in India, an endemic country of HEV genotype 1 infection (11). Lim *et al* (33) reported that a 59-year-old Caucasian male acquired HEV infection and fatal hepatic decompensated alcohol-associated liver cirrhosis in the United Kingdom, where the HEV genotype 3 is a major genotype. Fantilli *et al* (34) reported that HEV genotype 3 infection in a patient with alcohol-associated liver disease developed ACLF in Argentina.

To the best of our knowledge, there are two reported cases from Japan, where patients with primary biliary cholangitis were infected with HEV genotype 3b (35,36). Of these

2 patients, 1 patient succumbed due to the rupture of hepatocellular carcinoma (36). Another study reported that a 49-year-old male with excessive alcohol consumption and acute HEV genotype 4 infection developed acute liver failure (37). Thus, HEV genotype 3 or HEV genotype 4 is also a key acute insult in ACLF. Of interest, among patients with alcohol-associated liver cirrhosis, a higher prevalence of anti-HEV IgG has been observed in Poland (38) and Argentina (39).

Pegylated interferon- α with or without ribavirin may play a role in eradicating HEV in some patients, although pegylated interferon- α has more side-effects (40). Several drugs, such as interferon- λ , sofosbuvir, azithromycin and ritonavir, exert anti-viral effects on HEV replication *in vitro* (41,42). Further studies are required for the development of drugs against HEV infection.

In conclusion, careful attention should be paid to viral hepatitis, including hepatitis E, in patients with alcohol-associated liver disease. Further research and the development of novel drugs for HEV infection are required for the prevention of severe HEV infections.

Acknowledgements

Not applicable.

Funding

The present study was supported by the Japan Agency for Medical Research and Development (AMED) under the grant no. JP23fk0210132.

Availability of data and materials

The datasets used and/or analyzed during the current study are available from the corresponding author on reasonable request.

Authors' contributions

TK, RST, MTa and HO conceptualized the study, and collected and analyzed the patient's data. TK, SA, MTo, MH, RM, NM, MO and HK saw and examined the patient described in the present case report. MTa and HO analyzed the serum anti-HEV and serum HEV RNA levels of the patient. NM, MO and HK advised on medical images. TK, SA, RM, MTa and HO confirm the authenticity of all the raw data. TK, RST, MTa, HO and HK drafted the initial manuscript and revised the manuscript. All authors have read and approved the final manuscript.

Ethics approval and consent to participate

The study was conducted in accordance with the Declaration of Helsinki and approved by the Ethics Committee of Nihon University Itabashi Hospital (protocol code: RK-180911-12; dates of approval: October 5, 2018 and September 13, 2023) for studies involving human participants. Participation in the study was posted on the website of Nihon University Itabashi Hospital, and informed consent was obtained from the patient described herein.

Patient consent for publication

Written informed consent was obtained from the patient for the publication of the present case report and any accompanying images.

Competing interests

The authors declare that they have no competing interests.

References

- World Health Organization: Hepatitis E. WHO, Geneva, 2023. <https://www.who.int/news-room/fact-sheets/detail/hepatitis-e>. Accessed on December 25, 2023
- Balayan MS, Andjaparidze AG, Savinskaya SS, Ketiladze ES, Braginsky DM, Savinov AP and Poleschuk VF: Evidence for a virus in non-A, non-B hepatitis transmitted via the fecal-oral route. *Intervirology* 20: 23-31, 1983.
- Reyes GR, Purdy MA, Kim JP, Luk KC, Young LM, Fry KE and Bradley DW: Isolation of a cDNA from the virus responsible for enterically transmitted non-A, non-B hepatitis. *Science* 247: 1335-1339, 1990.
- Ray R, Aggarwal R, Salunke PN, Mehrotra NN, Talwar GP and Naik SR: Hepatitis E virus genome in stools of hepatitis patients during large epidemic in north India. *Lancet* 338: 783-784, 1991.
- Huang CC, Nguyen D, Fernandez J, Yun KY, Fry KE, Bradley DW, Tam AW and Reyes GR: Molecular cloning and sequencing of the Mexico isolate of hepatitis E virus (HEV). *Virology* 191: 550-558, 1992.
- Meng XJ, Purcell RH, Halbur PG, Lehman JR, Webb DM, Tsareva TS, Haynes JS, Thacker BJ and Emerson SU: A novel virus in swine is closely related to the human hepatitis E virus. *Proc Natl Acad Sci USA* 94: 9860-9865, 1997.
- Schlauder GG, Dawson GJ, Erker JC, Kwo PY, Knigge MF, Smalley DL, Rosenblatt JE, Desai SM and Mushahwar IK: The sequence and phylogenetic analysis of a novel hepatitis E virus isolated from a patient with acute hepatitis reported in the United States. *J Gen Virol* 79 (Pt 3): 447-456, 1998.
- Okamoto H, Takahashi M, Nishizawa T, Fukai K, Muramatsu U and Yoshikawa A: Analysis of the complete genome of indigenous swine hepatitis E virus isolated in Japan. *Biochem Biophys Res Commun* 289: 929-936, 2001.
- Takahashi K, Kang JH, Ohnishi S, Hino K, Miyakawa H, Miyakawa Y, Maekubo H and Mishiro S: Full-length sequences of six hepatitis E virus isolates of genotypes III and IV from patients with sporadic acute or fulminant hepatitis in Japan. *Intervirology* 46: 308-318, 2003.
- Sarin SK, Kumar A, Almeida JA, Chawla YK, Fan ST, Garg H, de Silva HJ, Hamid SS, Jalan R, Komolmit P, *et al*: Acute-on-chronic liver failure: Consensus recommendations of the Asian Pacific Association for the study of the liver (APASL). *Hepatol Int* 3: 269-282, 2009.
- Gupta E, Ballani N, Kumar M and Sarin SK: Role of non-hepatotropic viruses in acute sporadic viral hepatitis and acute-on-chronic liver failure in adults. *Indian J Gastroenterol* 34: 448-452, 2015.
- Mahtab MA, Rahman S, Khan M and Karim MF: Hepatitis E virus is a leading cause of acute-on-chronic liver disease: Experience from a tertiary centre in Bangladesh. *Hepatobiliary Pancreat Dis Int* 8: 50-52, 2009.
- Krishna YA, Saraswat VA, Das K, Himanshu G, Yachha SK, Aggarwal R and Choudhuri G: Clinical features and predictors of outcome in acute hepatitis A and hepatitis E virus hepatitis on cirrhosis. *Liver Int* 29: 392-398, 2009.
- Péron JM, Bureau C, Poirson H, Mansuy JM, Alric L, Selves J, Dupuis E, Izopet J and Vinel JP: Fulminant liver failure from acute autochthonous hepatitis E in France: Description of seven patients with acute hepatitis E and encephalopathy. *J Viral Hepat* 14: 298-303, 2007.
- Blasco-Perrin H, Madden RG, Stanley A, Crossan C, Hunter JG, Vine L, Lane K, Devooght-Johnson N, McLaughlin C, Petrik J, *et al*: Hepatitis E virus in patients with decompensated chronic liver disease: A prospective UK/French study. *Aliment Pharmacol Ther* 42: 574-581, 2015.
- Denner J, Pischke S, Steinmann E, Blümel J and Glebe D: Why all blood donations should be tested for hepatitis E virus (HEV). *BMC Infect Dis* 19: 541, 2019.
- Mizuo H, Suzuki K, Takikawa Y, Sugai Y, Tokita H, Akahane Y, Itoh K, Gotanda Y, Takahashi M, Nishizawa T and Okamoto H: Polyphyletic strains of hepatitis E virus are responsible for sporadic cases of acute hepatitis in Japan. *J Clin Microbiol* 40: 3209-3218, 2002.
- Takahashi M, Kusakai S, Mizuo H, Suzuki K, Fujimura K, Masuko K, Sugai Y, Aikawa T, Nishizawa T and Okamoto H: Simultaneous detection of immunoglobulin A (IgA) and IgM antibodies against hepatitis E virus (HEV) is highly specific for diagnosis of acute HEV infection. *J Clin Microbiol* 43: 49-56, 2005.
- Murton M, Goff-Leggett D, Bobrowska A, Sanchez JJ, James G, Wittbrodt E, Nolan S, Sörstadius E, Pecoits-Filho R and Tuttle K: Burden of chronic kidney disease by KDIGO categories of glomerular filtration rate and albuminuria: A systematic review. *Adv Ther* 38: 180-200, 2021.
- Ikegami C, Kanda T, Ishii T, Honda M, Yamana Y, Tanaka RS, Kumagawa M, Kanezawa S, Mizutani T, Yamagami H, *et al*: COVID-19 after treatment with direct-acting antivirals for HCV infection and decompensated cirrhosis: A case report. *In Vivo* 36: 1986-1993, 2022.
- Barbosa JV, Müllhaupt B, Brunner F, Sinnreich MF, Semela D, Montani M, Cathomas G, Neuweiler J, Gouttenoire J, Artru F, *et al*: Autochthonous hepatitis E as a cause of acute-on-chronic liver failure and death: Histopathology can be misleading but transaminases may provide a clue. *Swiss Med Wkly* 151: w20502, 2021.
- Inoue J, Takahashi M, Yazaki Y, Tsuda F and Okamoto H: Development and validation of an improved RT-PCR assay with nested universal primers for detection of hepatitis E virus strains with significant sequence divergence. *J Virol Methods* 137: 325-333, 2006.
- Hirano R, Kanda T, Honda M, Arima S, Totsuka M, Masuzaki R, Kanezawa S, Sasaki-Tanaka R, Matsumoto N, Yamagami H, *et al*: Hepatitis E virus infection caused elevation of alanine aminotransferase levels in a patient with chronic hepatitis B and cholelithiasis. *Reports* 6: 55, 2023.
- Miyoshi M, Kakinuma S, Tanabe Y, Ishii K, Li TC, Wakita T, Tsuura Y, Watanabe H, Asahina Y, Watanabe M and Ikeda T: Chronic hepatitis E infection in a persistently immunosuppressed patient unable to be eliminated after ribavirin therapy. *Intern Med* 55: 2811-2817, 2016.
- Frias M, López-López P, Rivero A and Rivero-Juarez A: Role of hepatitis E virus infection in acute-on-chronic liver failure. *Biomed Res Int* 2018: 9098535, 2018.

26. Choi JW, Son HJ, Lee SS, Jeon H, Cho JK, Kim HJ, Cha RR, Lee JM, Kim HJ, Jung WT and Lee OJ: Acute hepatitis E virus superinfection increases mortality in patients with cirrhosis. *BMC Infect Dis* 22: 62, 2022.
27. Zhao H, Ye W, Yu X, Hu J, Zhang X, Yang M, Sheng J and Shi Y: Hepatitis E virus superinfection impairs long-term outcome in hospitalized patients with hepatitis B virus-related decompensated liver cirrhosis. *Ann Hepatol* 28: 100878, 2023.
28. Saad MD, Hussein HA, Bashandy MM, Kamel HH, Earhart KC, Fryauff DJ, Younan M and Mohamed AH: Hepatitis E virus infection in work horses in Egypt. *Infect Genet Evol* 7: 368-373, 2007.
29. Zhang W, Shen Q, Mou J, Gong G, Yang Z, Cui L, Zhu J, Ju G and Hua X: Hepatitis E virus infection among domestic animals in eastern China. *Zoonoses Public Health* 55: 291-298, 2008.
30. Li Y, Qu C, Spee B, Zhang R, Penning LC, de Man RA, Peppelenbosch MP, Fieten H and Pan Q: Hepatitis E virus seroprevalence in pets in the Netherlands and the permissiveness of canine liver cells to the infection. *Ir Vet J* 73: 6, 2020.
31. Tsachev I, Gospodinova K, Pepovich R, Takova K, Kundurzhiev T, Zahmanova G, Kaneva K and Baymakova M: First insight into the seroepidemiology of hepatitis E Virus (HEV) in dogs, cats, horses, cattle, sheep, and goats from Bulgaria. *Viruses* 15: 1594, 2023.
32. Pischke S, Knoop EV, Mader M, Kling L, Wolski A, Wagner A, Mueller K, Horvatits T, Stiller J, Wisniewski K, *et al*: Anti-HEV seroprevalence and rate of viremia in a German cohort of dogs, cats, and horses. *Sci Rep* 13: 19240, 2023.
33. Lim KH, Howard M, Jackson N and Verma S: Long-term outcomes after hospitalization with spontaneous bacterial peritonitis. *BMJ Case Rep* 2014: bcr2013202561, 2014.
34. Fantilli A, Villa SD, Zerega A, Di Cola G, López L, Martínez MW, Pisano MB and Ré VE: Hepatitis E virus infection in a patient with alcohol related chronic liver disease: A case report of acute-on-chronic liver failure. *Virol J* 18: 245, 2021.
35. Inagaki K, Takaki S, Honda Y, Inoue M, Mori N, Kawakami H, Kawakami Y, Kawakami M, Okamoto H, Tuji K, *et al*: A case of hepatitis E virus infection in a patient with primary biliary cholangitis. *Kanzo* 58: 183-190, 2017 (In Japanese).
36. Okano H, Asakawa H, Tsuruga S, Nose K, Tochio T, Kumazawa H, Isono Y, Tanaka H, Matsusaki S, Sase T, *et al*: A fatal case of exacerbated liver cirrhosis caused by acute hepatitis E virus infection: Atypical dynamics of anti-hepatitis E virus antibody titers. *Kanzo* 61: 326-334, 2020 (In Japanese).
37. Kobayashi T, Tanaka S, Yokoyama T, Matsumoto S, Sarashina K and Kawahata S: A case of acute liver failure induced by hepatitis E virus in a patient with chronic alcoholic liver dysfunction. *Kanzo* 61: 376-381, 2020 (In Japanese).
38. Parfieniuk-Kowarda A, Jaroszewicz J, Łapiński TW, Łucejko M, Maciaszek M, Świdarska M, Grzeszczuk A, Naumnik B, Rowiński M and Flisiak R: High prevalence of anti-HEV antibodies among patients with immunosuppression and hepatic disorders in eastern Poland. *Arch Med Sci* 17: 675-681, 2018.
39. Fantilli AC, Trinks J, Marciano S, Zárate F, Balderramo DC, Wassaf MGM, Haddad L, Gadano A, Debes JD, Pisano MB and Ré VE: Unexpected high seroprevalence of hepatitis E virus in patients with alcohol-related cirrhosis. *PLoS One* 14: e0224404, 2019.
40. European Association for the Study of the Liver. Electronic address: easloffice@easloffice.; European Association for the Study of the Liver: EASL clinical practice guidelines on hepatitis E virus infection. *J Hepatol* 68: 1256-1271, 2018.
41. Nishiyama T, Kobayashi T, Jirintai S, Nagashima S, Primadharsini PP, Nishizawa T and Okamoto H: Antiviral candidates against the hepatitis E virus (HEV) and their combinations inhibit HEV growth in in vitro. *Antiviral Res* 170: 104570, 2019.
42. Primadharsini PP, Nagashima S, Nishiyama T, Takahashi M, Murata K and Okamoto H: Development of recombinant infectious hepatitis E virus harboring the nanoKAZ gene and its application in drug screening. *J Virol* 96: e0190621, 2022.



Copyright © 2024 Kanda et al. This work is licensed under a Creative Commons Attribution 4.0 International (CC BY 4.0) License.