

# Chemopreventive effect of saikosaponin-d on diethylnitrosamine-induced hepatocarcinogenesis: Involvement of CCAAT/enhancer binding protein $\beta$ and cyclooxygenase-2

XIN-LAN LU<sup>1</sup>, SHUI-XIANG HE<sup>1</sup>, MU-DAN REN<sup>1</sup>, YAN-LI WANG<sup>1</sup>, YA-XIN ZHANG<sup>1</sup> and EN-QI LIU<sup>2</sup>

<sup>1</sup>Department of Gastroenterology, The First Affiliated Hospital of Xi'an Jiaotong University;

<sup>2</sup>Laboratory Animal Center, Medical School of Xi'an Jiaotong University, Xi'an, Shaanxi 710061, P.R. China

Received July 10, 2011; Accepted December 6, 2011

DOI: 10.3892/mmr.2011.702

**Abstract.** Cyclooxygenase-2 (COX-2) and CCAAT/enhancer binding protein  $\beta$  (C/EBP $\beta$ ) have been shown to be involved in inflammation and carcinogenesis, and our previous study revealed that they were co-overexpressed in human hepatocellular carcinoma (HCC) tissue and a positive correlation was found. Saikosaponin-d (SSD), a triterpene saponin extracted from *Bupleurum falcatum* L. (Umbelliferae), is known to exert inhibitory effects on COX-2 expression, together with inflammation and hepatic fibrosis. These findings prompted us to investigate the chemopreventive potential of SSD against hepatocarcinogenesis and its possible molecular mechanism *in vivo*. An experimental model with diethylnitrosamine (DEN)-treated Sprague Dawley rats was used in the present study. DEN (50 mg/kg body weight) and SSD (2 mg/kg body weight) were intraperitoneally injected weekly and daily, respectively. Administration of SSD alone had no side effects. The liver nodule formation, tumorous invasion to surrounding organs and increased cellular atypia induced by DEN were markedly reduced by SSD in the SSD + DEN group compared with the DEN group. On the other hand, immunohistochemical staining demonstrated that the expression of COX-2 and C/EBP $\beta$  proteins was significantly increased in tumor cells and macrophages of liver tissue from DEN-treated rats, whereas the expression of the two proteins was markedly lowered in the SSD + DEN group. Overall, our results suggest that SSD prevents DEN-induced hepatocarcinogenesis in rats through inhibition of C/EBP $\beta$  and COX-2, providing indispensable

experimental evidence for the clinical application of SSD as a novel chemopreventive agent against HCC in the future.

## Introduction

Hepatocellular carcinoma (HCC) is a common human malignant disease, accounting for 748,300 new cases and 695,900 deaths worldwide in 2008 (1). Although approaches such as surgery and radiochemotherapy have been established for treatment, the high incidence, quick progression and poor prognosis of HCC still remain as critical issues leading to high cost and mortality (2). Thus, the exact molecular mechanisms underlying hepatocarcinogenesis and potent preventive agents require urgent investigation.

A variety of risk factors such as chronic hepatitis virus infection, chemical carcinogen exposure and obesity have been thought to foster hepatocarcinogenesis (3). Additionally, HCC is known to be an inflammation-related malignancy, which is attributed to the above-mentioned risk factors. Cyclooxygenase-2 (COX-2), a rate-limiting enzyme in the production of prostaglandins, is usually induced by stimuli involved in inflammatory responses and has been shown to be associated with carcinogenesis and tumor progression (4,5). Various HCC-related molecules such as hepatitis B virus X protein (6), hepatitis C virus (7) and diethylnitrosamine (DEN) (8), have been reported to induce the expression of COX-2, which finally facilitates hepatocarcinogenesis and cancer progression. Moreover, studies have revealed that COX-2 overexpression is present in well-differentiated HCC and is an early event in the process of hepatocarcinogenesis (9,10). Deregulation of the COX-2 signaling pathway serves as a basis for designing novel-targeted therapeutic strategies for cancer therapy. Consequently, a variety of anti-inflammatory drugs targeting COX-2 have been demonstrated to exert strong chemopreventive capabilities in various types of cancers including tongue carcinoma (11), mammary carcinoma (12) and HCC (13).

In recent years, the importance of the transcription factor CCAAT/enhancer binding protein  $\beta$  (C/EBP $\beta$ ) in promoting tumorigenesis and regulating COX-2 expression has been

**Correspondence to:** Dr Shui-Xiang He, Department of Gastroenterology, The First Affiliated Hospital of Xi'an Jiaotong University, No. 277 Yanta West Road, Xi'an, Shaanxi 710061, P.R. China  
E-mail: hesx123@126.com

**Key words:** cyclooxygenase-2, CCAAT/enhancer binding protein  $\beta$ , saikosaponin-d, hepatocellular carcinoma, diethylnitrosamine

recognized. C/EBP $\beta$  belongs to a basic-leucine zipper transcription factor family and plays multiple roles in the control of inflammation, cellular proliferation, survival and differentiation, and tumorigenesis (14-17). Recent evidence indicates that C/EBP $\beta$  is critical for carcinogen- and oncogene-mediated cell transformation (18,19). Furthermore, C/EBP $\beta$  activation is indispensable to liver proliferation and fibrosis (20-22).

C/EBP $\beta$  is one of the regulators implicated in COX-2 expression (23), and the two proteins are co-overexpressed in gastric carcinomas and play a crucial role in gastric tumorigenesis (24). HBV has been also reported to induce COX-2 expression by recruitment of C/EBP $\beta$  to the promoter (25). Furthermore, anti-inflammatory drugs such as salicylate suppress COX-2 expression via inhibition of C/EBP $\beta$  binding to the COX-2 promoter (26,27). Overall, these findings suggest a vital role of C/EBP $\beta$ /COX-2 in carcinogenesis, and render the two molecules as potential targets for the intervention of cancer by chemopreventive or chemotherapeutic agents.

Saikosaponin-d (SSD) is a triterpene saponin extracted from *Bupleurum falcatum* L. (Umbelliferae), a herb used to cure chronic liver diseases in traditional Chinese medicine (28). SSD exhibits multiple pharmacological activities including anti-inflammatory and anti-cancer effects (29-31). It has been shown that SSD reduces phorbol 12-myristate 13-acetate (PMA)-induced inflammation *in vivo* and COX-2 and lipoxygenase production *in vitro* (31). Moreover, SSD has been reported to attenuate toxin-induced hepatocyte injury and hepatic fibrosis in animal models through the inhibition of several types of inflammatory mediators (32,33). Our previous studies revealed that C/EBP $\beta$  and COX-2 were overexpressed in human HCC tissues and a positive correlation was found (34). We also found that SSD inhibited lipopolysaccharide-induced COX-2 expression in the HCC SMMC-7721 cell line *in vitro* (35).

However, to date, the effects of SSD on hepatocarcinogenesis and C/EBP $\beta$  and COX-2 expression *in vivo*, have not been clearly analyzed. To evaluate these, a DEN-induced model in rats was used, since weekly DEN injections efficiently promote hepatocarcinogenesis, which mimics the genetic process of human HCC (36). In this study, we determined that SSD chemoprevented hepatocarcinogenesis through inhibition of C/EBP $\beta$  and COX-2 expression.

## Materials and methods

**Reagents and chemicals.** SSD ( $\geq 98\%$  pure) was obtained from Jiangxi Herbfine Hi-Tech Co., Ltd. (China). DEN was purchased from Sigma Chemical Co. (St. Louis, MO). Rabbit polyclonal antibody against C/EBP $\beta$  and goat polyclonal antibody against COX-2 were both purchased from Santa Cruz Biotechnology (Santa Cruz, CA). All other chemicals were of the highest quality available and were obtained from authentic sources.

**Experimental animals.** Eight-week-old male Sprague Dawley rats weighing 180-200 g were obtained from the Laboratory Animal Centre of Xian Jiaotong University. All housing and animal procedures were carried out in accordance with the NIH Guidelines on the Use of Laboratory Animals. Animal

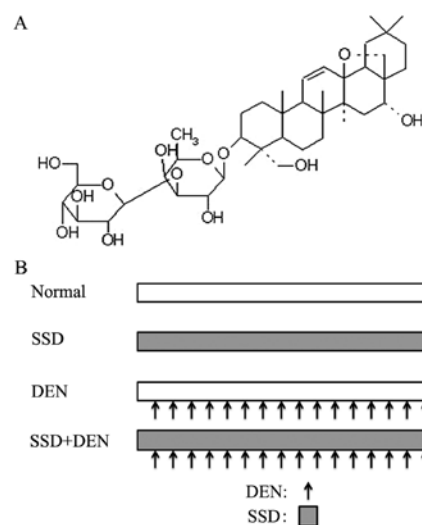


Figure 1. (A) Chemical structure of Saikosaponin-d (SSD). (B) Experimental design for the chemopreventive effect of SSD against hepatocarcinogenesis. Arrow assessins indicates administration with intraperitoneal injection of DEN at a dose of 50 mg/kg body weight weekly; grey rectangle indicates administration with intraperitoneal injection of SSD at a dose of 2 mg/kg body weight daily.

care and protocols were approved by the Institutional Animal Care and Use Committee of Xi'an Jiaotong University.

**Experimental design.** Fifty rats were randomly assigned into 4 experimental groups: normal group (n=10), rats were used as controls without any additional treatment; DEN group (n=15), rats received weekly intraperitoneal (i.p.) injections of DEN at a dose of 50 mg/kg body weight for 16 weeks; SSD + DEN group (n=15), rats received daily i.p. injections of SSD at a dose of 2 mg/kg body weight, starting 1 week before DEN induction and lasting until the termination of experiments; SSD group (n=10), rats received SSD alone at the same dose and duration as the SSD + DEN group. All rats were anaesthetized with sodium pentothal and were then sacrificed at the end of week 16 (timing from DEN administration). The number of tumors (whitish nodules,  $>3$  mm in diameter) at the liver surface was estimated (37). The livers were removed immediately and fixed in 4% paraformaldehyde.

**Histology and immunohistochemistry.** Paraformaldehyde-fixed tissues were embedded in paraffin blocks and cut into 4- $\mu$ m sections. The sections were used for haematoxylin and eosin (H&E) staining according to conventional procedures.

Immunohistochemistry was conducted using a Dako Autostainer Plus system (Dako Corporation, Carpinteria, CA) as described previously (38). Briefly, sections were dewaxed, rehydrated and subjected to 5 min of antigen retrieval by pressure cooking, followed by blocking of endogenous enzyme and nonspecific antigens for 15 min. The sections were incubated with specific primary antibodies to C/EBP $\beta$  (1:150 dilution) and COX-2 (1:100 dilution) for 60 min, and then incubation with DakoCytomation EnVision+ System-HRP reagent for the rabbit antibody for 30 min or incubation with biotinylated link for 15 min followed by a 15-min streptavidin-HRP incuba-

Table I. Effect of DEN and SSD treatment on body and liver weight.

Group	No. of rats	Body weight (g)	Liver weight (g)	Ratio (%) of liver to body weight
Normal	10	315±6.57	11.9±0.975	3.8±0.38
SSD	10	311±11.95	11.8±1.26	3.8±0.29
DEN	15	346±5.51 <sup>a</sup>	17.6±1.49 <sup>a</sup>	5.1±0.43 <sup>a</sup>
SSD + DEN	15	321±11.10 <sup>b</sup>	12.7±0.87 <sup>b</sup>	4.0±0.28 <sup>b</sup>

Data are expressed as the means ± SD; P<0.05 compared with <sup>a</sup>normal group or <sup>b</sup>DEN-treated group.

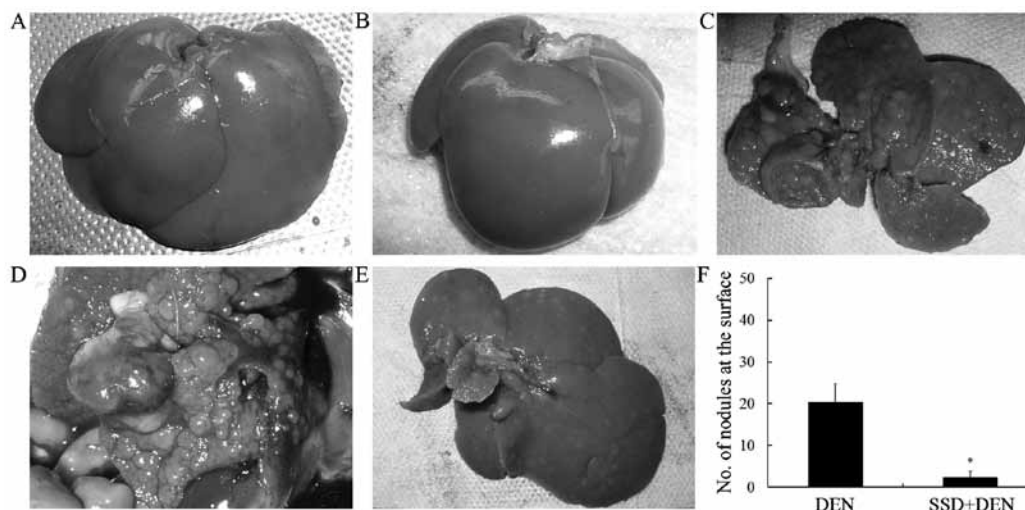


Figure 2. Macroscopic appearance of rat livers after treatment with DEN or SSD + DEN. Normal gross appearance of the liver from the (A) normal and (B) SSD groups. (C) Liver with multiple whitish, dyschromic nodules at the liver surface and tumor invasion to colon from DEN group. (D) Liver with tumorous invasion to blood vessel from the DEN group. (E) Liver with fewer and smaller nodules from the SSD + DEN group. (F) Number of nodules (>3 mm) at the liver surface of individual animals in the DEN and SSD + DEN groups. Data are expressed as means ± SD. \*P<0.05 compared with the DEN-treated group.

tion for goat antibody. This was followed by incubation with diaminobenzidine (DAB) in a dark room. The sections were then counterstained with hematoxylin followed by dehydration. Sections incubated with PBS without the primary antibody were used as negative controls. All of the stained sections were reviewed in a blinded manner by two pathologists using light microscopy. The results were assessed using the average percentage of positive cells (No. of positive cells × 100/total no. of cells) in 5 different random microscopic fields (×400) in each slice.

**Statistical analysis.** Data are presented as the means ± SD. Statistical significance was determined using one-way ANOVA or Student's t-test (SPSS 16.0 for windows). Significance was accepted at the level of P<0.05.

## Results

**Effects of SSD on hepatocarcinogenesis and tumor development in DEN-treated rats.** To determine the chemopreventive effects of SSD against hepatocarcinogenesis in rats, SSD was administered starting 1 week before induction of DEN and lasting until the end of the experiments (Fig. 1).

As shown in Table I, administration of DEN markedly caused hepatomegaly, while SSD treatment led to a significant reduction in liver weight and the liver to body weight ratio in the SSD + DEN-treated rats (P<0.05). No mortality or adverse effects suggestive of toxicity of SSD was observed in the SSD group.

Macroscopically, no nodules or additional abnormalities were found in the livers of the normal (Fig. 2A) and SSD (Fig. 2B) groups. As shown in Fig. 2C and D, in the DEN group, irregular appearing livers with cirrhosis and multiple whitish nodules distributed on the surface (15 of 15), were noted, and invasion to surrounding organs including colon and blood vessel (3 of 15; 20%) were visibly observed. In the SSD + DEN group, 2 of 15 animals (13.3%) were observed to have no nodules, while the other rats in this group were found to have less tumors and reduced tumor size (Fig. 2E). The number of nodules (>3 mm in diameter) over the liver surface in the SSD + DEN group was significantly less than that in the DEN group (Fig. 2F). No invasion to surrounding tissues was observed in the SSD + DEN group.

Hepatic histopathology from the various groups of rats was examined by H&E staining. Microscopically, the hepatic sections from the normal and SSD-treated animals



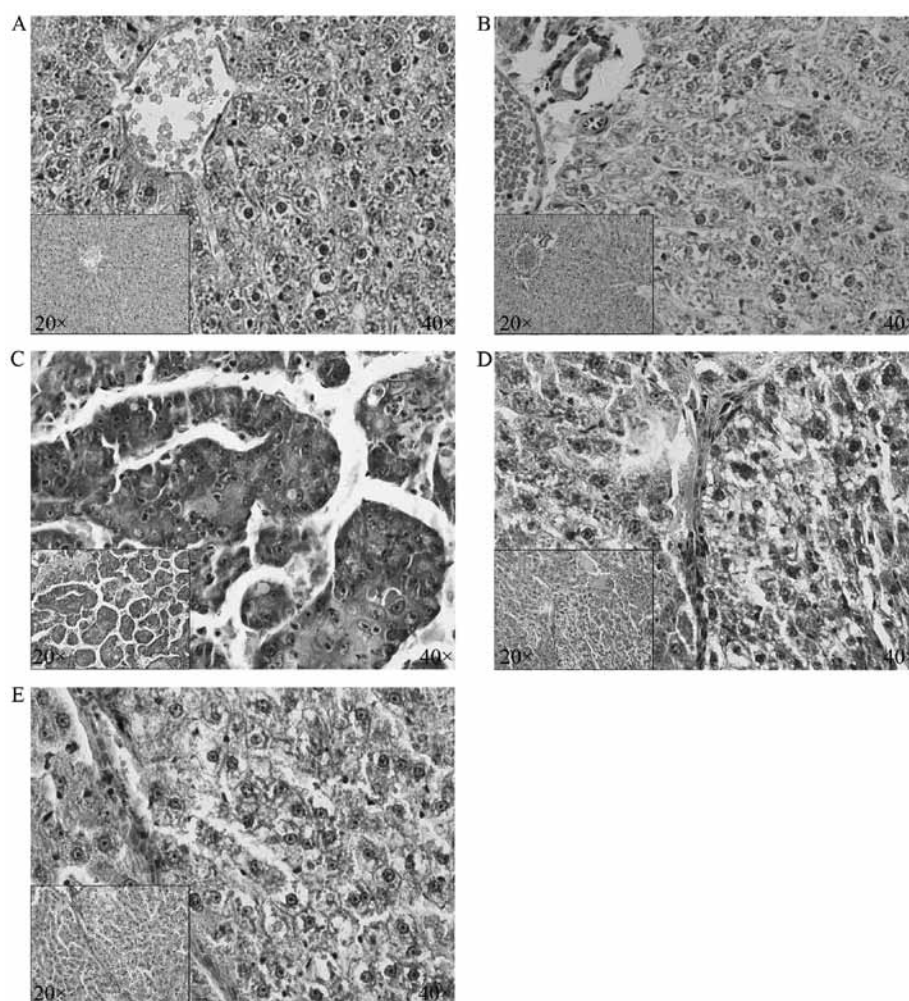


Figure 3. Histology of the livers in each group characterized by H&E staining. (A) Hepatic tissue from the normal group with normal hepatic lobules. (B) Liver with normal architecture from the SSD group. (C) Section of DEN-treated liver showing fibrosis and neoplastic lesions. (D) Section of SSD + DEN-treated liver with reduced number and size of neoplastic lesions. (E) Section of SSD + DEN-treated liver with pseudolobule and fibrosis but no malignant cells (magnification, x40; inserts, x20).

revealed normal liver parenchyma characterized by typical hepatic lobules and small uniform nuclei (Fig. 3A and B). However, as shown in Fig. 3C, liver tissue samples from the DEN group exhibited disordered architecture with a large number of pseudolobules, collagen deposition, infiltration of inflammatory cells, and abnormal cells with irregular-shaped cytoplasm and enlarged hyperchromatic nuclei, and these HCC cells generally tended to be moderately differentiated. In the SSD + DEN group, the hepatic pathological lesions with pseudolobules, fibrosis, inflammatory cell infiltration and cellular atypia were markedly improved compared with the DEN group, and the tumors in the SSD + DEN group were histologically well-differentiated (Fig. 3D and E).

**Effects of SSD on DEN-induced intracellular expression of COX-2 and C/EBP $\beta$  proteins.** Since chemopreventive effects of SSD against hepatocarcinogenesis in rats was observed, the possible molecular mechanisms were then explored. The expression levels of COX-2 and C/EBP $\beta$  proteins in tissue specimens were examined by immunohistochemical staining.

COX-2 expression was merely detectable in minor hepatocytes in normal hepatic tissue from the normal and SSD

groups (Fig. 4A and B). In contrast, an increased number of elevated positive cells (HCC cells and macrophages) in the DEN-induced tumor tissue were clearly observed (Fig. 4C), whereas SSD markedly suppressed COX-2 expression in the tumorous and non-tumorous tissues from the SSD + DEN group (Fig. 4D and E). As shown in Fig. 4F, a decreased number of COX-2 positive cells was observed in the SSD + DEN group.

Immunohistochemistry revealed the absence of C/EBP $\beta$  expression in the normal liver tissues from the normal and SSD groups (Fig. 5A and B), while hepatic tissue from the DEN-treated group showed markedly strong staining of C/EBP $\beta$  in tumor cells and macrophages (Fig. 5C). Both the tumorous and non-tumorous tissues from the SSD + DEN-treated group showed significantly lower expression of C/EBP $\beta$  protein compared with the DEN group (Fig. 5D and E). Additionally, a decreased number of C/EBP $\beta$ -positive cells was observed in the SSD + DEN group (Fig. 5F).

## Discussion

The goals of the present study were to show the *in vivo* chemopreventive effects of SSD on hepatocarcinogenesis and to

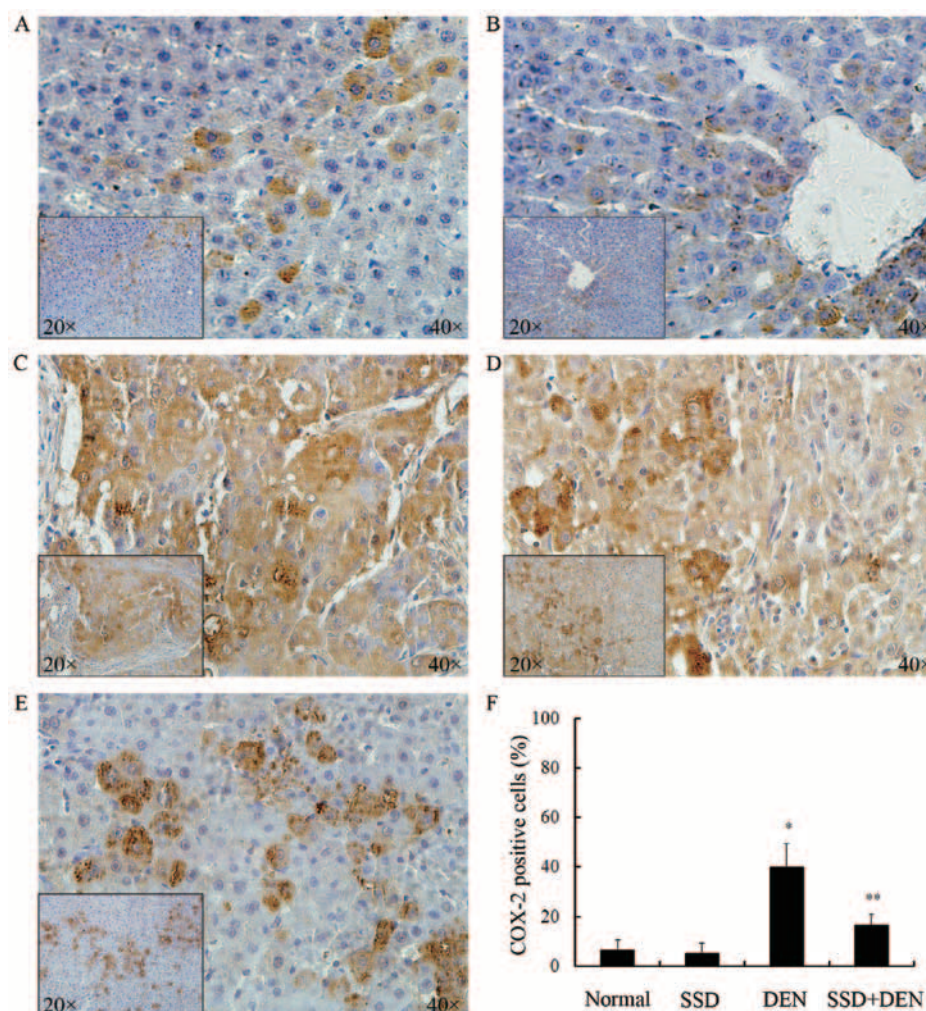


Figure 4. Immunohistochemical staining for the COX-2 protein. (A) Normal liver tissue with few COX-2-positive cells from the normal group. (B) Normal liver tissue with few COX-2-positive cells from the SSD group. (C) Hepatocarcinoma tissue from DEN-treated rats with strong positivity of COX-2 protein. (D) Moderate positivity of COX-2 staining in tumorous and non-tumorous tissue from the SSD + DEN group. (E) Weak COX-2 immunopositivity in hepatic tissues without tumors from the SSD + DEN group. (F) Statistical analysis of COX-2-positive cells in the various groups. Data are expressed as means  $\pm$  SD;  $P < 0.05$  compared with the \*normal or \*\*DEN-treated group.

elucidate the novel underlying mechanisms of the action. We demonstrated that SSD suppressed hepatocarcinogenesis and the overexpression of C/EBP $\beta$  and COX-2 induced by DEN. To the best of our knowledge, this is the first report on the effects of SSD on hepatocarcinogenesis involving regulation of C/EBP $\beta$  and COX-2.

The molecular mechanisms of HCC formation and effective approaches to prevent HCC still remain poorly defined. In recent years, studies have emphasized the potential role of COX-2 in linking chronic inflammation with carcinogenesis and progression in various cancer types (4). It has been shown that COX-2 plays crucial roles in fibrogenesis and hepatocarcinogenesis (9,39). In the present study, the increase in COX-2 expression was observed in DEN-induced HCC tissues in rats, consistent with a recent report (8). These results suggest that, under some conditions, COX-2 overexpression promotes hepatocarcinogenesis.

As an upstream regulator of the COX-2 gene, the transcription factor C/EBP $\beta$  is significantly elevated in colorectal tumors and is associated with human ovarian epithelial tumor progression, suggesting that C/EBP $\beta$  may be involved in

tumorigenesis and cancer development (40,41). Bundy and Sealy identified the role of C/EBP $\beta$  in carcinogenesis by evidence that the human breast epithelial cell line MCF10A overexpressing C/EBP $\beta$  acquired malignant phenotypes including anchorage-independent growth, colony formation in soft agar and invasion (42). Zhu *et al* demonstrated that C/EBP $\beta$ -null mice are completely refractory to skin tumor formation induced by a variety of carcinogens which produce tumors containing oncogenic Ras mutations, and that C/EBP $\beta$  participated in Ras-induced transformation of NIH 3T3 fibroblasts (16). In Ras-transformed MCF10A cells, C/EBP $\beta$  suppressed expression of tumor suppressor Siglemined-2, which has been found to inhibit malignant transformation of mammary ductal cells (19). Thus, C/EBP $\beta$  is downstream of the Ras signaling pathway and is required for Ras-induced malignant transformation. A recent study found elevated Ras activity in DEN-induced hepatocarcinogenesis (37), which may explain our finding that C/EBP $\beta$  expression was significantly increased in hepatic tumor tissue from DEN-treated rats. Moreover, C/EBP $\beta$  has been shown to be essential for TGF $\alpha$ -stimulated proliferation



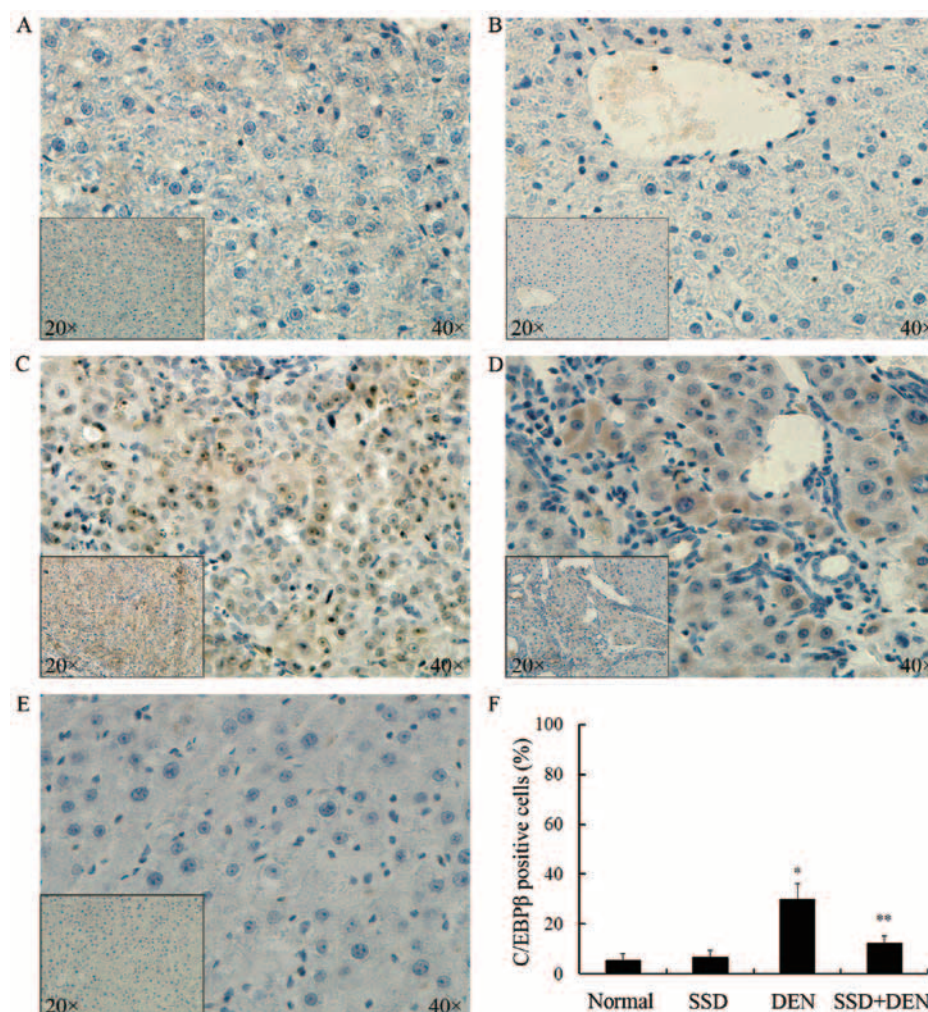


Figure 5. Immunohistochemical staining for C/EBP $\beta$  protein. (A) Normal liver tissue with C/EBP $\beta$  negativity from the normal group. (B) Normal liver tissue with lack of C/EBP $\beta$  staining from the SSD group. (C) Strong nuclear staining in the tumors from DEN-treated rats. (D) Moderate cytoplasmic and nuclear staining in tumorous and non-tumorous tissue from the SSD + DEN group. (E) Weak immunoreactivity in hepatic tissues without tumors from the SSD + DEN group. (F) Statistical analysis of C/EBP $\beta$ -positive cells in the various groups. Data are expressed as means  $\pm$  SD;  $P < 0.05$  compared with the \*normal or \*\*DEN-treated group.

of murine hepatocytes and CCl<sub>4</sub>-induced liver fibrosis and regeneration (precursors to HCC) (22), which supports our hypothesis that C/EBP $\beta$  is involved in hepatocarcinogenesis.

Activation of C/EBP $\beta$  is crucial for the initial induction of COX-2 by growth factors, tumor promoters, cytokines and other inflammatory mediators in various types of cells (43,44). Further study revealed that C/EBP $\beta$  and COX-2 showed overlapping overexpression in gastric carcinomas and that C/EBP $\beta$  has the potential to mediate gastric carcinogenesis via the regulation of COX-2 expression (24). In human prostate tissues, the expression of C/EBP $\beta$  and COX-2 was highly correlated and was involved in chronic inflammation and prostate cancer development (45). Our previous study demonstrated that C/EBP $\beta$  overexpression was correlated with COX-2 overexpression in human HCC tissue (34). All of these investigations provide evidences for our present finding that C/EBP $\beta$  and COX-2 are relatedly overexpressed in rat liver tumors induced by DEN, although double immunostaining to define the precise co-expression was not carried out. Moreover, our *in vitro* study showed that lysophosphatidic acid (LPA), a growth factor-like phospholipid, potently stimulated the cell proliferation and cell

cycle progression of human hepatocarcinoma SMMC-7721 cells through induction of C/EBP $\beta$  and COX-2 expression (data not shown). Given the drastic and invariable roles of C/EBP $\beta$  and COX-2 in liver fibrogenesis and carcinogenesis, potential drugs targeting these molecules may have preventive effects against liver fibrogenesis and tumorigenesis (22,46).

Previous *in vivo* studies have reported that SSD exerted hepatoprotective effects and attenuated toxin-induced liver fibrosis, due to the downregulation of pro-inflammatory cytokines such as TNF- $\alpha$ , IL-6 and TGF- $\beta$ 1 (32,33). In other words, the therapeutic effects of SSD on liver fibrosis and cirrhosis may be attributed to its anti-inflammatory pharmacological activity. At the cellular and molecular level, it has been reported that SSD suppresses T cell activity through inhibition of the NF- $\kappa$ B signaling pathway and COX-2 expression (31,47). Since SSD inhibits COX-2 activity, chronic inflammation, liver fibrosis and cirrhosis, which are relevant to HCC, it is reasonable to characterize SSD as a potential chemopreventive or chemotherapeutic agent against hepatocarcinogenesis. In this study, we found that SSD administration significantly inhibited liver inflammation, fibrosis and

tumor formation and invasion in rats in comparison to those administered DEN only, suggesting that SSD plays roles in inhibiting HCC in both the early and late stages. Since C/EBP $\beta$  and COX-2 play key roles in inflammation, hepatic fibrosis and tumorigenesis, we determined the effect of SSD on expression of these two proteins. As expected, SSD markedly reduced DEN-induced activity of C/EBP $\beta$  and COX-2. Additionally, we found that SSD inhibited LPA-stimulated proliferation of hepatocarcinoma cells by suppression of C/EBP $\beta$  and COX-2 expression (data not shown). Thus, it can be inferred from our finding that SSD-mediated downregulation of C/EBP $\beta$  and COX-2 may be one of the mechanisms by which SSD chemoprevents DEN-induced hepatocarcinogenesis in rats. However, further studies are needed to define the molecular mechanisms.

In conclusion, using a DEN-induced rat HCC model, we reported that SSD prevents hepatocarcinogenesis through inhibition of C/EBP $\beta$  and COX-2. Our findings may provide important insights into the mechanism of HCC and indispensable experimental evidence for the clinical application of SSD in the future.

## Acknowledgements

This study was supported by the National Natural Science Foundation of China (no. 30771895).

## References

- Jemal A, Bray F, Center MM, Ferlay J, Ward E and Forman D: Global cancer statistics. *CA Cancer J Clin* 61: 69-90, 2011.
- Villanueva A and Llovet JM: Targeted therapies for hepatocellular carcinoma. *Gastroenterology* 140: 1410-1426, 2011.
- Sherman M: Hepatocellular carcinoma: New and emerging risks. *Dig Liver Dis* 42: S215-S222, 2010.
- Williams CS, Mann M and DuBois RN: The role of cyclooxygenases in inflammation, cancer, and development. *Oncogene* 18: 7908-7916, 1999.
- Colby JK, Klein RD, McArthur MJ, *et al*: Progressive metaplastic and dysplastic changes in mouse pancreas induced by cyclooxygenase-2 overexpression. *Neoplasia* 10: 782-796, 2008.
- Lara-Pezzi E, Gomez-Gavero MV, Galvez BG, *et al*: The hepatitis B virus X protein promotes tumor cell invasion by inducing membrane-type matrix metalloproteinase-1 and cyclooxygenase-2 expression. *J Clin Invest* 110: 1831-1838, 2002.
- Rahman MA, Dhar DK, Yamaguchi E, *et al*: Coexpression of inducible nitric oxide synthase and COX-2 in hepatocellular carcinoma and surrounding liver: possible involvement of COX-2 in the angiogenesis of hepatitis C virus-positive cases. *Clin Cancer Res* 7: 1325-1332, 2001.
- Sivaramakrishnan V and Niranjali Devaraz S: Morin regulates the expression of NF-kappaB-p65, COX-2 and matrix metalloproteinases in diethylnitrosamine induced rat hepatocellular carcinoma. *Chem Biol Interact* 180: 353-359, 2009.
- Giannitrapani L, Ingrao S, Soresi M, *et al*: Cyclooxygenase-2 expression in chronic liver diseases and hepatocellular carcinoma: an immunohistochemical study. *Ann NY Acad Sci* 1155: 293-299, 2009.
- Koga H, Sakisaka S, Ohishi M, *et al*: Expression of cyclooxygenase-2 in human hepatocellular carcinoma: relevance to tumor dedifferentiation. *Hepatology* 29: 688-696, 1999.
- Yoshida K, Tanaka T, Kohno H, *et al*: A COX-2 inhibitor, nimesulide, inhibits chemically-induced rat tongue carcinogenesis through suppression of cell proliferation activity and COX-2 and iNOS expression. *Histol Histopathol* 18: 39-48, 2003.
- Banerjee S, Bueso-Ramos C and Aggarwal BB: Suppression of 7,12-dimethylbenz(a)anthracene-induced mammary carcinogenesis in rats by resveratrol: role of nuclear factor-kappaB, cyclooxygenase 2, and matrix metalloproteinase 9. *Cancer Res* 62: 4945-4954, 2002.
- Nagahara T, Okano J, Fujise Y, Abe R and Murawaki Y: Preventive effect of JTE-522, a selective cyclooxygenase-2 inhibitor, on DEN-induced hepatocarcinogenesis in rats. *Biomed Pharmacother* 64: 319-326, 2010.
- Ramji DP and Foka P: CCAAT/enhancer-binding proteins: structure, function and regulation. *Biochem J* 365: 561-575, 2002.
- Pal R, Janz M, Galson DL, *et al*: C/EBPbeta regulates transcription factors critical for proliferation and survival of multiple myeloma cells. *Blood* 114: 3890-3898, 2009.
- Zhu S, Yoon K, Sterneck E, Johnson PF and Smart RC: CCAAT/enhancer binding protein-beta is a mediator of keratinocyte survival and skin tumorigenesis involving oncogenic Ras signaling. *Proc Natl Acad Sci USA* 99: 207-212, 2002.
- Buck M, Poli V, Hunter T and Chojkier M: C/EBPbeta phosphorylation by RSK creates a functional XEXD caspase inhibitory box critical for cell survival. *Mol Cell* 8: 807-816, 2001.
- Connors SK, Balusu R, Kundu CN, Jaiswal AS, Gairola CG and Narayan S: C/EBPbeta-mediated transcriptional regulation of bcl-xL gene expression in human breast epithelial cells in response to cigarette smoke condensate. *Oncogene* 28: 921-932, 2009.
- Gustafson TL, Wellberg E, Laffin B, *et al*: Ha-Ras transformation of MCF10A cells leads to repression of Single-minded-2s through NOTCH and C/EBPbeta. *Oncogene* 28: 1561-1568, 2009.
- Luedde T, Duderstadt M, Streetz KL, *et al*: C/EBP beta isoforms LIP and LAP modulate progression of the cell cycle in the regenerating mouse liver. *Hepatology* 40: 356-365, 2004.
- Buck M, Poli V, van der Geer P, Chojkier M and Hunter T: Phosphorylation of rat serine 105 or mouse threonine 217 in C/EBP beta is required for hepatocyte proliferation induced by TGF alpha. *Mol Cell* 4: 1087-1092, 1999.
- Buck M and Chojkier M: A ribosomal S-6 kinase-mediated signal to C/EBP-beta is critical for the development of liver fibrosis. *PLoS One* 2: e1372, 2007.
- Gorgoni B, Caivano M, Arizmendi C and Poli V: The transcription factor C/EBPbeta is essential for inducible expression of the cox-2 gene in macrophages but not in fibroblasts. *J Biol Chem* 276: 40769-40777, 2001.
- Regalo G, Canedo P, Suriano G, *et al*: C/EBPbeta is over-expressed in gastric carcinogenesis and is associated with COX-2 expression. *J Pathol* 210: 398-404, 2006.
- Yue X, Yang F, Yang Y, *et al*: Induction of cyclooxygenase-2 expression by hepatitis B virus depends on demethylation-associated recruitment of transcription factors to the promoter. *Virol J* 8: 118, 2011.
- Cieslik K, Zhu Y and Wu KK: Salicylate suppresses macrophage nitric-oxide synthase-2 and cyclo-oxygenase-2 expression by inhibiting CCAAT/enhancer-binding protein-beta binding via a common signaling pathway. *J Biol Chem* 277: 49304-49310, 2002.
- Saunders MA, Sansores-Garcia L, Gilroy DW and Wu KK: Selective suppression of CCAAT/enhancer-binding protein beta binding and cyclooxygenase-2 promoter activity by sodium salicylate in quiescent human fibroblasts. *J Biol Chem* 276: 18897-18904, 2001.
- Guinea MC, Parellada J, Lacaille-Dubois MA and Wagner H: Biologically active triterpene saponins from *Bupleurum fruticosum*. *Planta Med* 60: 163-167, 1994.
- Hsu YL, Kuo PL and Lin CC: The proliferative inhibition and apoptotic mechanism of Saikosaponin D in human non-small cell lung cancer A549 cells. *Life Sci* 75: 1231-1242, 2004.
- Hsu YL, Kuo PL, Chiang LC and Lin CC: Involvement of p53, nuclear factor kappaB and Fas/Fas ligand in induction of apoptosis and cell cycle arrest by saikosaponin d in human hepatoma cell lines. *Cancer Lett* 213: 213-221, 2004.
- Bermejo Benito P, Abad Martinez MJ, Silvan Sen AM, *et al*: In vivo and in vitro antiinflammatory activity of saikosaponins. *Life Sci* 63: 1147-1156, 1998.
- Fan J, Li X, Li P, *et al*: Saikosaponin-d attenuates the development of liver fibrosis by preventing hepatocyte injury. *Biochem Cell Biol* 85: 189-195, 2007.
- Dang SS, Wang BF, Cheng YA, Song P, Liu ZG and Li ZF: Inhibitory effects of saikosaponin-d on CCl<sub>4</sub>-induced hepatic fibrogenesis in rats. *World J Gastroenterol* 13: 557-563, 2007.
- Liang X, Hu YN, He SX, *et al*: Significance of COX-2 and C/EBP $\beta$  expression in hepatocellular carcinoma. *World Chin J Digestol* 18: 3040-3044, 2010.
- He SX, Luo JY, Zhao G, *et al*: Effect of saikosaponins-d on cyclooxygenase-2 expression of human hepatocellular carcinoma cell line SMMC-7721. *Zhonghua Gan Zang Bing Za Zhi* 14: 712-714, 2006 (In Chinese).

36. Newell P, Villanueva A, Friedman SL, Koike K and Llovet JM: Experimental models of hepatocellular carcinoma. *J Hepatol* 48: 858-879, 2008.
37. Schneider-Merck T, Borbath I, Charette N, *et al*: The Ras inhibitor farnesylthiosalicylic acid (FTS) prevents nodule formation and development of preneoplastic foci of altered hepatocytes in rats. *Eur J Cancer* 45: 2050-2060, 2009.
38. Zeng J, Sun Y, Wu K, *et al*: Chemopreventive and chemotherapeutic effects of intravesical silibinin against bladder cancer by acting on mitochondria. *Mol Cancer Ther* 10: 104-116, 2011.
39. Yu J, Wu CW, Chu ES, *et al*: Elucidation of the role of COX-2 in liver fibrogenesis using transgenic mice. *Biochem Biophys Res Commun* 372: 571-577, 2008.
40. Rask K, Thorn M, Ponten F, *et al*: Increased expression of the transcription factors CCAAT-enhancer binding protein-beta (C/EBPbeta) and C/EBZeta (CHOP) correlate with invasiveness of human colorectal cancer. *Int J Cancer* 86: 337-343, 2000.
41. Sundfeldt K, Ivarsson K, Carlsson M, *et al*: The expression of CCAAT/enhancer binding protein (C/EBP) in the human ovary in vivo: specific increase in C/EBPbeta during epithelial tumour progression. *Br J Cancer* 79: 1240-1248, 1999.
42. Bundy LM and Sealy L: CCAAT/enhancer binding protein beta (C/EBPbeta)-2 transforms normal mammary epithelial cells and induces epithelial to mesenchymal transition in culture. *Oncogene* 22: 869-883, 2003.
43. Thomas B, Berenbaum F, Humbert L, *et al*: Critical role of C/EBPdelta and C/EBPbeta factors in the stimulation of the cyclooxygenase-2 gene transcription by interleukin-1beta in articular chondrocytes. *Eur J Biochem* 267: 6798-6809, 2000.
44. Wu KK, Liou JY and Cieslik K: Transcriptional control of COX-2 via C/EBPbeta. *Arterioscler Thromb Vasc Biol* 25: 679-685, 2005.
45. Wang W, Bergh A and Damber JE: Increased expression of CCAAT/enhancer-binding protein beta in proliferative inflammatory atrophy of the prostate: relation with the expression of COX-2, the androgen receptor, and presence of focal chronic inflammation. *Prostate* 67: 1238-1246, 2007.
46. Breinig M, Schirmacher P and Kern MA: Cyclooxygenase-2 (COX-2)-a therapeutic target in liver cancer? *Curr Pharm Des* 13: 3305-3315, 2007.
47. Wong VK, Zhou H, Cheung SS, Li T and Liu L: Mechanistic study of saikosaponin-d (Ssd) on suppression of murine T lymphocyte activation. *J Cell Biochem* 107: 303-315, 2009.