

Network centrality in patients with acute unilateral open globe injury: A voxel-wise degree centrality study

HUA WANG¹, TING CHEN¹, LEI YE², QI-CHEN YANG³, RONG WEI²,
YING ZHANG², NAN JIANG² and YI SHAO^{1,2}

¹Department of Ophthalmology, Xiangya Hospital, Central South University, Changsha, Hunan 410008;

²Department of Ophthalmology, The First Affiliated Hospital of Nanchang University, Jiangxi Province Clinical Ophthalmology Institute and Oculopathy Research Centre, Nanchang, Jiangxi 330006; ³Eye Institute of Xiamen University, Fujian Provincial Key Laboratory of Ophthalmology and Visual Science, Xiamen, Fujian 361102, P.R. China

Received January 12, 2017; Accepted August 1, 2017

DOI: 10.3892/mmr.2017.7635

Abstract. The present study aimed to investigate functional networks underlying brain-activity alterations in patients with acute unilateral open globe injury (OGI) and associations with their clinical features using the voxel-wise degree centrality (DC) method. In total, 18 patients with acute OGI (16 males and 2 females), and 18 healthy subjects (16 males and 2 females), closely matched in age, sex and education, participated in the present study. Each subject underwent a resting-state functional magnetic resonance imaging scan. The DC method was used to assess local features of spontaneous brain activity. Receiver operating characteristic curve analysis was used to distinguish OGIs from healthy controls (HCs). Correlation analysis was used to examine the association between the observed mean DC values of different brain areas and behavioral performance. Compared with HCs, patients with acute unilateral OGI had significantly increased DC values in the bilateral primary visual cortex (V1/V2) and left precuneus (PCUN), and significantly decreased DC values in the right insula, left insula, right inferior parietal lobule (IPL)/supramarginal gyrus (SMG), IPL/SMG, right supplementary motor area and right postcentral gyrus. Additionally, in the acute OGI group, it was observed that the duration of OGI was negatively correlated with the DC signal value of the bilateral V1/V2 ($r=-0.581$; $P=0.011$) and left PCUN ($r=-0.508$; $P=0.031$). Acute OGI led to brain functional network dysfunction in a number of brain regions, which may indicate impairment of the visual cortex and other vision-associated brain regions in OGI.

Introduction

Open globe injury (OGI) is a severe eye disease that frequently causes unilateral visual loss. Ocular trauma is a public health problem in developing countries (1,2). A previous study indicated that the annual prevalence of ocular trauma was 4.9 per 100,000 in the Western Sicily Mediterranean area, which investigated a 5 year period from January 2001 to December 2005 (3). In addition, the incidence of OGI is increased in men compared with women (4). OGI primarily occurs in the 15-44 and 0-14 age groups (5). A total of ~19 million cases of unilateral blindness or decreased vision are caused by ocular trauma each year (6). Clinically, OGI is frequently associated with corneal injury and iris prolapse (7), retinal detachment (8), glaucoma (9) and endophthalmitis (10). At present, surgery is the principal means of treatment for OGI (11,12).

Computed tomography (CT) and B-scan ultrasonography are important clinical tests for the diagnosis of OGI. Although CT may provide information for the diagnosis of OGI (13), it is insufficient for making the decision of immediate treatment (14). B-scan ultrasonography is able to locate retinal detachment points, retinal tears and vitreous traction, and thus may be beneficial for further medical treatment (15). The aforementioned methods focus solely on ocular trauma in OGI. However, other parts of the visual system, including the connecting pathways and the visual cortex, are frequently overlooked. Little is known about the underlying mechanisms of neural alterations in the OGI.

Resting-state functional magnetic resonance imaging (fMRI) is able to evaluate intrinsic brain activity in subjects at rest (16). It has been widely used in visual studies associated with brain functional alterations. A previous study reported decreased functional connectivity within the occipital visual cortices and a correlation with other vision-associated brain regions in patients with early blindness (17). An additional study demonstrated that patients with early blindness exhibited stronger connectivity in the primary somatosensory area (S1) and primary visual cortex (V1) compared with patients with late blindness (18). In addition, a previous report demonstrated that patients with early blindness exhibited markedly decreased gray matter volumes in the optic tract and visual

Correspondence to: Dr Yi Shao, Department of Ophthalmology, The First Affiliated Hospital of Nanchang University, Jiangxi Province Clinical Ophthalmology Institute and Oculopathy Research Centre, 17 Yong Wai Zheng Street, Dong Hu, Nanchang, Jiangxi 330006, P.R. China
E-mail: freebee99@163.com

Key words: open globe injury, functional magnetic resonance imaging, voxel-wise degree centrality, resting state

cortex (19). Although there have been numerous studies into visual and brain function alterations in patients with blindness, less is known about the spontaneous brain activity alterations in patients with acute unilateral vision loss caused by OGI.

Voxel-wise degree centrality (DC) is a measurement that illustrates the network architecture of functional connectivity within the human brain connectome at the voxel level (20). Distinct from the amplitude of low-frequency fluctuation (ALFF) (21) and regional homogeneity (ReHo) (22) techniques, it does not require the definition of regions of interest. The DC method is able to provide insights into the functional connectivity of the entire brain. The DC method has been successfully used to evaluate the pathological mechanisms underlying a number of diseases, including autism (23), obesity (24) and Parkinson's disease (25). A previous study investigated strabismus and optic neuritis through whole-brain voxel-based analysis of diffusion tensor imaging (26,27). In addition, ALFF and ReHo were previously used to analyze patients with acute OGI (28,29). The present study evaluated functional network brain activity alterations in patients with acute unilateral vision loss caused by OGI, and associations with clinical features.

Subjects and methods

Subjects. A total of 18 patients with acute unilateral OGI (16 male and 2 female; 8 right eye injury and 8 left eye injury; age range, 18–65 years) were recruited from the ophthalmology departments of the First Affiliated Hospital of Nanchang University and Xiangya Hospital between August 2015 and January 2016. Acute unilateral OGI was diagnosed with the following criteria: i) Severe ocular trauma; ii) acute vision loss; iii) corneal and scleral rupture; iv) decreased intraocular pressure; v) incomplete eyeball wall visualized using orbital CT or orbital MRI; and vi) contralateral eye best-corrected visual acuity (VA) ≥ 1.0 .

Exclusion conditions were as follows: i) Patients with other eye diseases (including cataracts, glaucoma, pterygium and strabismus, ocular infection and inflammation, hereditary optic neuropathy, ischemic diseases, demyelinating diseases, intraocular placeholder lesions, toxic lesions, vascular lesions and ischemic optic neuropathy); ii) central nervous system diseases and systemic disorders; iii) diabetes and cardiovascular diseases; and iv) addictions (including drugs or alcohol).

A total of 18 healthy controls (HCs; 16 males and 2 females) with matched age, sex and education were recruited for the present study. All HCs met the following conditions: i) Normal brain parenchyma on head MRI scan; ii) no ocular or central nervous system diseases; iii) naked eye or the best-corrected VA > 1.0 ; and iv) no MRI scanning contraindications (for example, implanted metal devices).

The research methods of the present study followed the Declaration of Helsinki and conformed to the principles of medical ethics. The present study was approved by the Ethics Committees of the First Affiliated Hospital of Nanchang University and Xiangya Hospital. All subjects participated voluntarily and were informed of the purposes, methods and procedures, and all subjects signed an informed consent form.

MRI data acquisition. MRI scanning was performed on a 3-Tesla MR scanner (Trio; Siemens AG, Munich, Germany). High-resolution T1-weighted images were acquired as described previously (30). A total of 240 functional images covering the whole brain in one subject were obtained.

fMRI data preprocessing. All functional data were prefiltered using MRICro (www.MRICro.com) and preprocessed using SPM8 (www.fil.ion.ucl.ac.uk/spm), DPARSFA (rfmri.org/DPARSFA) and the Resting-state Data Analysis Toolkit (www.restfmri.net), as described previously (30).

Degree centrality. The voxel-wise functional network was generated as described previously (30). Based on the voxel-wise functional network, DC was calculated as the counting of significant suprathresholded correlations (or the degree of the binarized adjacency matrix) for each subject. The voxel-wise DC map for each individual was converted into a z-score map, as described previously (30).

Statistical analysis. For demographic and clinical measurements, the data were presented as the mean \pm standard deviation. The differences in clinical features between the patients and HCs were calculated using independent two-sample t-tests.

Independent t-tests with generalized linear model analysis was performed using the SPM8 toolkit to investigate the group differences in DC values between patients with OGI and HCs. $P < 0.05$ was considered to indicate a statistically significant difference, with Gaussian random field theory correction. Pearson correlation analysis was used to calculate the association between mean DC values and clinical features. Statistical tests were performed using SPSS version 16.0 (SPSS, Inc., Chicago, IL, USA).

Results

Demographics and visual measurements. There were no significant differences in weight ($P = 0.423$), age ($P = 0.990$), best-corrected VA-right ($P < 0.001$) and best-corrected VA-left ($P < 0.001$) between the two groups (Table I).

DC differences. Compared with HCs, DC values of patients with acute OGI were increased in the bilateral visual cortex (V1/V2) and left precuneus (PCUN) regions, although they were decreased in the right insula, left insula, right inferior parietal lobule (IPL)/supramarginal gyrus (SMG), left IPL/SMG, right supplementary motor area (SMA) and S1 (Fig. 1; Table II; $z > 2.3$; cluster-wise $P < 0.05$ corrected). The mean altered DC values between patients with OGIs and HCs are presented in Fig. 2.

Correlation analysis of DC values and clinical outcomes in the OGI group. In the acute OGI group, it was observed that the duration of OGI was negatively correlated with the DC signal value of the bilateral V1/V2 ($r = -0.581$; $P = 0.011$; Fig. 3A) and the left PCUN ($r = -0.508$; $P = 0.031$; Fig. 3B).

Receiver operating characteristic (ROC) curve. It was proposed that DC differences between patients with OGI and HCs may be useful diagnostic markers. The mean DC values of

Table I. Demographic information and clinical features of subjects in the OGI and HC groups.

Feature	OGI	HC	t	P-value
Sex, male/female	16/2	16/2	N/A	N/A
Age ^a , years	44.17±13.94	44.11±12.78	0.012	0.990
Weight ^a , kg	55.83±6.04	54.39±4.42	0.813	0.423
Handedness	20 R	20 R	N/A	>0.999
Duration of OGI, h ^a	24.83±31.72	N/A	N/A	N/A
Best-corrected VA-right ^a	0.56±0.57	1.16±0.18	-4.262	<0.001
Best-corrected VA-left ^a	0.64±0.53	1.17±0.18	-4.023	<0.001

^aIndependent t-tests (mean ± standard deviation) were used to compare the two groups. OGI, open globe injury; HC, healthy control; N/A, not applicable; VA, visual acuity; R, right.

Table II. Brain regions with significant differences in DC between the OGI and HC groups.

Brain area	MNI coordinates			Voxel no.	BA	L/R/B	Peak T values
	x	y	z				
OGI<HC							
Insula	33	6	6	241	13	R	-5.503
Insula	-30	12	-3	167	13	L	-4.948
IPL/SMG	60	-30	36	147	40	R	-4.741
IPL/SMG	-60	-33	27	119	40	L	-4.382
SMA	15	-6	66	176	6	R	-4.970
S1	21	-51	63	128	5	R	-5.711
OGI>HC							
V1/V2	27	-99	-12	879	17,18	B	8.076
PCUN	-3	0	75	278	7	L	5.935

The statistical threshold was set at $P<0.05$ for multiple comparisons using Gaussian Random Field theory ($z>2.3$; cluster-wise $P<0.05$ corrected). DC, degree centrality; BA, Brodmann area; OGI, open globe injury; HC, healthy control; MNI, Montreal Neurological Institute; V1/V2, primary visual cortex; PCUN, precuneus; IPL, inferior parietal lobule; SMG, supramarginal gyrus; SMA, supplementary motor area; S1, postcentral gyrus; R, right; L, left; B, bilateral.

the different brain regions were used for ROC curves analysis. The area under the curve values were: Bilateral V1/V2, 1.000 and left PCUN, 0.994, respectively (Fig. 4).

Discussion

To the best of our knowledge, the present study was the first to evaluate the effects of acute OGI on functional networks and brain-activity changes using the DC technique. Compared with HCs, patients with acute unilateral OGI exhibited increased DC values in the bilateral V1/V2 and left PCUN, and decreased DC values in the right insula, left insula, right IPL/SMG, left IPL/SMG, right SMA and S1. It was observed that the duration of OGI was negatively correlated with the DC signal value of the bilateral V1/V2 ($r=-0.581$; $P=0.011$) and left PCUN ($r=-0.508$; $P=0.031$).

The primary visual cortex, also termed V1 (striate cortex or Brodmann area 17) (31) is located in the occipital lobe involved in the processing of visual information. The extrastriate areas

are located next to the primary visual cortex, including functional areas V2, V3, V4 and V5 (32). The extrastriate areas receive visual information from the primary visual cortex and transmit the information to other brain areas (33). A previous study reported that visual acuity exerts a marked effect on the V1 blood oxygen level-dependent (BOLD) response (34). An additional study demonstrated that central vision loss may lead to cortical atrophy of V1 (35). Increased regional homogeneity in the occipital areas was reported in patients with early blindness (36). Consistent these previous findings, it was observed in the present study that patients with acute unilateral OGI exhibited significantly increased DC values in the bilateral V1/V2, which may reflect the compensation of the visual cortex in acute unilateral vision loss associated with OGI. It was additionally demonstrated that the duration of OGI exhibited a negative correlation with the DC signal value of the bilateral V1/V2 ($r=-0.581$; $P=0.011$). This suggested that a stronger visual compensatory function may occur in V1/V2 during the early phase of acute OGI.

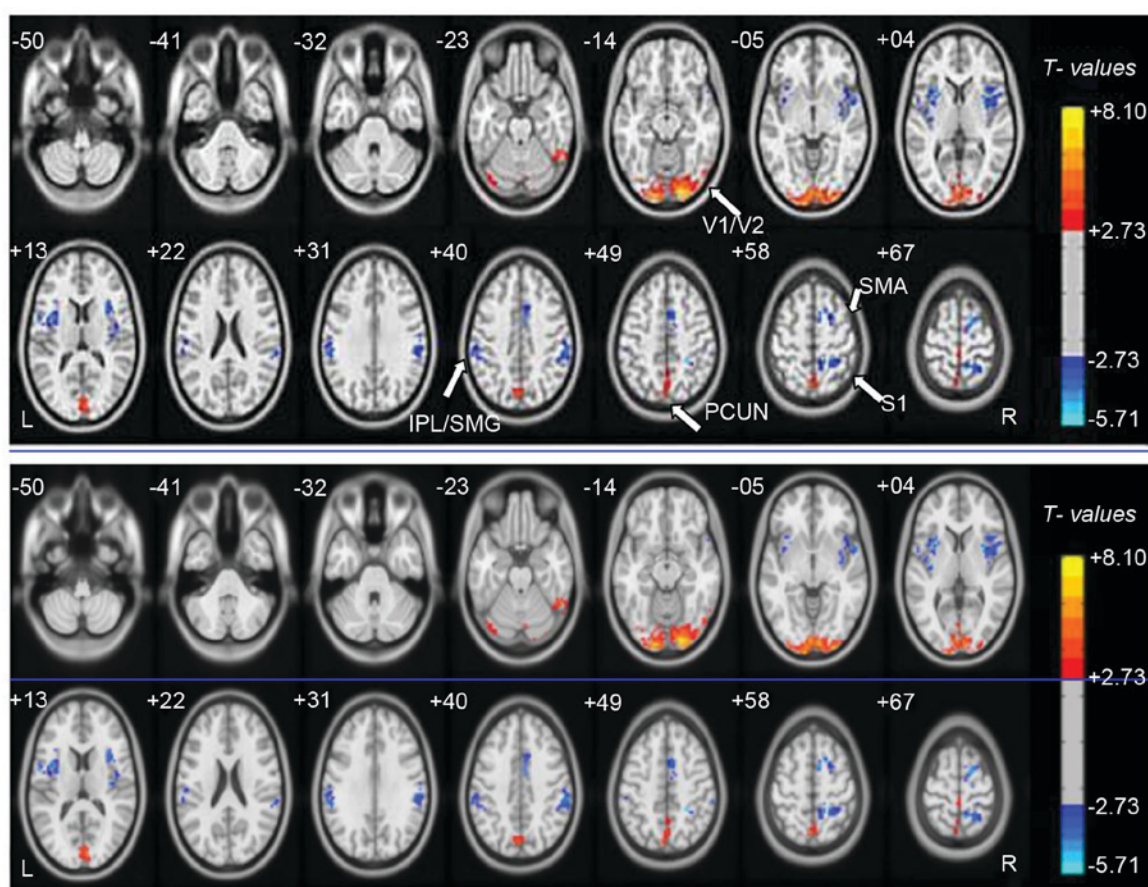


Figure 1. Voxel-wise comparison of DC in the OGI and HC groups. Significant differences in DC were observed in the bilateral V1/V2, left PCUN, right insula, left insula, right IPL/SMG, left IPL/SMG, right SMA and S1. Red, increased DC values; blue, decreased DC values. DC, Degree centrality; OGI, open globe injury; HC, healthy control; V1/V2, primary visual cortex; PCUN, precuneus; IPL, inferior parietal lobule; SMG, supramarginal gyrus; SMA, supplementary motor area; S1, postcentral gyrus.

The PCUN, located forward of the occipital lobe, contributes to visuospatial information processing (37) and memory (38). A previous study reported that the PCUN is activated during visuospatial activities (39). In the present study, it was observed that patients with acute unilateral OGI had increased DC values in the left PCUN, which may reflect the compensation of the PCUN in acute unilateral visual loss associated with OGI. Additionally, it was observed that the duration of OGI was negatively correlated with the DC signal value of the left PCUN. Therefore, a stronger compensatory function may occur in the PCUN during the early phase of acute OGI.

The insula, located in the lateral sulcus (40), is divided into two part. The insula serves roles in emotion and cognition (41-43). A previous study reported that increased activity of the insula is associated with emotional regulation (44). Dysfunction of the insula has been observed in negative emotional experiences (45) and anxiety-prone subjects (46). In the present study, it was demonstrated that DC values in the right insula and left insula were decreased in patients with OGI, which may reflect impaired emotional processing caused by acute unilateral OGI.

The SMA, located in front of the primary motor cortex, is involved in the control of movement (47,48). A previous study demonstrated that the SMA served an important role in the orchestration of movements (49). An additional study

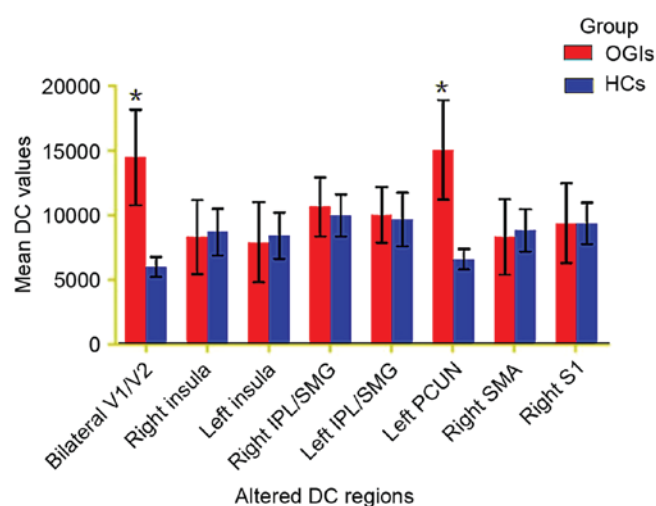


Figure 2. Mean altered DC values in the OGI and HC groups. DC, degree centrality; OGI, open globe injury; HC, healthy control; V1/V2, primary visual cortex; PCUN, precuneus; IPL, inferior parietal lobule; SMG, supramarginal gyrus; SMA, supplementary motor area; S1, postcentral gyrus. * $P < 0.05$ vs. HC.

demonstrated the role of injury to the upper motor neuron in supplementary motor area syndrome (50). In the present study, it was observed that patients with acute unilateral OGI

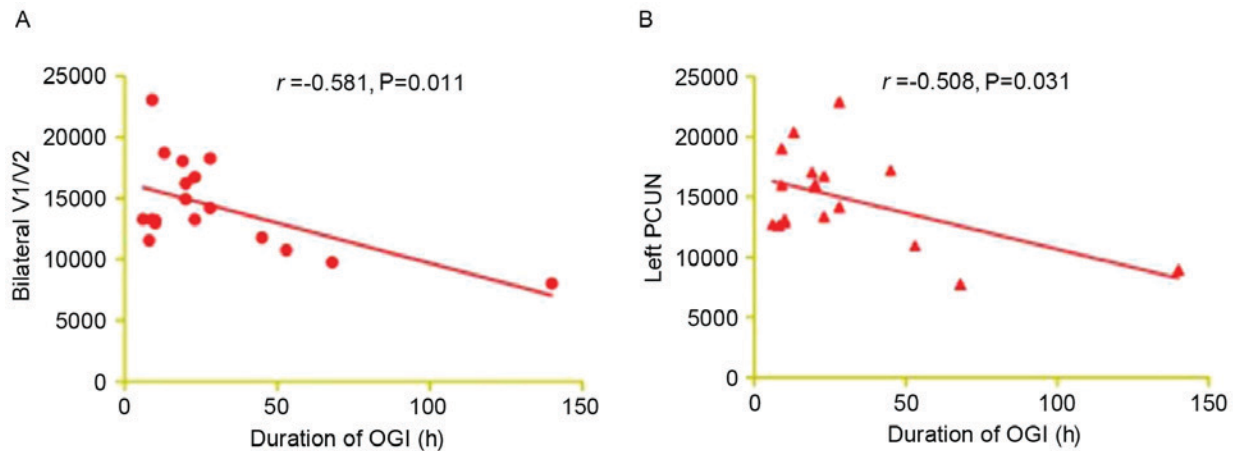


Figure 3. Correlations between the mean DC values of the different areas and behavioral performance. The duration of OGI exhibited a negative correlation with the DC signal value of (A) the bilateral V1/V2 ($r=-0.581$; $P=0.011$) and (B) the left PCUN ($r=-0.508$; $P=0.031$). DC, degree centrality; OGI, open globe injury; V1/V2, primary visual cortex; PCUN, precuneus.

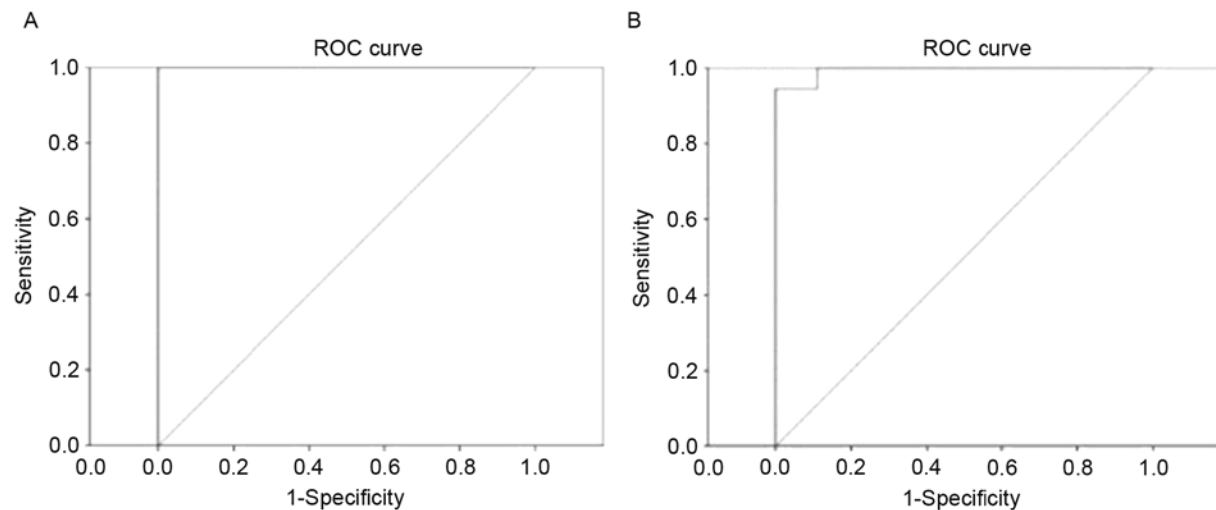


Figure 4. ROC curve analysis of the mean DC values for altered brain regions. The area under the ROC curve was (A) 1.000 ($P<0.001$; 95% CI, 1.000-1) for the bilateral V1/V2, and (B) 0.994 ($P=0.008$; 95% CI, 0.978-1) for the left PCUN. ROC, receiver operating characteristic; DC, degree centrality; CI, confidence interval; V1/V2, primary visual cortex; PCUN, precuneus.

exhibited increased DC values in the right SMA, indicating that OGI may be associated with the dysfunction of movement.

In conclusion, the results of the present study demonstrated that patients with OGI had dysfunctional activity in specific regions of the brain, which may be associated with compensation for vision loss in acute OGI. The present findings may provide a basis for identifying the downstream impact of OGI on brain network organization. However, the sample size of the present study was relatively small. In addition, the clinical characteristics were not strictly defined. Right and left eye-injured patients were included in the present study, which may have affected the DC results. In future studies, differences will be distinguished and brain function activity alterations measured more accurately.

Acknowledgements

The present study was supported by the National Natural Science Foundation of China (grant nos. 81170,823, 81460092

and 81400372), the Science and Technology Program Project of Hunan Province Science and Technology Department (grant nos. 2015JC3011 and 2015JC3118), the Jiangxi Province Voyage Project (grant no. 2014022), the Natural Science Key Project of Jiangxi Province (grant no. 20161ACB21017), the Youth Science Foundation of Jiangxi Province (grant no. 20151BAB215016), and the Technology and Science Foundation of Jiangxi Province (grant no. 20151BBG70223).

References

1. Chaikitmongkol V, Leeungurasatien T and Sengupta S: Work-related eye injuries: Important occupational health problem in northern Thailand. *Asia Pac J Ophthalmol* (Phila) 4: 155-160, 2015.
2. Vasu U, Vasnaik A, Battu RR, Kurian M and George S: Occupational open globe injuries. *Indian J Ophthalmol* 49: 43-47, 2001.
3. Cillino S, Casuccio A, Di Pace F, Pillitteri F and Cillino G: A five-year retrospective study of the epidemiological characteristics and visual outcomes of patients hospitalized for ocular trauma in a Mediterranean area. *BMC Ophthalmol* 8: 8, 2008.

4. Liu X, Liu Z, Liu Y, Zhao L, Xu S, Su G and Zhao J: Determination of visual prognosis in children with open globe injuries. *Eye (Lond)* 28: 852-856, 2014.
5. Cao H, Li L and Zhang M: Epidemiology of patients hospitalized for ocular trauma in the Chaoshan region of China, 2001-2010. *PLoS One* 7: e48377, 2012.
6. Négrel AD and Thylefors B: The global impact of eye injuries. *Ophthalmic Epidemiol* 5: 143-169, 1998.
7. Nawani N, Vazirani J, Ojha H and Sangwan VS: Conjunctival pedicle flap in management of open globe injury with corneal tissue loss. *BMJ Case Rep* 2016: pii: bcr2015213703, 2016.
8. Stryjewski TP, Andreoli CM and Elliott D: Retinal detachment after open globe injury. *Ophthalmology* 121: 327-333, 2014.
9. Osman EA: Glaucoma after open globe injury. *Saudi J Ophthalmol* 29: 222-224, 2015.
10. Zhang Y, Zhang MN, Jiang CH, Yao Y and Zhang K: Endophthalmitis following open globe injury. *Br J Ophthalmol* 94: 111-114, 2010.
11. Feng K, Hu YT and Ma Z: Prognostic indicators for no light perception after open-globe injury: Eye injury vitrectomy study. *Am J Ophthalmol* 152: 654-662.e2, 2011.
12. Heidari E and Taheri N: Surgical treatment of severely traumatized eyes with no light perception. *Retina* 30: 294-299, 2010.
13. Arey ML, Mootha VV, Whittemore AR, Chason DP and Blomquist PH: Computed tomography in the diagnosis of occult open-globe injuries. *Ophthalmology* 114: 1448-1452, 2007.
14. Allon G, Beiran I, Seider N and Blumenthal EZ: The role of computed tomography in the immediate workup of open globe injury. *Eur J Ophthalmol* 26: 503-504, 2016.
15. Andreoli MT, Yiu G, Hart L and Andreoli CM: B-scan ultrasonography following open globe repair. *Eye (Lond)* 28: 381-385, 2014.
16. Biswal BB: Resting state fMRI: A personal history. *Neuroimage* 62: 938-944, 2012.
17. Liu Y, Yu C, Liang M, Li J, Tian L, Zhou Y, Qin W, Li K and Jiang T: Whole brain functional connectivity in the early blind. *Brain* 130: 2085-2096, 2007.
18. Fujii T, Tanabe HC, Kochiyama T and Sadato N: An investigation of cross-modal plasticity of effective connectivity in the blind by dynamic causal modeling of functional MRI data. *Neurosci Res* 65: 175-186, 2009.
19. Pan WJ, Wu G, Li CX, Lin F, Sun J and Lei H: Progressive atrophy in the optic pathway and visual cortex of early blind Chinese adults: A voxel-based morphometry magnetic resonance imaging study. *Neuroimage* 37: 212-220, 2007.
20. Zuo XN, Ehmke R, Mennes M, Imperati D, Castellanos FX, Sporns O and Milham MP: Network centrality in the human functional connectome. *Cereb Cortex* 22: 1862-1875, 2012.
21. Huang X, Cai FQ, Hu PH, Zhong YL, Zhang Y, Wei R, Pei CG, Zhou FQ and Shao Y: Disturbed spontaneous brain-activity pattern in patients with optic neuritis using amplitude of low-frequency fluctuation: A functional magnetic resonance imaging study. *Neuropsychiatr Dis Treat* 11: 3075-3083, 2015.
22. Shao Y, Cai FQ, Zhong YL, Huang X, Zhang Y, Hu PH, Pei CG, Zhou FQ and Zeng XJ: Altered intrinsic regional spontaneous brain activity in patients with optic neuritis: A resting-state functional magnetic resonance imaging study. *Neuropsychiatr Dis Treat* 11: 3065-3073, 2015.
23. Di Martino A, Zuo XN, Kelly C, Grzadzinski R, Mennes M, Schvartz A, Rodman J, Lord C, Castellanos FX and Milham MP: Shared and distinct intrinsic functional network centrality in autism and attention-deficit/hyperactivity disorder. *Biol Psychiatry* 74: 623-632, 2013.
24. Garcia-Garcia I, Jurado MÁ, Garolera M, Marqués-Iturria I, Horstmann A, Segura B, Pueyo R, Sender-Palacios MJ, Vernet Vernet M, Villringer A, *et al*: Functional network centrality in obesity: A resting-state and task fMRI study. *Psychiatry Res* 233: 331-338, 2015.
25. Lou Y, Huang P, Li D, Cen Z, Wang B, Gao J, Xuan M, Yu H, Zhang M and Luo W: Altered brain network centrality in depressed Parkinson's disease patients. *Mov Disord* 30: 1777-1784, 2015.
26. Dai H, Yin D, Hu C, Morelli JN, Hu S, Yan X and Xu D: Whole-brain voxel-based analysis of diffusion tensor MRI parameters in patients with primary open angle glaucoma and correlation with clinical glaucoma stage. *Neuroradiology* 55: 233-243, 2013.
27. Huang X, Li HJ, Zhang Y, Peng DC, Hu PH, Zhong YL, Zhou FQ and Shao Y: Microstructural changes of the whole brain in patients with comitant strabismus: Evidence from a diffusion tensor imaging study. *Neuropsychiatr Dis Treat* 12: 2007-2014, 2016.
28. Huang X, Li HJ, Ye L, Zhang Y, Wei R, Zhong YL, Peng DC and Shao Y: Altered regional homogeneity in patients with unilateral acute open-globe injury: A resting-state functional MRI study. *Neuropsychiatr Dis Treat* 12: 1901-1906, 2016.
29. Tan G, Huang X, Ye L, Wu AH, He LX, Zhong YL, Jiang N, Zhou FQ and Shao Y: Altered spontaneous brain activity patterns in patients with unilateral acute open globe injury using amplitude of low-frequency fluctuation: A functional magnetic resonance imaging study. *Neuropsychiatr Dis Treat* 12: 2015-2020, 2016.
30. Cai F, Gao L, Gong H, Jiang F, Pei C, Zhang X, Zeng X and Huang R: Network centrality of resting-state fMRI in primary angle-closure glaucoma before and after surgery. *PLoS One* 10: e0141389, 2015.
31. Tootell RB, Hadjikhani NK, Vanduffel W, Liu AK, Mendola JD, Sereno MI and Dale AM: Functional analysis of primary visual cortex (V1) in humans. *Proc Natl Acad Sci USA* 95: 811-817, 1998.
32. Orban GA: Higher order visual processing in macaque extrastriate cortex. *Physiol Rev* 88: 59-89, 2008.
33. Laramée ME, Bronchti G and Boire D: Primary visual cortex projections to extrastriate cortices in enucleated and anophthalmic mice. *Brain Struct Funct* 219: 2051-2070, 2014.
34. Cunningham SI, Weiland JD, Bao P, Lopez-Jaime GR and Tjan BS: Correlation of vision loss with tactile-evoked V1 responses in retinitis pigmentosa. *Vision Res* 111: 197-207, 2015.
35. Burge WK, Griffis C, Nenert R, Elkhetafi A, Decarlo K, Ver Hoef W, Ross A and Visscher M: Cortical thickness in human V1 associated with central vision loss. *Sci Rep* 6: 23268, 2016.
36. Liu C, Liu Y, Li W, Wang D, Jiang T, Zhang Y and Yu C: Increased regional homogeneity of blood oxygen level-dependent signals in occipital cortex of early blind individuals. *Neuroreport* 22: 190-194, 2011.
37. Mahayana IT, Tcheang L, Chen CY, Juan CH and Muggleton NG: The precuneus and visuospatial attention in near and far space: A transcranial magnetic stimulation study. *Brain Stimul* 7: 673-679, 2014.
38. Bonni S, Veniero D, Mastropasqua C, Ponzo V, Caltagirone C, Bozzali M and Koch G: TMS evidence for a selective role of the precuneus in source memory retrieval. *Behav Brain Res* 282: 70-75, 2015.
39. Oshio R, Tanaka S, Sadato N, Sokabe M, Hanakawa T and Honda M: Differential effect of double-pulse TMS applied to dorsal premotor cortex and precuneus during internal operation of visuospatial information. *NeuroImage* 49: 1108-1115, 2010.
40. Naidich TP, Kang E, Fatterpekar GM, Delman BN, Gultekin SH, Wolfe D, Ortiz O, Yousry I, Weissman M and Yousry TA: The insula: Anatomic study and MR imaging display at 1.5 T. *AJNR Am J Neuroradiol* 25: 222-232, 2004.
41. Gu X, Hof PR, Friston KJ and Fan J: Anterior insular cortex and emotional awareness. *J Comp Neurol* 521: 3371-3388, 2013.
42. Seth AK, Suzuki K and Critchley HD: An interoceptive predictive coding model of conscious presence. *Front Psychol* 2: 395, 2012.
43. Gasquoine PG: Contributions of the insula to cognition and emotion. *Neuropsychol Rev* 24: 77-87, 2014.
44. Grecucci A, Giorgetta C, Bonini N and Sanfey AG: Reappraising social emotions: The role of inferior frontal gyrus, temporo-parietal junction and insula in interpersonal emotion regulation. *Front Hum Neurosci* 7: 523, 2013.
45. Steward T, Picó-Pérez M, Mata F, Martínez-Zalacain I, Cano M, Contreras-Rodríguez O, Fernández-Aranda F, Yucel M, Soriano-Mas C and Verdejo-García A: Emotion regulation and excess weight: Impaired affective processing characterized by dysfunctional insula activation and connectivity. *PLoS One* 11: e0152150, 2016.
46. Stein MB, Simmons AN, Feinstein JS and Paulus MP: Increased amygdala and insula activation during emotion processing in anxiety-prone subjects. *Am J Psychiatry* 164: 318-327, 2007.
47. Halsband U, Ito N, Tanji J and Freund HJ: The role of premotor cortex and the supplementary motor area in the temporal control of movement in man. *Brain* 116: 243-266, 1993.
48. Eccles JC: The initiation of voluntary movements by the supplementary motor area. *Arch Psychiatr Nervenkr (1970)* 231: 423-441, 1982.
49. Salardini A, Narayanan NS, Arora J, Constable T and Jabbari B: Ipsilateral synkinesia involves the supplementary motor area. *Neurosci Lett* 523: 135-138, 2012.
50. Florman JE, Duffau H and Rughani AI: Lower motor neuron findings after upper motor neuron injury: Insights from postoperative supplementary motor area syndrome. *Front Hum Neurosci* 7: 85, 2013.