

Therapeutic effect of chitosan on CCl₄-induced hepatic fibrosis in rats

ZHONG-FENG WANG¹, MAO-YU WANG², DE-HAI YU³, YAN ZHAO⁴, HONG-MEI XU⁵, SHENG ZHONG¹, WEN-YI SUN⁶, YU-FANG HE⁷, JUN-QI NIU¹, PU-JUN GAO¹ and HAI-JUN LI⁸

¹Department of Geriatrics, The First Hospital, Jilin University, Changchun, Jilin 130021; ²Department of CCU,

The First People's Hospital of Aksu Prefecture in Xinjiang, Aksu, Xinjiang 843000; ³Cancer Center,

The First Hospital of Jilin University; ⁴College of Chinese Medicinal Materials, Jilin Agriculture University;

⁵Department of Obstetrics, The First Hospital, Jilin University, Changchun, Jilin 130061;

⁶Department of Clinical Pharmacy and Pharmaceutical Management, School of Pharmaceutical Sciences, Jilin University,

Changchun, Jilin 130021; ⁷Institute of Phytochemistry, Jilin Academy of Chinese Medicine Sciences, Changchun,

Jilin 130012; ⁸Institute of Translational Medicine, The First Hospital, Jilin University, Changchun, Jilin 130021, P.R. China

Received November 4, 2017; Accepted June 19, 2018

DOI: 10.3892/mmr.2018.9343

Abstract. Chitosan is a linear polysaccharide that is made by treating the chitin shells of shrimp and crustaceans with an alkaline substance, for example sodium hydroxide. Due to its unique physical and chemical properties, chitosan has a wide range of applications in the medical field. Currently, there are no effective treatments for liver fibrosis; therefore, the aim of the present study was to investigate the therapeutic effect of chitosan in a CCl₄-induced hepatic fibrosis (HF) rat model. The serum levels of aspartate transaminase (AST), alanine transaminase (ALT) and alkaline phosphatase (ALP) were measured by ELISA. Collagen (COL) 3 and α -smooth muscle actin (SMA) expression levels in the rat liver were detected by reverse transcription-semiquantitative polymerase chain reaction and western blotting, respectively. The results demonstrated that treatment with chitosan significantly improved HF, by decreasing the serum levels of AST, ALT, and ALP; improving liver histology; and decreasing the expression levels of COL3 and α -SMA. Chitosan may offer an alternative approach for the clinical treatment of HF.

Introduction

Chitin, poly- β -(1-4)-N-acetyl-D-glucosamine, is the most abundant natural amino polysaccharide and its annual production is estimated to almost equal that of cellulose (1). The principal sources of chitin are two marine crustaceans, shrimp and crab. Chitosan is a well-known N-deacetylated derivative of chitin, although this N-deacetylation is almost never complete. There is great interest in examining the potential therapeutic effects of chitosan on hepatic fibrosis (HF), as chitin and its derivatives have been reported to have a wide range of medical applications (2-4). It has been suggested that chitosan inhibits fibroplasia in wound healing, and promotes tissue growth and differentiation *in vitro* (5,6). Notably, chitosan has anti-inflammatory and anti-oxidative properties (7-9).

Carbon tetrachloride (CCl₄) is an established hepatotoxin. It is thought to require activation by hepatic microsomal mixed-function oxidase to form the trichloromethyl free radical, CCl₃·. This, in turn, reacts with oxygen to form the more reactive trichloromethylperoxy radical, CCl₃OO·. CCl₃OO· interacts with polyunsaturated fatty acids to cause lipid peroxidation, whereas CCl₃· binds to lipids and protein components of the membrane leading to covalent binding. CCl₃OO· causes severe cell injury, stimulating inflammation and fibroblasts (10-13).

Liver fibrosis results from chronic liver damage in conjunction with the accumulation of extracellular matrix (ECM) proteins, which consist predominantly of collagen (COL) 1 and COL3. The primary causes of liver fibrosis include chronic hepatitis C virus infection, alcohol abuse and non-alcoholic steatohepatitis. Accumulation of ECM proteins distorts the hepatic architecture by forming a fibrous scar and leads to cirrhosis, which is defined by the subsequent development of regenerating hepatocyte nodules. During this period, oxidative stress serves an important role, as this stimulus may liberate mediators of cytokines and assist in the activation of hepatic stellate cells (HSCs), which are the predominant

Correspondence to: Dr Hai-Jun Li, Institute of Translational Medicine, The First Hospital, Jilin University, 71 Xinmin Street, Changchun, Jilin 130021, P.R. China
E-mail: hqli2012@jlu.edu.cn

Professor Pu-Jun Gao, Department of Geriatrics, The First Hospital, Jilin University, 71 Xinmin Street, Changchun, Jilin 130021, P.R. China
E-mail: gpj0411@163.com

Key words: hepatic fibrosis, chitosan, α -smooth muscle actin, collagen 3

collagen-producing fibrogenic cell type in the liver (14-17). Cirrhosis causes hepatocellular dysfunction and increased intrahepatic resistance to blood flow, resulting in hepatic insufficiency and portal hypertension, respectively (18-20). There are currently no effective treatments for liver fibrosis; therefore, it was hypothesized that chitosan may have a therapeutic effect on CCl₄-induced HF in rats. To test this hypothesis, the effect of treatment with chitosan on HF in the rats was evaluated by determining the production of aspartate transaminase (AST), alkaline phosphatase (ALP) and alanine transaminase (ALT); assessing histological features; and detecting the relative gene expression levels of COL3 and the protein expression levels of α -smooth muscle actin (SMA).

Materials and methods

Reagents. Chitosan (98% purity, by high-performance liquid chromatography analysis) was purchased from Shandong Jinan Haidebei Marine Bioengineering Co., Ltd. (Shandong, China) and the chemical structure is presented in Fig. 1. CCl₄, xylene, alcohol, chloral hydrate and formaldehyde were purchased from Beijing Chemical Factory (Beijing, China). ALT (cat. no. A7526), ALP (cat. no. A7516) and AST (cat. no. A7561) Elisa kits were purchased from Pointe Scientific, Inc. (Canton, MI, USA). Anti-AST antibody (cat. no. AV43932), anti- α -SMA antibody (cat. no. A2547), secondary antibodies were purchased from Sigma-Aldrich (Merck KGaA, Darmstadt, Germany). Anti- β -actin was purchased from Abcam (cat. no. ab8227, Cambridge, UK). Poly-L-lysine and radioimmunoprecipitation assay (RIPA) lysis buffer were purchased from DGCS-Biology Technology, Inc. (cat. no. 9806; Nanjing, China). The enhanced chemiluminescent western blotting kit was purchased from GE Healthcare (Chicago, IL, USA).

Animal experiments. The present study was approved by the medical ethics committee of The First Hospital of Jilin University (Changchun, China). Male Sprague-Dawley (SD) rats aged 8 weeks, weighing 190 \pm 10 g, were purchased from the Laboratory Research Center of Jilin University (certificate no. 2000-042; Changchun, China). All animals were housed under standard laboratory conditions. Rats were fed and housed in groups in plastic-bottomed cages containing sawdust. Animals were bred in a temperature-controlled environment (25 \pm 2°C) with lighting between 6:00 a.m. and 6:00 p.m. From a total of 72 SD male rats, 16 were randomly selected as the control group and the remaining 56 were used as the CCl₄ treatment groups. Rats in the control group received intraperitoneal injections of olive oil (1.75 ml/kg) 3 times a week and for 7 weeks. The CCl₄ group rats received intraperitoneal injections of CCl₄ and an olive oil mixture (1.75 ml/kg) 3 times a week and for 7 weeks (CCl₄:olive oil=4:6) to induce liver fibrosis. After 7 weeks, 6 rats in the control group and 6 rats in the CCl₄ treatment group were sacrificed randomly for morphometric analysis of liver tissue; to measure the serum levels of ALT, AST, and ALP; to quantify the expression levels of the COL3 gene and α -SMA protein in the liver tissue; and to assess the establishment of the HF model. The remaining 50 rats in the CCl₄ group were randomly divided into five groups (n=10): The HF group; glycyrrhizinate group; low-dose chitosan group (2.5 mg/kg); middle-dose chitosan group (5.0 mg/kg);

and high-dose chitosan group (10.0 mg/kg). Subsequently, the six groups were unified by a continuous administration of daily tail vein injections for 28 days. Control groups and HF groups were administered normal saline; glycyrrhizinate and chitosan groups were administered the corresponding regents. Blood was collected from the inner canthus vein on days 7, 14, 21 and 28 to detect the ALT, AST and ALP levels. On day 28, rats were anesthetized via an intraperitoneal injection of 10% chloral hydrate (300 mg/kg) and sacrificed by heart puncture for blood extraction. Subsequently, the abdominal cavity was opened using a U-shaped incision; the rat liver was harvested, cut into two uniform blocks, washed with saline and dried with filter paper. A piece of liver tissue was fixed in 10% formalin at 4°C for 24 hours for morphometric analysis, whilst the other piece was wrapped in foil and stored in liquid nitrogen for western blot analysis. Following 7 days of fixation, the fixed liver tissues were embedded in paraffin for sectioning.

Measurement of organ injury markers. Serum levels of AST, ALT and ALP were measured using commercial assay kits, according to the manufacturer's protocols.

Morphometric analysis. Livers were fixed in 10% neutral buffered formalin. The fixed tissues were dehydrated through an ascending alcohol series (70, 80, 90 and 100% v/v) and paraffinized in benzene, prior to being embedded in paraffin. Paraffin sections (5 μ m) were cut using a microtome for hematoxylin and eosin (H&E) staining to evaluate liver injury. In brief, the paraffin sections were stained with hematoxylin for 5 mins at room temperature, then washed in running water for 5 mins. Following immersion in 1% hydrochloric acid for 30 sec, the sections were stained with 0.5% eosin. The extent of HF in each sample was assessed based on the scoring criteria presented in Table I. This grading system was proposed by Brunt *et al* in 1999 for scoring fibrosis (21). A modified non-alcoholic fatty liver disease fibrosis score (22) was used for scoring inflammatory lesions.

Western blot analysis. Liver tissue lysates were prepared by homogenizing liver samples in RIPA buffer. The supernatant was transferred into a 1.5-ml Eppendorf tube, kept at 4°C in the refrigerator for 40 min and centrifuged at room temperature for 10 min at 12,000 \times g. Protein concentration in the supernatants were measured using a Bradford protein assay according to the manufacturer's protocol. A total of 50 μ g protein per sample was separated by 10% SDS-PAGE and transferred onto a nitrocellulose membrane. The membranes were blocked for 2 h in PBS containing 10% non-fat dried milk and 0.1% Tween 20. Subsequently, membranes were incubated at 37°C for 1 h with anti- α -SMA (1:200) or anti- β -actin (1:40,000) antibodies in PBS containing 5% milk, and then incubated with the goat anti-rat secondary antibody (1:2,000) at room temperature for 2 h. Following washing, the membranes were visualized using the enhanced chemiluminescent western blot kit and densitometric analysis was performed using Image J version 1.44 (National Institutes of Health, Bethesda, MD, USA).

Reverse transcription-semiquantitative polymerase chain reaction (RT-sqPCR). Total RNA was extracted from liver tissues using the TRIzol® reagent (Thermo Fisher Scientific,

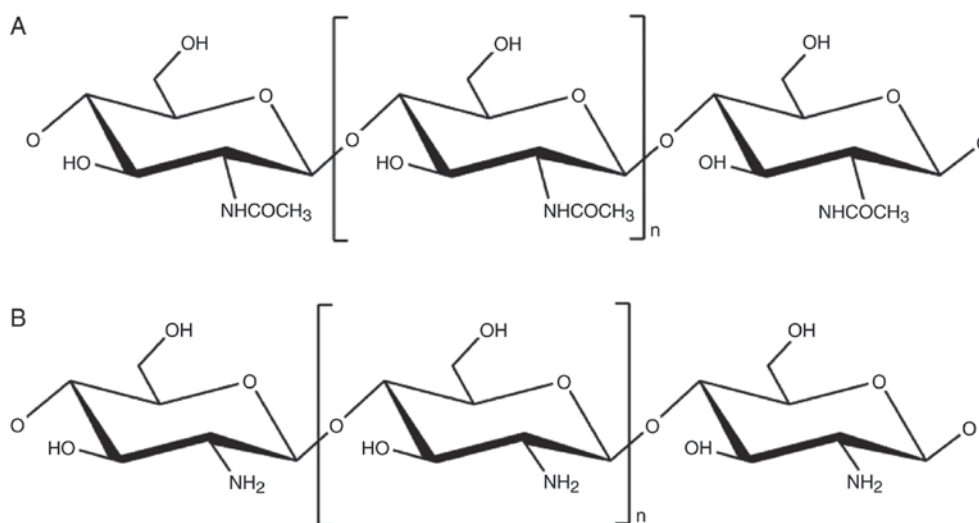


Figure 1. Chemical structure of (A) chitin and (B) chitosan.

Inc., Waltham, MA, USA), according to the manufacturer's protocol. A total of 2 μ g RNA was reverse transcribed to complementary (c)DNA at 37°C for 15 min and at 85°C for 5 seconds using random hexamers and the SuperScript™ III First-Strand Synthesis system (Invitrogen; Thermo Fisher Scientific, Inc.). cDNA was PCR-amplified in tandem using specific primers for COL3 and GAPDH, and Taq polymerase (cat. no. EP0402; Thermo Fisher Scientific, Inc.). The primer sequences were as follows: COL3 (169 bp product), forward 5'-AACCCTGCTCGGAATTGCAG-3', reverse 5'-TCTGTC CACCA GTGCTTCCG-3'; GAPDH (687 bp product), forward 5'-GGGTGATGCTGGTGCTGAGTATGT-3', reverse 5'-AAG AATGGGAGTTGCTGTTGAAGT-3'. Amplification was performed for 30 cycles with a denaturation temperature of 94°C, annealing temperature of 58°C and extension temperature of 74°C for COL3 and GAPDH in a thermal cycler (Veriti; Thermo Fisher Scientific, Inc.). PCR products were verified on 1.2% agarose gels and visualized under UV following ethidium bromide staining. Band intensities were analyzed using the Image Master Total Lab image analysis software version 2.01 (Nonlinear Dynamics, Ltd., Newcastle upon Tyne, UK). GAPDH was used as an internal control to normalize target gene expression.

Statistical analysis. All data were analyzed and assessed for significance using the Pearson omnibus normality test. All data are presented as the mean \pm standard error of the mean. The significance between experimental groups and control group was determined by Dunnett-t test using SPSS version 20.0 (IBM Corp., Armonk, NY, USA). $P < 0.05$ was considered to indicate a statistically significant difference.

Results

Treatment with CCl_4 induces liver fibrosis in rats. Rat livers were visually assessed to evaluate morphological alterations following treatment with CCl_4 . As presented in Fig. 2A, the livers from rats treated with CCl_4 (right) became pale, hard, rough, shrunken and thick, indicating serious liver injury, compared with the control group (left). The serum levels of

ALT, AST and ALP in the CCl_4 -treated group were three- to four-fold higher compared with in the control group ($P < 0.05$), demonstrating that the rat model of liver fibrosis was successfully established (Fig. 2B). In addition, the expression levels of α -SMA and COL3 in liver tissues were evaluated using western blotting and RT-sqPCR, respectively (Fig. 2C). The expression levels of the α -SMA protein and COL3 gene in the CCl_4 -treated group were approximately two-fold higher compared with the control group ($P < 0.05$; Fig. 2D), indicating HSC activation and liver fibrosis.

Effect of treatment with chitosan on liver enzymes in rats with HF. The physical status of rats in the different treatment groups was recorded. Rats in the control group were healthy and active, and had glossy, smooth coats with bright eyes. Conversely, HF rats exhibited dull eyes, swollen paws, slow movement, decreased food intake, unkempt back hair, trichomadesis and hard abdominal swelling. Rats treated with chitosan or glycyrrhizinate increased their food intake, and edema and trichomadesis were reduced. Following 7 days of treatment with chitosan, there was a significant reduction in ALT, AST and ALP enzymes compared with the HF group (Fig. 3). The recovery of rats in the middle- and high-dose chitosan treatment groups was also better compared with the low-dose chitosan treatment group. In addition, the effect of treatment with chitosan was dependent on the duration of administration, with improved recovery occurring after 21 days of treatment.

Effect of treatment with chitosan on liver histology in rats with HF. The liver tissue from rats in the HF group exhibited serious liver injury, as identified by substantial macrosteatosis, hepatocellular ballooning, transparent cytoplasm and nuclei being pushed to the side, suggesting cellular necrosis. In addition, pseudolobuli were visible, which are characteristic structures of HF. In the glycyrrhizinate group, inflammation was markedly reduced and the pseudolobule was not visible; however, ballooning degeneration and fatty degeneration remained. The low-dose chitosan group exhibited obvious pseudolobule formation and alveolar inflammatory cell infiltration.

Table I. Histological scoring of fibrosis.

Score	Fibrosis	Inflammatory lesion
0	None	None
1	Limited to central veins	1 lesion per x100 field
2	Extended to Glisson's capsules	2-4 lesions per x100 field
3	Bridging fibrosis	2-4 lesions per x200 field
4	Nodular transformation	>5 lesions per x200 field

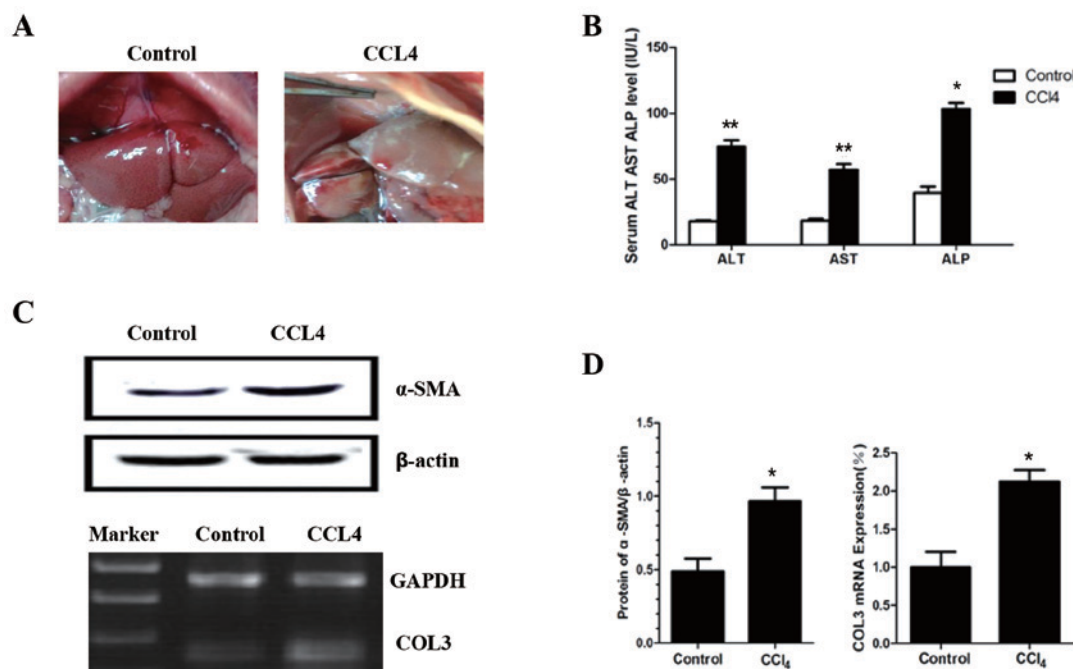


Figure 2. CCl₄ induces liver fibrosis in rats. (A) Representative images of livers from control (left) or CCl₄-treated (right) rats. (B) Serum levels of ALT, AST and ALP. (C and D) Expression levels of α -SMA protein and COL3 by (C) western blot analysis and agarose gel electrophoresis, and (D) reverse transcription-semiquantitative polymerase chain reaction, respectively. *P<0.05 and **P<0.01 vs. control. ALP, alkaline phosphatase; ALT, alanine transaminase; AST, aspartate transaminase; CCl₄, carbon tetrachloride; COL, collagen; α -SMA, α -smooth muscle actin.

Treatment with middle-dose chitosan produced similar results to the glycyrrhizinate group. The high-dose chitosan group had the best outcome, with liver tissues exhibiting no signs of pseudolobules, ballooning degeneration or fatty degeneration. The functional status of the high-dose group improved rapidly. The other groups exhibited certain improvements, although their overall recovery was worse compared with the high-dose chitosan group (Fig. 4 and Table II). These results indicated that chitosan reduced hepatocellular damage and improved liver function in HF rats, with the highest dose having the best treatment effect.

Effect of chitosan on the expression levels of α -SMA and COL3 in rats with HF. The expression levels of α -SMA were significantly decreased in all treatment groups compared with the HF group (Fig. 5A). α -SMA expression levels were lowest in the liver tissues of rats in the high-dose chitosan group and in the glycyrrhizinate group. The α -SMA expression levels were decreased to a lesser extent in the low-dose chitosan group. Notably, alterations in α -SMA expression levels in each

experimental group were in line with the corresponding H&E staining results. The expression levels of COL3 in the liver tissues of the treatment groups were lower compared with the HF group (Fig. 5B). The high-dose chitosan group displayed a significant reduction in COL3 expression compared with the HF group (P<0.01). The middle-dose and glycyrrhizinate groups displayed a less significant reduction after 21 days of treatment (P<0.05).

Discussion

CCl₄-induced hepatotoxicity is caused by the reductive dehalogenation of CCl₄ catalyzed by CYP450 in the endoplasmic reticulum of liver cells, generating unstable trichloromethyl (CCl₃[•]) and trichloromethyl peroxy (CCl₃OO[•]) radicals. Free radicals attack and covalently bind to microsomal lipids and proteins, leading to lipid peroxidation and the initiation of secondary biochemical processes that ultimately cause the pathological consequences associated with CCl₄ (23,24). Similar to CCl₄, acetaminophen has also been used to induce

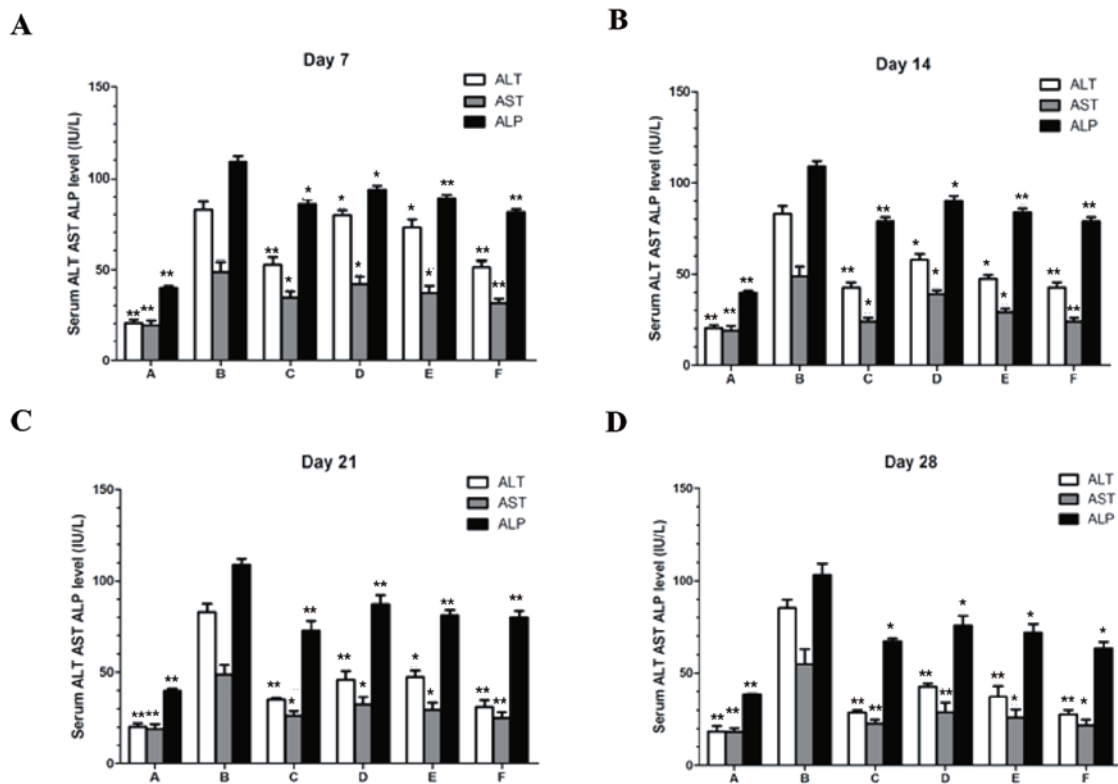


Figure 3. Serum levels of ALT, AST and ALP in the different experimental groups. Serum levels were measured following (A) 7, (B) 14, (C) 21 and (D) 28 days of treatment. Group A, control group; group B, hepatic fibrosis; group C, glycyrrhizinate; group D, 2.5 mg/kg chitosan; group E, 5 mg/kg chitosan; and group F, 10 mg/kg chitosan. * $P < 0.05$ and ** $P < 0.01$ vs. group B. ALP, alkaline phosphatase; ALT, alanine transaminase; AST, aspartate transaminase.

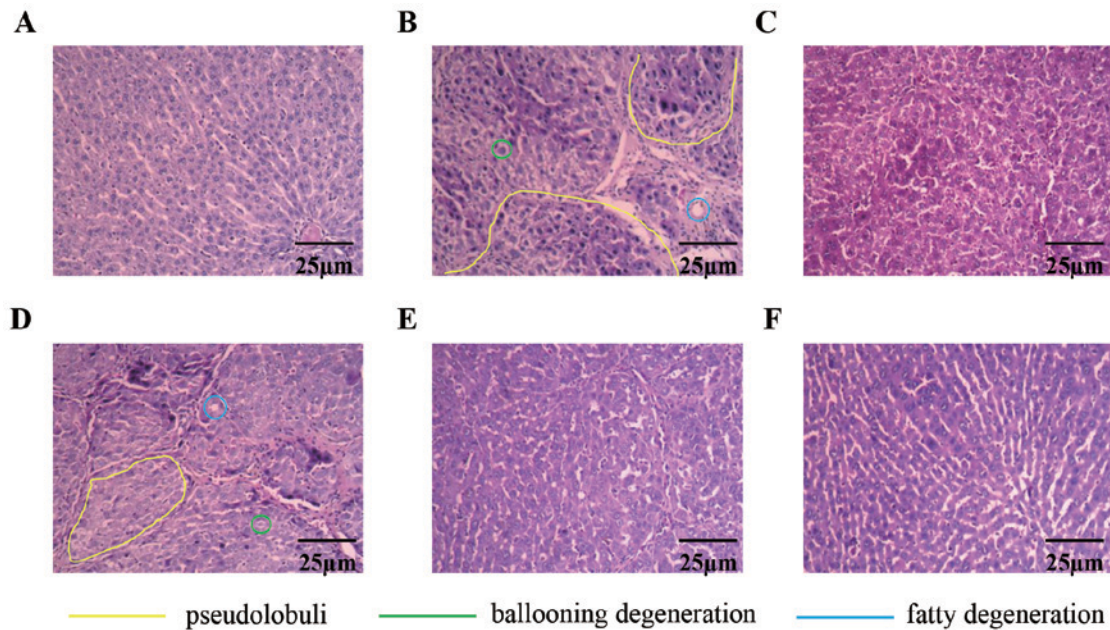


Figure 4. Hematoxylin and eosin staining of liver sections from rats. (A) Control group, (B) hepatic fibrosis, (C) glycyrrhizinate, (D) 2.5 mg/kg chitosan, (E) 5 mg/kg chitosan and (F) 10 mg/kg chitosan group. Yellow lines indicate pseudolobuli, green lines indicate ballooning degeneration, and blue lines indicate fatty degeneration.

hepatic injury in rats to test potential drug targets (25,26). In the present study, treatment with CCl_4 resulted in hepatotoxicity, as confirmed by increased serum liver enzyme levels (ASP, ALT and AST) and abnormal liver histology. In addition, alterations in the expression levels of COL3 and α -SMA were

measured, which are two important markers for the development of liver cirrhosis (27). These may also be associated with liver immune cell function, which merits further study.

Chitosan is widely used due to its anti-inflammatory and anti-oxidative properties; therefore, it was hypothesized that

Table II. Degree of liver fibrosis in each treatment group on day 28.

Group (n=10)	Scores					P-value
	0	1	2	3	4	
A, healthy rats (Control)	10	0	0	0	0	<0.05
B, hepatic fibrosis	0	0	0	1	9	-
C, glycyrrhizinate	0	6	4	0	0	<0.05
D, chitosan (2.5 mg/kg)	0	0	8	2	0	<0.05
E, chitosan (5 mg/kg)	0	7	3	0	0	<0.05
F, chitosan (10 mg/kg)	2	6	2	0	0	<0.05

Liver fibrosis was scored based on a modified non-alcoholic fatty liver disease scale in which increasing scores indicated greater severity. Significance was determined by non-parametric Kruskal-Wallis test followed by a Dunn's test for paired comparisons.

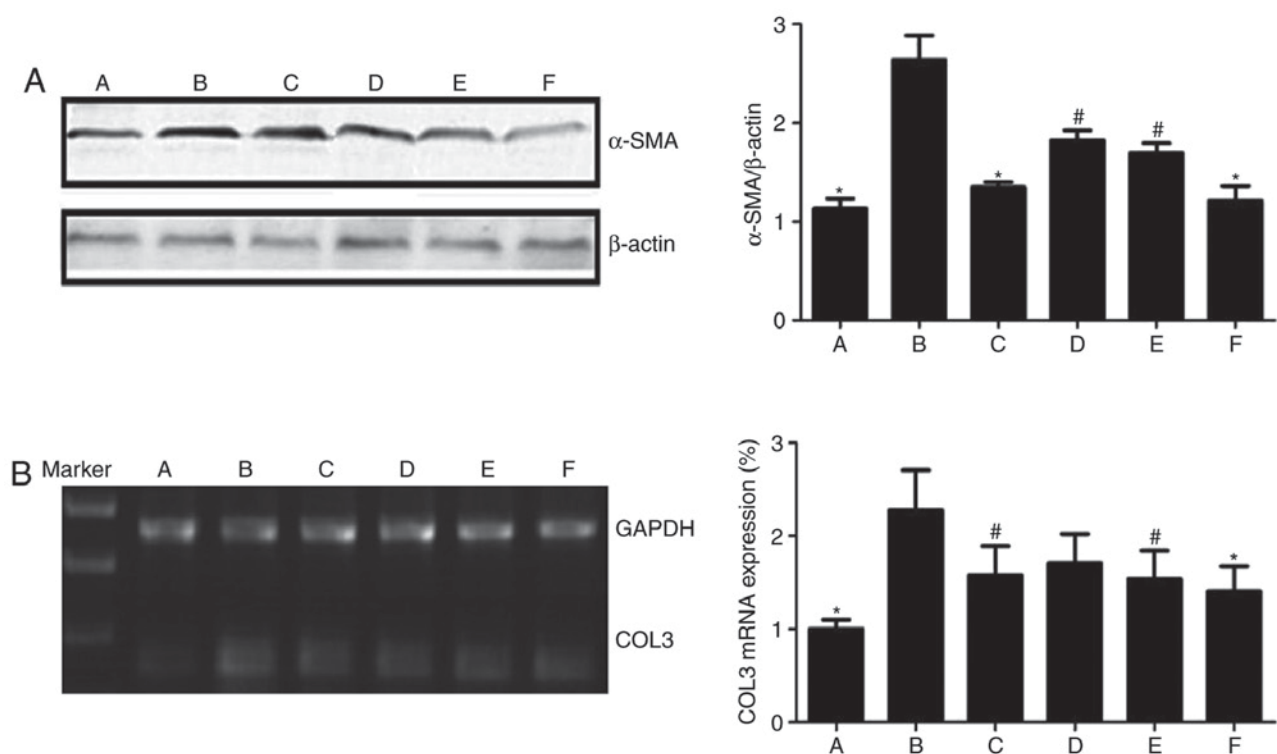


Figure 5. Effect of treatment with chitosan on α -SMA and COL3 expression in rats with hepatic fibrosis. (A) Western blot analysis of α -SMA and (B) reverse transcription-semiquantitative polymerase chain reaction of COL3 in each experimental group (A, control group; B, hepatic fibrosis; C, glycyrrhizinate; D, 2.5 mg/kg chitosan; E, 5 mg/kg chitosan; F, 10 mg/kg chitosan). Relative quantification is presented on the right. * $P<0.05$ and # $P<0.01$ vs. group B. COL, collagen; α -SMA, α -smooth muscle actin.

it may inhibit free radical action in a model of CCl_4 -induced HF, and may resolve HF or inhibit its progression. In the present study, all three doses of chitosan reduced serum liver enzyme levels. However, the high-dose chitosan (10 mg/kg) treatment group demonstrated the most marked improvement, as indicated by reduced hepatocellular damage and an improved fibrotic liver status. The histopathological observations and scores were also in accordance with the biochemical data. Notably, treatment with high-dose chitosan improved the liver histoarchitecture and resulted in better recovery compared with the glycyrrhizinate-treated positive control group.

Liver fibrosis is associated with production of collagens, including COL1 and COL3, in the hepatic ECM, primarily by HSCs. During HSC activation, these cells undergo morphological and phenotypic alterations towards myofibroblasts, and exhibited upregulated α -SMA expression (28). Notably, myofibroblast-like cells also produce COL1 in HF. In the present study, western blot analysis revealed that treatment with low-dose chitosan significantly decreased the expression levels of α -SMA and COL3. These data indicate that chitosan may protect liver cells from CCl_4 -induced HF by inhibiting activation of HSCs, as well as their subsequent production of COL1 and COL3.

The hepatoprotective effects of chitosan against hepatotoxicity may also rely on other mechanisms. Chitosan is known for its anti-inflammatory effects, which may be protective against CCl₄-induced infiltration of inflammatory cells in the liver. Furthermore, the antioxidative activity of chitosan may inhibit lipid peroxidation. Chitosan may also regulate the expression of antioxidant enzymes, including catalase and superoxide dismutase.

In conclusion, chitosan offers notable protection against CCl₄-induced hepatotoxicity, as confirmed by the reversal of various biochemical and histological indices. The protective effects of chitosan against liver damage may be due to its ability to inhibit HSC activation, and inhibit the production of COL1 and COL3. However, other mechanisms may be involved in the protective effects of chitosan. Owing to the hepatoprotective potential of chitosan, it may have clinical importance and may offer a novel therapeutic strategy for treating liver diseases.

Acknowledgements

Not applicable.

Funding

The present study was supported in part by a Special Financial Grant from the China Postdoctoral Science Foundation (grant no. 2018T110251), the Jilin Provincial Natural Science Foundation of China (grant no. 20140520014JH, to HJL; grant no. 20180101135JC, to HMX), the Interdisciplinary Chemistry and Medicine Foundation of Jilin University (grant no. YDYYJCHX004), and the National Natural Science Foundation of China (grant no. 31470418, to YFH).

Availability of data and materials

All data generated or analyzed during this study are included in this published article.

Authors' contributions

ZFW and PJG planned and performed the experiments, analyzed data and wrote the manuscript. MYW, DHY, YZ, HMX, SZ and WYS performed the experiments. YFH and JQN performed the animal experiments and analyzed the data. HJL designed, interpreted and part funded the study, and wrote the manuscript.

Ethics approval and consent to participate

The present study was approved by the medical ethics committee of The First Hospital of Jilin University (Changchun, China).

Patient consent for publication

Not applicable.

Competing interests

The authors declare that they have no competing interest.

References

1. Ali A and Ahmed S: A review on chitosan and its nanocomposites in drug delivery. *Int J Biol Macromol* 109: 273-286, 2018.
2. Kurita K, Koyama Y, Inoue S and Nishimura S: ((Diethylamino) ethyl) chitins: Preparation and properties of novel aminated chitin derivatives. *Macromolecules* 23: 2865-9, 1990.
3. Andrew CA, Khor E and Hastings GW: The influence of anionic chitin derivatives on calcium phosphate crystallization. *Biomaterials* 19: 1309-1316, 1998.
4. Liu X, Gu X, Sun J and Zhang S: Preparation and characterization of chitosan derivatives and their application as flame retardants in thermoplastic polyurethane. *Carbohydr Polym* 167: 356-363, 2017.
5. Fonseca-Santos B and Chorilli M: An overview of carboxymethyl derivatives of chitosan: Their use as biomaterials and drug delivery systems. *Mater Sci Eng C Mater Biol Appl* 77: 1349-1362, 2017.
6. Abdel-Latif M, El-Shahawi G, Aboelhadid SM and Abdel-Tawab H: Immunoprotective effect of Chitosan particles on *hymenolepis nana*-infected mice. *Scand J Immunol* 86: 83-90, 2017.
7. Comblain F, Rocasalbas G, Gauthier S and Henrotin Y: Chitosan: A promising polymer for cartilage repair and viscosupplementation. *Biomed Mater Eng* 28: S209-S215, 2017.
8. Yar M, Shahzad S, Shahzadi L, Shahzad SA, Mahmood N, Chaudhry AA, Rehman U and MacNeil S: Heparin binding chitosan derivatives for production of pro-angiogenic hydrogels for promoting tissue healing. *Mater Sci Eng C Mater Biol Appl* 74: 347-356, 2017.
9. Ming Guo and Yanfei Ma: Synthesis, anti-oxidant activity, and biodegradability of a novel recombinant polysaccharide derived from chitosan and lactose. *Carbohydrate Polymers* 118: 218-223, 2015.
10. Dey A and Cederbaum AI: Alcohol and oxidative liver injury. *Hepatology* 43: S63-S74, 2006.
11. Sun KH, Chang Y, Reed NI and Sheppard D: α -Smooth muscle actin is an inconsistent marker of fibroblasts responsible for force-dependent TGF β activation or collagen production across multiple models of organ fibrosis. *Am J Physiol Lung Cell Mol Physiol* 310: L824-L836, 2016.
12. Iwaisako K, Jiang C, Zhang M, Cong M, Moore-Morris TJ, Park TJ, Liu X, Xu J, Wang P, Paik YH, *et al*: Origin of myofibroblasts in the fibrotic liver in mice. *Proc Natl Acad Sci USA* 111: E3297-E3305, 2014.
13. Hong IH, Park SJ, Goo MJ, Lee HR, Park JK, Ki MR, Kim SH, Lee EM, Kim AY and Jeong KS: JNK1 and JNK2 regulate α -SMA in hepatic stellate cells during CCl₄-induced fibrosis in the rat liver. *Pathol Int* 63: 483-491, 2013.
14. Svegliati Baroni G, D'Ambrosio L, Ferretti G, Casini A, Di Sario A, Salzano R, Ridolfi F, Saccomanno S, Jezequel AM and Benedetti A: Fibrogenic effect of oxidative stress on rat hepatic stellate cells. *Hepatology* 27: 720-726, 1998.
15. Ghatak S, Biswas A, Dhali GK, Chowdhury A, Boyer JL and Santra A: Oxidative stress and hepatic stellate cell activation are key events in arsenic induced liver fibrosis in mice. *Toxicol Appl Pharmacol* 251: 59-69, 2011.
16. Peng L, Jia X, Zhao J, Cui R and Yan M: Substance P promotes hepatic stellate cell proliferation and activation via the TGF- β 1/Smad-3 signaling pathway. *Toxicol Appl Pharmacol* 329: 293-300, 2017.
17. Lee YS, Kim SY, Ko E, Lee JH, Yi HS, Yoo YJ, Je J, Suh SJ, Jung YK and Kim JH: Exosomes derived from palmitic acid-treated hepatocytes induce fibrotic activation of hepatic stellate cells. *Sci Rep* 7: 3710, 2017.
18. Friedman SL: Liver fibrosis-from bench to bedside. *J Hepatol* 38 (Suppl 1): S38-S53, 2003.
19. Wang L, Feng Y, Ma X, Wang G, Wu H, Xie X, Zhang C and Zhu Q: Diagnostic efficacy of noninvasive liver fibrosis indexes in predicting portal hypertension in patients with cirrhosis. *PLoS One* 12: e0182969, 2017.
20. Chang CC, Lee WS, Chuang CL, Hsin IF, Hsu SJ, Chang T, Huang HC, Lee FY and Lee SD: Effects of raloxifene on portal hypertension and hepatic encephalopathy in cirrhotic rats. *Eur J Pharmacol* 802: 36-43, 2017.
21. Brunt EM, Janney CG, Di Bisceglie AM, Neuschwander-Tetri BA and Bacon BR: Nonalcoholic steatohepatitis: A proposal for grading and staging the histological lesions. *Am J Gastroenterol* 94: 2467-2474, 1999.

22. Kleiner DE, Brunt EM, Van Natta M, Behling C, Contos MJ, Cummings OW, Ferrell LD, Liu YC, Torbenson MS, Unalp-Arida A, *et al*: Design and validation of a histological scoring system for nonalcoholic fatty liver disease. *Hepatology* 41: 1313-1321, 2005.
23. Li M, Wang XF, Shi JJ, Li YP, Yang N, Zhai S and Dang SS: Caffeic acid phenethyl ester inhibits liver fibrosis in rats. *World J Gastroenterol* 21: 3893-3903, 2015.
24. Subhapradha N, Saravanan R, Saravanan P, Srinivasan A, Shanmugam V and Shanmugam A: Hepatoprotective effect of β -chitosan from gladius of *Sepioteuthis lessoniana* against carbon tetrachloride-induced oxidative stress in Wistar rats. *Appl Biochem Biotechnol* 172: 9-20, 2014.
25. Ramasamy P, Subhapradha N, Shanmugam V and Shanmugam A: Protective effect of chitosan from *Sepia kobsiensis* (Hoyle 1885) cuttlebone against CCl₄ induced hepatic injury. *Int J Biol Macromol* 65: 559-563, 2014.
26. Ozcelik E, Uslu S, Erkasap N and Karimi H: Protective effect of chitosan treatment against acetaminophen-induced hepatotoxicity. *Kaohsiung J Med Sci* 30: 286-290, 2014.
27. Bai Q, Yan H, Sheng Y, Jin Y, Shi L, Ji L and Wang Z: Long-term acetaminophen treatment induced liver fibrosis in mice and the involvement of Egr-1. *Toxicology* 382: 47-58, 2017.
28. Natarajan K, Singh S, Burke TR Jr, Grunberger D and Aggarwal BB: Caffeic acid phenethyl ester is a potent and specific inhibitor of activation of nuclear transcription factor NF-kappa B. *Proc Natl Acad Sci USA* 93: 9090-9095, 1996.



This work is licensed under a Creative Commons Attribution-NonCommercial-NoDerivatives 4.0 International (CC BY-NC-ND 4.0) License.