

Expression of c-Kit and PDGFR α in epithelial ovarian tumors and tumor stroma

CUNJIAN YI, LI LI, KEMING CHEN, SHENGRONG LIN and XIANGQIONG LIU

Department of Obstetrics and Gynecology, First Affiliated Hospital, Yangtze University,
Jingzhou, Hubei 434000, P.R. China

Received June 3, 2011; Accepted October 11, 2011

DOI: 10.3892/ol.2011.481

Abstract. The purpose of this study was to investigate the expression of c-Kit and platelet-derived growth factor receptor α (PDGFR α) in epithelial ovarian tumor cells and tumor stroma. The expression of c-Kit and PDGFR α in 71 malignant or benign epithelial ovarian tumor tissues and 20 normal ovarian tissues was evaluated by immunohistochemical staining. The expression of c-Kit and PDGFR α in 71 malignant epithelial ovarian tumors and tumor stroma tissue samples was analyzed. A significant increase ($P<0.01$) of c-Kit expression was observed in malignant ovarian tumors (50.7%) when compared to normal ovarian tissues (10.0%) or benign ovarian tumors (20.0%). The PDGFR α expression rate in malignant ovarian tumors (63.4%) was also significantly higher ($P<0.01$) than that in normal ovarian tissues (15.0%) or benign ovarian tumors (25.0%). c-Kit was expressed in only 4.2% of the tumor stroma samples, which was significantly lower than the expression of malignant ovarian tumors ($P<0.01$), whereas the PDGFR α expression in tumor stroma (87.3%) was significantly higher than that of the malignant ovarian tumors ($P<0.01$). The expression levels of c-Kit and PDGFR α are higher in the malignant ovarian tumors than in the benign ovarian tumors or normal tissues. In the malignant ovarian tumor stroma, c-Kit expression is low and PDGFR α expression is high, and the differential changes of c-kit and PDGFR α suggest distinct roles in ovarian cancer.

Introduction

Intracellular and extracellular signal transduction is capable of driving tumor formation. The upregulated signaling of tyrosine kinases plays crucial roles in the regulation of cell growth and differentiation, and exhibits direct correlations with cancer progression. c-Kit and platelet-derived growth factor receptor (PDGFR) belong to the class III receptor tyro-

sine kinase (RTK) family. Previous studies reported that c-Kit and PDGFR were associated with cell proliferation, invasiveness and metastasis of malignant tumors (1,2).

The expression and activation of c-Kit are well documented in a variety of human tumors including myeloid leukemia, GIST, lung cancer and breast carcinoma (3-5). The expression of c-Kit in epithelial ovarian tumors was previously described. However, the results obtained from human tissues showed specific new information to add to previous studies (6). At present, there are few reports on c-Kit expression in ovarian stromal tissues.

PDGFR α and β are involved in a variety of physiological and pathological processes, such as cell growth and survival, transformation, migration, vascular permeability, stroma modulation and wound healing. The expression of PDGFR in ovarian tumors was previously reported (2,6). PDGFR α exhibits different expression profiles in ovarian carcinoma and normal ovarian epithelium. Its expression is often linked to poor prognosis (7) and aggressive tumor characteristics (8). PDGFR expression in epithelial ovarian tumor cells and tumor stroma has not been well studied.

We previously reported the overexpression of c-Kit and PDGFR α in epithelial ovarian tumors (9). In the present study, we systematically investigated c-Kit and PDGFR α expression in malignant and benign epithelial ovarian tumors, normal tissues and tumor stroma. Our hypothesis is that the c-Kit and PDGFR-dependent tumor-stromal interactions may play significant roles in the growth of normal epithelial cells and the development of tumorigenic tissues as well.

Materials and methods

Tissue sources. This study was approved by the Institutional Review Board of the First Affiliated Hospital, Yangtze University, China. Written informed consent was obtained prior to enrollment. Tissues from 71 malignant and 20 benign epithelial ovarian tumors were collected between January 1997 and January 2006. The age of the patients ranged from 28 to 65 years, with a mean age of 43 years. The benign ovarian epithelial tumors included 10 serous and 10 mucinous cystadenomas, and the malignant ovarian epithelial tumors included 59 serous and 12 mucinous cystadenomas. These 71 malignant ovarian tumors were composed of 45 low-grade (well-differentiated) and 26 high-grade (poorly-differentiated)

Correspondence to: Dr Xiangqiong Liu, Department of Obstetrics and Gynecology, First Affiliated Hospital, Yangtze University, Jingzhou, Hubei 434000, P.R. China
E-mail: cunjianyi@yahoo.com.cn

Key words: PDGFR α , c-Kit, ovarian cancer

Table I. Expression level of c-Kit and PDGFR α in different types of tissues.

Tissue types	Case (n)	c-Kit expression		PDGFR α expression	
		Positive (n)	Positive rate (%)	Positive (n)	Positive rate (%)
Normal ovarian tissues	20	2	10.0	3	15.0
Benign ovarian tumors	20	4	20.0 ^a	5	25.0 ^a
Malignant ovarian tumors	71	36	50.7 ^b	45	63.4 ^b

^aP>0.05 (benign ovarian tumor tissues vs. normal ovarian tissues); ^bP<0.01 (malignant ovarian tumors vs. benign ovarian tumor tissues or normal ovarian tissues).

tumors. According to the Federation of Gynecology and Obstetrics (FIGO) of 1998, 30 cases were at stage I-II, and 41 were at stage III-IV. A total of 20 normal ovarian tissues were collected as controls from patients following surgery for uterine fibroids.

Immunohistochemistry. Tissue sections (4 μ m) were cut from paraffin-embedded tissue blocks. The sections were deparaffinized in xylene, rehydrated in an ethanol gradient and rinsed in phosphate-buffered saline (PBS). Sections were then heated in EDTA buffer at 95°C for 8 min for antigen retrieval. Endogenous peroxidase activity was quenched by incubation in 3% hydrogen peroxide at 37°C for 10 min. The sections were incubated with primary mouse monoclonal antibody against human c-Kit or PDGFR α (Fuzhou Maxim Biotech Co., China) at room temperature for 60 min in a humid chamber. The sections were stained using a commercial kit (Fuzhou Maxim Biotech Co.) and visualized using freshly prepared solutions of diaminobenzidine (DAB) (Maxim Biotech Inc.). The specimens were counterstained with hematoxylin and mounted with mounting medium. Positive controls (including GIST for c-Kit and breast carcinoma for PDGFR α) were also performed to confirm antibody staining.

Evaluation of immunohistochemical staining. Staining was considered as positive when cytoplasmic or membranous staining was observed. Semi-quantitative analysis of the immunostaining for c-Kit or PDGFR α was performed according to the procedures described previously (9). The percentage of immunoreactive cells for each area was determined using a score of 0-3 (0, 0-5% ; 1, 6-25% ; 2, 26-50%; and 3, 51-100% stained cells). The staining intensity was also scored as 0-3 (0, negative; 1, weak; 2, moderate; and 3, strong). In each slide, the expression level scores of c-Kit or PDGF were achieved by amplifying the scores of staining intensity to the number of stained cells. The expression levels of c-Kit or PDGFR α were evaluated according to following scoring criteria: grade 0 or - (score 0-1); grade 1 or + (scores 2-3); grade 2 or ++ (scores 4-6); and grade 3 or +++ (scores 6-9). Specimens with grade 1 were regarded as having a weakly positive expression, whereas grades 2 and 3 were defined as having a strongly positive expression or overexpression.

Statistical analysis. The differences in c-Kit and PDGFR α expression among benign and malignant epithelial ovarian tumors, normal tissues and tumor stroma were analyzed using

the Chi-square test. P \leq 0.05 was considered to be statistically significant.

Results

Expression of c-Kit and PDGFR α in normal ovarian, benign and malignant ovarian tumor tissues. Based on the immunohistochemical staining, 10.0% of the normal ovarian tissue samples and 20.0% of the benign ovarian epithelial tumor samples were positive for c-Kit expression (Table I). No significant difference in expression levels of c-Kit in normal ovarian tissues and benign ovarian epithelial tumors was observed (P>0.05). In contrast, c-Kit was positively expressed in 50.7% of the malignant ovarian tumor tissues (Table I). The expression level of c-Kit in malignant ovarian tumors was found to be significantly higher (P<0.01) when compared to the normal ovarian tissues and benign ovarian tumors.

Similarly, no significant difference (P>0.05) was found in PDGFR α expression in normal ovarian tissues and benign ovarian tumors. In the normal ovarian tissues and benign ovarian tumors, 15.0 and 25.0% of the tissues and tumors, respectively, were positive for PDGFR α expression (Table I). PDGFR α was positively expressed in 63.4% of the malignant ovarian tumor tissues (Table I). The expression level of PDGFR α in malignant ovarian tumor was also found to be significantly higher (P<0.01) when compared to the normal ovarian tissues and benign ovarian tumors.

Correlation of c-Kit and PDGFR α expression with clinicopathological parameters. To characterize the grade-specific expression of these kinases, tumors were subdivided into two categories: low-grade (Grade 1 and 2) and high-grade (Grade 3). c-Kit or PDGFR α was expressed more highly in the high-grade tumors, and the difference between groups was statistically significant (P<0.05). Although c-Kit and PDGFR α were expressed more highly in the FIGO clinical stages III-IV than in stages I-II, the difference between groups was not statistically significant (P>0.05). Compared with mucinous carcinomas, the expression of c-Kit in the serous carcinomas was higher (P<0.05), but the expression of PDGFR α showed no difference between serous and mucinous carcinomas (P>0.05).

Expression of c-Kit and PDGFR α in malignant epithelial ovarian tumor and stroma. The expression level of c-Kit in tumor stroma was significantly lower than that of malignant epithelial ovarian tumor tissues (P<0.01). In tumor stroma,

Table II. Expression of c-Kit and PDGFR α in malignant epithelial ovarian tumors and tumor stroma.

Tissue types	Case (n)	c-Kit expression		PDGFR α expression	
		Positive (n)	Positive rate (%)	Positive (n)	Positive rate (%)
Epithelial ovarian tumors	71	36	50.7	45	63.4
Tumor stroma	71	3	4.2 ^a	62	87.3 ^a

^aP<0.01 (epithelial ovarian tumors vs. tumor stroma).Table III. Expression of c-Kit and PDGFR α in samples of various clinical stages (FIGO) and histological subtypes of ovarian serous carcinomas.

	Case	c-Kit expression			PDGFR α expression		
		Positive (n)	Positive rate (%)	P-value	Positive (n)	Positive rate (%)	P-value
Grade				<0.05			<0.05
1,2	45	18	40.0		24	53.3	
3	26	18	69.2		21	28.8	
Stage				<0.05			<0.05
I-II	30	12	40.0		18	60.0	
III-IV	41	24	58.5		27	65.9	
Histologic subtype				<0.05			<0.05
Serous	59	34	57.6		39	66.1	
Mucinous	12	2	16.7		6	50.0	

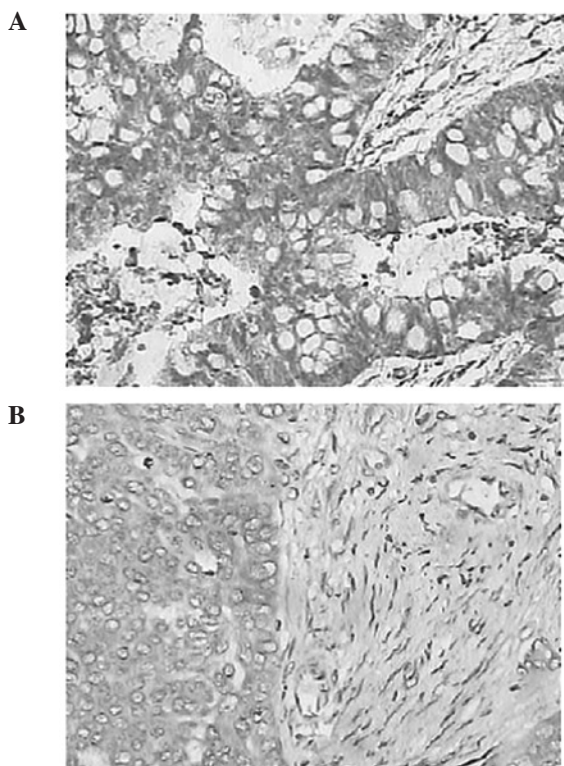


Figure 1. Immunohistochemical staining of c-Kit or PDGFR α in malignant ovarian tumor and tumor stroma. (A) Positive expression of c-Kit in the tumor tissue and negative expression of c-Kit in tumor stroma (magnification, $\times 400$). (B) Positive expression of PDGFR α in the tumor tissue and the tumor stroma (magnification, $\times 200$).

only 4.2% of the tissues were positive for c-Kit expression, whereas 50.7% of the malignant ovarian tumors were positive (Table II). As shown in Table II, although PDGFR α was highly expressed in malignant epithelial ovarian tumor tissues (63.4%) and tumor stroma (87.3%), the expression level of PDGFR α in tumor stroma was significantly higher than that in malignant epithelial ovarian tumors (P<0.01). The representative immunohistochemical staining images are shown in Fig. 1.

Discussion

Ovarian cancer is often variable in response to treatment. Effective molecular markers that are capable of stratifying patient tumors are essential to determine the best treatment options for patients. The type III tyrosine kinases c-Kit and PDGFR have been extensively investigated in human epithelial ovarian cancer as potential molecular markers. However, the previously reported c-Kit and PDGFR expression levels in ovarian tumors are inconsistent and occasionally even contradictory to each other. For example, Parrott *et al* (10) reported c-Kit expression in normal ovarian surface epithelium, but this finding has not been confirmed by other studies (6,11). In ovarian carcinomas, a high expression of c-Kit has been demonstrated (6,10,11). However, other studies have shown lower levels of c-Kit expression (12,13). Similarly, the reported level of PDGFR α expression in ovarian carcinomas ranges from 5 to 100% (7,14,15). Thus, further evaluation of c-Kit

and PDGFR expression in ovarian cancer is required. In the present study, we showed a significantly higher expression of c-Kit and PDGFR α in malignant ovarian tumors when compared to normal ovarian tissues and benign ovarian tumors. No significant difference was observed in c-Kit and PDGFR α expression in normal ovarian tissues and benign ovarian tumors. These results suggest that a high expression of c-Kit and PDGFR α is associated with the malignant form of ovarian tumor. Therefore, it is possible to distinguish malignant ovarian tumors from benign tumors or normal tissues by examining c-Kit and PDGFR α expression.

In the current study, the positive staining of c-Kit and PDGFR α in the low-differentiated grade group was higher than that in the high- and middle-differentiated grade groups (Table III). The detection of c-Kit and PDGFR α proteins may be useful for examining the differential degree of malignancy and the prognosis of patients with epithelial ovarian carcinomas. The expression of c-Kit in the serous carcinomas was higher as compared with the mucinous carcinomas, but no difference was observed in the expression of PDGFR α between serous and mucinous carcinomas. The overexpression of c-Kit is actually more closely associated with tumorigenesis and development of the serous ovarian carcinomas.

The interactions between ovarian epithelial cells and stromal cells also exhibit crucial biological functions, such as involvement in the formation of a variety of extracellular matrix components (16). The ovarian epithelial tumorigenic tissues, as well as most ovarian tumors, have a close correlation with tumor stromal tissues. Therefore, the interactions between stromal and ovarian epithelial cells may play a key role in the growth of normal epithelial cells and the development of tumorigenic tissues. However, the role of tumor stromal tissues in the development of ovarian cancer is not well understood.

Findings of the present study demonstrated a high PDGFR α expression but a low c-Kit expression in the tumor stroma of the malignant ovarian tumors. These results suggest that the major functions of c-Kit and PDGFR α during the formation of epithelial ovarian cancer may be different. c-Kit is mainly expressed in ovarian cancer cells. Over-activated c-Kit results in the inhibition of apoptosis and cell proliferation in the tumor. By contrast, a high expression of PDGFR α in stromal tissues of ovarian cancer may be beneficial for the growth, invasion and metastasis of ovarian tumors by promoting cell proliferation and angiogenesis (17). PDGFR was found to be highly expressed in fibroblasts, pericytes and endothelial cells (18,19). Blocking PDGFR is capable of changing the tumor microenvironment by increasing stroma permeability and inhibiting angiogenesis, thus affecting tumor cells directly. Blocked PDGFR signaling may also enhance chemotherapy delivery (17). Whether c-Kit and PDGFR are capable of synergistically affecting the development of ovarian cancer requires further study.

Acknowledgements

This study was supported by the Research Foundation of the Health Department of Hubei Province (JX3C54).

References

1. Marcia LL, Brian PR, Tara LB, *et al*: KIT extracellular and kinase domain mutations in gastrointestinal stromal tumors. *Am J Pathol* 156: 791-795, 2000.
2. Matei D, Chang DD and Jeng MH: Imatinib mesylate (Gleevec) inhibits ovarian cancer cell growth through a mechanism dependent on platelet-derived growth factor receptor alpha and Akt inactivation. *Clin Cancer Res* 10: 681-690, 2004.
3. Malaise M, Steinbach D and Corbacioglu S: Clinical implications of c-Kit mutations in acute myelogenous leukemia. *Curr Hematol Malig Rep* 4: 77-82, 2009.
4. Chi P, Chen Y, Zhang L, *et al*: ETV1 is a lineage survival factor that cooperates with KIT in gastrointestinal stromal tumours. *Nature* 467: 849-853, 2010.
5. Schneider BJ, Kalemkerian GP, Ramnath N, *et al*: Phase II trial of imatinib maintenance therapy after irinotecan and cisplatin in patients with c-Kit-positive, extensive-stage small-cell lung cancer. *Clin Lung Cancer* 11: 223-227, 2010.
6. Schmandt RE, Broaddus R, Lu KH, *et al*: Expression of c-ABL, c-KIT, and platelet-derived growth factor receptor-beta in ovarian serous carcinoma and normal ovarian surface epithelium. *Cancer* 98: 758-764, 2003.
7. Henriksen R, Funa K, Wilander E, Bäckström T, Ridderheim M, and Oberg K: Expression and prognostic significance of platelet-derived growth factor and its receptors in epithelial ovarian neoplasms. *Cancer Res* 53: 4550-4554, 1993.
8. Lassus H, Sihto H, Leminen A, Nordling S, Joensuu H, Nupponen NN and Butzow R: Genetic alterations and protein expression of KIT and PDGFR α in serous ovarian carcinoma. *Br J Cancer* 91: 2048-2055, 2004.
9. Yi CJ, Lin SR and Chen KM: Expression and clinical significance of c-kit and PDGFR α in ovarian serous carcinomas. *Chinese Journal of Gynecology and Obstetrics* 22: 295-296, 2006.
10. Parrott JA, Kim G and Skinner MK: Expression and action of kit ligand/stem cell factor in normal human and bovine ovarian surface epithelium and ovarian cancer. *Biol Reprod* 62: 1600-1609, 2000.
11. Tonary AM, Macdonald EA, Faught W, Senterman MK and Vanderhyden BC: Lack of expression of c-KIT in ovarian cancers is associated with poor prognosis. *Int J Cancer* 89: 242-250, 2000.
12. Arber DA, Tamayo R and Weiss LM: Paraffin section detection of the c-Kit gene product (CD117) in human tissues: value in the diagnosis of mast cell disorders. *Hum Pathol* 29: 498-504, 1998.
13. Singer G, Schraml P, Belgard C, *et al*: KIT in ovarian carcinoma: disillusion about a potential therapeutic target. *J Natl Cancer Inst* 95: 1009-1010, 2003.
14. Dabrow MB, Francesco MR, McBrearty FX and Caradonna S: The effects of platelet-derived growth factor and receptor on normal and neoplastic human ovarian surface epithelium. *Gynecol Oncol* 71: 29-37, 1998.
15. Apte SM, Bucana CD, Killian JJ, Gershenson DM and Fidler IJ: Expression of platelet-derived growth factor and activated receptor in clinical specimens of epithelial ovarian cancer and ovarian carcinoma cell lines. *Gynecol Oncol* 93: 78-86, 2004.
16. Vigne JL, Halburnt LL and Skinner MK: Characterization of bovine ovarian surface epithelium and stromal cells: identification of secreted proteins. *Biol Reprod* 51: 1213-1221, 1994.
17. Baranowska-Kortylewicz J, Abe M, Pietras K, *et al*: Effect of platelet-derived growth factor receptor-beta inhibition with STI571 on radioimmunotherapy. *Cancer Res* 65: 7824-7831, 2005.
18. Yu J, Moon A and Kim HR: Both platelet-derived growth factor receptor (PDGFR)-alpha and PDGFR-beta promote murine fibroblast cell migration. *Biochem Biophys Res Commun* 282: 697-700, 2001.
19. Bergers G, Song S, Meyer-Morse N, Bergsland E and Hanahan D: Benefits of targeting both pericytes and endothelial cells in the tumor vasculature with kinase inhibitors. *J Clin Invest* 111: 1287-1295, 2003.