

Primary adrenal nodular lymphocyte-predominant Hodgkin lymphoma: A case report and review of the literature

JINGJING WANG¹, JIN'AN MA¹, CHUNHONG HU¹, DAIQIANG LI² and XIAOLING SHE²

Departments of ¹Oncology and ²Pathology, The Second Xiangya Hospital of Central South University, Changsha, Hunan 410011, P.R. China

Received November 25, 2013; Accepted May 23, 2014

DOI: 10.3892/ol.2014.2289

Abstract. Nodular lymphocyte-predominant Hodgkin lymphoma (NLPHL) is a subtype of Hodgkin lymphoma (HL), and is a rare disease manifestation in the adrenal gland, which is difficult to be diagnosed and treated. In the present study, we report a case of primary adrenal NLPHL in a 36-year-old male patient. The patient was without specific clinical signs and the definitive diagnosis was achieved by histological study. The patient underwent a laparoscopic left adrenalectomy and chemotherapy regimen of doxorubicin, bleomycin, vinblastine and dacarbazine (ABVD). There is no standard treatment for adrenal NLPHL and therefore, treatment is based on that for other types of NLPHL, which includes radiotherapy and ABVD chemotherapy. Given the rarity of this disease, there are limited experiences with regard to its diagnosis and treatment. This study is useful for the differential diagnosis and treatment of adrenal masses.

Introduction

The majority of adrenal lesions are benign adrenal cortical adenomas. However, nodular lymphocyte-predominant Hodgkin lymphoma (NLPHL) is a rare disease manifestation in the adrenal gland. NLPHL is a subtype of Hodgkin lymphoma (HL), which represents ~5% of HLs and involves peripheral lymph nodes. NLPHL is a 'benign' disease which is characterized by an indolent course (1,2). Mortalities due to NLPHL are rare, however treatment toxicities and various secondary malignancies may contribute to the overall mortality rate. Secondary aggressive non-Hodgkin lymphoma may occur in ~7–14% of NLPHL cases, but the majority of NLPHL patients present at an early stage and have a favourable prognosis (3-6). The peripheral and most commonly the cervical

regions are involved (1,2). NLPHL has a peak incidence in the fourth decade of life with a significant male predominance (75%). B symptoms, extranodal involvement and bulky disease are particularly uncommon (7). We report a unique case of NLPHL affecting only the adrenal gland in a patient who was successfully diagnosed by histological examination, and treated with surgery and a chemotherapy regimen of doxorubicin, bleomycin, vinblastine and dacarbazine. This study was approved by the ethics committee of the Second Xiangya Hospital of Central South University (Changsha, China). Patient provided written informed consent.

Case report

Case presentation. A 36-year-old male presented at The Second Xiangya Hospital of Central South University (Changsha, China) with high fever and weight loss lasting for 10 days, as well as a left adrenal mass that had been identified one week previously. The patient had no history of hypertension and physical examination showed no abnormalities. A total body computed tomography (CT) scan revealed the presence of a large left adrenal mass measuring 4.5x5.5 cm in size (Fig. 1). No obvious abnormalities in the right adrenal gland, retroperitoneal area and other parts of the body were identified by CT. Bone marrow aspiration and biopsy were normal. Plasma metanephrine, plasma renin activity, serum aldosterone, dehydroepiandrosterone and basic metabolic panel test results were all normal. Routine hematological parameters and liver and kidney function tests were normal. Hepatitis B and C and human immunodeficiency virus serology test results were negative. In addition, Epstein-Barr virus (EBV) serology showed negativity for immunoglobulin M (IgM) and IgG antibodies. The patient subsequently underwent laparoscopic left adrenalectomy.

Pathology. The adrenalectomy specimen measured 5.5x4.0x4.0 cm. Microscopic examination revealed tumors of lymphoid-hematopoietic tissues in the adrenal tissue, which destroyed the adrenal gland and formed a mass in the retroperitoneum. Morphologically, the majority of atypical cells resembled lymphocyte-predominant (LP) cells. Immunohistochemical analysis showed that the tumor cells were negative for cluster of differentiation 30 (CD30) and EBV-encoded small RNAs (EBERs), and positive for CD20,

Correspondence to: Professor Jin'an Ma, Department of Oncology, The Second Xiangya Hospital of Central South University, 139 Renmin Road, Changsha, Hunan 410011, P.R. China
E-mail: majinancs@hotmail.com

Key words: nodular lymphocyte-predominant Hodgkin lymphoma, adrenal gland, histopathology.

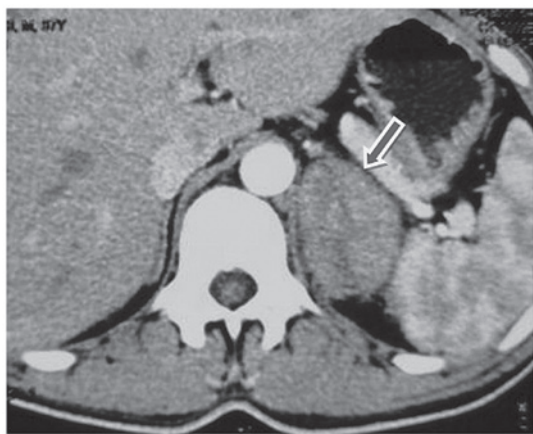

Figure 1. Abdominal computed tomography of the patient with primary adrenal nodular lymphocyte-predominant Hodgkin lymphoma. A soft tissue mass was observed in the left adrenal gland (arrow), measuring 4.5x5.5 cm, with a less uniform density and clear borders.

paired box protein 5, CD79a, octamer binding protein 2 and epithelial membrane antigen (EMA). Additionally, very few cells were positive for CD15. The tumor cells were surrounded by T cells, which were positive for CD3 and CD57 (Fig. 2). According to the immunohistochemistry results, the patient was diagnosed with primary adrenal NLPHL, stage IB according to the World Health Organization (WHO) (8).

Postoperative treatment. Systemic positron emission tomography (PET)-CT examination was conducted

following surgery, and there were no obvious abnormalities. Postoperative adjuvant chemotherapy was administered; the patient received four cycles of doxorubicin, bleomycin, vinblastine and dacarbazine (ABVD) regimen. This comprised 25 mg/m² doxorubicin (day 1 and 14), 10 mg/m² bleomycin (day 1 and 14), 6 mg/m² vinblastine (day 1 and 14) and 375 mg/m² dacarbazine (day 1 and 14), to be repeated every four weeks. The patient has been followed up for 16 months from the end of chemotherapy, with a stable condition and no recurrence.

Discussion

According to the present WHO classification, HLs comprise two disease entities: NLPHL and classical HL (cHL) (8). cHL represents ~95% of HLs, while NLPHL is rare, representing ~5%. NLPHL has a male predominance and typically presents in middle-aged individuals. NLPHL frequently presents as localized disease and has a good outcome. The ten year overall survival rate for early-stage patients is ~85-100% (3,4). Approximately 20-25% of NLPHL patients present with an advanced stage of the disease. Xing *et al* (9) demonstrated that the ten year overall survival for patients with advanced NLPHL is 86%. The most common sites of involvement are the peripheral lymph nodes, and disease manifestation in the adrenal gland is rare. To the best of our knowledge, only three cases of primary adrenal HL have been reported worldwide, two of which were adrenal cHL (10,11) and one of which was composite lymphoma of NLPHL and cHL concurrently affecting the same lymph nodes (12).

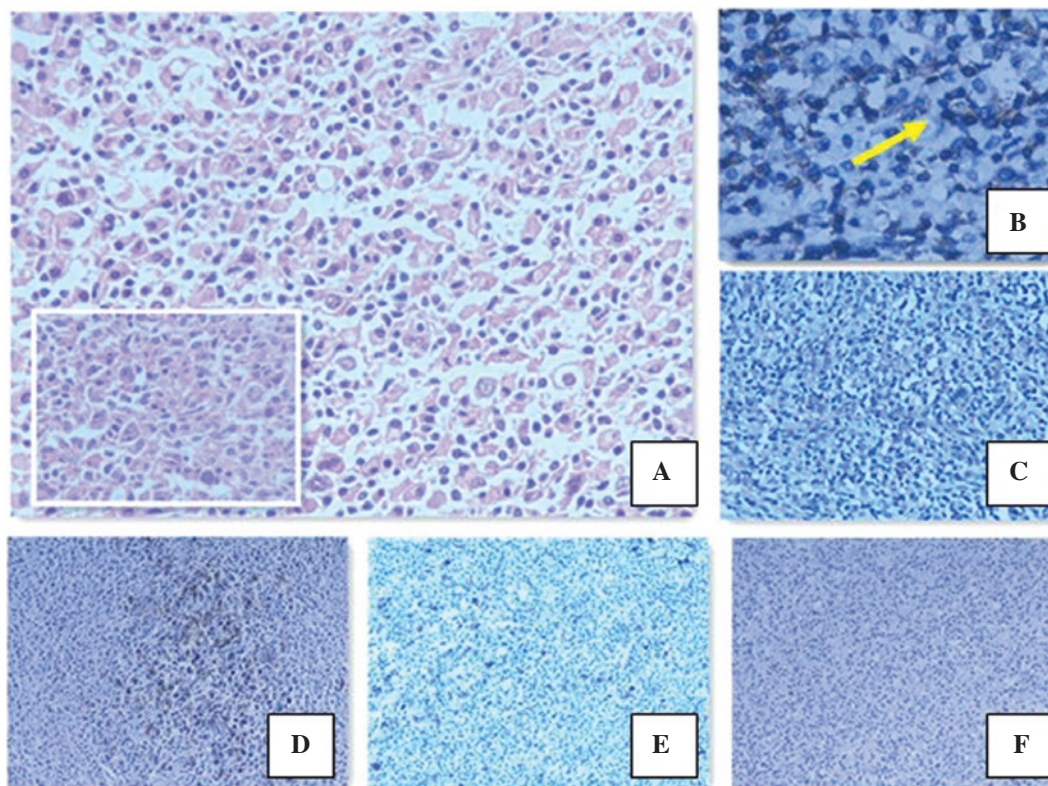


Figure 2. Histological and immunohistochemical analysis of the pathological tissue of the patient with primary adrenal nodular lymphocyte-predominant Hodgkin lymphoma. (A) Hematoxylin and eosin staining of the tumor tissue (magnification of main image, x200; magnification of the smaller image, x400). (B) CD3⁺ T-cell rosettes surrounding the tumor cells as indicated by the arrow (immunostaining; magnification, x200). (C) EMA⁺ LP cells (immunostaining; magnification, x200). (D) CD20⁺ LP cells (immunostaining; magnification, x100). (E) A few CD15⁺ LP cells (immunostaining; magnification, x100). (F) CD30⁺ LP cells (immunostaining; magnification, x100).

Ultrasound, CT and magnetic resonance imaging have become the preferred methods for identifying adrenal tumors. PET-CT is not only able to distinguish between benign and malignant tumors of the adrenal gland in order to make a diagnosis, but also plays a significant role in the staging, evaluation of therapeutic effects and prediction of patient prognosis in HL (13).

NLPHL is characterized by a nodular or nodular and diffuse growth pattern. The neoplastic cells in NLPHL have been known as lymphocytic and histiocytic cells, LP cells or 'popcorn' cells, which are embedded in a nodular non-neoplastic background mainly composed of small B lymphocytes and some CD57⁺ T cells. The immunophenotype of NLPHL is useful for the diagnosis. LP cells are positive for B-cell markers including CD19, CD20, CD22 and CD79a, in addition to CD45 and EMA; however, they lack expression of CD15 and CD30, which are the characteristic markers for cHL. In the background, CD3⁺ or CD57⁺ T cells typically surround the LP cells, forming what are commonly referred to as T-cell rosettes (14). NLPHL is not associated with EBV infection, so EBERs are negative in LP cells. The tumor cells of NLPHL originate from B cells characterized by somatic mutations in the variable domain of the rearranged Ig heavy chain genes and the expression of B-cell markers. The morphological and immunohistochemical features in the present case were consistent with the diagnosis of NLPHL.

Patients with NLPHL are mainly treated with radiotherapy and chemotherapy (15,16). Surgery is mainly used to obtain the pathological tissue and diagnosis, and does not affect the prognosis (6).

In early-stage, limited NLPHL cases (I and II stage) treatment with radiotherapy alone has been recommended in the past. Clinical studies on 202 patients in Australasia showed that the 15-year overall survival (OS) rate was 83% and the freedom from progression rate was 82% in patients with I-II stage LPHL treated with radiotherapy alone (17). Another study, conducted in Germany, showed that of 131 patients, 98% of patients with stage IA LPHL achieved complete remission following radiotherapy (18). The suggested cumulative dose is 30-36 Gy (19). However, more recent studies have found that treating limited-stage NLPHL with ABVD-like chemotherapy for two cycles followed by radiotherapy may improve outcome compared with the use of radiation alone (3,20). A retrospective study analyzed 88 patients with limited stage NLPHL and the results showed a marked improvement in the 10-year time to progression (98 vs. 76%; $P=0.0074$), progression-free survival (91 vs. 65%; $P=0.0024$) and OS (93 vs. 84%; $P=0.074$) for patients treated with ABVD followed by radiotherapy compared with those treated with radiotherapy alone (3).

Patients with early-stage NLPHL who have received ABVD chemotherapy and/or radiotherapy have a good prognosis; studies have shown that the 10-year overall survival rate is >90%, even up to 100% (1,2). Patients who seek to achieve long-term survival must consider the side effects of treatment and treatment-related mortality. A recent study of 405 patients showed that the 12-year overall survival rate was 94% among those receiving treatment with ABVD alone, as compared with 87% among those receiving radiation therapy ($P=0.04$). It was suggested that among patients with early-stage

HL, ABVD therapy alone was associated with a higher rate of overall survival compared with radiation therapy, owing to a lower rate of death from other causes (21). However, a number of studies have suggested a watch-and-wait strategy as a potentially curative approach after initial lymph node surgery, particularly for children (2,22,23). The optimal treatment for limited-stage NLPHL is unclear, and very few cases of adrenal NLPHL have been reported. As a result, there is no standard treatment for adrenal NLPHL and a suitable treatment can only be determined based on that of other types of NLPHL. In order to reduce treatment-related toxicity, the patient in the present case was only treated with adjuvant chemotherapy after surgery. The invasion site of the tumor presented in this case was the kidney. In order to prevent damage to the kidney from radiotherapy and to reduce treatment-related toxicity, the patient was treated only with ABVD adjuvant chemotherapy following a laparoscopic left adrenalectomy.

The current recommendation for advanced-stage NLPHL consists of standard cHL protocols, with ABVD chemotherapy and combined therapy including radiotherapy (3).

The LP cells in NLPHL express high levels of CD20 antigen, rituximab, which has emerged as a potential treatment option for NLPHL. Ekstrand *et al* (24) conducted a phase 2 trial where 22 patients with LPHL (untreated and previously treated, stages I-III) were treated with rituximab. The overall response rate was 100%. The German Hodgkin Lymphoma Study Group reported an overall response rate (ORR) of 94% in NLPHL patients administered with rituximab, including eight patients who achieved complete remission (CR) and six who achieved partial remission (PR) (25). It was suggested that rituximab was highly effective in relapsed and refractory NLPHL. In another phase 2 trial, newly diagnosed stage IA NLPHL patients treated with rituximab were investigated. Among the 28 evaluable patients, the ORR was 100%, 85.7% patients achieved CR and 14.3% achieved PR, and the 43-month OS rate was 100% (14). Treatment results with rituximab appear inferior compared with radiotherapy and combined-modality approaches in early-stage patients. The 2012 National Comprehensive Cancer Network guidelines recommend rituximab for the treatment of NLPHL of stage Ib or greater (26).

Primary adrenal NLPHL is extremely rare, and pathological analysis and immunohistochemical examination are key in achieving a diagnosis. Due to the rarity of NLPHL, there have been few prospective studies, and as a result, a wide range of management approaches are available. Thus, the optimal management strategy for NLPHL is unclear. Patients with limited stage NLPHL treated with ABVD chemotherapy followed by radiotherapy have more successful outcome compared with those treated with radiotherapy alone. The current recommendation for advanced-stage NLPHL consists of standard cHL protocols, with ABVD chemotherapy and combined therapy including radiotherapy and rituximab. Rituximab has emerged as a potential treatment option for NLPHL. The optimal treatment of NLPHL in the era of targeted therapy should be further explored. Further studies, particularly long-term, prospective randomized clinical trials are required to improve the diagnostic techniques and the optimal treatment of NLPHL. Additionally, the differential diagnosis of adrenal tumors should be considered.

References

- Nogová L, Rudiger T and Engert A: Biology, clinical course and management of nodular lymphocyte-predominant Hodgkin lymphoma. *Hematology Am Soc Hematol Educ Program* 2006: 266-272, 2006.
- Illés A, Simon Z, Tóth E, Rosta A, Miltényi Z and Molnár Z: Nodular lymphocyte predominant Hodgkin lymphoma (NLPHL)-clinicopathological features based on the data of two Hungarian lymphoma centres. *Pathol Oncol Res* 14: 411-421, 2008.
- Savage KJ, Skinnider B, Al-Mansour M, Sehn LH, Gascoyne RD and Connors JM: Treating limited-stage nodular lymphocyte predominant Hodgkin lymphoma similarly to classical Hodgkin lymphoma with ABVD may improve outcome. *Blood* 118: 4585-4590, 2011.
- Chen RC, Chin MS, Ng AK, *et al*: Early-stage, lymphocyte-predominant Hodgkin's lymphoma: patient outcomes from a large, single-institution series with long follow-up. *J Clin Oncol* 28: 136-141, 2010.
- Al-Mansour M, Connors JM, Gascoyne RD, Skinnider B and Savage KJ: Transformation to aggressive lymphoma in nodular lymphocyte-predominant Hodgkin's lymphoma. *J Clin Oncol* 28: 793-799, 2010.
- Biasoli I, Stamatoullas A, Meignin V, *et al*: Nodular, lymphocyte-predominant Hodgkin lymphoma: a long-term study and analysis of transformation to diffuse large B-cell lymphoma in a cohort of 164 patients from the Adult Lymphoma Study Group. *Cancer* 116: 631-639, 2010.
- Nogová L, Reineke T, Brillant C, *et al*: Lymphocyte-predominant and classical Hodgkin's lymphoma: a comprehensive analysis from the German Hodgkin Study Group. *J Clin Oncol* 26: 434-439, 2008.
- Harris NL, Jaffe ES, Diebold J, *et al*: World Health Organization Classification of neoplastic diseases of hematopoietic and lymphoid tissues: Report of the Clinical Advisory Committee Meeting - Airlie House, Virginia, November 1997. *J Clin Oncol* 17: 3835-3849, 1999.
- Xing KH, Connors JM, Lai A, *et al*: The outcome of advanced stage nodular lymphocyte predominant Hodgkin's lymphoma (NLPHL) compared to classical Hodgkin's lymphoma (CHL): a matched pair analysis. *Blood* 123: 3567-3573, 2014.
- Hagspiel KD: Manifestation of Hodgkin's lymphoma in an adrenal myelolipoma. *Eur Radiol* 15: 1757-1759, 2005.
- Bourne AE, Bell SW, Wayment RO and Schwartz BF: Primary Hodgkin lymphoma of the adrenal gland: a unique case presentation. *Cn J Urol* 16: 4694-4696, 2009.
- Szczepanowski M, Masqué-Soler N, Oschlies I, Schmidt W, Lück A and Klapper W: Composite lymphoma of nodular lymphocyte-predominant and classical Hodgkin lymphoma-Epstein-Barr virus association suggests divergent pathogenesis despite clonal relatedness. *Hum Pathol* 44: 1434-1439, 2013.
- Engert A, Haverkamp H, Kobe C, *et al*: Reduced-intensity chemotherapy and PET-guided radiotherapy in patients with advanced stage Hodgkin's lymphoma (HD15 trial): a randomised, open-label, phase 3 non-inferiority trial. *Lancet* 379: 1791-1799, 2012.
- Anagnostopoulos I, Hansmann ML, Franssila K, *et al*: European Task Force on Lymphoma project on lymphocyte predominance Hodgkin disease: histologic and immunohistologic analysis of submitted cases reveals 2 types of Hodgkin disease with a nodular growth pattern and abundant lymphocytes. *Blood* 96: 1889-1899, 2000.
- Eichenauer DA, Fuchs M, Pluetschow A, Klimm B, *et al*: Phase 2 study of rituximab in newly diagnosed stage IA nodular lymphocyte-predominant Hodgkin lymphoma: a report from the German Hodgkin Study Group. *Blood* 118: 4363-4365, 2011.
- Eichenauer DA, Engert A and Dreyling M; ESMO Guidelines Working Group: Hodgkin's lymphoma: ESMO Clinical Practice Guidelines for diagnosis, treatment and follow-up. *Ann Oncol* 22 (Suppl 6): Svi55-Svi58, 2011.
- Wirth A, Yuen K, Barton M. Long-term outcome after radiotherapy alone for lymphocyte-predominant Hodgkin lymphoma: a retrospective multicenter study of the Australasian Radiation Oncology Lymphoma Group. *Cancer* 104: 1221-1229, 2005.
- Nogova L, Reineke T, Eich HT, *et al*: Extended field radiotherapy, combined modality treatment or involved field radiotherapy for patients with stage IA lymphocyte-predominant Hodgkin's lymphoma: a retrospective analysis from German Hodgkin Study Group (GHSG). *Ann Oncol* 16: 1683-1687, 2005.
- Specht L, Yahalom J, Illidge T, *et al*: Modern radiation therapy for Hodgkin lymphoma: field and dose guidelines from the International Lymphoma Radiation Oncology Group (ILROG). *Int J Radiat Oncol Biol Phys*: doi: 10.1016/j.ijrobp.2013.05.005.
- Savage KJ, Hoskins P, Klasa R, *et al*: ABVD chemotherapy is essential for optimal treatment of limited stage nodular lymphocyte predominant Hodgkin lymphoma. *Hematologica* 92 (Suppl 5): 27-28, 2007.
- Meyer RM, Gospodarowicz MK, Connors JM, *et al*: NCIC Clinical Trials Group; Eastern Cooperative Oncology Group: ABVD alone versus radiation-based therapy in limited-stage Hodgkin's lymphoma. *N Engl J Med* 366: 399-408, 2012.
- Pellegrino B, Terrier-Lacombe MJ, Oberlin O, *et al*: Lymphocyte-predominant Hodgkin's lymphoma in children: therapeutic abstention after initial lymph node resection - a Study of the French Society of Pediatric Oncology. *J Clin Oncol* 21: 2948-2952, 2003.
- Mauz-Körholz C, Gorde-Grosjean S, Hasenclever D, *et al*: Resection alone in 58 children with limited stage, lymphocyte-predominant Hodgkin lymphoma-experience from the European network group on pediatric Hodgkin lymphoma. *Cancer* 110: 179-185, 2007.
- Ekstrand BC, Lucas JB, Horwitz SM, *et al*: Rituximab in lymphocyte-predominant Hodgkin disease: results of a phase 2 trial. *Blood* 101: 4285-4289, 2003.
- Schulz H, Rehwal U, Morschhauser F *et al*: Rituximab in relapsed lymphocyte-predominant Hodgkin lymphoma: long-term results of a phase 2 trial by the German Hodgkin Lymphoma Study Group (GHSG). *Blood* 111: 109-111, 2008.
- Hoppe RT, Advani RH, Ai WZ, *et al*: Hodgkin lymphoma, version 2.2012 featured updates to the NCCN guidelines. *J Natl Compr Canc Netw* 10: 589-597, 2012.