

# Large cell neuroendocrine cervical tumor treated by radical surgery and adjuvant chemotherapy: A case report and literature review

NICOLAE BACALBAȘA<sup>1</sup>, CLAUDIA STOICA<sup>2</sup>, MADALINA MARCU<sup>1</sup>, DANIELA MIHALACHE<sup>3</sup>, FLORINA VASILESCU<sup>4</sup>, ILEANA POPA<sup>4</sup>, GRATIELA MIREA<sup>4</sup> and IRINA BĂLESCU<sup>5</sup>

<sup>1</sup>Department of Obstetrics and Gynecology, Carol Davila University of Medicine and Pharmacy, Bucharest 050474;

<sup>2</sup>Department of General Surgery, Ilfov County Hospital, Bucharest 13118; <sup>3</sup>Department of Anatomopathology, Cytopath Laboratory, Braila 810249; <sup>4</sup>Department of Anatomopathology, GreenOnco Medical, Bucharest 010903;

<sup>5</sup>Department of General Surgery, Ponderas Hospital, Bucharest 014412, Romania

Received December 21, 2014; Accepted September 15, 2015

DOI: 10.3892/ol.2015.3878

**Abstract.** Neuroendocrine carcinomas of the uterine cervix are rare, but extremely aggressive, gynecological malignancies that are associated with an overall poor prognosis. The present study reports the case of a 41-year-old patient diagnosed with large cell neuroendocrine cervical tumor. A radical total hysterectomy with bilateral adnexectomy, pelvic and lymph node dissection was performed. The post-operative course was uneventful, and the patient was discharged on post-operative day 8.

## Introduction

Neuroendocrine tumors are rare benign or malignant neoplasms that originate from the endocrine and nervous systems, and may develop in various organs (1). Neuroendocrine carcinoma of the uterine cervix (NECC) is a rare cancer that was first described by Albores-Saavedra in 1976 and accounts for almost 2% of all cervical malignancies (2). In the USA, almost 250 patients are diagnosed with NECC each year (3). The main histopathological types of cervical malignancies include small cell NECC, large cell NECC, typical carcinoid tumors and atypical carcinoid tumors. While carcinoid tumors are considered as low-grade malignant tumors, the other histopathological subtypes are

poorly differentiated or high-grade carcinomas, which are associated with an overall poor prognosis (4). Due to the particularly aggressive biological behavior, small and large cell NECC necessitates a wide resection in order to gain control of the disease. The present study reports the case of a 41-year-old female in whom a large cell NECC was identified. The patient underwent surgery and a radical total hysterectomy, with bilateral adnexectomy, pelvic and para-aortic lymph node dissection, was performed. The patient provided written informed consent.

## Case report

A 41-year-old female patient presented with pelvic pain and vaginal bleeding at Ilfov County Hospital, Bucharest, Romania in February 2014. Local examination revealed a cervical tumor, with no signs of local invasion. Colposcopy revealed the presence of a 3-cm red polypoid endocervical tumor, which was biopsied. Histopathological examination revealed the presence of a malignant epithelial tumor with round cells and numerous mitoses. Immunohistochemistry revealed the presence of synaptophysin, chromogranin and cytokeratine-7 in the tumor cells. In up to 90% of the tumor cells, this was associated with Ki-67 expression and no Wilms tumor protein (WT)-1 or estrogen receptor expression. These findings determined the diagnosis of large cell NECC. Pelvic magnetic resonance imaging confirmed the presence of a 4 cm tumor, with no signs of local invasion or distant metastases (Fig. 1A and B). The patient underwent surgery and a total radical hysterectomy with bilateral adnexectomy, pelvic and para-aortic lymph node dissection was performed (Figs. 2-9). The patient was discharged on post-operative day 8.

Histopathological examination confirmed the pre-operative diagnosis of a large cell NECC, with vascular tumor emboli (Fig. 10A-C). The tumor cells expressed synaptophysin, chromogranin and cytokeratine-7, and in up to 90% of the cells, this was associated with Ki-67 expression and no estrogen receptor expression. The tumor cells did not express progesteron receptors, which were expressed in the surrounding stroma and

---

*Correspondence to:* Dr Nicolae Bacalbașa, Department of Obstetrics and Gynecology, Carol Davila University of Medicine and Pharmacy, 2 Dimitrie Racoviță Street, Bucharest 050474, Romania  
E-mail: nicolae\_bacalbașa@yahoo.ro

*Abbreviations:* NECC, neuroendocrine carcinoma of the uterine cervix

*Key words:* neuroendocrine cervical tumor, large cell, radical hysterectomy, bilateral adnexectomy

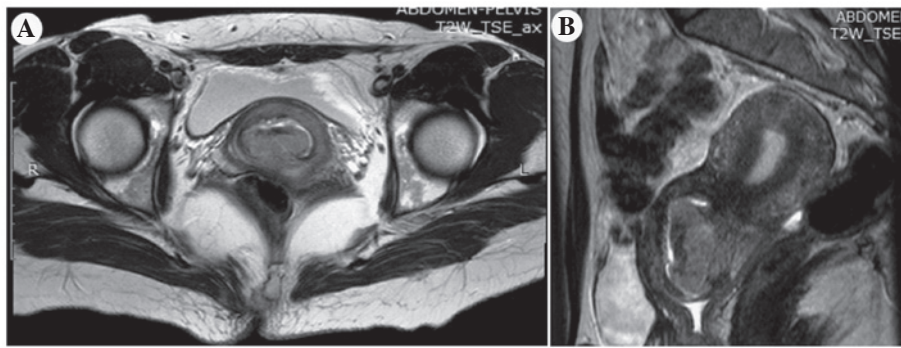


Figure 1. (A and B) A large cervical tumor was identified in the T2 sequence of pelvic magnetic resonance imaging, demonstrating no signs of local invasion.

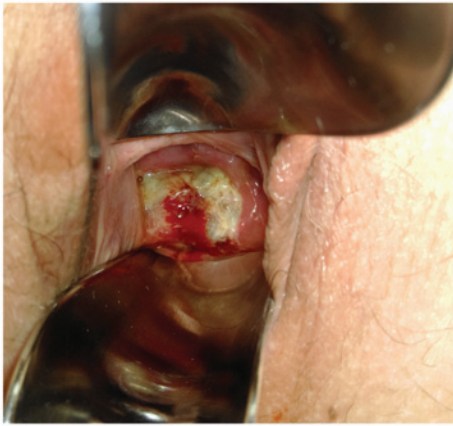

Figure 2. A local examination of the vagina revealed a large ulcerated and hemorrhagic tumor.

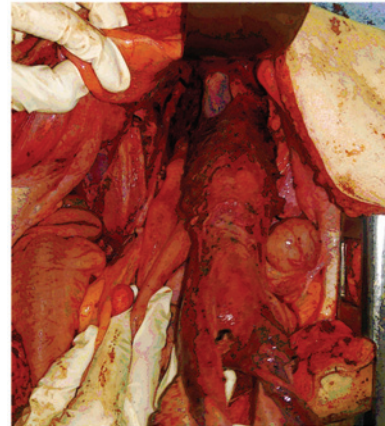


Figure 4. Total radical hysterectomy with bilateral adnexectomy was performed. The lesion was completely mobilised and the vagina was partially sectioned.

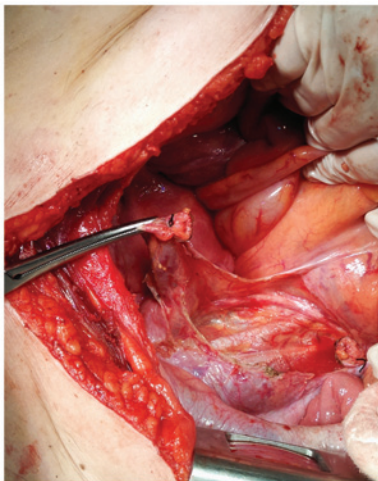


Figure 3. Dissection of the left ureter and the left iliac vessels from the intra-operative aspect.

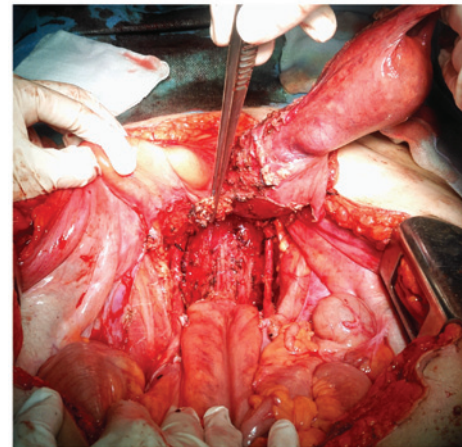


Figure 5. *En bloc* resection of the left utero-sacrat ligament with the specimen.

cervical glands (Fig. 10D-I). The histopathological examination also revealed 2 pelvic lymph nodes that were positive for metastasis. Therefore, the patient was referred to the Oncology Clinic of Brăila County Hospital (Brăila, Romania) for adjuvant chemotherapy. In total, the patient received 6 cycles of cisplatin (60 mg/m<sup>2</sup>, day 1, with 4-week cycles) and etoposide (100 mg/m<sup>2</sup>/day, days 1-3), which was well-tolerated. At the 1-year follow-up the patient was free of any local or distant recurrence.

## Discussion

NECC tumors are uncommon and the etiology and risk factors of this disease are not clearly known. Although several studies have demonstrated that there may be an association between human papilloma virus (HPV) and NECC (4,5), the studies have failed to demonstrate that an HPV screening test could provide an early diagnosis for NECC, in a pre-invasive phase (5).

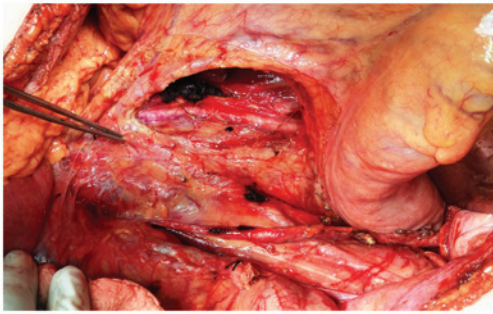


Figure 6. Large adenopathies at the origin of the inferior mesenteric artery.

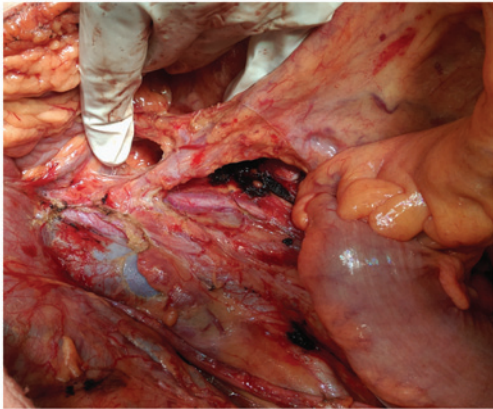


Figure 7. The inferior mesenteric artery was completely dissected, with para-aortic lymph node dissection.

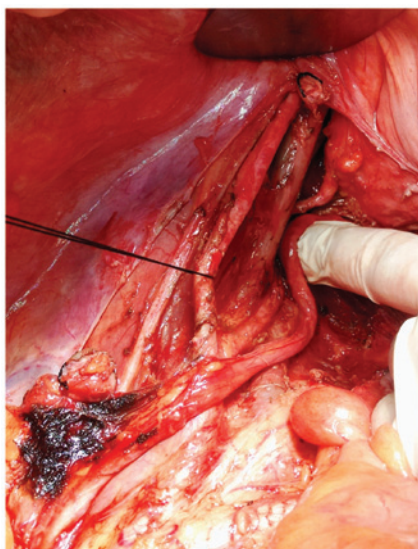


Figure 8. The common iliac artery and its branches were dissected and the lymph nodes were removed.

Due to distinct histopathological behavior, NECC tumors are associated with the local symptoms characteristic of a cervical tumor, such as vaginal bleeding and pelvic pain, and general para-neoplastic syndromes that involve the endocrine and nervous system, for example syndrome of inappropriate antidiuretic hormone, Cushing's syndrome or hypercalcemia. These general syndromes are also identified in neuroendocrine

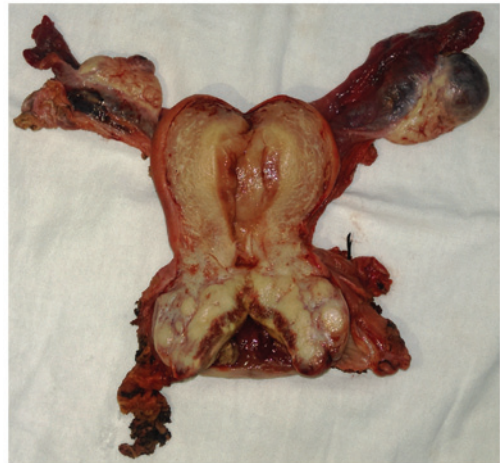

Figure 9. Large tumor of the uterine cervix.

tumors with other localization, the most common are those located in the lungs (6).

Large cell NECC is a special subcategory that accounts for up to 0.6% of all cervical malignancies, and demonstrated an extremely aggressive biological behavior (7,8). The presence of prominent vesicular nuclei and nucleoli with >10 mitotic figures/10 high-power fields associated with variable areas of necrosis is required for the diagnosis of large cell NECC (3). Immunohistochemical demonstration of the presence of  $\geq 1$  neuroendocrine marker, such as chromogranin, synaptophysin, cluster of differentiation (CD)-56 or protein gene product 9.5, is also mandatory for diagnosis (3).

There is no standard protocol for the treatment of NECC malignancies, due to their rarity. However, the main treatment principles are extrapolated from standard treatment protocols for other neuroendocrine tumors, including high-grade lung neuroendocrine cancer (9).

In patients presenting with early-stage tumors measuring <4 cm, with no signs of local invasion or distant metastases, the gold-standard of treatment is surgery consisting of a radical hysterectomy with bilateral adnexectomy, pelvic and para-aortic lymph-node dissection, followed by adjuvant chemo-irradiation (10-13). The most recommended adjuvant chemotherapy regimen is a combination of cisplatin and etoposide (14). By contrast, patients presenting with local invasion or distant extra-pelvic disease are candidates for neo-adjuvant chemotherapy with vincristine, adriamycin and cyclophosphamide, alternating with cisplatin and etoposide and followed by radical surgery (10-14).

As with other histopathological types of cervical cancer, one of the most important prognostic factors for NECC is the stage of disease at the time of diagnosis. Chen *et al* concluded that patients diagnosed at an early stage of disease demonstrate a significantly increased 5-year overall survival rate; stages I-IIA resulted in an overall survival of 37%, while for more advanced stages this decreased to 9% (10). McCusker *et al* reported a 5-year overall survival rate of 42% for stage I, 19% for stage II, 10% for stage III, and 2.3% for stage IV disease (11). Chen *et al* also described a 5-year overall survival rate of 36% for patients with NECC and an almost double survival rate (70%) for patients with other histopathological types of cervical cancer (10).

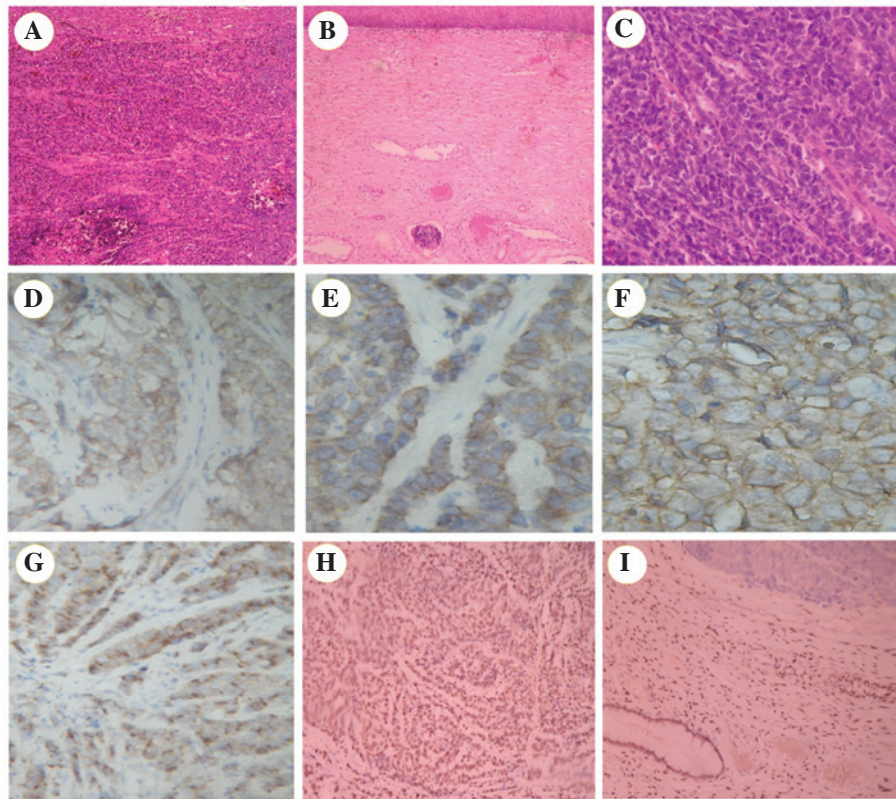


Figure 10. Histopathological investigations revealed (A) the presence of a neuroendocrine cervical tumor (H&E staining; magnification, x10), (B) intravascular tumor embolus in the inferior region of the image (magnification, x10), (C) and a malignant tumor with high grade mitotic activity (H&E staining; magnification, x40). Immunohistochemistry investigations revealed the expression of (D) synaptophysin (magnification, x20), (E) cytokeratin-7 (magnification, x40), (F) carcinoembryonic antigen (magnification, x40), (G) chromogranin (magnification, x40) and (H) Ki-67 (magnification, x20), and (I) the lack of progesterone receptor expression in tumor cells (top), but the presence of progesterone receptor in the surrounding stroma (magnification, x20). H&E, hematoxylin and eosin.

However, it appears that the 5-year overall survival rate for patients with early and advanced stage NECC is increased when compared to pulmonary neuroendocrine tumors. For early stage NECC, the 5-year overall survival rate ranges between 19 and 42%, while for lung neuroendocrine carcinoma the 5-year overall survival rate is 10%. For advanced stage NECC, the 5-year overall survival rate is 10-20%, while for lung neuroendocrine carcinoma the 5-year overall survival rate is 1-2% (12).

Rekhi *et al* conducted a study using 50 patients diagnosed with NECC, 24 of whom were diagnosed with large cell NECC (13). This study concluded that patients with small cell NECC possess a poorer prognosis in comparison to those with large cell NECC. The most common prognosis factors associated with NECC identified by Rekhi *et al* were synaptophysin, which was present in 59.4% of the cases, and chromogranin, which was present in 72.9% of the cases (13). By contrast, Gilks *et al* reported similar rates of survival for small and large cell NECC (14).

Embry *et al* performed a literature review using the Medline database and the keywords 'uterine cervical neoplasms', 'large cell NECC', 'NECC' and 'large cell carcinoma' (15). The authors obtained data on the cases of 62 women diagnosed with large cell NECC. In total, 54 cases contained data pertaining to the overall survival rate of patients. Embry *et al* reported an overall median survival time of the 54 patients of 16.5 months, and concluded that the most important prognostic factors associated with an improved survival time were a younger

age ( $P=0.03$ ), initial earlier Federation of Gynecologists and Obstetricians stage of the disease ( $P<0.0001$ ), radical surgery ( $P=0.006$ ) and chemotherapy at any point during initial treatment ( $P=0.049$ ). In addition, this study investigated whether platinum-based chemotherapy regimens act as a prognostic factor associated with increased overall survival. The results of this study revealed that the platinum ( $P=0.034$ ) and platinum with etoposide ( $P=0.027$ ) regimens provided an improved outcome when compared to other chemotherapy regimens (15).

The absence of pelvic lymph node metastases may be another positive prognostic factor, indicating a significantly improved survival rate in patients diagnosed with NECC (8,16). Wang *et al* reported a mean overall survival time of 12 months in patients with involved pelvic lymph nodes, whereas in patients with no lymph node metastases, the mean survival time increased to 67 months (8).

Kasamatu *et al* performed a study in which 10 patients with NECC underwent radical hysterectomy with bilateral adnexectomy. Histopathological studies revealed that 4 patients possessed pathological tumor-node-metastasis (pTNM) stage pT1bN0 disease, 4 possessed pT1bN1 disease, 1 possessed pT2aN0 disease, and 1 possessed pT2bN1 disease. Lymph node metastases were reported in 4 patients and lymph-vascular space invasion was reported in 7 patients; all patients possessed stage T1b disease. All patients with N1 disease underwent adjuvant chemotherapy or radiotherapy. Recurrence arose in 7 patients at a median interval of 8 months subsequent to surgery. Following recurrence, the median survival time was

16 months, despite aggressive multimodal treatment. For all 10 patients, the 5-year overall survival rate was 43% and the reported median survival time was 29 months. Pelvic lymph node metastases were identified in 3 patients among those who relapsed, and in a single patient that did not experience recurrence. The main sites of recurrence were as follows: Liver, 3 patients; lungs, 3 patients; brain, 1 patient; and para-aortic lymph nodes, 1 patient. Kasamatu *et al* concluded that the most important prognostic factors were the initial stage of the tumor, as stromal invasion >6 mm is associated with a poor prognosis, and the presence of positive lymph nodes, which significantly increased the rates of recurrence (17).

Large cell NECC is an aggressive tumor, with a poorer prognosis at each stage compared with similar stages of squamous cell carcinoma of the cervix. Due to the rarity of large cell NECC, it is challenging to determine the most appropriate therapy protocol. However it appears that long-term survival may be obtained with an aggressive surgical approach combined with peri-operative platinum-based chemotherapy regimens.

## References

1. Klimstra DS, Modlin IR, Coppola D, Lloyd RV and Suster S: The pathologic classification of neuroendocrine tumors: A review of nomenclature, grading, and staging systems. *Pancreas* 39: 707-712, 2010.
2. Albores-Saavedra J, Larraza O, Poucell S and Rodriguez Martinez HA: Carcinoid of the uterine cervix: Additional observations on a new tumor entity. *Cancer* 38: 2328-2342, 1976.
3. Albores-Saavedra J, Gersell D, Gilks CB, Henson DE, Lindberg G, Santiago H, Scully RE, Silva E, Sobin LH, Tavassoli FJ, *et al*: Terminology of endocrine tumors of the uterine cervix: Results of a workshop sponsored by the College of American Pathologists and the National Cancer Institute. *Arch Pathol Lab Med* 121: 34-39, 1997.
4. Reagan JW, Hamonic MJ and Wentz WB: Analytical study of the cells in cervical squamous-cell cancer. *Lab Invest* 6: 241-250, 1957.
5. Stoler MH, Mills SE, Gersell DJ and Walker AN: Small-cell neuroendocrine carcinoma of the cervix. A human papillomavirus type 18-associated cancer. *Am J Surg Pathol* 15: 28-32, 1991.
6. Hirahatake K, Hareyama H, Kure R, Kawaguchi I, Yamaguchi J, Sakuragi N and Fujimoto S: Cytologic and hormonal findings in a carcinoid tumor of the uterine cervix. *Acta Cytol* 34: 119-124, 1990.
7. Sato Y, Shimamoto T, Amada S, Asada Y and Hayashi T: Large cell neuroendocrine carcinoma of the uterine cervix: A clinicopathological study of six cases. *Int J Gynecol Pathol* 22: 226-230, 2003.
8. Wang KL, Wang TY, Huang YC, Lai JC, Chang TC and Yen MS: Human papillomavirus type and clinical manifestation in seven cases of large-cell neuroendocrine cervical carcinoma. *J Formos Med Assoc* 108: 428-432, 2009.
9. Strosberg JR, Coppola D, Klimstra DS, Phan AT, Kulke MH, Wiseman GA and Kvols LK; North American Neuroendocrine Tumor Society (NANETS): The NANETS consensus guidelines for the diagnosis and management of poorly differentiated (high-grade) extrapulmonary neuroendocrine carcinomas. *Pancreas* 39: 799-800, 2010.
10. Chen J, Macdonald OK and Gaffney DK: Incidence, mortality, and prognostic factors of small cell carcinoma of the cervix. *Obstet Gynecol* 111: 1394-1402, 2008.
11. McCusker ME, Coté TR, Clegg LX and Tavassoli FJ: Endocrine tumors of the uterine cervix: Incidence, demographics, and survival with comparison to squamous cell carcinoma. *Gynecol Oncol* 88: 333-339, 2003.
12. Gaspar LE, Gay EG, Crawford J, Putnam JB, Herbst RS and Bonner JA: Limited-stage small-cell lung cancer (stages I-III): Observations from the National Cancer Data Base. *Clin Lung Cancer* 6: 355-360, 2005.
13. Rekhi B, Patil B, Deodhar KK, Maheshwari A, A Kerkar R, Gupta S, Tongaonkar HB and Shrivastava SK: Spectrum of neuroendocrine carcinomas of the uterine cervix, including histopathologic features, terminology, immunohistochemical profile, and clinical outcomes in a series of 50 cases from a single institution in India. *Ann Diagn Pathol* 17: 1-9, 2013.
14. Gilks CB, Young RH, Gersell DJ and Clement PB: Large cell neuroendocrine [corrected] carcinoma of the uterine cervix: A clinicopathologic study of 12 cases. *Am J Surg Pathol* 21: 905-914, 1997.
15. Embry JR, Kelly MG, Post MD and Spillman MA: Large cell neuroendocrine carcinoma of the cervix: Prognostic factors and survival advantage with platinum chemotherapy. *Gynecol Oncol* 120: 444-448, 2011.
16. Boruta DM II, Schorge JO, Duska LA, Crum CP, Castrillon DH and Sheets EE: Multimodality therapy in early-stage neuroendocrine carcinoma of the uterine cervix. *Gynecol Oncol* 81: 82-87, 2001.
17. Kasamatsu T, Sasajima Y, Onda T, Sawada M, Kato T and Tanikawa M: Surgical treatment for neuroendocrine carcinoma of the uterine cervix. *Int J Gynaecol Obstet* 99: 225-228, 2007.