

# Endobronchial fibroma in a pneumoconiosis patient with a history of tuberculosis: A case report and literature review

MEIFANG WANG<sup>1,2</sup>, YUQUAN LIU<sup>1,2</sup>, DAN LI<sup>3</sup>, CHANG XIONG<sup>1,2</sup>, XIN QIAN<sup>1,2</sup> and YIJUN TANG<sup>1,2</sup>

<sup>1</sup>Department of Respiratory Medicine; <sup>2</sup>Institute of Respiratory Medicine; <sup>3</sup>Department of Pathology, Taihe Hospital, Hubei University of Medicine, Shiyan, Hubei 442000, P.R. China

Received March 12, 2015; Accepted April 1, 2016

DOI: 10.3892/ol.2016.4726

**Abstract.** Bronchial fibroma is uncommon, with only 18 cases reported since 1948. The current study presents a rare case of endobronchial fibroma, along with a relevant literature review. A 54-year-old male patient with pneumoconiosis and a history of tuberculosis was admitted to the Taihe Hospital Affiliated With Hubei University of Medicine, Shiyan, China, due to refractory dry cough. Computed tomography of the chest showed multiple nodular and confluent opacities in the lung and one cavitation in the right upper lobe region. Bronchoscopy revealed an endobronchial mass in the left main bronchus. A bronchoscopic resection was performed, and the pathological evaluation confirmed fibroma. The patient's dry cough resolved following the removal of the fibroma, and no recurrence was detected during 6 months of follow-up. Endobronchial fibroma is an extremely rare disease, for which a pathological analysis is typically required for an accurate diagnosis. Bronchoscopic treatments, including removal by forceps, argon plasma coagulation and laser or electrocautery snares, may be used to treat patients affected by endobronchial fibroma.

## Introduction

Fibroma is a rare type of benign bronchopulmonary tumor that primarily occurs in the lung parenchyma or pleura (1-5). Endobronchial fibroma is extremely rare (3,4), with only 18 cases reported since 1948 (6-19). Fibromas are usually detected on routine chest X-ray as a lung shadow (6,8,15,16,19) and definitive diagnosis is made based on histopathological examination (6,10,12,15). Endobronchial fibromas generally present with obstructive pneumonia or atelectasis (8,15,16). When fibromas are small or pedunculated, they can be readily

detachable from the bronchial wall through bronchoscopy using forceps or laser (5,9,11,17,18). When the tumors are large and occlude the bronchus, leading to irreversible peripheral changes in the lung, they can be treated by lobectomy (7,8,10,12,15,19). Fibromas do not normally recur, and they are associated with a favorable prognosis (6-12,15-19). The etiology of fibroma remains unclear; however, an association with trauma is possible. The present study reports a rare case of endobronchial fibroma in a patient with pneumoconiosis and a history of tuberculosis but no history of trauma. Such a case is extremely rare and, to the best of our knowledge, has not been previously reported in the literature.

## Case report

A 54-year-old male patient presented to the Taihe Hospital Affiliated to Hubei University of Medicine (Shiyan, China) in May 2014, presenting with a refractory dry cough and dyspnea upon exertion. There was no loss of appetite or weight and no history of fever, chest pain or hemoptysis. The patient was normotensive and non-diabetic and had no history of smoking, trauma or radiation exposure. The patient had been a gold miner with dust exposure for 10 years. In 2008, a chest radiograph was performed as part of a health evaluation, which identified small rounded and irregular opacities in bilateral upper lobes. The patient was diagnosed with early-stage pneumoconiosis without presenting symptoms, based on the diagnostic criteria of pneumoconiosis (20,21). One year prior to admission, the patient had experienced a cough with sputum production. Chest radiographs revealed confluent opacities in bilateral upper lobes and a lung field shadow accompanied by a cavitation in the right upper lobe. In addition, mycobacterium tuberculosis was detected in the sputum. So the patient was diagnosed with pneumoconiosis complicated by tuberculosis. Subsequent to the diagnosis, the patient quit his mining job based on advice from his doctor and initiated anti-tuberculous therapy. The patient experienced remission of symptoms following the 1 month administration of anti-tuberculosis drugs, and therefore continued the treatment for 8 more months (isoniazid tablets, 0.3 g per oral (P.O.) once a day (QD) for 9 months; rifampicin capsules, 0.45 g P.O. QD for 9 months; pyrazinamide tablets, 1.0 g P.O. QD for the first 3 months; ethambutol tablets, 0.75 g P.O. QD, for the first 3 months).

---

*Correspondence to:* Dr Yijun Tang, Department of Respiratory Medicine, Taihe Hospital, Hubei University of Medicine, Jishi Building, 32 Renmin South Road, Shiyan, Hubei 442000, P.R. China  
E-mail: tangyijun\_799@163.com

**Key words:** benign tumors of bronchus, endobronchial fibroma, cough, tuberculosis

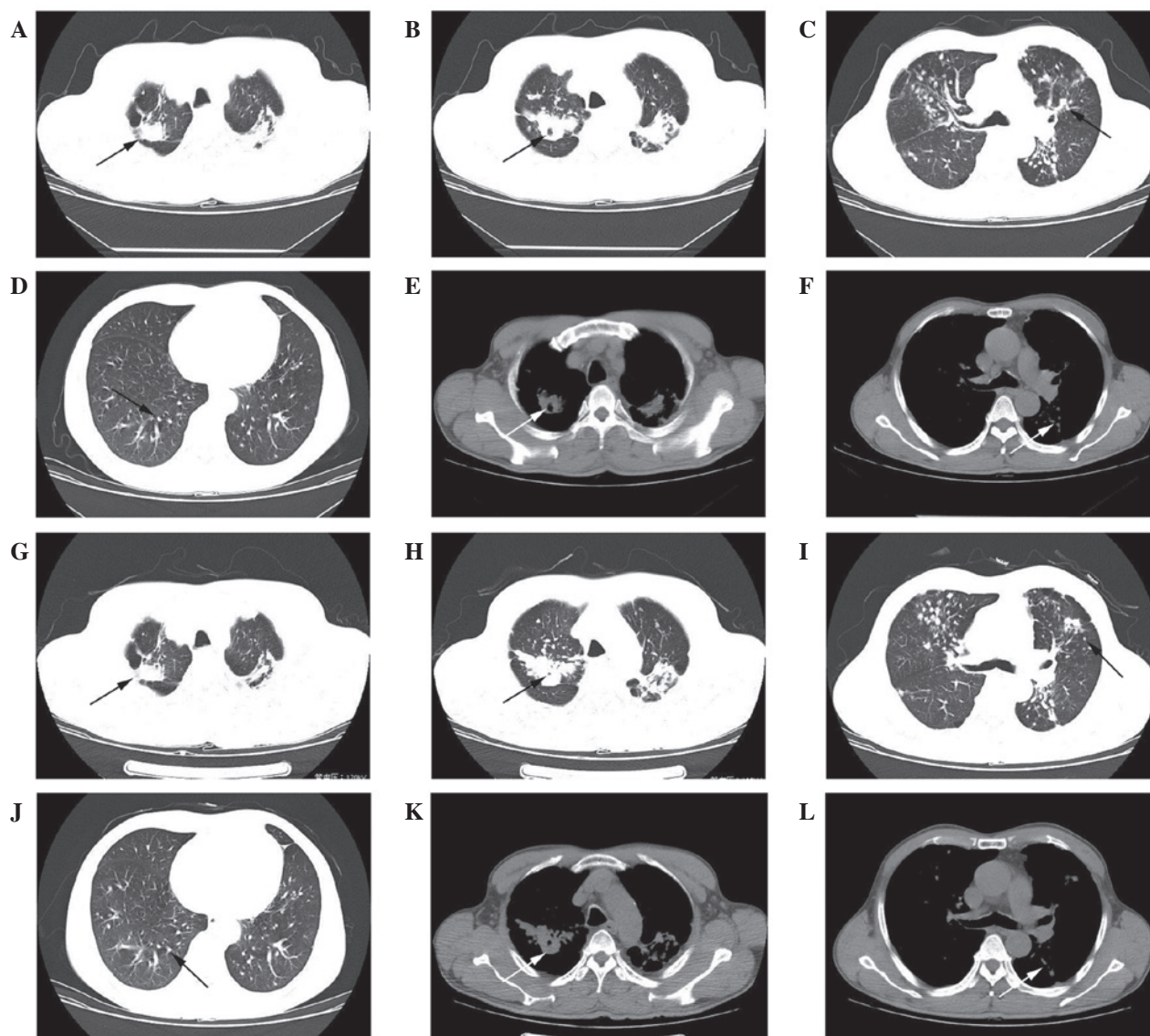


Figure 1. Chest computed tomography scan of the patient upon admission (A-F) and 6 months later (G-L). Confluent opacities in the bilateral upper lobes (A) upon admission and (G) 6 months later. One area of focal cavitation in the right upper lobe (B) upon admission and (H) 6 months later. Nodular opacities in the bilateral upper lobes (C) upon admission and (I) 6 months later. Nodular opacities in the bilateral lower lobes (D) upon admission and (J) 6 months later. One area with focal cavitation in the right upper lobe, shown in the mediastinal window, (E) upon admission and (K) 6 months later. Nodular opacities in the bilateral upper lobes, shown in the mediastinal window, (F) upon admission and (L) 6 months later.

At the time of the examination at the Taihe Hospital Affiliated With Hubei University of Medicine, the patient appeared well in all physical aspects. The respiratory and heart rates were 22 breaths/min (normal rates, 16-20 breaths/min) and 98 beats/min (normal rates, 60-100 breaths/min), respectively, and the blood pressure was 110/83 mmHg (normal range: systolic, 90-140; diastolic, 60-90 mmHg). Examination of the respiratory system revealed slightly decreased respiratory sounds at the apex of the lungs bilaterally. The remainder of the examination was unremarkable.

Laboratory studies showed that the complete blood count, erythrocyte sedimentation rate, arterial gas analysis, fasting plasma glucose, serum creatinine, liver function tests, serum carcinoembryonic antigen, bleeding time and clotting time were all within normal limits. No infectious agents were identified, despite the examination and culture of several induced sputum smears.

Pulmonary function tests revealed a severe combined obstructive-restrictive ventilatory disorder. The chest computed tomography (CT) scan (Light speed VCT 64; GE Healthcare Bio-Sciences, Pittsburgh, PA, USA) (Fig. 1) revealed multiple nodular and confluent opacities in the lung, particularly in the bilateral upper lobes (Fig. 1A-F). One focal cavitation was present in the right upper lobe region (Fig. 1B and E). The borders of the lesions were clear (Fig. 1A-D). Additional examinations with electronic bronchoscopy showed a polypoid mass in the left main bronchus (Fig. 2A), which auto-fluoresced weakly (Fig. 2B). The mass was too hard to be resected with forceps; therefore, it was removed using an electrocautery snare and argon plasma coagulation therapy apparatus (ECO-800E1, Nanjing Medical Equipment Co., Ltd., Nanjing, China) (Fig. 2C). The resected mass was 0.5 cm in diameter. The mass was put into a small bottle containing 10% neutral buffered formalin (Nanchang Rain Experimental

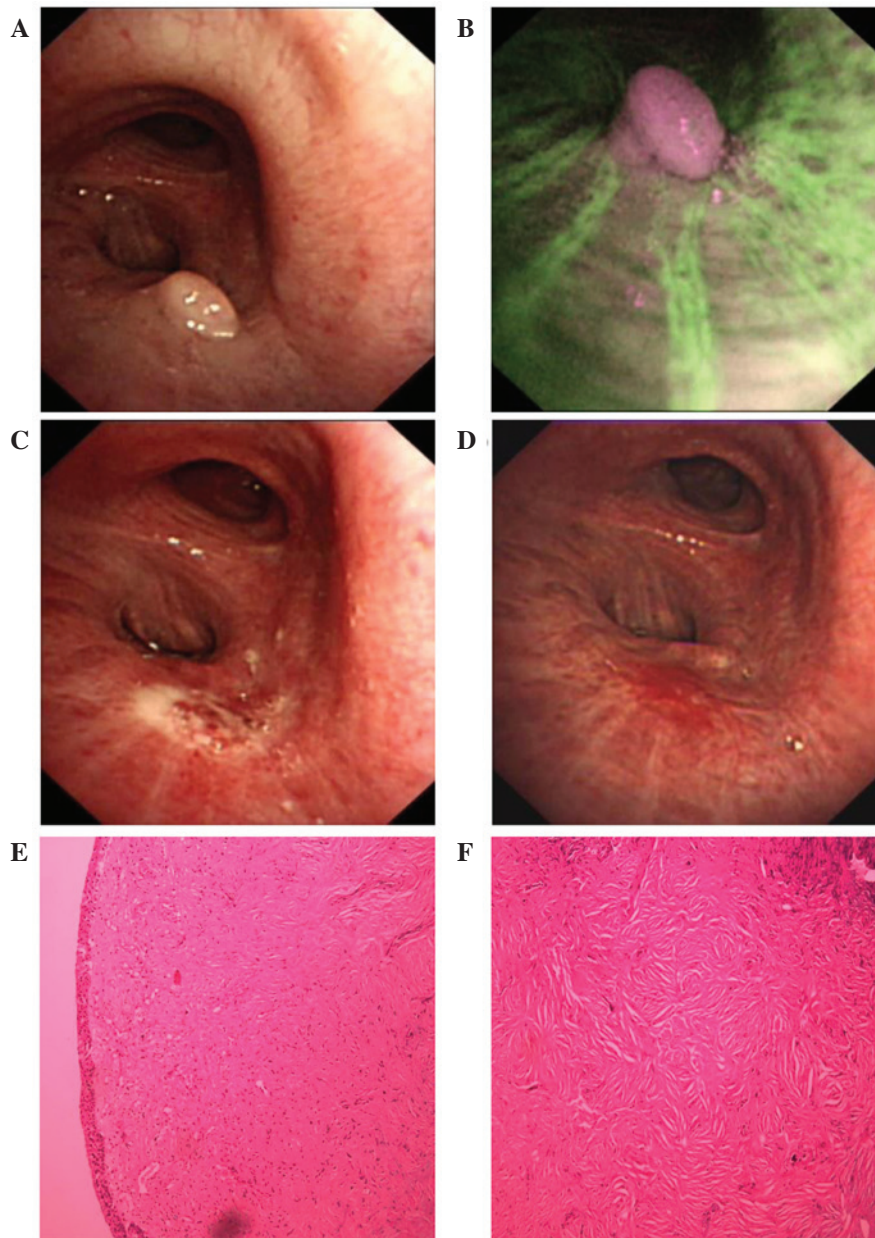


Figure 2. Electronic bronchoscopy and histopathological specimens from the patient. (A) A polypoid mass in the left main bronchus; (B) the mass weakly autofluoresced. (C) Bronchoscopic findings following snaring of the mass. (D) Bronchoscopy performed six months subsequent to tumor resection. (E) H&E staining (original magnification, x100) of the specimens demonstrated that the mass was lined with normal respiratory epithelium and was composed of fibrous connective tissue with hyaline degeneration and sporadic lymphocytes; (F) H&E staining (original magnification, x100) of the specimens demonstrated that the core of the mass was composed of fibrous connective tissue with hyaline degeneration. H&E, hematoxylin and eosin.

Equipment Co., Ltd., Nanchang, China) and sent to the Department of Pathology. A histopathological examination revealed that the tumor was composed of fibrous connective tissue with hyaline degeneration and occasional lymphocytes and was covered by pseudostratified ciliated columnar epithelium (Fig. 2E and F). For immunocytochemical phenotyping, tissue sections were stained for vimentin, desmin, S-100, cluster of differentiation (CD)34, CD99, B-cell lymphoma 2 (BCL-2), cytokeratin (CK), epithelial membrane antigen (EMA), Ki67 and smooth muscle actin (SMA). The results were as follows: CD34 (-), CD99 (-), BCL-2 (-), desmin (-), S-100 (-), CK (-), vimentin (+), Ki67 (<1%+), SMA (-) and EMA (-).

Following treatment, the patient's dry cough resolved and the dyspnea on exertion was relieved. No further treatment

was administered to the patient. To ensure thorough surveillance, the patient was followed up with bronchoscopy and chest CT scans, which confirmed that neither recurrent fibroma nor recurrent tuberculosis had developed during the 6 months of follow-up. No evidence of tumor recurrence was indicated (Fig. 2D). A chest CT scan six months subsequent to treatment showed no recurrence of tuberculosis (Fig. 1H-L). Multiple nodular and confluent opacities remained in the bilateral upper lobes (Fig. 1H-L). Certain nodules and confluent opacities were slightly larger in size compared with previous measurements (Fig. 1H and I), which may be due to the progression of pneumoconiosis. The borders of these nodules remained clear (Fig. 1G-I). The focal cavitation in the right upper lobe region was stable (Fig. 1H and K).

## Discussion

Tumors in the tracheobronchial tree are unusual, and the majority of these tracheobronchial tumors are malignant (22). Benign tracheobronchial tumors are rare, and bronchial fibromas are even rarer. Even the largest known study, reported by Shah *et al*, included only four cases of tracheobronchial fibromas (9). A review of the literature revealed that various terms, including fibrous histiocytoma and histiocytoma, have been used to describe fibromas of the bronchus (6,10,11), and the incidence of endobronchial fibromas remains unclear.

According to the literature, the clinical presentation of bronchial fibromas varies widely; patients may be asymptomatic or may have coughing, dyspnea or hemoptysis (8,10). One of the central changes is airway stenosis, which leads to recurrent pneumonia, atelectasis and bronchiectasis (8,15,16). These complications are the most common reasons for admission. The patient described in the present study was admitted for a refractory cough. A high-resolution CT scan of the chest and 3D imaging of the central airways is often useful for demonstrating tracheobronchial tumors; however, CT scans cannot discriminate between fibromas and other tumors. Furthermore, small tracheobronchial tumors are often challenging to demonstrate using high-resolution CT. Therefore, as the present study shows, bronchoscopy is critical for the detection of such tumors and to prevent misdiagnosis.

Histopathologically, fibromas are benign lesions, and sparse or absent mitotic figures differentiate fibromas from malignant tumors (10). Throughout the lesion, as shown in the present case, the fibrous tissues are arranged in storiform patterns, which in certain regions are densely hyalinized. A differential diagnosis must be made since fibroma resembles numerous other benign lesions. Fibromas are often confused with inflammatory pseudotumors, which are neoplastic mass lesions composed of inflammatory and mesenchymal cells (23); however, histologically, these two tumors are similar in appearance with abundant fibrous tissue. Microscopically, a large number of inflammatory cells surrounded by collagen are always present in inflammatory pseudotumors (2). Solitary fibrous tumors (SFTs) also resemble fibromas; however, SFTs typically have a patternless architecture of alternating hypo- and hypercellular regions of spindle-shaped cells (2,24). A positivity for CD34, CD99 and BCL-2 proteins in immunohistochemistry may be useful in forming a diagnosis of SFT (24). Pulmonary adenofibroma, a rare benign biphasic tumor involving epithelial and stromal components, with stromal composition of haphazardly arranged bland spindle-cell fibroblastic proliferation and regions of hyalinization, may be distinguished from fibromas by the characteristic appearance of club-shaped and papillary structures (2). CK protein (expressed by the epithelial component) and CD34 (expressed by the stromal component) are also useful for the differential diagnosis between adenofibroma and fibroma, as the former is positive for both markers, while the latter is negative (25).

Papillomas have fibrous cores lined by columnar and glandular cells, and in certain instances vaguely resemble transitional-type epithelium (2); a feature that is absent in fibromas. CK protein immunoreactivity may be useful for

the differential diagnosis between papilloma and fibroma, as the former is characterized by CK protein positivity and the latter by negativity (26). Neurofibroma may be confused with fibroma because of its fibrous stroma; however, its nuclei are usually arranged in a typical palisade formation, and this is accompanied by cystic degeneration and hemorrhage (1). S-100 protein immunoreaction products, which do not appear in fibroma, are seen in the Schwann cells of neurofibroma (27). Angiofibroma, which has numerous thin-walled vessels surrounded by fibrous stroma, may be distinguished from fibroma by the appearance of small branching capillaries with CD34 protein immunoreactivity (24). An endobronchial leiomyoma with a proliferation of spindle cells in a whorl pattern may also be challenging to differentiate from fibromas; however, the desmin and actin immunoreaction products seen in the spindle cells of endobronchial leiomyoma tumors may aid this differential diagnosis (28).

Although the pathogenesis of fibromas remains obscure, a variant in the inflammatory repair process is an important factor, due to the relationship between inflammatory and fiber proliferation (13,14,29-34). During the first stage of wound healing, inflammation around the damaged area stimulates the proliferation of fibrous tissue (13,14). Inflammation in tuberculosis stimulates proliferation of fibrous tissue (29-34) and the formation of fibrous scar is the common way of tuberculosis healing up. As for the etiology of fibromas, an association with trauma, including surgical trauma, has been proposed (29); in the 18 available fibroma case reports, three patients had a history of trauma (13,14). An association between tuberculosis and fibromas has also been reported in certain cases (30-34). However, the etiology of the fibroma described in the present case remains unclear, and whether the endobronchial fibroma was associated with pneumoconiosis or tuberculosis remains unknown.

Treatment of endobronchial fibromas varies according to the size, position and hardness of the lesion. Usually, bronchoscopic treatments, including removal by forceps, argon plasma coagulation and laser or electrocautery snare, may be used selectively (5,9,11,17,18), while sometimes, lobectomy may be necessary (7,8,10,12,15,19). In the present case, the fibroma had a diameter of 0.5 cm and was too hard to remove using forceps; therefore, the fibroma was removed using an endoscopic snare via argon plasma coagulation therapy apparatus. To ensure thorough surveillance, the patient was followed up with bronchoscopy and chest CT scans, which confirmed that neither recurrent fibroma nor recurrent tuberculosis had developed during the 6 months of follow-up.

The prognosis for endobronchial tumors with abundant fibrous tissue varies, rendering accurate diagnosis crucial. For instance, lung adenofibromas and papillomas have been shown to have a higher recurrence rate than fibroma (2,25,26), and may therefore require further medical treatment in order to prevent recurrence and malignant transformation (2,25,26). By contrast, fibroma is associated with a favorable long-term prognosis (5,7-12,15-19). In the present study, following the removal of the small and hard mass through bronchoscopy, histological examination using hematoxylin (Shanghai Chemical Reagent Co., Ltd., Shanghai, China) and eosin (Tianjin Bodi Chemical Co., Ltd., Tianjin, China)

staining and immunohistochemical analysis were performed. Solitary fibrous tumors, adenofibroma, papillomas, neurofibroma, angiofibroma and leiomyoma, which resemble fibroma histopathologically, were ruled out one by one, due to the negativity of the sample for CD34, CD99, BCL-2, desmin, S-100, CK, SMA and EMA. Due to the favorable prognosis of fibroma, the present patient required no further treatment.

In conclusion, endobronchial fibromas are extremely rare, and their etiology remains unclear. Pathological analysis is typically required for an accurate diagnosis. The current study presents a rare case of endobronchial fibroma in a patient with pneumoconiosis and a history of tuberculosis, but no history of trauma. Endobronchial fibromas may be associated with endobronchial tuberculosis or pneumoconiosis. For patients with tuberculosis or pneumoconiosis, bronchoscopy is required for the detection of such tumors and the prevention of misdiagnosis.

### Acknowledgements

The present study was supported by the National Natural Science Foundation of China (grant no. 81270092).

### References

1. Aletras A, Bjoerk VO, Fors B, Intonti F and Madsen R: 'Benign' bronchopulmonary neoplasms. *Dis Chest* 44: 498-504, 1963.
2. Borczuk AC: Neoplastic and nonneoplastic benign mass lesions of the lung. *Arch Pathol Lab Med* 136: 1227-1233, 2012.
3. Engelman RM: Pulmonary fibroma: A rare benign tumor. *Am Rev Respir Dis* 96: 1242-1245, 1967.
4. Sauk JJ Jr, Pliego M and Anderson WR: Primary pulmonary fibroma. *Minn Med* 55: 220-223, 1972.
5. Jhun BW, Lee KJ, Jeon K, Um SW, Suh GY, Chung MP, Kwon OJ and Kim H: The clinical, radiological, and bronchoscopic findings and outcomes in patients with benign tracheobronchial tumors. *Yonsei Med J* 55: 84-91, 2014.
6. Vandeurzen R and Verschakelen JA: Endobronchial histiocytoma. *Rontgenblatter* 43: 461-462, 1990.
7. Halttunen P, Meurala H and Standerstjöld-Nordenstam CG: Surgical treatment of benign endobronchial tumours. *Thorax* 37: 688-692, 1982.
8. Corona FE and Okeson GC: Endobronchial fibroma: An unusual case of segmental atelectasis. *Am Rev Respir Dis* 110: 350-353, 1974.
9. Shah H, Garbe L, Nussbaum E, Dumon JF, Chiodera PL and Cavaliere S: Benign tumors of the tracheobronchial tree. Endoscopic characteristics and role of laser resection. *Chest* 107: 1744-1751, 1995.
10. Maeda Y, Segawa Y, Takigawa N, Takata I, Nakata M, Saeki H and Mandai K: A fibrous histiocytoma with a polypoid pattern of growth in a major bronchus. *Intern Med* 35: 724-727, 1996.
11. Das SK, Mukherjee RS, Das A, Halder AK and Saha SK: A case of haemoptysis due to endobronchial fibroma, a rare benign tumour of lung. *Lung India* 25: 25-27, 2008.
12. Mumtaz S, Alkhuziem M, Chow J, Yen A, Lin G, Harrell JH and Thistlethwaite PA: Multifocal endobronchial fibromas presenting as unilobar emphysema. *Ann Thorac Surg* 100: 1109-1111, 2015.
13. Bohn W and Sprenger F: Endobronchial fibroma as an uncommon complication of bronchus anastomosis. *Schweiz Med Wochenschr* 98: 1359-1361, 1968 (In German).
14. Yoon HK, Kim TS, Han J, Ahn KM and Shim YM: Delayed bronchostenosis after blunt chest trauma in children: CT and pathologic findings. *J Korean Med Sci* 21: 555-558, 2006.
15. Nakahara K, Miyoshi S, Kido T, Kitagawa Y, Fujii Y, Ohno K, Nanjo S, Tanioka T, Monden Y and Kawashima Y: A case report of complete right lung collapse due to the endobronchial fibroma - a successful treatment with resection and end to end anastomosis of the right main bronchus. *Nihon Kyobu Geka Gakkai Zasshi* 31: 127-32, 1983 (In Japanese).
16. Nakajima M, Yagi S, Watanabe M, Moriya O, Hashiguchi K, Okimoto N, Soejima R and Manabe T: A case of endobronchial fibroma associated with recurrent pneumonia. *Nihon Kyobu Shikkan Gakkai Zasshi* 30: 673-678, 1992 (In Japanese).
17. Sokur PP: The excision of a benign tumor of the bronchus during bronchoscopy. *Klin Khir* 5: 27-29, 1997 (In Russian).
18. Wyszynacka W, Cichicka I, Krolikiewicz K, Iwinska M and Groniowski J: Case of successful surgery of bronchial fibroma. *Gruzlica* 18: 568-579, 1950 (In undetermined language).
19. Langston HT and Fox RT: Intrabronchial fibroma managed by posterior transpleural bronchotomy. *Proc Inst Med Chic* 17: 53, 1948.
20. International Labor Organization (ILO): Guidelines for the Use of the ILO International Classification of Radiographs of Pneumoconiosis. Occupational Safety and Health Series, No. 22 (Rev. 2011). International Labor Office, Geneva Switzerland, 1980.
21. Yu P, Xu H, Zhu Y, Yang C, Sun X and Zhao J: An automatic computer-aided detection scheme for pneumoconiosis on digital chest radiographs. *J Digit Imaging* 24: 382-393, 2011.
22. Wood DE: Management of malignant tracheobronchial obstruction. *Surg Clin North Am* 82: 621-642, 2002.
23. Park SH, Choe GY, Kim CW, Chi JG and Sung SH: Inflammatory pseudotumor of the lung in a child with mycoplasma pneumonia. *J Korean Med Sci* 5: 213-223, 1990.
24. Vogels RJ, Vletterie M, Versleijen-Jonkers YM, Ruijter E, Bekers EM, Verdijk MA, Link MM, Bonenkamp JJ, van der Graaf WT, Slootweg PJ, et al: Solitary fibrous tumor-clinicopathologic, immunohistochemical and molecular analysis of 28 cases. *Diagn Pathol* 9: 224, 2014.
25. Kumar R, Desai S, Pai T, Pramesh CS and Jambhekar NA: Pulmonary adenofibroma: Clinicopathological study of 3 cases of a rare benign lung lesion and review of the literature. *Ann Diagn Pathol* 18: 238-243, 2014.
26. Lin D, Jiang Y, Wang J, Ding L, Xin F, Zhao H and Li Y: Pulmonary mixed squamous cell and glandular papilloma mimicking adenocarcinoma: a case study and literature review. *J Thorac Dis* 5: E129-E132, 2013.
27. González-Vela MC, Val-Bernal JF, González-López MA, Drake M and Fernández-Llaca JH: Pure sclerotic neurofibroma: a neurofibroma mimicking sclerotic fibroma. *J Cutan Pathol* 33: 47-50, 2006.
28. Behesthirouy S, Kakaei F, Azhough R and Fakhrjou A: Bronchial leiomyoma in a chemical warfare victim-a causative agent or an incidental finding: A case report. *Int J Surg Case Rep* 3: 420-423, 2012.
29. Cohen S, Ad-El D, Benjaminov O and Gutman H: Post-traumatic soft tissue tumors: Case report and review of the literature a propos a post-traumatic paraspinal desmoid tumor. *World J Surg Oncol* 6: 28, 2008.
30. Grant JD: Fibroma of the left vocal cord in the subject of incipient tuberculosis of the larynx. *Proc R Soc Med* 13: 151, 1920.
31. Adinolfi G and Carozza M: Genital tuberculosis and uterine fibroma. *Arch Ostet Ginecol* 77: 105-114, 1972 (In Italian).
32. Malinovskii AF and Kalechenkov MK: Successful treatment of giant desmoid of the chest wall in a patient with pulmonary tuberculosis. *Vestn Khir Im I I Grek* 145: 45-46, 1990 (In Russian).
33. Vasil'ev NA, Rymko LP and Kozhevnikov SF: Rare late complications after surgery on the lungs and chest wall in patients with tuberculosis. *Grudn Khir* 12: 81-84, 1970 (In Russian).
34. Balice G: Tuberculous myometritis simulating fibroma. *G Ital Chir* 7: 729-750, 1951 (In Italian).