

Letrozole as second-line hormonal treatment for recurrent low-grade endometrial stromal sarcoma: A case report and review of the literature

KOHEI NAKAMURA¹, KENTARO NAKAYAMA¹, MASAKO ISHIKAWA¹, NORIYOSHI ISHIKAWA²,
HIROSHI KATAGIRI¹, ATSUKO KATAGIRI¹, TOMOKA ISHIBASHI¹, EMI SATO¹,
KOHJI IIDA¹, RAZIA SULTANA¹ and SATORU KYO¹

Departments of ¹Obstetrics and Gynecology and ²Organ Pathology, Shimane University School of Medicine,
Izumo, Shimane 6938501, Japan

Received April 24, 2015; Accepted August 3, 2016

DOI: 10.3892/ol.2016.5186

Abstract. Low-grade endometrial stromal sarcoma (LGESS) is a rare malignancy. The tumor is reportedly responsive to hormonal therapy, most commonly with medroxyprogesterone acetate (MPA), but the effectiveness of aromatase inhibitors for recurrent LGESS remains unclear. The present study reports a case of stage IC LGESS presenting with abnormal uterine bleeding, and also provides a review of the literature. Following a total abdominal hysterectomy and bilateral salpingo-oophorectomy, MPA therapy was initiated; treatment was successful, but discontinued 19 months later due to disruptive side effects. A further 2 months later, the patient presented with recurrent disease and received chemotherapy. MPA treatment was restarted with a partial response. A second recurrence, 4 years later, presented with lung and para-aortic lymph node metastases. The patient responded to treatment with the aromatase inhibitor letrozole. The patient has since exhibited stable disease and remained free of symptoms for 7 years. This case suggests that aromatase-inhibitor treatment may be effective for recurrent LGESS as a second-line treatment.

Introduction

Endometrial stromal sarcoma (ESS) is an uncommon malignancy, accounting for <1% of all uterine carcinomas and 7-15% of all uterine sarcomas (1). ESS is classified as low-grade endometrial stromal sarcoma (LGESS), high-grade endometrial stromal sarcoma (HGESS) and undifferentiated uterine sarcoma (2). LGESS shows minimal to no cytological

atypia and low mitotic activity (usually <5 mitoses per 10 high-power fields (HPFs)). HGESS shows high mitotic activity (typically >10 per 10 HPFs) and is typically very striking. LGESS is generally a slow-growing malignancy with an indolent clinical course, but with a tendency for late recurrence, while HGESS is more aggressive, frequently metastasizes and has an extremely poor outcome.

Although no universal staging system exists for ESS, the International Federation of Gynecology and Obstetrics surgical staging system for endometrial cancer is typically used (2). Total abdominal hysterectomy and bilateral salpingo-oophorectomy is recommended as the primary treatment, with debulking recommended when extrauterine disease is apparent. The role of chemotherapy, radiation or hormonal treatment as adjuvant therapy has not yet been established. A number of studies have demonstrated estrogen and progesterone receptor expression in LGESS (3,4). Furthermore, LGESS has previously been shown to be responsive to hormonal therapy, including aromatase inhibitors and megestrol acetate (3,5,6). Studies have shown that synthesized progestins, including medroxyprogesterone acetate (MPA), are an effective conservative treatment for endometrial cancer (7,8).

In our previous study, we reported the cases of 2 patients with metastatic LGESS lesions who experienced prolonged survival following treatment with MPA (9). However, to the best of our knowledge, only 5 case reports detailing recurrent LGESS treated with aromatase inhibitors are reported in the literature. The present study reports a case of recurrent LGESS that was treated with surgery, followed by MPA for 2 years as first-line therapy and the aromatase inhibitor letrozole for 6 years as second-line hormonal therapy. The patient has survived for 13 years since the initial surgery.

Case report

A 58-year-old (gravida 2, para 2) woman was referred to Shimane University School of Medicine (Izumo, Japan) in May 2002 due to persistent abnormal vaginal bleeding. The patient reported a history of rheumatoid arthritis, but no other significant past medical or surgical history.

Correspondence to: Dr Kentaro Nakayama, Department of Obstetrics and Gynecology, Shimane University School of Medicine, Enyacho 89-1, Izumo, Shimane 6938501, Japan
E-mail: kn88@med.shimane-u.ac.jp

Key words: low-grade endometrial stromal sarcoma, hormonal therapy, medroxyprogesterone acetate, aromatase inhibitor, survival

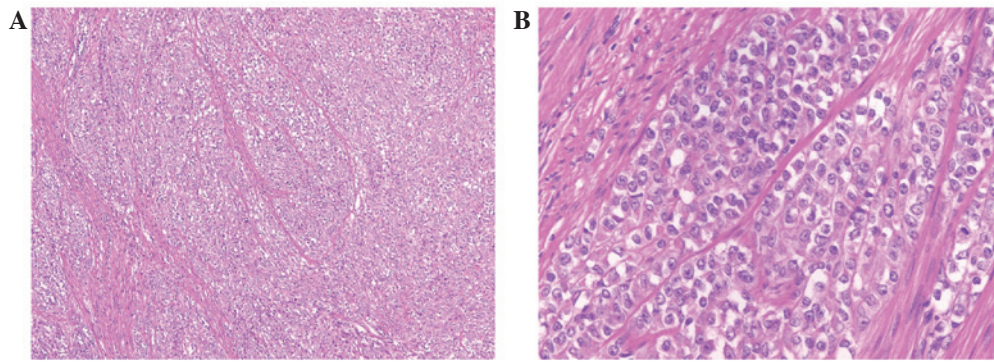


Figure 1. Cells resembling the stromal cells of proliferative endometrium arranged around small arterioles. Magnification, (A) x100 and (B) x400.

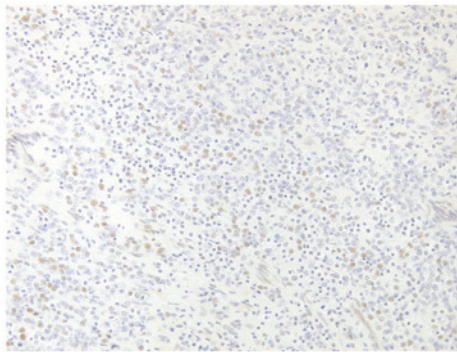


Figure 2. Immunohistochemical staining positive for estrogen receptor (magnification, x200).

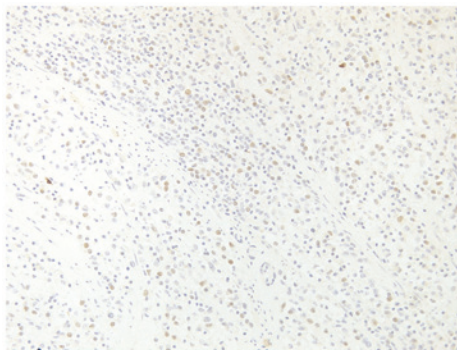


Figure 3. Immunohistochemical staining positive for progesterone receptor (magnification, x200).

Endometrial curettage revealed LGESS, based on the characteristics of the cells observed, which resembled the stromal cells of proliferative endometrium. In consequence, a total abdominal hysterectomy with bilateral salpingo-oophorectomy was performed in May 2002. The resected specimens were sectioned (section thickness, 3 μ m), and stained with hematoxylin and eosin. Subsequently, the specimens were immunohistochemically stained with the following antibodies: Anti-cluster of differentiation (CD) 10 (1:1; pre-diluted rabbit monoclonal; clone SP67; Roche Diagnostics, Basel, Switzerland); anti-estrogen receptor (1:1; pre-diluted rabbit monoclonal; clone SP1; Roche Diagnostics); anti-progesterone receptor (1:1; pre-diluted rabbit monoclonal; clone 1E2; Roche Diagnostics); anti-h-caldesmon (1:50;

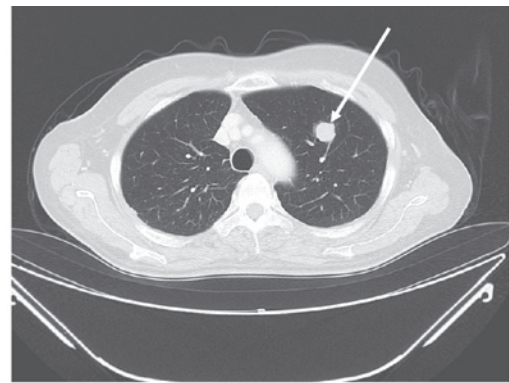

Figure 4. Contrast-enhanced computed tomography of the lungs showing a metastatic lesion (arrow).

mouse monoclonal; clone h-CD; Dako, Glostrup, Denmark); anti-cytokeratin AE1/AE3/PCK26 (1:1; pre-diluted; clone AE1/AE3/PCK26; Roche Diagnostics); anti-cytokeratin Cam5.2 (1:2; mouse monoclonal; clone Cam5.2; Roche Diagnostics); anti-desmin (1:100; mouse monoclonal; clone D33; Dako); anti- α -smooth muscle actin (1:100; mouse monoclonal; clone 1A4; Dako); anti-Melan A (1:1; pre-diluted mouse monoclonal; clone A103; Dako); and anti-human melanoma black-45 (1:50; mouse monoclonal; clone HMB-45; Dako). The histopathological result was of stage IC, low-grade ESS of the corpus uteri (Fig. 1). In addition, immunostaining revealed that the tumor tissue was positive for estrogen receptor (Fig. 2), progesterone receptor (Fig. 3) and CD10, and negative for h-caldesmon, AE1/AE3, Cam5.2, desmin, α -smooth muscle actin, Melan A and human melanoma black 45.

Post-operatively, the patient was started on 600 mg daily MPA as adjuvant therapy. The patient experienced no recurrence for 19 months, but was forced to discontinue MPA at that time, as it worsened the rheumatoid arthritis symptoms. Another 2 months later, computed tomography (CT) revealed enlargement of the common iliac lymph nodes. The patient underwent chemotherapy with 6 cycles of doxorubicin (25 mg/m² on days 1-2) and ifosfamide (1 mg/m² on days 1-5) every 3 weeks, along with lymph-node radiation. Three months after completing chemotherapy, MPA was restarted as the rheumatoid arthritis symptoms had improved. The lymph nodes gradually decreased in size and this partial response was maintained for 3 years.

Table I. Previous cases of recurrent low-grade endometrial stromal sarcoma treated with aromatase inhibitors.

First author, year	Patient age at diagnosis, years	Tumor stage	Immunostaining	Interval from diagnosis to recurrence, months	Site of recurrent lesion	First-line treatment for recurrence	Second-line treatment for recurrence	Survival since initial diagnosis, years	Survival since use of aromatase inhibitor, years	(Ref.)
Leunen <i>et al</i> 2004	76	-	ER(+), PR(+)	300	Pelvis	Aromatase inhibitor (letrozole)	-	28	3	(5)
Spano <i>et al</i> 2003	44	-	ER(+), PR(+)	3	Lung, rectum	HRT	Aromatase inhibitor (aminoglutethimide)	16	8	(19)
	34	-	ER(+), PR(+)	12	Lung	HRT	Aromatase inhibitor (letrozole)	11	2	
Leiser <i>et al</i> 2004	48	I	ER(+), PR(+)	18	Pelvis	Chemotherapy (BEP)	Megestrol acetate + aromatase inhibitor (anastrozole)	4.5	2	(20)
Maluf <i>et al</i> 2001	51	-	ER(+), PR(+)	60	Pelvis, subcutaneous nodules, subcapsular liver implant	MPA	Aromatase inhibitor (letrozole)	8	0.75	(21)
Shoji <i>et al</i> 2011	34	I	ER(+), PR(+)	60	Pelvis, ovary, peritoneum	MPA	Aromatase inhibitor (anastrozole)	21	2	(22)
Current patient	58	IC	ER(+), PR(+)	19	Lung, para-aortic lymph node	MPA and chemotherapy (ICA)	Aromatase inhibitor (letrozole)	13	7	

ER, estrogen receptor; PR, progesterone receptor; MPA, medroxyprogesterone acetate; HRT, hormonal replacement therapy; BEP, bleomycin + etoposide + cisplatin; ICA, ifosfamide + carboplatin + doxorubicin.

In January 2008, CT revealed a mass in the left lung measuring 19x13 mm (Fig. 4) and a para-aortic lymph node enlarged to 20x12 mm, compressing the right common iliac vein. MPA treatment was discontinued at this point and the patient underwent a secondary complete resection of the lung tumor. Similarly to the endometrial curettage result, the histopathological result confirmed disease metastasis. Post-operatively, informed consent was obtained for treatment with 2.5 mg daily letrozole. The patient has continued letrozole treatment to this date, and has remained asymptomatic and progression-free for 7 years.

Discussion

ESS is classified as low grade, high grade and undifferentiated based on morphology and mitotic rate. Although LGEES exhibits a relatively indolent behavior, the possibility of late recurrences and distant metastases exists (10). The risk of recurrence is believed to be as much as 50%, although such tumors usually grow slowly and the recurrence occurs late (10). In a previous large case series, the time between diagnosis or hysterectomy and recurrence was reported as between 3 months and 23 years, with a median time of 3 years (10). In the largest clinical study to date on LGEES, the median time between hysterectomy and relapse was recorded as 5.4 years for stage I disease and 9 months for disease at stages III-IV (11). In our previous series, the median disease-free time was 50 months (12).

Lymphadenectomy has not been determined to confer long-term survival in patients with LGEES (13,14). The patient in the present study was diagnosed with LGEES following surgery, which did not include either pelvic or para-aortic lymphadenectomy. Although there has been no systematic study on the advantages of adjuvant chemotherapy in LGEES, a number of retrospective analyses have shown that doxorubicin and ifosfamide combination chemotherapy exhibit a certain degree of efficacy (15-18). The present patient experienced a partial response to doxorubicin and ifosfamide-containing chemotherapy and MPA following the first recurrence.

There are few reports on the effectiveness of aromatase inhibitors in patients with recurrent LGEES due to the rarity of the disease. To the best of our knowledge, there are only 5 case reports describing aromatase inhibitors as either first- or second-line treatment for recurrent LGEES (5,19-22). Table I shows the demographic features of the patients in these cases, including the patient featured in the present study.

Several studies have described estrogen and progesterone receptor expression in ESS tumors, and have evaluated the efficacy of progestins as a treatment modality (2,23-26). In all previous patients treated with aromatase inhibitors, immunostaining was positive for estrogen and progesterone receptors; this also applied to the present patient. All studies in the present literature review have suggested the effectiveness of aromatase inhibitors, including letrozole and anastrozole, in the treatment of recurrent LGEES (5,19-22). No definitive conclusions about treatment with aromatase inhibitors can be drawn, but this option should be taken into consideration for patients with recurrent LGEES and positive immunostaining for estrogen and progesterone receptors. We recommend that immunostaining be performed when the tumor is first determined to be ESS.

Aromatase inhibitors were used as second-line treatment in 3 previous studies and as first-line treatment in only 1 study by Leunen *et al* (5). Therefore, no conclusions can be drawn as to the priority of MPA or aromatase inhibitors as first-line treatment. Due to their efficacy, further studies are warranted to evaluate aromatase inhibitors as first-line hormonal therapy in these neoplasms.

In summary, the present case reported a recurrent LGEES that responded to treatment with the aromatase inhibitor letrozole, and our experience suggests that aromatase inhibitor treatment may be effective for patients with recurrent LGEES. A number of additional case studies will be necessary to confirm these findings and support the suggested treatment.

References

- Echt G, Jepson J, Steel J, Langholz B, Luxton G, Hernandez W, Astrahan M and Petrovich Z: Treatment of uterine sarcomas. *Cancer* 66: 35-39, 1990.
- Kurman RJ, Carcangiu ML, Herrington S and Young RH (eds): World Health Organization Classification of Tumours of Female Reproductive Organs, 4th edition. IARC Press, Lyon, France.
- Tsakamoto N, Kamura T, Matsukuma K, Imachi M, Uchino H, Saito T and Ono M: Endolymphatic stromal myosis: A case with positive estrogen and progesterone receptors and good response to progestins. *Gynecol Oncol* 20: 120-128, 1985.
- Sabini G, Chumas JC and Mann WJ: Steroid hormone receptors in endometrial stromal sarcomas. A biochemical and immunohistochemical study. *Am J Clin Pathol* 97: 381-386, 1992.
- Leunen M, Breugelmanns M, De Sutter P, Bourgain C and Amy JJ: Low-grade endometrial stromal sarcoma treated with the aromatase inhibitor letrozole. *Gynecol Oncol* 95: 769-771, 2004.
- Pink D, Lindner T, Mrozek A, Kretzschmar A, Thuss-Patience PC, Dörken B and Reichardt P: Harm or benefit of hormonal treatment in metastatic low-grade endometrial stromal sarcoma: Single center experience with 10 cases and review of the literature. *Gynecol Oncol* 101: 464-469, 2006.
- Kaku T, Yoshikawa H, Tsuda H, Sakamoto A, Fukunaga M, Kuwabara Y, Hataeg M, Kodama S, Kuzuya K, Sato S, *et al*: Conservative therapy for adenocarcinoma and atypical endometrial hyperplasia of the endometrium in young women: Central pathologic review and treatment outcome. *Cancer Lett* 167: 39-48, 2001.
- Ushijima K, Yahata H, Yoshikawa H, Konishi I, Yasugi T, Saito T, Nakanishi T, Sasaki H, Saji F, Iwasaka T, *et al*: Multicenter phase II study of fertility-sparing treatment with medroxyprogesterone acetate for endometrial carcinoma and atypical hyperplasia in young women. *J Clin Oncol* 25: 2798-2803, 2007.
- Ishibashi M, Nakayama K, Shamima Y, Katagiri A, Iida K, Nakayama N and Miyazaki K: Two cases of endometrial stromal sarcoma (ESS) in which survival was prolonged by administration of MPA. *Gan To Kagaku Ryoho* 35: 857-861, 2008 (In Japanese).
- Stadsvold JL, Molpus KL, Baker JJ, Michael K and Remmenga SW: Conservative management of a myxoid endometrial stromal sarcoma in a 16-year-old nulliparous woman. *Gynecol Oncol* 99: 243-245, 2005.
- Amant F, Moerman P, Cadron I, Neven P, Berteloot P and Vergote I: The diagnostic problem of endometrial stromal sarcoma: Report on six cases. *Gynecol Oncol* 90: 37-43, 2003.
- Nakayama K, Ishikawa M, Nagai Y, Yaegashi N, Aoki Y and Miyazaki K: Prolonged long-term survival of low-grade endometrial stromal sarcoma patients with lung metastasis following treatment with medroxyprogesterone acetate. *Int J Clin Oncol* 15: 179-183, 2010.
- Shah JP, Bryant CS, Kumar S, Ali-Fehmi R, Malone JM Jr and Morris RT: Lymphadenectomy and ovarian preservation in low-grade endometrial stromal sarcoma. *Obstet Gynecol* 112: 1102-1108, 2008.
- Thomas MB, Keeney GL, Podratz KC and Dowdy SC: Endometrial stromal sarcoma: Treatment and patterns of recurrence. *Int J Gynecol Cancer* 19: 253-256, 2009.

15. Haberal A, Kayıkçıoğlu F, Boran N, Calışkan E, Özgül N and Köse MF: Endometrial stromal sarcoma of the uterus: Analysis of 25 patients. *Eur J Obstet Gynecol Reprod Biol* 109: 209-213, 2003.
16. Omura GA, Blessing JA, Major F, Lifshitz S, Ehrlich CE, Mangan C, Beecham J, Park R and Silverberg S: A randomized clinical trial of adjuvant adriamycin in uterine sarcomas: A gynecologic oncology group study. *J Clin Oncol* 3: 1240-1245, 1985.
17. Pautier P, Genestie C, Fizazi K, Morice P, Mottet C, Haie-Meder C, Le Cesne A and Lhommé C: Cisplatin-based chemotherapy regimen (DECAV) for uterine sarcomas. *Int J Gynecol Cancer* 12: 749-754, 2002.
18. Kim WY, Lee JW, Choi CH, Kang H, Kim TJ, Kim BG, Lee JH and Bae DS: Low-grade endometrial stromal sarcoma: A single center's experience with 22 cases. *Int J Gynecol Cancer* 18: 1084-1089, 2008.
19. Spano JP, Soria JC, Kambouchner M, Piperno-Neuman S, Morin F, Morere JF, Martin A and Breau JL: Long-term survival of patients given hormonal therapy for metastatic endometrial stromal sarcoma. *Med Oncol* 20: 87-93, 2003.
20. Leiser AL, Hamid AM and Blanchard R: Recurrence of prolactin-producing endometrial stromal sarcoma with sex-cord stromal component treated with progestin and aromatase inhibitor. *Gynecol Oncol* 94: 567-571, 2004.
21. Maluf FC, Sabbatini P, Schwartz L, Xia J and Aghajanian C: Endometrial stromal sarcoma: Objective response to letrozole. *Gynecol Oncol* 82: 384-388, 2001.
22. Shoji K, Oda K, Nakagawa S, Kawana K, Yasugi T, Ikeda Y, Takazawa Y, Kozuma S and Taketani Y: Aromatase inhibitor anastrozole as a second-line hormonal treatment to a recurrent low-grade endometrial stromal sarcoma: A case report. *Med Oncol* 28: 771-774, 2011.
23. Chu MC, Mor G, Lim C, Zheng W, Parkash V and Schwartz PE: Low-grade endometrial stromal sarcoma: Hormonal aspects. *Gynecol Oncol* 90: 170-176, 2003.
24. Piver MS, Rutledge FN, Copeland L, Webster K, Blumenson L and Suh O: Uterine endolymphatic stromal myosis: A collaborative study. *Obstet Gynecol* 64: 173-178, 1984.
25. Katz L, Merino MJ, Sakamoto H and Schwartz PE: Endometrial stromal sarcoma: A clinicopathologic study of 11 cases with determination of estrogen and progestin receptor levels in three tumors. *Gynecol Oncol* 26: 87-97, 1987.
26. Scribner DR Jr and Walker JL: Low-grade endometrial stromal sarcoma preoperative treatment with Depo-Lupron and Megace. *Gynecol Oncol* 71: 458-460, 1998.