

# Anti-osteoclastic agent, denosumab, for a giant cell tumor of the bone with concurrent Paget's disease: A case report

TAKAAKI TANAKA<sup>1,2</sup>, JOHN SLAVIN<sup>3</sup>, SUE-ANNE McLACHLAN<sup>4</sup> and PETER CHOONG<sup>1,5,6</sup>

<sup>1</sup>Department of Orthopedics, St. Vincent's Hospital Melbourne, Fitzroy, Victoria 3065, Australia;

<sup>2</sup>Department of Orthopedic Surgery, Osaka University Graduate School of Medicine, Suita, Osaka 565-0871, Japan;

Departments of <sup>3</sup>Pathology, <sup>4</sup>Oncology and <sup>5</sup>Surgery, St. Vincent's Hospital Melbourne, Fitzroy, Victoria 3065;

<sup>6</sup>Bone and Soft Tissue Sarcoma Unit, Peter MacCallum Cancer Centre, East Melbourne, Victoria 3002, Australia

Received February 24, 2016; Accepted November 30, 2016

DOI: 10.3892/ol.2017.5693

**Abstract.** Paget's disease of the bone may predispose the development of malignant bone tumors such as osteosarcoma. Giant cell tumor (GCT) as a consequence of Paget's disease is rare. Bone GCT is characterized by rapid growth, the destruction of bone, extension to the surrounding soft tissue and abnormal bone turnover caused by an abnormality of the receptor activator of nuclear factor- $\kappa$ B (RANK)-RANK ligand (RANKL) pathway. Denosumab is a RANK-RANKL inhibitor, which is used to treat osteoporosis and bone GCT. In the current study, a 60-year-old male presented with severe pain located between the right thigh and the knee. The patient could not bear weight on the affected leg. The patient had suffered from Paget's disease for 15 years. The complications from Paget's disease included degenerative hip disease, for which the patient underwent a right total hip replacement. A right periacetabular lesion was identified and confirmed as Paget's disease-induced GCT by needle biopsy. A positron emission tomography (PET) scan revealed significant tumor metabolic activity. Subsequent to obtaining informed consent, the patient started treatment with denosumab. A total of 2.5 months after starting denosumab, a PET scan showed no residual pathological uptake at the site of the previously identified large PET avid tumor. After 1 year, the patient exhibited a satisfactory clinical improvement. In conclusion, treatment with denosumab markedly reduced the size of the hemi-pelvic GCT and led to a complete metabolic response.

## Introduction

Paget's disease of the bone is a disorder of bone remodeling, bone expansion and bone structure due to hyperactive and irregular osteoclast and osteoblast activity. Anti-osteoclastic agents such as bisphosphonates are used to suppress increased bone turnover to normal levels. Major complications of the disease include fractures, osteoarthritis, and hearing difficulties (1). Paget's disease is also known to predispose affected individuals to bone tumors, most commonly osteosarcoma, which occurs in ~1% of patients, however, the development of giant cell tumors (GCT) is rare (2,3).

Bone GCTs are known for their rapid growth, the destruction of bone and extension into the surrounding soft tissue. Local recurrence is common if surgery to completely remove the tumor is inadequate (4). When surgical procedures are not possible or deemed unacceptable due the associated level of morbidity, radiotherapy, chemotherapy, interferons and bisphosphonates have been recommended as alternative treatments (5). However, radiotherapy is associated with a risk of malignant transformation, and chemotherapy, interferon and bisphosphonates exhibit unpredictable response rates. Denosumab is a human monoclonal antibody to the receptor activator of nuclear factor- $\kappa$ B ligand (RANKL) (5) and has demonstrated clinical efficacy for the treatment of patients with GCT. Recent studies have suggested that denosumab may be an acceptable and more predictable anti-GCT agent (5-8).

Paget's disease and GCT are characterized by abnormal bone turnover caused by the RANK-RANKL pathway. Denosumab is a RANK-RANKL inhibitor, which has been deployed for the treatment of osteoporosis and, more recently, for GCT of the bone. To the best of our knowledge, the current study presents the first reported case of Paget's disease-induced GCT treated effectively by denosumab. This study was approved by the Ethics Committee of St. Vincent's Hospital Melbourne (Melbourne, Victoria, Australia). The patient provided informed consent regarding medical information and the publication of the present study.

---

*Correspondence to:* Professor Peter Choong, Department of Orthopedics, St. Vincent's Hospital Melbourne, 41 Victoria Parade, Fitzroy, Victoria 3065, Australia  
E-mail: sarcoma@bigpond.net.au

*Abbreviations:* GCT, giant cell tumor; RANK, receptor activator of nuclear factor- $\kappa$ B

*Key words:* giant cell tumor, Paget's disease, denosumab, RANK-RANK ligand pathway, abnormal bone turnover

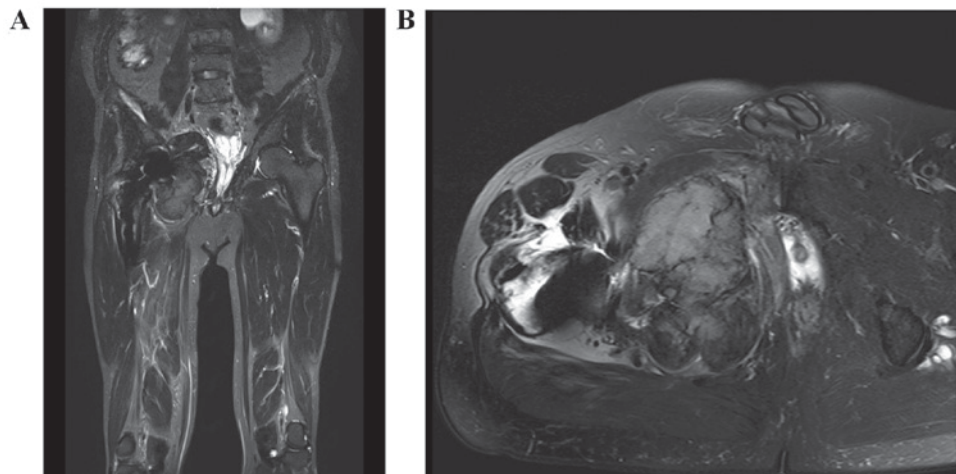


Figure 1. Pre-treatment MRI. T2-weighted (A) coronal and (B) axial pre-treatment MRI showing the large right hemi-pelvis lesion extending into the proximal right adductor compartment. MRI, magnetic resonance imaging.

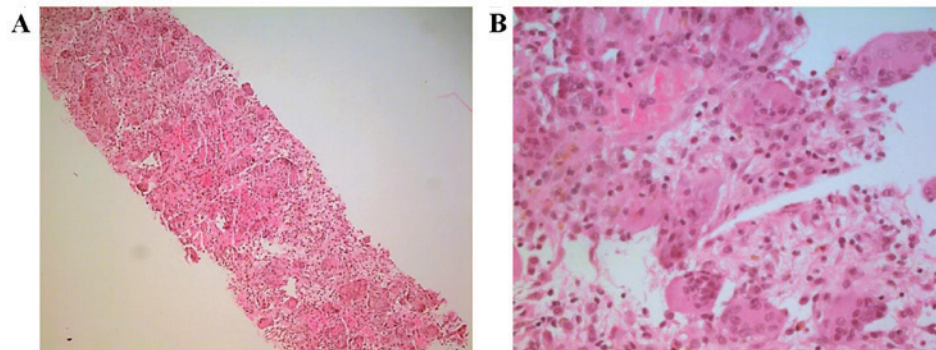


Figure 2. Hematoxylin and eosin staining of the pre-treatment biopsy specimen. Microscopic examination revealing multiple giant cell tumors composed of large osteoclastic giant cells mixed with mononuclear cells. (A) Low-power view (magnification, x10) and (B) high-power view (magnification, x40).

### Case report

A 60-year-old male, with an 18-month history of right groin pain for which no cause had been found, was admitted to St. Vincent's Hospital Melbourne in July 2014. A total of 4-5 weeks prior to presentation, the patient developed progressive right thigh pain that extended to the knee. The patient was previously diagnosed with Paget's disease in 1999, and had been receiving treatment of bisphosphonate medication at Austin Hospital (Melbourne, Victoria, Australia). The complications from Paget's disease included degenerative hip disease, for which the patient underwent a right total hip replacement in 2011. The patient also exhibited bilateral hearing loss and pain in the spine and knees. Regarding family history, the father and uncle of the patient were also diagnosed with Paget's disease. The patient could not weight bear on the right side due to the pain. Blood investigations obtained results that were within the normal ranges, including the serum alkaline phosphatase level (87 U/l). Magnetic resonance imaging (MRI) revealed a large right periacetabular lesion that extended into the ilium and pubis, and into the adductor compartment of the thigh (Fig. 1). A computed tomography (CT)-guided needle biopsy of the right acetabular lesion was performed, Hematoxylin and eosin staining of the pre-treatment biopsy specimen showed large osteoclastic giant cells mixed with mononuclear cells, and this

pathological examination revealed GCT of the bone (Fig. 2), with no evidence of malignancy. Positron emission tomography (PET) showed the pelvic mass with a maximum standardized uptake value of 20 and low-grade uptake within the L3 and L5 vertebrae, the sacrum and the left posterior ilium consistent with the benign bone remodeling of Paget's disease (Fig. 3). These findings suggested that the right acetabular lesion was a GCT induced by Paget's disease, and that the other lesions were focally increased bone resorption and bone formation due to hyperactive osteoclasts and osteoblasts. The case was discussed in a multidisciplinary meeting, and it was decided that the patient should be treated with denosumab. Subsequent to obtaining informed consent, the patient was administered 120 mg denosumab by subcutaneous injection on days 1, 8 and 15, and then once every 4 weeks since July 2014 to the time of writing. A total of 2.5 months after starting denosumab treatment, an MRI scan showed a marked reduction in the size of the periacetabular tumor (Fig. 4). A PET scan showed no residual pathological uptake at the site of the previously identified large intensity avid right pelvic tumor, and a decrease in the size of the residual right pelvic soft-tissue mass (Fig. 5). Notably, there was a marked reduction in PET avidity at the other sites aforementioned. A CT-guided needle biopsy of the periacetabular lesion was repeated, revealing no evidence of GCT, only features of Paget's disease (Fig. 6). Presently, 1 year

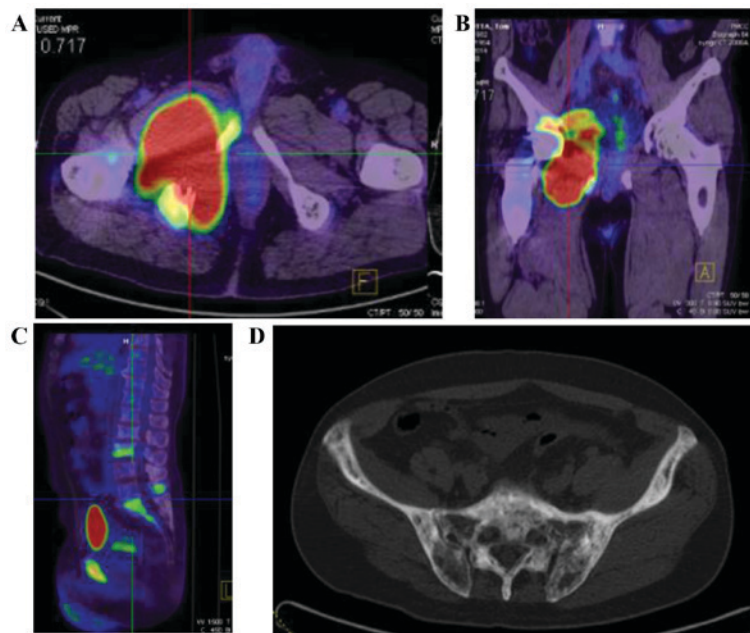


Figure 3. Pre-treatment positron emission tomography. (A and B) Large right hemi-pelvic lesion with a maximum standardized uptake value of 20 and (C) low grade uptake within the L3 and L5 vertebrae, and the sacrum. (D) Plain computed tomography of the sacrum and ilium, with an appearance consistent with benign bone remodeling of Paget's disease.

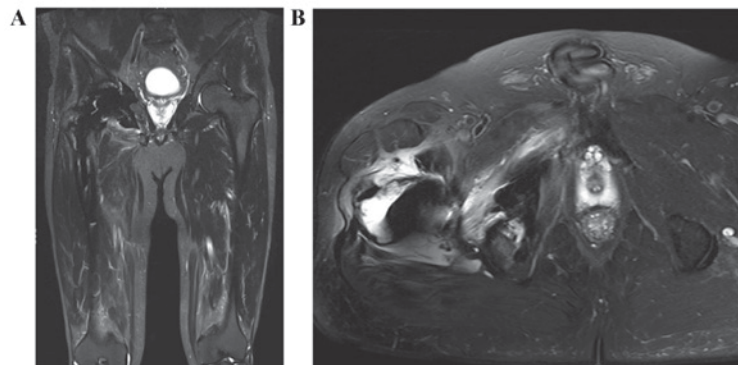


Figure 4. MRI after 2.5 months of denosumab treatment. T2-weighted (A) coronal and (B) axial MRI showing a marked reduction in the size of the tumor around the extraosseous component of the right acetabulum. MRI, magnetic resonance imaging.

after the diagnosis of Paget's disease-induced GCT of bone, the patient exhibits minimal symptoms and can fully weight bear on the right side.

### Discussion

The symptoms and signs of the patient with Paget's disease in the present study were of concern with respect to malignancy. However, subsequent to biopsy, a rare complication of Paget's disease was diagnosed, namely, GCT of the bone. The main reason surgery was not performed was due to the previous hip replacement, and the high risk of blood vessel and nerve injuries from an approach requiring wide excisional margins. A non-surgical approach was therefore used, focusing on the RANK-RANKL pathway, which has been associated with diseases where osteoclastic action is affected, such as Paget's disease and GCT. In these diseases, abnormal bone turnover is caused by an aberration in the RANK-RANKL pathway. Denosumab is a RANK-RANKL inhibitor that has been found

to exhibit efficacy in the treatment of osteoporosis and in small case series of GCT (5-8).

Only 3 studies have described the use of denosumab in the treatment of Paget's disease, 1 in a patient with chronic kidney disease for whom bisphosphonates were contraindicated (9) and 2 in patients who had been diagnosed with juvenile Paget's disease (10,11). All 3 studies demonstrated that denosumab successfully controlled the disease, but 1 patient exhibited severe hypocalcaemia during the treatment. There have been no reports of denosumab use in the treatment of concurrent Paget's disease and GCT.

A limitation of the present study is that the follow-up was only 1 year, however, the effect of the denosumab was observed following treatment for only 2.5 months. The present study confirmed the diagnosis of GCT for the large right hemi-pelvic lesion by CT-guided needle biopsy prior to denosumab treatment, but biopsies were not performed on the lesions in the L3 and L5 vertebrae, the sacrum and the left ilium, as these appeared typical for Paget's disease, without

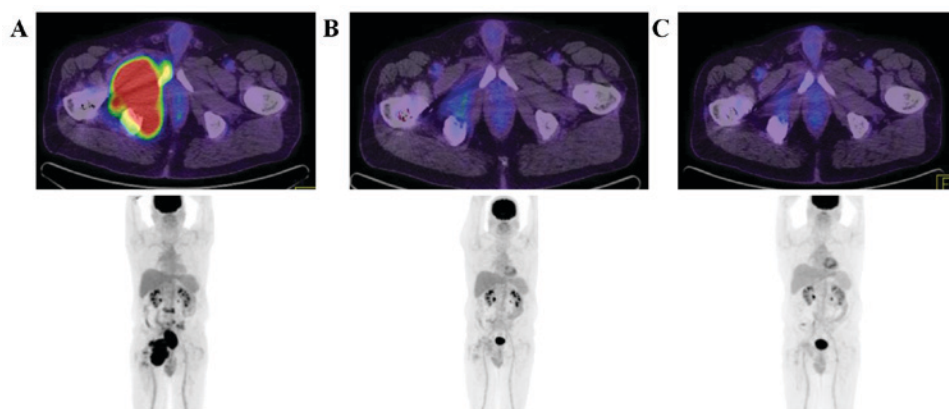


Figure 5. Sequential PET images. PET images (A) prior to treatment, and (B) 3 and (C) 8 months after denosumab treatment. A large right hemi-pelvic lesion was observed pre-treatment, but not subsequent to treatment with denosumab. PET, positron emission tomography.

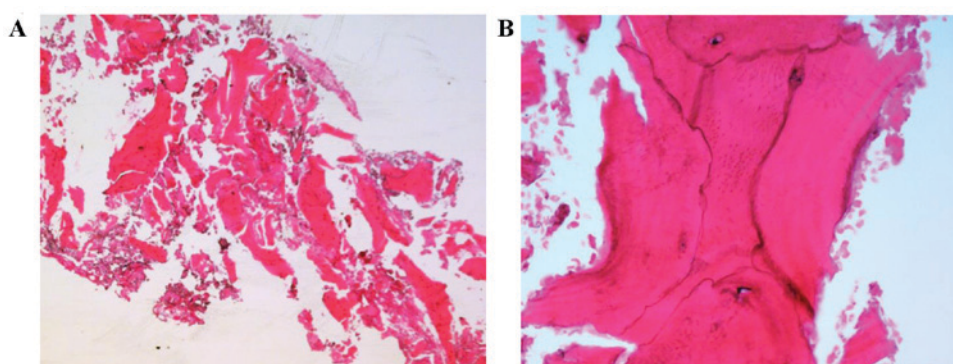


Figure 6. Hematoxylin and eosin stain of the biopsy specimen subsequent to denosumab treatment. Microscopic examination of the biopsy specimen subsequent to denosumab treatment for 4 months revealing trabecular bone with irregular cement lines, the typical histopathological feature of Paget's disease. (A) Low-power view (magnification, x4) and (B) high-power view (magnification, x40).

any imaging features of transformation. The patient is still being administered denosumab treatment every 4 weeks, even 1 year subsequent to treatment with denosumab, and it is unclear when this treatment should be ceased.

In conclusion, a 60-year-old male who presented with Paget's disease of the right pelvis complicated by GCT with extension into the proximal right adductor compartment was treated successfully with denosumab in the present study. The treatment with denosumab markedly reduced the size of the hemi-pelvic lesion and led to a complete metabolic response. Therefore, denosumab may be a good option for the treatment of Paget's disease-induced GCT.

### Acknowledgements

The authors would like to thank Ms. Deborah May, a Clinical Research Nurse of the Department of Orthopedics at St. Vincent's Hospital Melbourne, and Ms. Danielle Jensen, Administrative Support for the Bone and Soft Tissue Clinic at Peter McCallum Cancer Institute, for their assistance with the databases of the two institutes.

### References

- Whyte MP: Clinical practice. Paget's disease of bone. *N Engl J Med* 355: 593-600, 2006.
- Haibach H, Farrell C and Dittrich FJ: Neoplasms arising in Paget's disease of bone: A study of 82 cases. *Am J Clin Pathol* 83: 594-600, 1985.
- Mankin HJ and Hornicek FJ: Paget's sarcoma. A historical and outcome review. *Clin Orthop Relat Res* 438: 97-102, 2005.
- Malawer M, Helman L and O'Sullivan B: Sarcomas of bone. In *Cancer: Principles and practices of oncology*. 8th edition. Lippincott Williams and Wilkins, Philadelphia, pp1794-1834, 2008.
- Skubitz KM: Giant cell tumor of bone: Current treatment options. *Curr Treat Options Oncol* 15: 507-518, 2014.
- Xu SF, Adams B, Yu XC and Xu M: Denosumab and giant cell tumour of bone-a review and future management considerations. *Curr Oncol* 20: e442-e447, 2013.
- Mak IW, Evaniew N, Popovic S, Tozer R and Ghert M: A translational study of the neoplastic cells of giant cell tumor of bone following neoadjuvant denosumab. *J Bone Joint Surg Am* 96: e127, 2014.
- Ueda T, Morioka H, Nishida Y, Kakunaga S, Tsuchiya H, Matsumoto Y, Asami Y, Inoue T and Yoneda T: Objective tumor response to denosumab in patients with giant cell tumor of bone: A multicenter phase II trial. *Ann Oncol* 26: 2149-2154, 2015.
- Schwarz P, Rasmussen AQ, Kvist TM, Andersen UB and Jørgensen NR: Paget's disease of the bone after treatment with Denosumab: A case report. *Bone* 50: 1023-1025, 2012.
- Grasemann C, Schündeln MM, Hövel M, Schweiger B, Bergmann C, Herrmann R, Wiczorek D, Zabel B, Wieland R and Hauffa BP: Effects of RANK-ligand antibody (denosumab) treatment on bone turnover markers in a girl with juvenile Paget's disease. *J Clin Endocrinol Metab* 98: 3121-3126, 2013.
- Polyzos SA, Singhellakis PN, Naot D, Adamidou F, Malandrinou FC, Anastasilakis AD, Polymerou V and Kita M: Denosumab treatment for juvenile Paget's disease: Results from two adult patients with osteoprotegerin deficiency ('Balkan' mutation in the TNFRSF11B gene). *J Clin Endocrinol Metab* 99: 703-707, 2014.