

A large Chinese pedigree of multiple endocrine neoplasia type 2A with a novel C634Y/D707E germline mutation in *RET* exon 11

FANQIAN LU^{1,2}, XIAOHONG CHEN^{1,2}, YUNLONG BAI^{1,2}, YARU FENG^{1,2} and JIAN WU³

¹Department of Otolaryngology, Head and Neck Surgery, Beijing Tongren Hospital, Capital Medical University, Beijing 100730; ²Key Laboratory of Otolaryngology, Head and Neck Surgery, Ministry of Education, Beijing Institute of Otolaryngology, Beijing 100005; ³MyGenostics, Inc., Beijing 101318, P.R. China

Received October 16, 2015; Accepted March 17, 2017

DOI: 10.3892/ol.2017.6583

Abstract. The present study identified the clinical features of the largest multiple endocrine neoplasia type 2 (MEN2) A pedigree from China, with a novel double missense *rearranged during transfection* (*RET*) mutation (C634Y/D707E). To the best of our knowledge, the D707E mutation has not been identified to date. In the present study, a total of 101 family members who originated from a large pedigree (134 members in total) underwent *RET* mutation screening by next-generation sequencing and polymerase chain reaction (PCR) amplification, followed by direct bidirectional DNA sequencing. The clinical features of this pedigree were carefully reviewed retrospectively, and statistical analyses were conducted using SPSS software. A total of 33 (32.67%) carriers were identified to exhibit the C634Y/D707E *RET* germline mutation. The mean age of the patients with medullary thyroid carcinoma (MTC) identified by *RET* screening was 38.4±16.5 years (n=11; range, 14-65 years). Only 4 patients with pheochromocytoma with a median age of 37 years were identified. No hyperparathyroidism was diagnosed. Persistent or recurrent disease developed in the patients of the present study who underwent inappropriate initial thyroid surgeries that were performed in previous decades (III10, III23, III24, III27 and IV46, as they had undergone two surgeries prior to the present study). A total of 66.70% (6/9) of patients, following thyroidectomy, continued to develop persistent or recurrent disease during the present screening study. In

total, 3 patients succumbed to MTC or distant metastasis in the present study. The increase in carcinoembryonic antigen (CEA) levels correlated with the increase in basal serum calcitonin (Ct) levels according to Pearson correlation analysis in patients with MTC without surgery. Ct and CEA levels were also significantly correlated with tumor volumes. To the best of our knowledge, the present study is the first to identify a novel double *RET* missense mutation in the largest MEN2A pedigree from China. Additional in-depth study is necessary to elucidate the molecular mechanisms of the D707E mutation and its potential joint effects with the other C634Y mutation in the pedigree of the present study.

Introduction

Multiple endocrine neoplasia type 2 (MEN2) is an autosomal-dominant disease; mutations in the *rearranged during transfection* (*RET*) proto-oncogene on chromosome 10q11.2 have been identified as the genetic cause of MEN2 (1,2). Worldwide, >500 families with >70 mutations in the *RET* gene have been identified in MEN2 (2-4). The majority of mortalities of patients with MEN2 are attributed to medullary thyroid carcinoma (MTC), a malignant neuroendocrine tumor originating from thyroid parafollicular C cells (4,5). At present, treatment options include total thyroidectomy, central neck nodal dissection or lateral neck nodal dissection following presurgical diagnosis and a correct clinical staging of MTC (5). Although the timely diagnosis of this tumor is challenging in clinical practice (5), screening at-risk relatives of a patient with MTC for mutations of the *RET* gene may improve early identification of susceptible carriers and asymptomatic patients (6). Different mutations within the *RET* gene may result in varying risks for malignancy (6,7). The classification system created to predict risk for aggressive MTC in patients with MEN2A for *RET* mutations has assisted in guiding clinical treatment (1,6). As ≥2 simultaneous *RET* mutations, or combined with other gene mutations, are being continuously identified, the classification system is also being continuously improved (6,7).

Previous studies have suggested that the transforming activity of double *RET* germline mutations is stronger compared with that of only one mutation; it is hypothesized that double *RET* mutations may be associated with unusual MEN2 phenotypes (8-10). In the present study, a five-generation

Correspondence to: Dr Xiaohong Chen, Department of Otolaryngology, Head and Neck Surgery, Beijing Tongren Hospital, Capital Medical University, 1 Dong Jiao Min Xiang, Dongcheng, Beijing 100730, P.R. China
E-mail: trchxh@163.com

Abbreviations: CEA, carcinoembryonic antigen; MEN2, multiple endocrine neoplasia type 2; MTC, medullary thyroid carcinoma; PCR, polymerase chain reaction; *RET*, *rearranged during transfection*

Key words: MEN2A, medullary thyroid carcinoma, C634Y, D707E, double mutation

northern Chinese pedigree with a combination of two germline missense mutations (C634Y and D707E) within exon 11 of *RET* was investigated. This pedigree presented with pheochromocytoma (PHEO) as a result of MEN2A. Of the 101 family members tested by sequencing for all the relevant exons of the *RET* gene, 22 patients and 5 carriers were identified in this pedigree, while 6 suspicious patients without *RET* screening were excluded. The functional effect of D707E mutation remains uncharacterized.

Patients and methods

The index case (III-17; Fig. 1) was a 52-year-old male with bilateral MTC from Northern China. Prior to arrival at Beijing Tongren Hospital (January 2014; Beijing, China) for examination and potential treatment, the patient complained of a palpable neck mass as the simple clinical manifestation the first time the patient visited a clinician. The patient underwent total thyroidectomy without central compartment node dissection 1 year prior to hospital admission. Apart from routine examination for MTC, genomic DNA was also purified from the peripheral blood. As certain point mutations occur within and outside of hot point locations (6), and next-generation sequencing offers significant advantages in enabling the sensitive detection of low-prevalence mutations, all exons of the *RET* gene were tested for mutations by next-generation sequencing in MyGenostics, Inc. (Beijing, China). *RET* mutation c.1901 G>A (p.Cys634Tyr) at position chr10-43609949 and *RET* mutation c.2121T>A (p.D707E) at position chr10-43610169 were identified in exon 11. A total of 3 common polymorphisms were also identified in this patient, including p.A45A in exon 2, p.A432A in exon 7 and p.L769L in exon 13.

From the family history of the patient, it was revealed that there were 5 generations with a total of 134 individuals in the whole family. A total of 101 relatives from 3 generations completed genetic testing from January to September 2014 following the provision of a detailed explanation about MEN2A disease. All participants and/or their legal guardians provided written informed consent for participation in the present study, as required by the Ethics Committee of the Beijing Tongren Hospital (approval no. TRECKY2014-011).

All the *RET* mutation carriers identified underwent clinical and biochemical examinations, including a biochemical evaluation consisting of basal serum calcitonin (Ct; pg/ml; normal range, female: 0.00-11.50; male: 0.00-18.50), carcinoembryonic antigen (CEA; ng/ml; normal range, 0.00-5.00), parathyroid hormone (PTHJK; pg/ml; normal range, 12.00-65.00), epinephrine (E; pmol/ml; normal range, 0.05-1.39), norepinephrine (NE; pmol/ml; normal range, 0.51-3.26) and dopamine (DA; pmol/ml; normal range, 0.07-0.68) measurements. Doppler ultrasound and computerized tomography scans were also performed. Genomic DNA was purified from the peripheral blood, and the two mutations of *RET* which were identified by probes were tested by polymerase chain reaction (PCR) amplification, followed by direct bidirectional DNA sequencing by MyGenostics, Inc., for all the available family members. The PCR and sequencing were performed by MyGenostics, Inc., and the normal PCR reagent used was KAPA2G Mix, provided by Beijing ComWin Biotech Co., Ltd. (Beijing, China). PCR was performed prior to sequencing

using BigDye® Mix provided by Applied Biosystems (Thermo Fisher Scientific, Inc., Waltham, MA, USA). Statistical analyses (t-test and Pearson's correlation analysis) were performed using SPSS software (version 17.0; SPSS, Inc., Chicago, IL, USA). $P < 0.05$ was considered to indicate a statistically significant difference.

Results

Of the 101 family members tested for relevant *RET* mutations in the present study (Fig. 1), 22 patients with MTC were identified that possessed the C634Y/D707E mutation (mutation point illustrated in Fig. 2) (mean age, 38.4 ± 16.5 years old; range, 14-65 years;). A total of 4 patients (III-19, III-25, III-27 and IV-44) presented with PHEO and MTC; 5 participants (IV-8, IV-39, IV-49, V-7 and V-39) had negative hematological and imaging examinations and were non-symptomatic carriers of the mutations; 5 suspected patients (II-2, II-3, II-5, II-6 and III-15) were deceased at the time of screening and II-4 rejected the screening. II-2, II-3, II-4, II-5 and II-6 were suspected due to them having the same ancestors and their descendants possessed the C634Y/D707E mutation. Of the 4 patients with PHEO, 3 underwent PHEO resection, and 11 of all patients identified (mean age at first diagnosis, 36.2 ± 12.7 years; range, 15-50 years) received thyroidectomy prior to genetic screening (Table I). However, due to poor recognition of this disease in previous years, 9 out of the 11 patients did not receive timely or effective treatment. In total, 3 patients (III-13, III-25 and IV-44) out of these 9 individuals underwent tumor resection only, and 2 of these 3 patients (III-13 and IV-44) suffered recurrent MTC in the residual thyroid, as indicated by markedly elevated Ct levels (III-13, Ct, pg/ml, $>2,000.00$, normal range, female: 0.00-11.50; male: 0.00-18.50; CEA, ng/ml, 46.57, normal range, 0.00-5.00) (IV-44, Ct, pg/ml, 356.00, normal range, female: 0.00-11.5; male: 0.00-18.50; CEA, ng/ml, 11.51, normal range, 0.00-5.00) and positive thyroid ultrasound results during the present screening study (Table I). Patient III-25 survived without tumor recurrence for 34 years. A total of 5 patients (III-10, III-24, IV-46, III-27 and III-23) underwent two surgeries, with the surgeries in each patient having been performed within 10, 3, 7, 9 and 24 years, respectively. Patient eIII-24 received a non-total thyroidectomy in the second operation 3 years following the first operation; 4 patients (III-10, III-24, III-27 and III-23) exhibited biochemical recurrence during this screening; and patient eIV-46 did not exhibit elevated biochemical marker levels (Ct, pg/ml, <2.00 , normal range, female: 0.00-11.50; male: 0.00-18.50; CEA, ng/ml, 0.68, normal range, 0.00-5.00), but developed lymphatic metastasis 7 years subsequent to the first non-total thyroidectomy and received the second surgery.

Regarding the 5 deceased but suspected patients (II-2, II-3, II-5, II-6 and III-15), their surviving partners were screened for *RET* gene mutations, and none of them carried the identified *RET* mutations. Considering the consistent mutation manifestation in their descendants, and the absence of such mutations in their partners, it was suggested that these 5 deceased individuals carried the identified *RET* gene mutations, although confirmatory evidence was impossible to obtain as they had succumbed prior to the present study. For

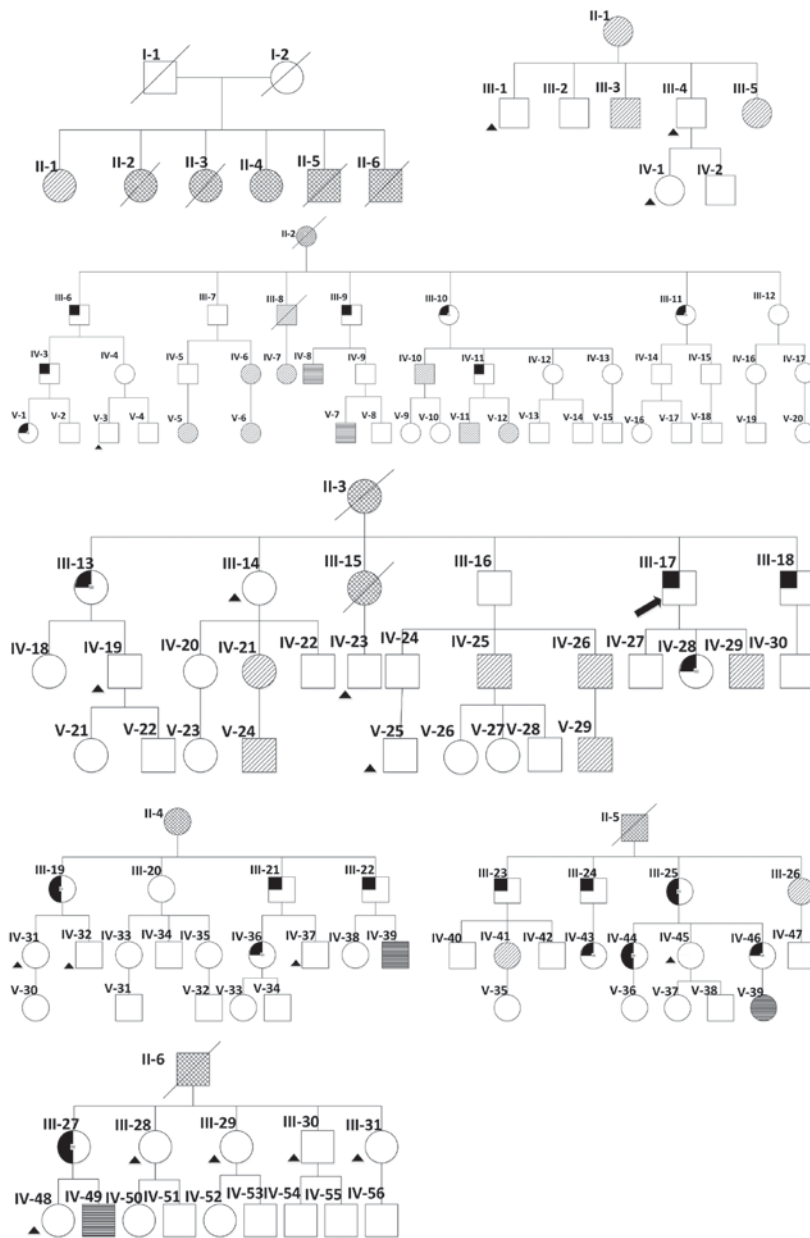


Figure 1. All family members of the present pedigree: □, normal male; ○, normal female; ■/●, positive for MTC and *RET* mutation; ▨/⊖, negative for MTC and positive for *RET* mutation; ●/●, not tested but suspected positive for MTC and *RET*; /, deceased; ■/●, positive for MTC and PHEO; ▲, benign thyroid disease and negative for *RET* mutation; ⚡, index case; □/○, not tested. MTC, medullary thyroid carcinoma; *RET*, rearranged during transfection; I, II, III, IV, V and VI refer to the different generations in the family, from oldest to youngest.

example, patient III-15 was 35 years old when succumbing to bone metastases. This patient developed persistent diarrhea 9 years following the diagnosis of MTC, and received a partial thyroidectomy. Patient II-3 succumbed to lung cancer 1 year following a total thyroidectomy performed to remove two marked nodules in the neck. This patient exhibited no other surgical history prior to this procedure. Patient III-8 succumbed to cervical carcinoma, with no clear cause of mortality.

Of the 4 patients who suffered PHEO with hypertension and/or headache, palpitations, sweating and vomiting, 3 (III-19, III-25 and IV-44) were subjected to adrenal-sparing surgical resection, while 1 (III-27) was waiting for surgery at the time of the present study. Patient III-19 was scheduled for adrenal-sparing surgery due to a recurrent PHEO 1 year

subsequent to her first PHEO resection. The manifestations of PHEO were identified following MTC diagnosis in patients III-25, IV-44 and III-27, while MTC was not identified in patient III-19 until the present screening study.

With the exception of the 4 patients with PHEO, almost all the identified patients presented with a palpable neck lump or thyroid nodules by physical examination as the first clinical manifestation. Patients III-23, III-27 and IV-36 additionally exhibited symptoms of facial flushing, diarrhea and palpitation. Among the total 22 patients, 6 patients (III-13, III-18, IV-28, IV-36, IV-44 and IV-46) exhibited bilateral lymph node metastases that were confirmed by pathological examinations. There was no clinical or biochemical evidence of hyperparathyroidism in any of the carriers. Hirschsprung disease and cutaneous lichen amyloidosis were also excluded based

Table I. Clinical characteristics and radiological data of the mutation-positive family members operated prior to *rearrangement during transfection* screening.

Patient	Sex	Age, years	Age at first diagnosis, years	Ct, pg/ml	CEA, ng/ml	Surgery	Thyroid imaging (ultrasound), cm
III-10	F	68	42	27.90	4.40	2TT	NA
III-11	F	62	34	<2.00	2.53	TT	NA
III-13	F	62	42	>2,000.00	46.57	NTT	RL: 1.9x1.5x2.0, IL: 1.0x0.5, LL: 0.6x0.4
III-17	M	52	50	6.47	3.08	TT	Negative
III-21	M	46	46	307.00	55.52	TT	NA
III-23	M	81	46	28.00	4.84	2TT	Negative
III-24	M	69	47	32.10	2.53	2NTT	RL: 0.3x0.2
III-25	F	50	37	3.56	1.58	NTT	Negative
IV-44	F	27	15	356.00	11.51	NTT	RL: 1.5x1.0x1.1
IV-46	F	24	16	<2.00	0.68	2TT + BLND	Negative
III-27	F	38	23	43.10	3.08	2TT	Negative

M, male; F, female; TT, total thyroidectomy; 2TT, total thyroidectomy in the second operation; BLND, bilateral lymph node dissection; RL, right lobe; IL, isthmus; LL, left lobe; N, no; Y, yes; NA, not available.

Table II. Two-tailed Pearson correlation analysis of biochemical markers in 11 patients with MTC identified by *rearranged during transfection* mutation screening.

Biochemical marker/tumor volume	CEA, ng/ml (median, 16.57 ng/ml)	Tumor volume, cm ^{3b} (median, 0.573 cm ³)
Calcitonin, pg/ml (median, 285 pg/ml)		
r	0.975 ^a	0.984 ^a
P-value	<0.001	<0.001
CEA, ng/ml (median, 16.57 ng/ml)		
r	-	0.994 ^a
P-value	-	<0.001

^aTwo-tailed P<0.01. ^bTumor volume = length x width²/2. CEA, carcinoembryonic antigen; r, correlation coefficient.

on the absence of intestinal obstruction or pruritic lichenoid skin lesions located on the upper back. Following the present screening, patients IV-36, III-13, III-18, IV-28 and IV-44 underwent total thyroidectomy with bilateral neck dissection at Beijing Tongren Hospital.

Finally, the Ct and CEA levels of the patients were compared using SPSS (Pearson correlation analysis), and the results are summarized in Table II. It was demonstrated that an increase in CEA levels correlated with an increase in Ct levels, according to Pearson correlation analysis in patients with MTC without surgery. It was also revealed that Ct and CEA levels significantly (P<0.001) correlated with tumor volumes.

Discussion

As all the *RET* mutation carriers in the present study exhibited the C634Y/D707E mutation, codons 707 and 634 were considered as the cis double mutation. Although C634Y is a common mutation (6), the double mutation of D707E together

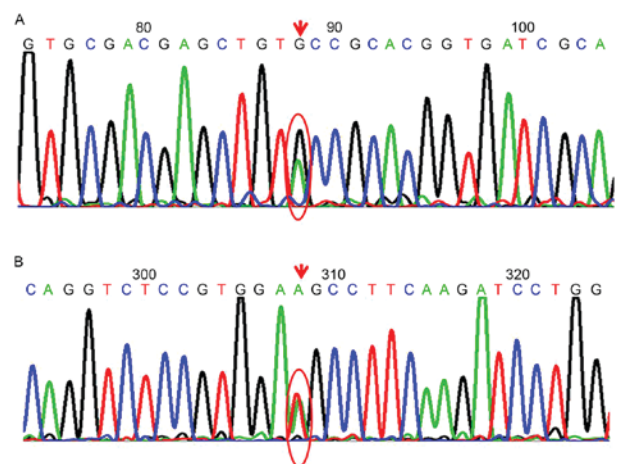


Figure 2. Point mutations identified in *rearranged during transfection*. (A) Base G was replaced by A (complementary chain C>T) at position chr10-43609949. (B) Base T was replaced by A (complementary chain A>T) at position chr10-43610169. Downward arrow, base mutation position; red circle, non-mutated base and mutated base all exist.

Table III. Characteristics of 6 patients with MTC with available biochemical marker measurements who underwent total thyroidectomy.

Patient	Sex	Age, years	Age at first surgery, years	Preoperative Ct, pg/ml	Preoperative CEA, ng/ml	Surgery	MTC, cm	TNM staging	Post-operative CT, pg/ml	Post-operative CEA, ng/ml
IV-46	F	24	16	NA	NA	2TT + BLND	L: 3.0x2.0x1.0	T2N1bM0 (IVA)	<2.00	0.68
III-13	F	62	42	>2,000.00	46.57	2TT + BLND	L: 2.1x1.8x1.5, 2.5x1.2x0.6	T2N1bM0 (IVA)	4.21	18.80
III-18	M	48	48	394.00	17.00	TT + BLND	L: 1x1x1, R: 1.5x1x0.8	T1N1bM0 (IVA)	6.90	2.32
IV-28	F	25	25	481.00	27.72	TT + BLND	Multiple foci: L: 0.8x0.6x0.5, 0.6x0.5x0.4, R: 1.2x1.1x1.1	T4N1bM0 (IVB)	<2.00	1.58
IV-36	F	27	25	1,961.00	258.86	TT + BLND	L: 2.5x2x2, R: 4x3x2	T2N1bM0 (IVA)	<2.00	14.83
IV-44	F	28	18	356.00	11.51	2TT + BLND	R: 1.3x0.8x0.8	T1N1bM0 (IVA)	NA	NA

M, male; F, female; Ct, calcitonin; CEA, carcinoembryonic antigen; NA, not available; TT, total thyroidectomy; 2TT, total thyroidectomy in the second operation; BLND, bilateral lymph node dissection; MTC, medullary thyroid carcinoma; TNM, tumor-node-metastasis; R, right lobe; L, left lobe.

with C634Y, or the single D707E mutation, has not been reported thus far. However, the effect of this double mutation on MEN2A disease remains unknown. As demonstrated previously, the singular D707E *RET* mutation by itself may serve a weak or none pathogenic role in the development of MTC (6). However, when combined with the known C634Y mutation, this D707E mutation may exert a modifying effect such as other polymorphisms in the *RET* gene (11). As a result, the transforming activity of *RET* may be intensified by this double mutation compared with that of each individual mutation alone (8,10). Additional studies are required to confirm whether this hypothesis is correct. Individuals in the present pedigree who carried the double mutation displayed significant variations in disease processes such as age of onset, transfer rate and severity, which may be due to the combined results of different external environment and the involvement of other unknown genetic mutations.

Among the 33 mutation carriers, including the 5 deceased patients and patient II-4, the sex female: male ratio was 1.06 (17:16). In the cohort of the present study, only 4 patients were identified to suffer from PHEO, with a median age of 37 years at diagnosis. However, it has been known that the development of PHEO is slow compared with that of MTC, and that the majority of PHEO symptoms in MEN2 occur in the third to sixth decade of life (6). Therefore, more PHEO events may occur in the present pedigree in the future as previously reported (12).

Hereditary MTC progresses from preneoplastic C-cell hyperplasia, and is a gradual process (13,14). It will take a long time to accomplish this change in the majority of cases, but the malignant transformation of C-cells is inevitable in C-cell hyperplasia (13,14). Although MTC accounts for ~2% of all types of thyroid cancer, ≤13.4% of all thyroid cancer mortalities have been attributed to MTC (15,16). At present, the only therapeutic option for MTC is early detection or/and prophylactic surgery, as MTC exhibits a low response to existing chemotherapy or radiotherapy, and other efficacious systemic therapies are lacking (6). C-cells are located predominantly at the junction of the upper third and lower two-thirds of the thyroid gland, but they may be identified throughout the entire gland (14). Theoretically, every C-cell possesses the potential of being malignantly transformed (14). A total of ~50% of individuals diagnosed with MTC who had undergone total thyroidectomy and neck nodal dissections exhibited disease recurrence (6). Therefore, it is important to remove the whole thyroid completely during the first treatment of MTC, as post-operative normalization of increased Ct levels or biochemical cure are more frequently achieved at initial surgery compared with those at subsequent surgeries (17).

Similar to previous studies (18), persistent or recurrent disease developed in the patients of the present study who underwent inappropriate initial thyroid surgeries that were performed in previous decades (III10, III23, III24, III27, IV46 presented in Table I, as they had undergone two surgeries prior to the current study). The high recurrence rate greatly affects the quality of life of patients with MTC, particularly because a number of patients with stage IVA (6) were relatively young, as summarized in Table III. Although there are numerous significant determinants of outcome based on a univariate analysis, the age of surgery is the single independent factor associated with

persistent disease in multivariate analyses (6,19). The progression of MTC may be slow, but the progression from C-cell hyperplasia to intrathyroidal MTC, and eventually lymphatic and distant metastatic spread, is correlated with age (19-24). This may be also verified in the present study, in which mortality was almost always caused by this disease or distant metastasis in the patients with MTC without intervention. Timely diagnosis and appropriate surgery are therefore critical.

CEA may be expressed in a number of cancer types, including colorectal, pancreatic and salivary tumors, and thus, it may not be a specific biomarker for MTC (25,26). However, Ct and CEA levels, and particularly their doubling times (6,17), remain effective serum markers of MTC. Ct, which may be released into the bloodstream by external stimuli, is an indispensable tool for the early detection of occult MTC (6). However, unlike Ct, CEA is less susceptible to stimulation as a membrane-bound protein, and therefore, is less suitable than Ct for identifying occult MTC (6). However, variable abnormal preoperative CEA levels were revealed to be associated with lymph node metastases, and may suggest advanced disease (7,17). Machens *et al* (17) demonstrated that surgical cure would be unusual when CEA levels exceeded 30.00 ng/ml, which was associated with central and ipsilateral lateral lymph node metastases. In addition, distant metastasis may be indicated when CEA is >100.00 ng/ml (17). Due to the lack of pre- and post-operative Ct and CEA measures in the majority of patients, and the limited follow-up time, the association between these serum markers and lymph metastases was not effectively explored in the present study. However, it was identified that an increase in CEA levels correlated with an increase in Ct levels according to Pearson correlation analysis in patients with MTC without surgery. Ct and CEA levels were also significantly correlated with tumor volumes. However, whether Ct levels just slightly above the normal upper limit reflect the persistence of tiny occult foci of the tumor, particularly without elevated abnormal CEA levels following total thyroidectomy, remains unknown. Although the exact mechanism of the heterogeneity of clinical features within the same family remains unclear, the levels of Ct and CEA may guide individualized treatment; for example, the decision of the extent of initial/recurrent surgery or the consideration of other adjuvant therapies following surgery.

In conclusion, the double C634Y/D707E germline mutation in the same exon 11 of the *RET* gene was identified in a large Chinese pedigree of MEN2A. A detailed natural clinical history was documented for this pedigree, in which it was revealed that inappropriate therapy led to high recurrence rate and even mortality. It is urgent to disseminate the screening of *RET* mutations in China, as it may identify genetic mutation carriers and asymptomatic patients for effective follow-up and timely surgical procedures. Additional in-depth study is necessary to elucidate the molecular mechanisms of the D707E mutation and its potential joint effects with the other C634Y mutation in the present pedigree.

Acknowledgements

The present study was supported by the Beijing City Health Personnel 'Thou' 100 Level Candidates Project (grant no. 2012-0053) and The Training Project of High-level

Medical Technical Personnel in Health System In Beijing City (grant no. 2013-03-054).

References

- Machens A, Brauckhoff M, Holzhausen HJ, Thanh PN, Lehnert H and Dralle H: Codon-specific development of pheochromocytoma in multiple endocrine neoplasia type 2. *J Clin Endocrinol Metab* 90: 3999-4003, 2005.
- Wells SA Jr, Pacini F, Robinson BG and Santoro M: Multiple endocrine neoplasia type 2 and familial medullary thyroid carcinoma: An update. *J Clin Endocrinol Metab* 98: 3149-3164, 2013.
- Kouvaraki MA, Shapiro SE, Perrier ND, Cote GJ, Gagel RF, Hoff AO, Sherman SI, Lee JE and Evans DB: *RET* proto-oncogene: A review and update of genotype-phenotype correlations in hereditary medullary thyroid cancer and associated endocrine tumors. *Thyroid* 15: 531-544, 2005.
- Brandi ML, Gagel RF, Angeli A, Bilezikian JP, Beck-Peccoz P, Bordi C, Conte-Devolx B, Falchetti A, Gheri RG, Libroia A, *et al*: Guidelines for diagnosis and therapy of MEN type 1 and type 2. *J Clin Endocrinol Metab* 86: 5658-5671, 2001.
- Trimboli P, Giovanella L, Crescenzi A, Romanelli F, Valabrega S, Spriano G, Cremonini N, Guglielmi R and Papini E: Medullary thyroid cancer diagnosis: An appraisal. *Head Neck* 36: 1216-1223, 2014.
- American Thyroid Association Guidelines Task Force, Kloos RT, Eng C, Evans DB, Francis GL, Gagel RF, Gharib H, Moley JF, Pacini F, Ringel MD, *et al*: Medullary thyroid cancer: Management guidelines of the American Thyroid Association. *Thyroid* 19: 565-612, 2009.
- Hu MI, Ying AK and Jimenez C: Update on medullary thyroid cancer. *Endocrinol Metab Clin North Am* 43: 423-442, 2014.
- Toledo RA, Wagner SM, Coutinho FL, Lourenco DM Jr, Azevedo JA, Longuini VC, Reis MT, Siqueira SA, Luon AM, Tavares MR, *et al*: High penetrance of pheochromocytoma associated with the novel C634Y/Y791F double germline mutation in the *RET* protooncogene. *J Clin Endocrinol Metab* 95: 1318-1327, 2010.
- Cranston AN, Carniti C, Oakhill K, Radzio-Andzelm E, Stone EA, McCallion AS, Hodgson S, Clarke S, Mondellini P, Leyland J, *et al*: *RET* is constitutively activated by novel tandem mutations that alter the active site resulting in multiple endocrine neoplasia type 2B. *Cancer Res* 66: 10179-10187, 2006.
- Iwashita T, Murakami H, Kurokawa K, Kawai K, Miyauchi A, Futami H, Qiao S, Ichihara M and Takahashi M: A two-hit model for development of multiple endocrine neoplasia type 2B by *RET* mutations. *Biochem Biophys Res Commun* 268: 804-808, 2000.
- Barbieri RB, Bufalo NE, Secolin R, Silva AC, Assumpção LV, Maciel RM, Cerutti JM and Ward LS: Evidence that polymorphisms in detoxification genes modulate the susceptibility for sporadic medullary thyroid carcinoma. *Eur J Endocrinol* 166: 241-245, 2012.
- Imai T, Uchino S, Okamoto T, Suzuki S, Kosugi S, Kikumori T and Sakurai A: MEN Consortium of Japan: High penetrance of pheochromocytoma in multiple endocrine neoplasia 2 caused by germ line *RET* codon 634 mutation in Japanese patients. *Eur J Endocrinol* 168: 683-687, 2013.
- Sippel RS, Kunnimalaiyaan M and Chen H: Current management of medullary thyroid cancer. *Oncologist* 13: 539-547, 2008.
- Dionigi G, Bianchi V, Rovera F, Boni L, Piantanida E, Tanda ML, Dionigi R and Bartalena L: Medullary thyroid carcinoma: Surgical treatment advances. *Expert Rev Anticancer Ther* 7: 877-885, 2007.
- Enewold L, Zhu K, Ron E, Marrogi AJ, Stojadinovic A, Peoples GE and Devesa SS: Rising thyroid cancer incidence in the United States by demographic and tumor characteristics, 1980-2005. *Cancer Epidemiol Biomarkers Prev* 18: 784-791, 2009.
- Kebebew E, Ituarte PH, Siperstein AE, Duh QY and Clark OH: Medullary thyroid carcinoma: Clinical characteristics, treatment, prognostic factors, and a comparison of staging systems. *Cancer* 88: 1139-1148, 2000.
- Machens A, Ukkat J, Hauptmann S and Dralle H: Abnormal carcinoembryonic antigen levels and medullary thyroid cancer progression: A multivariate analysis. *Arch Surg* 142: 289-294, 2007.
- Chen Z, Qi X, Fei J, Yu X, Zhao Y, Zhao J, Jin H, Wang J, Ying R and Zhang X: Multiple endocrine neoplasia type 2A caused by a p.C618R *RET* proto-oncogene mutation in a Chinese pedigree. *Zhonghua Yi Xue Yi Chuan Xue Za Zhi* 31: 348-351, 2014 (In Chinese).

19. Schreinemakers JM, Vriens MR, Valk GD, de Groot JW, Plukker JT, Bax K, Hamming JF, van der Luijt RB, Aronson DC and Borel Rinkes IH: Factors predicting outcome of total thyroidectomy in young patients with multiple endocrine neoplasia type 2: A nationwide long-term follow-up study. *World J Surg* 34: 852-860, 2010.
20. Niederle B, Sebag F and Brauckhoff M: Timing and extent of thyroid surgery for gene carriers of hereditary C cell disease-a consensus statement of the European society of endocrine surgeons (ESES). *Langenbecks Arch Surg* 399: 185-197, 2014.
21. Machens A, Ukkat J, Brauckhoff M, Gimm O and Dralle H: Advances in the management of hereditary medullary thyroid cancer. *J Intern Med* 257: 50-59, 2005.
22. Kaserer K, Scheuba C, Neuhold N, Weinhäusel A, Vierhapper H and Niederle B: Recommendations for reporting C cell pathology of the thyroid. *Wien Klin Wochenschr* 114: 274-278, 2002.
23. Kaserer K, Scheuba C, Neuhold N, Weinhäusel A, Haas OA, Vierhapper H and Niederle B: Sporadic versus familial medullary thyroid microcarcinoma: A histopathologic study of 50 consecutive patients. *Am J Surg Pathol* 25: 1245-1251, 2001.
24. Wolfe HJ, Melvin KE, Cervi-Skinner SJ, Saadi AA, Juliar JF, Jackson CE and Tashjian AH Jr: C-cell hyperplasia preceding medullary thyroid carcinoma. *N Engl J Med* 289: 437-441, 1973.
25. Kurzrock R, Atkins J, Wheeler J, Fu S, Naing A, Busaidy N, Hong D and Sherman S: Tumor marker and measurement fluctuations may not reflect treatment efficacy in patients with medullary thyroid carcinoma on long-term RET inhibitor therapy. *Ann Oncol* 24: 2256-2261, 2013.
26. Shively JE and Beatty JD: CEA-related antigens: Molecular biology and clinical significance. *Crit Rev Oncol Hematol* 2: 355-399, 1985.